Is Salvage Surgery for Large Vestibular Schwannomas After Failed Gamma-knife Radiosurgery More Challenging?

Lucas Troude (lucas.troude@ap-hm.fr)
Aix-Marseille Universite https://orcid.org/0000-0003-2995-4820

Mohamed Boucekine
Department of statistical analysis, Faculté des Sciences médicales et Paramédicales, Aix-Marseille Université (AMU) - 27 bd Jean Moulin 13385 Marseille, France

Anne Balossier
Department of Neurosurgery, Timone University Hospital, APHM-AMU - 264 Rue Saint-Pierre, 13385 Marseille, FRANCE

Guillaume Baucher
Department of Neurosurgery, North University Hospital, APHM-AMU Chemin des Bourrely, Marseille 13015, FRANCE

Jean-Pierre Lavieille
Department of Neurosurgery, North University Hospital, APHM-AMU Chemin des Bourrely, Marseille 13015, FRANCE

Jean Régis
Department of Neurosurgery, Timone University Hospital, APHM-AMU - 264 Rue Saint-Pierre, 13385 Marseille, FRANCE

Pierre-Hugues Roche
Department of Neurosurgery, North University Hospital, APHM-AMU Chemin des Bourrely, Marseille 13015, FRANCE

Research Article

Keywords: Facial nerve, failed radiosurgery, Gamma Knife Surgery, salvage surgery, subtotal resection, tumor control, vestibular schwannoma

Posted Date: June 7th, 2021

DOI: https://doi.org/10.21203/rs.3.rs-560835/v1

Version of Record: A version of this preprint was published at Neurosurgical Review on July 16th, 2021. See the published version at https://doi.org/10.1007/s10143-021-01604-3.

Abstract

Objectives: In order to verify whether a previous Gamma-Knife surgery (GKS) treatment could influence the oncological and functional outcome in large vestibular schwannoma (VS) surgery, we have compared group of patients operated on for large VS after failed-GKS to a group of genuine VS that underwent the same functional nerve-sparing resection technique regimen in the same period.

Methods: Single center retrospective cohort study of 23 consecutive GKS-failure and 170 genuine VS patients operated on between April 2003 and March 2019. After resection, patients were allocated to a Wait-&-rescan or an upfront GKS policy.

Results: At last follow-up examination, the facial nerve function was good (House-Brackmann Grades I or II) in 95% of the GKS-failure and 84% of the genuine VS patients (p=.25). The median volume of tumor residue was .56cc in the GKS-failure group, and .62cc in the genuine VS group (p=.70). Tumor control was achieved in 91% and 83% of cases with a mean follow-up of 74 and 63 months in the GKS-failure and the genuine VS populations, respectively. The 1-, 5- and 7-year progression free survival were 100%, 95% & 85% respectively in the GKS-failure group, and 97%, 80% & 81% in the genuine VS group (p=.27).

Conclusion: Despite significant modifications of the microsurgical environment associated to salvage surgery after GKS-failure, a functional nerve-sparing resection is an effective strategy to optimize the results on facial nerve function, with similar long-term tumor control to those observed in the genuine VS population.

Introduction

The invasiveness and reported tumor growth control of 92 to 98% tend to propose the Gamma-knife surgery (GKS) as one of the established standard treatments for small to middle vestibular schwannomas (VS) [6,12,15,21-23]. Salvage surgery after failed GKS have been reported in only 1.57 to 5% of cases [6,12,15,21-23]. Some authors asserted that previous radiosurgery may significantly complicate this resection due to post-GKS fibrosis and severe adhesion to the neurovascular structures, which lead to additional morbidity [14,19,28,29]. Radical resection of those tumors are then associated to a higher risk of permanent postoperative facial nerve (FN) deficit [2,20]. In an effort to reduce the incidence of FN palsy, alternative strategies of non-total resections, a so called “Functional Sparing Surgery” policy, has emerged over the past 20 years [5,8,9,17,30,32]. In order to verify whether a previous GKS treatment could hamper the oncological and functional outcome, we conducted a comparative study between patients operated on for large VS after failed-GKS to a consecutive group of genuine VS that underwent the same functional nerve-sparing resection technique regimen in the same period.

Methods

All consecutive patients who underwent a salvage surgical treatment of large Koos Grade IV VS [13] after a failed GKS, between April 2003 and March 2019 were enrolled in this retrospective cohort study. All of these patients in have been previously treated in our institution, using the same GKS protocol (see below).

GKS failure was defined as the need to deliver salvage surgery because of worsening symptoms or continuous growth of the VS. The decision for a second stair treatment after regrowth is taken extremely cautiously in our institution because of the reported transient swelling remodeling of VSs within 3 years after GKS treatment that turned out on longer follow-up to be pseudo-progression with subsequent tumor control [1,16,18,24,35]. In order to verify whether previous GKS treatment could influence the oncological and functional outcome, we compared this group to a group of consecutive patients operated on for large genuine VSs in the same period, excluding those who reported history of previous treatment different than GKS (radiotherapy, Cyber Knife, microsurgery). Two patients harboring post-GKS growing tumors were diagnosed malignant peripheral nerve sheath tumors (over 3606 VSs treated with GKS in our institution – rate $5/10^4$) and were excluded from the analysis (see Flow-chart Figure 1).

An otoneurosurgical team performed the microsurgical resection via either an enlarged translabyrinthine or retrosigmoid approach. The diagnosis of VS was histologically confirmed in all cases. Informed consent of all patients was obtained, and our institutional local ethical committee approved this study (Aix-Marseille University Ethics Committee - Authorization number: 2018-24-01-003).

Patient characteristics:

Clinical features such as FN function (scored according to the House & Brackmann Classification (HB)) [7], cochleo-vestibular symptoms including Gardner-Robertson Hearing Scale (G&R) [3], and radiological examinations (including volumetric measurements performed pre- and postoperatively on axial Gadolinium-enhanced T1 weighted MR images– iPlan 3.0 Cranial *Brainlab*, Munich, Germany) [33] were recorded at presentation and during follow-up. Surgical findings (such as post-GKS arachnoiditis and severe adhesion to the neurovascular structures) were extracted from a systematic analysis of the operative report and recorded surgical video.

Tumor regrowth was defined as a volume increasing of the tumor remnant of more than 20% as compared to the first postoperative MRI [33].

Surgical protocol:

Monitoring of the FN is mandatory. An exceptional dorsal course of the FN was checked by the means of visual control and systematic mapping of the dorsal part of the tumor surface (under 0.3 mAp stimulation – NIM-Response® 3.0 *Medtronic* Xomed, Jacksonville, FL). The tumor capsule was opened and extensive intracapsular debulking was carried-out using an ultrasonic aspirator. Thresholds of 0.05mA stimulation were performed throughout the tumor removal. The origin of the FN at the brainstem level was identified at the inferior pole of the schwannoma. The anterograde dissection was conducted at the close vicinity of the FN all the way to the porus. The intraoperative decision to interrupt the resection was driven by the evidence of critical adhesion of the tumor capsule to the facial nerve and /or deterioration of the electromyography EMG responses during stimulation [31]. The interruption of FN dissection was decided in cases of decreasing amplitude of the EMG recorded responses despite repeated stimulation at 0.2 mA. The patient was informed before the operation of the possibility of leaving a tumor residue.

Postoperative Outcome:

A Gadolinium-enhanced MRI was performed 6 months after surgery to assess the tumor residue. According to postoperative FN palsy, the volume of the tumor residue and patient age, a Wait-&-rescan or an upfront Gamma Knife Surgery (GKS) policy was proposed to the patient [30]. Practically, we preferentially allocated to the W&reS group those who displayed a small tumor remnant (NTR), the ones who were affected by a postoperative FN deficit and elderly patients. Conversely, larger tumor remnants (STR or PR), those who presented with grade I-II facial nerve function and younger patients were predominantly oriented toward GK. Clinico-radiological follow-up was planned at 6 and 12 months after resection, and subsequently at 2, 3, 5, 7 & 10 years after surgery, and then once every 3 years thereafter.

According to the first postoperative MRI, extent of resection was classified as gross total resection (100% tumor resection), near total resection (tumor remnant <5%), subtotal resection (tumor remnant between 5% and 10%), or partial resection (tumor remnant >10%).

Preoperative or postoperative Radiosurgical Protocol

Treatment was delivered using a Leksell Gamma Knife (Elekta Instrument AB, Stockholm, Sweden) according to a previously published methodology [25]. The median dose directed at the tumor margin was 12 Gy, and the median isodose to the margin was 50%.

Statistical Analysis

Statistics were performed with IBM Corp. Released 2012. IBM SPSS Statistics for Windows, Version 21.0. Armonk, NY: IBM Corp. Categorical variables are presented as numbers and percentages; Continuous variables as means ± SD. The significance of baseline differences was determined by the chi-square test, Fisher's exact test, or the unpaired t-test, as appropriate. Statistical significance was defined by a two-sided p-value <0.05. The event was defined as an increasing of the tumor residue >20% as compared to first postoperative MRI for the survival analysis. Survival was estimated by the Kaplan–Meier method. Survival differences were assessed by the log-rank test.

Results

Population Study (GKS-failuregroup): (Table 1)

Twenty-three consecutive patients who underwent salvage surgery for large VS after GKS failure were enrolled in this study, including 12 females and 11 males, with a mean age of 56 years (range 28-73). Every patient included in the study showed evidence of progressive tumor growth after GKS (mean tumor growth x 946 – range 126-5161). The mean delay between GKS and salvage surgery was 66 months (median 47 months). One patient included in the analysis had been operated on before the delay of 3 years after GKS (23months) because of worsening symptoms related to tumor growth. This patient had received a radiosurgical treatment for a Koos IV VS.

Clinical Features: (Table 1)

Before GKS treatment, 16 (70%) patients presented with serviceable hearing, including 6 (26%) G&R Class 1 and 10 (43%) Class 2. All of the patients previously treated with GKS experienced hearing loss related to tumor growth. At the time of salvage surgery, none of the patient presented with serviceable hearing anymore.

Ten (43%) patients reported balanced instability, 10 (43%) presented with tinnitus, 2 (9%) with vertigo, and cerebellar ataxia in 4 cases (17%). Three (13%) patients presented symptoms related to hydrocephalus treated by ventriculoperitoneal shunting before GKS treatment. Trigeminal neuropathy with facial hypoesthesia was present in 13 (57%) patients. Five (22%) patients suffered from trigeminal neuralgia. Two patients (9%) presented preoperative facial weakness (HB Grade II, III).

Radiological Features: (Table 1)

At the time of the first stage GKS treatment, 1 patient harbored a Koos Grade I VS (4% - VS volume 0.3cc), 7 Koos Grade 2 VS (30% - mean VS volume 1.6cc), 10 Koos Grade 3 VS (44% - mean VS volume 2.5cc) and 5 Koos Grade IV VS (22% - mean VS volume 6.0cc).

At the time of salvage surgery, all patients harbored a Koos IV VS. The mean VS extrameatal diameter was 26 mm (range 19-39 / median 25 mm); the mean VS volume was 10 cc (range 4-22 / median 8 cc). Four of the tumors (17%) displayed a cystic component. Two (9%) patients presented radiological hydrocephalus (Evans ratio > 0.3); none had received CSF shunting before tumor resection (but three patients had received VP shunting that were placed before radiation).

Surgical Features: (Figures 2&3 - Table 1)

Nine (39%) patients underwent surgery via a translabyrinthine and 14 (61%) via a retrosigmoid approach. The mean operative time was 338 min (150-720); the translabyrinthine mean operative time was 479 min (370-720) vs 251 min (150-350) in the retrosigmoid group.

The tumor consistency was soft and lipidized in 13 cases (57% - Figure 2), whereas indurated in 10 (43%). As described in the radiological study, 4 of the tumors (17%) displayed a cystic component. Post-GKS arachnoiditis had been reported in 20 cases (87% - Figure 3). The tumor was highly vascularized in 8 cases (35%). A severe adhesion to the brainstem or cranial nerves was reported in 8 patients (35% - Figure 3).

The overall mean postoperative tumor volume measured on the first postoperative MRI was .56 cc (range .08 - 1.50 / median .52 cc). Two patients (9%) underwent GTR, 9 underwent near total resection (39%), 9 (39%) subtotal resection, and 3 (13%) partial resection.

Histopathological findings:

The irradiated VSs were histologically similar to the genuine ones. The Antoni A (areas composed of Schwann cells that have a spindle cell morphology) and Antoni B patterns (loosely textured and microcystic areas) were both represented as follows: 2 (9%) tumors showed pure Antoni A pattern, 15 (65%) tumors presented pure Antoni B pattern, while 6 (26%) tumors exhibited both Antoni A & B patterns. As a

comparison, 25% of the guenine VSs showed pure Antoni A pattern, 43% presented pure Antoni B pattern, while 32% exhibited both Antoni A & B patterns.

As a reminder, 2 tumors operated on after GKS-failure were diagnosed as MNSTs (Malignant Nerve Sheath Tumors). Both patients have been excluded from the analysis

(Figure 1).

Complications:

One patient (4%) presented postoperative meningitis which was cured under medical treatment. One (4%) postoperative hematoma had been treated by revision surgery and external ventricular drain. This patient retained postoperative permanent CN VI paralysis. No CSF leak occurred and no patient required CSF shunting.

Cranial Nerve Preservation:

Trigeminal nerve:

The patients who displayed a preoperative facial numbness were released from this symptom in 12 cases (92%) after surgery, whereas the other one have improved. None of the patients freed from this symptom before surgery have developed a postoperative facial hypoesthesia.

Cochlear nerve:

None of the patients presented with preoperative serviceable hearing; none reported recovery after surgery.

Facial nerve function: (Table 2)

Immediately after surgery, among the 21 patients with normal preoperative FN function, 19 (90%) retained a good FN function (HB Grades I & II), 1 (5%) displayed an intermediate FN function (HB Grade III), and 1 (5%) a poor FN function (cf. Table 2). No patient exhibited a delayed FN palsy.

At last follow-up examination, good HB Grade I & II FN function was observed in 20 patients (95%). Only one patient (5%) presented moderate deficit (HB Grade III). (cf. Table 2). Exposure keratitis occurred in 4 cases (17%). None of the patients secondarily treated by GKS presented FN deterioration in the long term.

Tumor Control:

The overall mean radiological follow-up was 74 months (range 12-175 / median 64 months). Thirteen patients (54%) were scanned for more than 5 years. Of the 21 patients who had undergone non-total resection of their VS, 11 (52%) had been allocated into a Wait-&-rescan policy and 10 (48%) underwent upfront GKS. The tumor control was achieved in 91% of cases. Two (9%) cases of regrowth were diagnosed during the follow-up period, respectively at 32 and 68 months. The 1-, 5- & 7-year tumor progression free survival (PFS) were 100% (n=23), 95% (n=18) & 85% (n=9), respectively.

During the follow-up period, 2 patients displayed pseudoprogression of their tumor remnants. The first one experienced a secondary regression to the postoperative tumor volume within 107 months, while the remnant of the second one remains >20% than the postoperative tumor volume at the time of analysis, and is therefore defined as regrowth.

Both patients harboring growing residues have been allocated under repeated MRI surveillance without additional treatment. None of the patient who received salvage surgery after a first-stage GKS required a second revision surgery.

Comparison to the genuine VSpopulation: (Figure 4 - Table 2, 3 & 4)

During the study period, 170 patients had undergone microsurgical resection for a large Koos IV VS. The GKS-failure and genuine VS groups differed in sex ratio, age and preoperative VS volume (p<.05) (cf Table 3).

The mean operative time was similar to the GKS-failure population (473 min – p=.93 and 265 min – p=.85, respectively after translabyrinthine and retrosigmoid approaches). The mean postoperative tumor residue was .62cc (median .41cc – p=.70). There was no difference in the occurrence of postoperative complications in the GKS-failure and genuine VS populations (p=.82).

At last follow-up examination, among the 160 patients with normal preoperative FN function, good FN function (HB Grade I & II) was observed in 134 patients (84%), moderate HB Grade III deficit in 25 (15%) of patients, while poor FN outcome were observed in one case (1%) (Table 2). Salvage surgery after GKS failure was not associated to early postoperative (p=.14), three months postoperative (p=.10), nor long-term (p=.25) impaired FN outcomes.

The overall mean radiological follow-up was 63 months (range 12-186 / median 55 months) in the genuine VS population (p=.34). Of the 155 patients who had undergone non-total resection of their VS, 89 (57%) had been allocated into a Wait-&-rescan policy and 66 (43%) underwent upfront GKS. The 1-, 5- & 7-year tumor progression free survival (PFS) were 97% (n=154), 81% (n=66) & 80% (n=49), respectively (Table 4). The tumor control was achieved in 83% of cases. Twenty-seven (17%) cases of regrowth were diagnosed during the FU period. Again, the GKS-failure population did not seem to be related to a higher rate of regrowth of the residues (p=.27 - Figure 4).

Discussion

To the best of our knowledge we display the results of the first comparative study about consecutive GKS-failure and genuine large VSs populations, treated by the same experienced otoneurosurgical group during the same period. The GKS-failure group is made up of a homogenous cohort of patients who underwent the same radiosurgical protocol, were followed up by our team, and diagnosed as failure according to widely accepted criteria.

GKS Failure or Transient Swelling?

Many studies have reported transient swelling remodeling of VSs after GKS treatment, that turned out on longer follow-up to be pseudo-progression with subsequent tumor control [1,16,18,24,35]. Transient expansion was reported to have occurred in 15 to 74% of cases, with a mean increase in volume of 20% [35]. Although most of those pseudo-progression resolved within one year, a 3 years follow-up time period of continuous growth is recommended before conclude to a GKS-failure [1,16,18,24,35]. Anyway, volumetric criteria for the definition of tumor escape vary depending on the volume of the tumor being treated. Indeed, while a tumor volume expansion of more than 100% can be tolerated for intracanalar VSs without further treatment, this range of tumor growth in not acceptable for larger schwannomas. In our study, only one patient harboring a Koos IV VS and who experienced tumor growth after GKS, had been operated on only 23 months after the radiosurgical treatment because of worsening symptoms. Furthermore, our attitude has changed with experience. While we were once reluctant to redo a GKS, evidence of tumor progression, especially for Koos I & II VSs, would led us to propose a second stage GKS before the tumor grows up to a Koos IV VS.

Difficulties of Microsurgery after GKS Failure

A part of the neurosurgical community postulated that low doses delivered on the tumor volume during the GKS procedure would be responsible for more failures, thereby requiring tumor resection significantly more complicated than in genuine VS surgery.

Salvage surgery after GKS-failure is considered to be associated with operative difficulties related to thickening of the arachnoid membrane, loss of the peritumoral arachnoidal plane, high vascularization or tight adherence to the neurovascular structures [14,19,28,29]. In the recent literature, radical resection of large VSs after GKS failure results in about 50% of permanent FN deficit (HB Grade III to VI) [2,4,20,27]. Alternative strategies of nontotal resections have emerged in sporadic large VS surgery for more than 15 years [5,8,9,17,30,32] and previous authors already advocated the need for subtotal resection after GKS failure [2,20].

Although post-GKS arachnoiditis was reported in 87% of our cases in our series, most of the operative dilemmas were related to severe facial nerve or neurovascular structures adherences, (35% of cases in the present study). Despite those reported difficulties, the mean operative time and the mean postoperative tumor residue were similar in the GKS failure and genuine VS populations (p=.88 and p=.70, respectively). Furthermore, we reported in the present study 90% facial nerve function preservation (HB Grades 1&2) in the long-term. Other recent series have reported similar results in patients who underwent subtotal resection after failed-GKS [10,11,26,34]. Comparison between the GKS-failure and genuine populations did not show FN outcome differences in our series (p=.25 – Figure 4, Tables 2 & 4).

Last but not least, two patients (8%) have experienced postoperative complications in the GKS-failure group; no difference could be demonstrated with the genuine VS population (p=.82). Of note, we didn’t observe additional CSF dysfunction nor wound complication consecutive to a surgical intervention in a previously irradiated patient.

How to explain the discrepancy between our "good" results and those of the literature? The department of radiosurgery in our institution is a high volume center, which can legitimately claim a good knowledge of the tumor behavior after GKS. The decision of salvage surgery because of GKS-failure was made after careful analysis of the VS progression, by comparing the sequential radiological data. We report in this study the surgical outcome of an experienced otoneurosurgical group familiar with the functional sparing surgery for large VS. Most of reports about salvage surgery after failed irradiation treatment present a lot of weaknesses that convey inaproporiate message: the decision-making for salvage surgery in a too short time period in a freshly modified post-irradiated environment; inclusion of patients treated with multiple techniques (radiotherapy, GKS, Cyber-Knife…); inexperienced neurosurgeons; low volumes of case load.

The fate of the postoperative tumor residues

Leaving some remnant tumor in order to upgrade the functional outcome could potentially expose the patient to regrowth. Herein we showed that tumor control was achieved in 91% of cases with sequential long term scanning (mean radiological follow-up of 74 months). Those results are concordant to the recent literature of VS subtotal resection after failed GK [10,11,26,34]. Two (9%) cases of regrowth were diagnosed. One of those cases may be considered as a transient swelling of the tumor residue after a proactive postoperative GKS. The patient experienced a 289% tumor volume expansion within 2 years after GKS, followed by a decrease of size, and a +100% tumor volume expansion 3 years after GKS. The volume of the growing tumor residue of the second patient is less than 0.3cc. The patient is allocated to a Wait-&-rescan strategy. Salvage surgery after GKS was not associated to a higher rate of regrowth of the tumor residues as compared to the genuine population in the long term (p=.27).

Limitations

The foremost weakness of our series concerns the difference between numbers of patients included in the post-GKS failure and genuine VS groups. Limitations inherent to the retrospective design of the series can also be pointed at. Both populations were not matched in respect of the tumor volumes and the patients of both groups did not receive the same postoperative treatment regimen (some of the residues were allocated to a Wait-&-rescan strategy; others underwent proactive GKS). The operative findings were subjectively assessed even though we carefully reviewed the video of the surgical procedures.

Conclusions

Failure of treatment is a rare and unpredictable situation after radiosurgery. Evidence of a significant and continuous augmentation of the tumor volume is an indispensable criterion to conclude to failure. Despite significant modifications of the microsurgical environment associated to salvage surgery after GKS-failure, a functional nerve-sparing resection is an effective strategy to optimize the results on facial nerve function with no more complications, and similar long-term tumor control to those observed in the genuine VS population. These findings deserve to be shared with neurosurgical teams who are confronted with this situation and provided to the patients at the decision making time.

Abbreviations

Cerebro-spinal fluid (CSF), Facial nerve (FN), Gamma-Knife surgery (GKS), Gardner & Robertson (G&R), House & Brackmann (HB), Progression free survival (PFS), Vestibular schwannoma (VS).

Declarations

Conflict of interest: None of the authors disclose any conflict of interest in relation with this study.

Disclosure of Funding: None of the authors disclose any financial disclosure in relation with this study.

Availability of data and material: My manuscript has data included as electronic supplementary material.

Code availability: Not applicable

ORCID ID: 0000-0003-2995-4820

Ethics approval: Comité d'Ethique de l'Université d'Aix-Marseille (Authorization number: 2018-24-01-003).

Consent to participate: Informed consent was obtained from all patients

Consent for publication: All patients agreed for publication

Submission Statement: This manuscript has not been previously published in whole or in part or submitted elsewhere for review.

Author contributions: All authors have made substantial contributions so as to qualify for authorship, and have read and approved the final version of this manuscript.

- LT, JPL, JR, PHR: conception and design of the study
- LT, AB, GB: acquisition of data & drafting the Article
- LT, MB: analysis and interpretation of data
- JPL, JR, PHR: critically revising the Article

References

1. Delsanti C, Roche PH, Thomassin JM, et al. Morphological changes of vestibular schwannomas after radiosurgical treatment: pitfalls and diagnosis of failure.*Prog Neurol Surg*. 2008;21:93-7
2. Friedman RA, Berliner KI, Bassim M, Ursick J, Slattery WH 3rd, Schwartz MS, Brackmann DE. A paradigm shift in salvage surgery for radiated vestibular schwannoma. *Otol Neurotol*. 2011 Oct;32(8):1322-8.
3. Gardner G, Robertson JH (1998) Hearing preservation in unilateral acoustic neuroma surgery. *Ann Otol Rhinol Laryngol* 97:55-66

4. Gerganov VM, Giordano M, Samii A, Samii M. Surgical treatment of patients with vestibular schwannomas after failed previous radiosurgery. *J Neurosurg* 2012, 116(4):713-20
5. Haque R, WojtasiewiczTJ, Gigante PR, et al (2011) Efficacy of facial-sparing approach in patients with vestibular schwannomas. *J Neurosurg* 115:917-23
6. Hasegawa T, Kida Y, Kato T, Iizuka H, Kuramitsu S, Yamamoto T: Long-term safety and efficacy of stereotactic radiosurgery for vestibular schwannomas: evaluation of 440 patients more than 10 years after treatment with Gamma Knife surgery. J Neurosurg 118:557-565, 2013.
7. House JW, Brackmann DE (1985) Facial nerve grading system. *Otolaryngol Head Neck Surg* 93:146–7
8. Iwai Y, Ishibashi K, Nakanishi Y, et al. Functional outcomes of salvage surgery for vestibular schwannomas after failed gamma knife radiosurgery. *World Neurosurgery* 2016; PMID:
9. Iwai Y, Ishibashi K, Watanabe Y, et al (2015) Functional preservation after planned partial resection followed by Gamma Knife Radiosurgery for large Vestibular Schwannomas. *World Neurosurg* 84(2):292-300
10. Iwai Y, Yamanaka K, Ishiquro T (2003) Surgery combined with radiosurgery of large acoustic Surg Neurol 59(4):283-289
11. Iwai Y, Yamanaka K, Yamagata K, Yasui T. Surgery after radiosurgery for acoustic neuromas: surgical strategy and histological findings. *Neurosurgery*. 2007;60(2Suppl1):ONS7582;discussion ONS82.
12. Kondziolka D, Lunsford LD, Mclaughlin MR, Flickinger JC: Long-term outcomes after radiosurgery for acoustic neuromas. N Engl J Med. 339:1426–1433, 1998.
13. Koos WT, Day JD, Matula C, et al (1998) Neurotopographic considerations in the microsurgical treatment of small acoustic neurinomas. *J Neurosurg* 88:506–12
14. Lee DJ, Westra WH, Staecker H, Long D, Niparko JK, Slattery WH 3rd: Clinical and histopathological features of recurrent vestibular schwannoma (acoustic neuroma) after stereotactic radiosurgery. Otol Neurotol 24:650–660, 2003.
15. Lunsford LD, Niranjan A, Flickinger JC, Maitz A, Kondziolka D: Radiosurgery of vestibular schwannomas: Summary of experience in 829 cases. J Neurosurg 102 (Suppl):195-199, 2005.
16. Marston AP, Jacob JT, Carlson ML, et al. *Pretreatment growth rate as a predictor of tumor control following Gamma Knife radiosurgery for sporadic vestibular schwannoma.J Neurosurg.* 2017;**127**(2):380-7
17. Monfared A, Corrales CE, Theodosopoulos PV, et al (2016) Facial Nerve Outcome and Tumor Control Rate as a Function of Degree of Resection in Treatment of Large Acoustic Neuromas: Preliminary Report of the Acoustic Neuroma Subtotal Resection Study (ANSRS).*Neurosurgery* 79(2):194-203
18. Nagano O, Higuchi Y, Serizawa T, Ono J, Matsuda S, Yamakami I, Saeki N: Transient expansion of vestibular schwannoma following stereotactic radiosurgery. J Neurosurg 109:811-816, 2008.
19. Pollock BE, Lunsford LD, Kondziolka D, Sekula R, Subach BR, Foote RL, Flickinger JC. Vestibular schwannoma management. Part II. Failed radiosurgery and the role of delayed microsurgery. *J Neurosurg*. 1998;89(6):949-55.

20. Pollock BE: Management of vestibular schwannomas that enlarge after stereotactic radiosurgery: treatment recommendations based on a 15 year experience. Neurosurgery 58:241-248, 2006.
21. Régis J, Carron R, Delsanti C, et al. *Radiosurgery for vestibular schwannomas.Neurosurg Clin N Am.* 2013;**24**(4):521-30
22. Régis J, Carron R, Moucharrafien S, et al. *Role of radiosurgery and stereotactic radiotherapy in the management of vestibular schwannomas.Cancer Radiother*. 2012;**16 Suppl**:S70-8
23. Regis J, Delsanti C, Roche PH. *Editorial: Vestibular schwannoma radiosurgery: progression or pseudoprogression? J Neurosurg*. 2016;**25**:1-3
24. Regis J, Roche PH, Delsanti C, et al. *Stereotactic Radiosurgery for Vestibular Schwannoma. In: Pollock BE, ed. Contemporary Stereotactic Radiosurgery: Technique and Evaluation.* New York: Futura Publishing Company 2002:181-212
25. Régis J, Roche PH, Delsanti C, et al. Modern management of vestibular schwannomas. *Prog Neurol Surg* 2007, 20:129–141
26. Roche PH, Khalil M, Thomassin JM, Delsanti C, Régis J. Surgical removal of vestibular schwannoma after failed gamma knife radiosurgery. *Prog Neurol Surg*. 2008;21:152-157.
27. Samii M, Gerganov V, Samii A. Improved preservation of hearing and facial nerve function in vestibular schwannoma surgery via the retrosigmoid approach in a series of 200 patients. *J Neurosurg*. 2006, 105(4):527-35.
28. Schulder M, Sreepada GS, Kwartler JA, Cho ES: Microsurgical removal of a vestibular schwannoma after stereotactic radiosurgery: Surgical and pathologicaln findings. Am J Otol 20:364–368, 1999.
29. Shuto T, Inomori S, Matsunaga S, Fujino H: Microsurgery for vestibular schwannoma after gamma knife radiosurgery. Acta Neurochir (Wien) 150:229-234, 2008.
30. Troude L, Boucekine M, Montava M, Lavieille JP, Régis J, Roche PH (2018) Adjunctive Gamma-Knife Surgery or Wait & Scan policy after optimal resection of large vestibular schwannomas: clinical and radiological outcomes. *World Neurosurgery* DOI: 1016/j.wneu.2018.07.093
31. Troude L, Boucekine M, Montava M, Lavieille JP, Régis JM, Roche PH. Predictive Factors of Early Postoperative and Long-Term Facial Nerve Function After Large Vestibular Schwannoma Surgery. World Neurosurg. 2019, 127:e599-e608. doi: 10.1016/j.wneu.2019.03.218. Epub 2019 Mar 28. PMID: 30930324
32. Van de Langenberg R, de Bondt BJ, Nelemans PJ, et al (2009) Follow-up assessment of vestibular schwannomas: volume quantification versus two-dimensional measurements. *Neuroradiology* 51:517–24
33. Van de Langenberg R, Hanssens PE, Van Overbeeke JJ, et al (2011) Management of large vestibular schwannoma. Part I. Planned subtotal resection followed by Gamma Knife surgery: radiological and clinical aspects. *J Neurosurg* 115:875-84
34. Wise SC, Carlson ML, Tveiten ØV, Driscoll CL, Myrseth E, Lund-Johansen M, Link MJ. Surgical salvage of recurrent vestibular schwannoma following prior stereotactic radiosurgery. *Laryngoscope*. 2016, 126(11):2580-2586.

35. Yu CP, Cheung JY, Leung S, Ho R: Sequential volume mapping for confirmation of negative growth in vestibular schwannomas treated by gamma knife radiosurgery. J Neurosurg 93 [Suppl 3]:82–89, 2000.

Tables

Table 1: GKS Failure-population characteristics

Characteristic	Nb	
M/F (%)	12 (52) / 11 (48)	67 (39) / 103 (61)
Mean age in years (range)	56 (28-73)	50 (47-53) / 52
Clinical features (%)		
G&R Hearing Class		
1	0	10 (6)
2	0	42 (25)
3	8 (35)	39 (23)
4	7 (30)	48 (28)
5	8 (35)	31 (18)
balanced instability	10 (43)	77 (45)
tinnitus	10 (43)	58 (34)
vertigo	2 (9)	26 (15)
cerebellar ataxia	4 (17)	18 (11)
axial symptoms	0	5 (3)
Trigeminal hypoesthesia	13 (57)	75 (44)
Trigeminal neuralgia	5 (22)	5 (3)
Facial weakness	2 HB Grade II (17)	10 (6)
Radiological features (%)		
VS Koos Grade IV	23 (100)	170 (100)
VS side right/left	14 (61) / 9 (39)	82 (48) / 88 (52)
Cystic VS	4 (17%)	33 (19)
Mean VS diameter in mm (range)	26 (19-39)	31 (30-33) / 30
Mean VS volume in cc (range)	10 (4-22)	17 (15-20) / 14
Hydrocephalus		
- Radiological	2	27 (16)
- Symptomatic	0	17 (10)
- Drainage before VS resection	0	8 (5)
Surgical Features		
TL (%)	9 (39)	46 (27)

mean time TL in min (range)	479 (370-720)	473 (320-780)
RS (%)	14 (61)	124 (73)
mean time RS in min (range)	251 (150-350)	265 (140-480)
Extent of Resection (%)		
GTR	2 (9)	15 (9)
NTR	9 (39)	101 (64)
SBT	9 (39)	29 (18)
PR	3 (13)	14 (9)
Postop vol Residue in cc (range) / Median	0.56 (.08-1.5) / 0.52	0.62 (.04-16.95) / 0.41
Mean Follow-Up (IC 95%) / Median	74 (12-175) / 64	63 (12-186) / 55

M: male. F: female. MS: microsurgery. G&R: Gardner & Robertson. HB: House-Brackmann. GTR: gross total resection. NTR: near total resection. PR: partial resection. RS: retrosigmoid approach. STR: subtotal resection. TL: translabyrinthine approach. VS: vestibular schwannoma

Table 2: Postoperative facial nerve function after microsurgical resection of large vestibular schwannomas in GKS-failure and genuine VS populations with normal (House & Brackmann Grade I) preoperative function. Salvage surgery after GKS failure was not associated to early postoperative (p=.14), three months postoperative (p=.10), nor long-term (p=.25) impaired FN outcomes.

		Early Postop (%)		**3 months Postop (%)**		**Last FU (%)**	
House & Brackmann Scale		**GKS-failure Population**	**Genuine VS Population**	**GKS-failure Population**	**Genuine VS Population**	**GKS-failure Population**	**Genuine VS Population**
Good FN function	I	14 (66)	57 (36)	17 (80)	74 (46)	18 (85)	99 (62)
	II	5 (24)	42 (26)	2 (10)	40 (25)	2 (10)	35 (22)
Intermediate FN function	III	1 (5)	20 (13)	2 (10)	18 (11)	1 (5)	25 (15)
Poor FN function	IV	1 (5)	22 (14)	1 (5)	20 (13)	0	0
	V	0	17 (10)	0	7 (4)	0	1 (1)
	VI	0	2 (1)	0	1 (1)	0	0
p-value		**0.142**		**0.103**		**0.252**	

FN: facial nerve. **FU:** Follow-up. **Postop:** postoperative

Table 3: Comparison of sex ratio, age and preoperative extrameatal tumor diameter & volume in the GKS-failure and genuine VS populations

Characteristic	GKS-failure Population mean (CI 95%) / median	Genuine VS Population mean (CI 95%) / median	p-value
M/F (%)	11 (48) / 12 (52)	67 (39) / 103 (61)	.04
Age in years	57 (52-62) / 56	50 (47-53) / 52	.00
Preop VS diameter in mm	26 (24-29) / 25	31 (30-33) / 30	.00
Preop VS volume in cc	10 (7-12) / 8	17 (15-20) / 14	.00

M: male. F: female. FU: Follow-up. Preop: preoperative. VS: vestibular schwannoma

Table 4: Tumor regrowth-free survival analysis in the GKS-failure and genuine VS populations

Progression-Free Survival		%	CI 95-	CI 95+
GKS-failure Population	1-yr	100	100	100
	5-yr	95	69	99
	7-yr	85	50	96
Genuine VS Population	1-yr	97	93	99
	5-yr	81	73	87
	7-yr	80	71	86

Figures

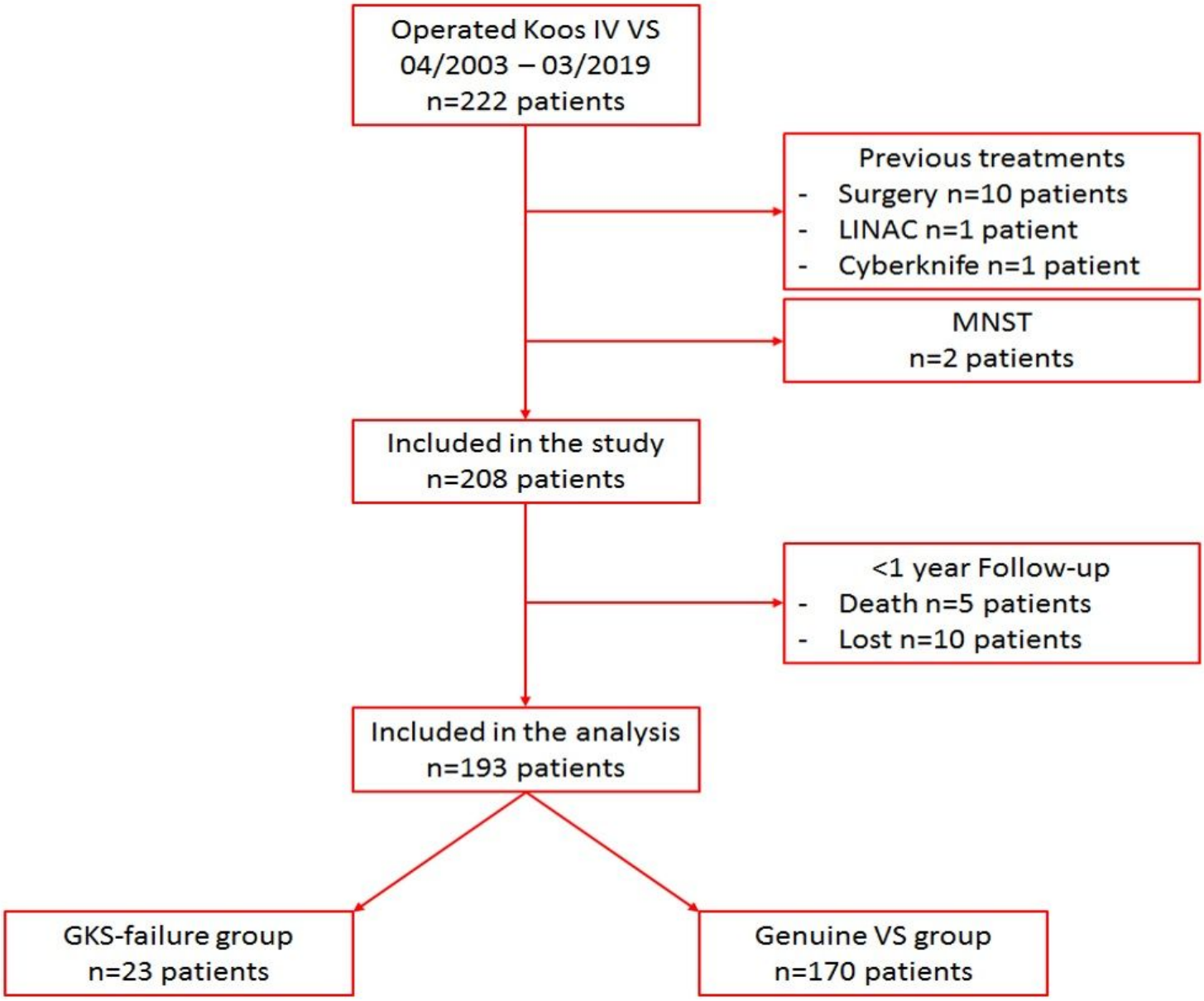

Figure 1

Flow-chart of the study population. Patients who reported history of previous treatment different than GKS (radiotherapy, Cyber Knife, microsurgery), those who were diagnosed malignant tumors (MNST), and those who presented a postoperative follow-up period inferior to 1 year were excluded from the analysis.

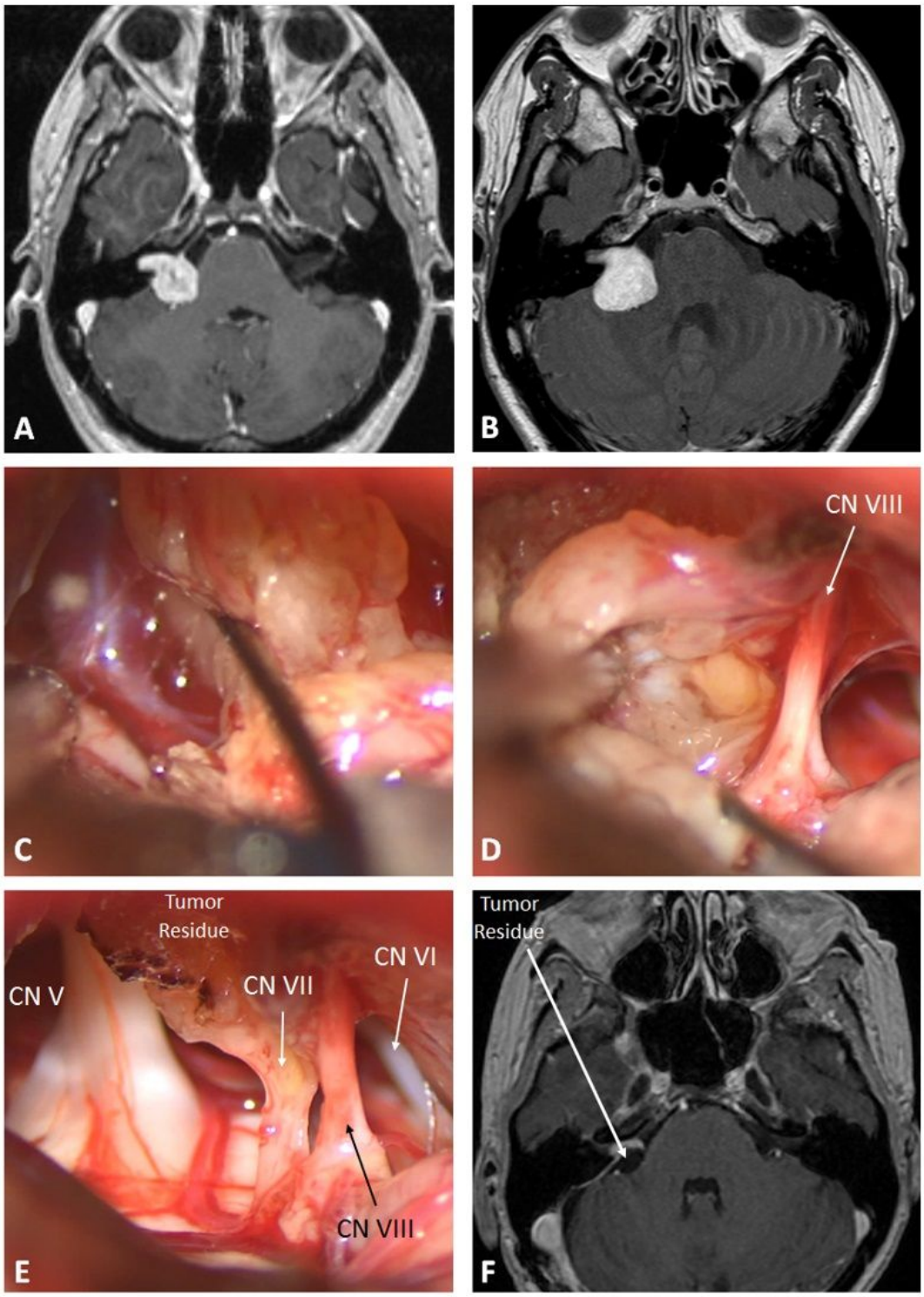

Figure 2

Optimal tumor resection in large vestibular schwannomas (VS) surgery after failed GKS - Significant modifications of the microsurgical environment associated to salvage surgery after GKS-failure. A: A 42-year-old patient underwent GK radiosurgery for a Koos III VS. B: Four years after GKS, the preoperative axial contrast-enhanced T1-weighted MRI showed a Koos IV VS. The diagnosis of GKS failure was confirmed. An optimal resection of the left Koos Grade IV VS with a functional sparing technique was decided. C & D: Peroperative views. Significant modifications of the microsurgical environment associated to salvage

surgery after GKS-failure were noticed: post-GKS arachnoiditis (Fig 2C) and severe adhesion of the surrounding vascular structures to the tumor (Fig 2D). E: The intraoperative decision to interrupt the resection was driven by the evidence of critical adhesion to the facial nerve. F: Postoperative axial contrast-enhanced T1-weighted MRI showing the tumor residue after a near total resection of the VS. The patient retained good postoperative FN function (HB Grade 2 immediately after surgery – HB Grade 1 one year after surgery). VS: vestibular schwannoma.

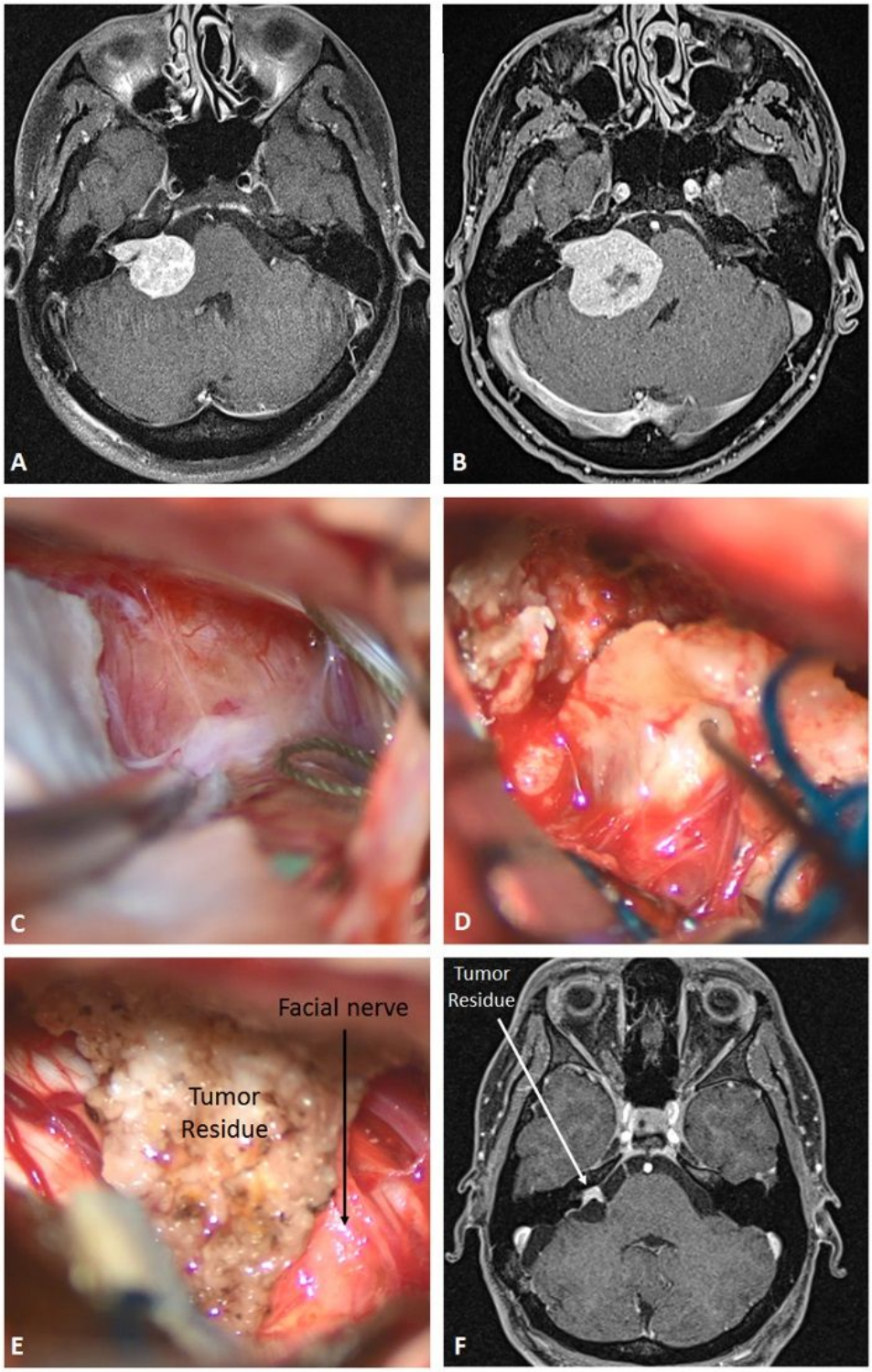

Figure 3

Optimal tumor resection in large vestibular schwannomas (VS) surgery after failed GKS - No consequences of the GKS on the microsurgical environment. A: A 50 years-old women underwent GK radiosurgery for a little Koos III VS. The patient suffered from trigeminal neuralgia. B: Four years after GKS, the VS as grown continuously and the patient reported a resurgence of neuralgia. A salvage surgery was decided. C & D: The tumor was soft and lipidized, and easily removable from the surrounding structures. E: End of the tumor resection. The cranial nerves (CN) are intact, even CN VIII. A tumor residue is left against CN VII. F: Postoperative axial contrast-enhanced T1-weighted MRI showing the tumor residue after a near total resection of the VS. The patient retained Grade 1 postoperative FN function. The intensity and frequency of the preoperative neuralgia decreased after surgery, but the patient was not totally freed from this symptom.

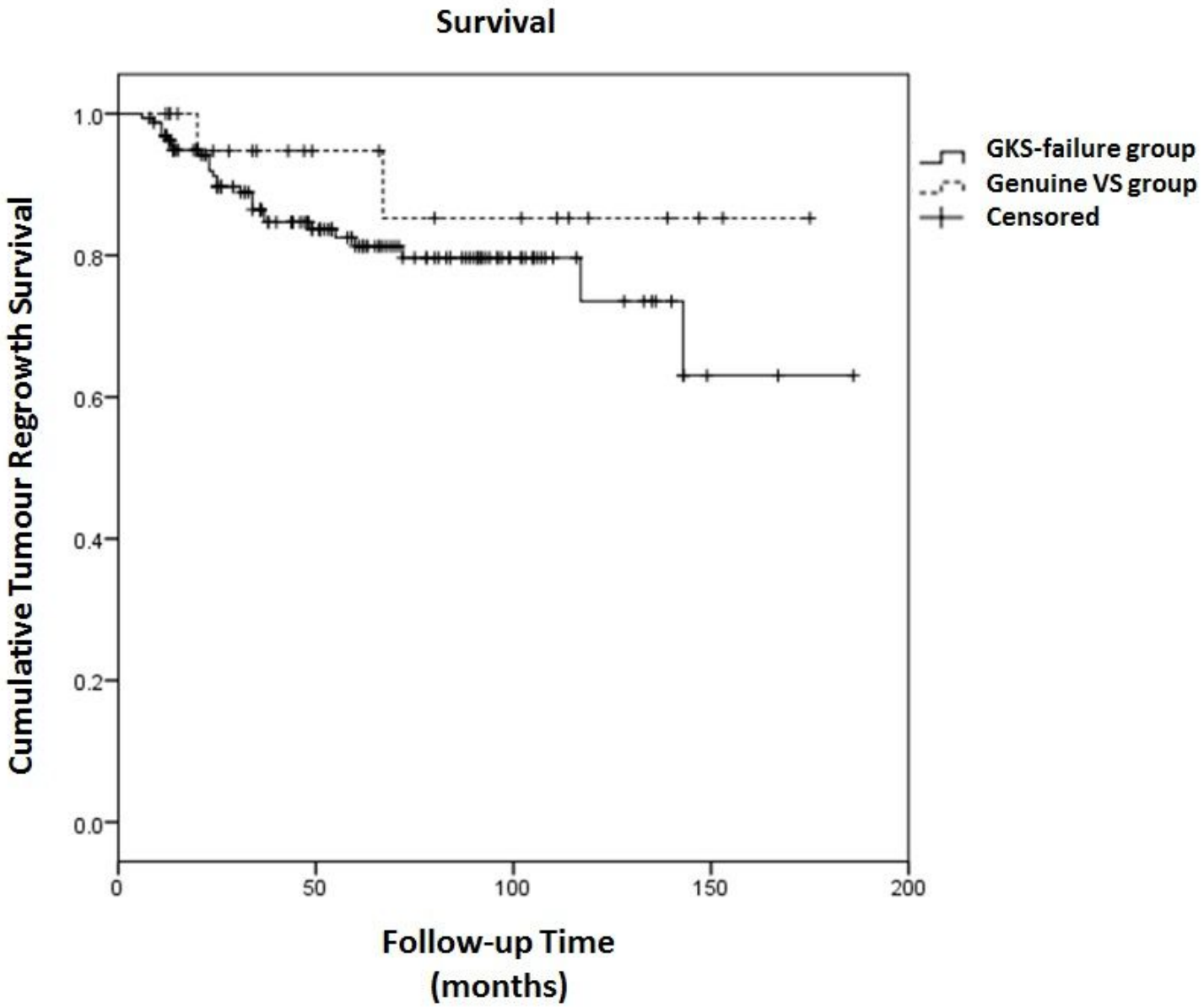

Figure 4

Kaplan-Meier analysis of tumor control during follow-up after subtotal resection in the GKS-failure (n=23) and genuine VS (n=170) populations who had undergone nontotal resection of a large Koos IV vestibular schwannoma during the study period. The 1-, 5- and 7-year Progression free survival were 100%, 95% & 85%

respectively in the GKS-failure group, and 97%, 80% & 81% in the genuine VS group. Logrank not significant (p=.27).