Volar Locking Plating for the Intra- and Extra-articular Distal Radius Fractures With Dorsal Metaphyseal Comminution

Xue-yang Gui
Nanjing Drum Tower Hospital, The Affiliated Hospital of Nanjing University Medical School
Zhao-hui Cheng
Nanjing Drum Tower Hospital, The Affiliated Hospital of Nanjing University Medical School
Hongfei Shi (michaelshi@nju.edu.cn)
Nanjing Drum Tower Hospital, The affiliated Hospital of Nanjing University Medical School
Yi-xin Chen
Nanjing Drum Tower Hospital, The Affiliated Hospital of Nanjing University Medical School
Jin Xiong
Nanjing Drum Tower Hospital, The Affiliated Hospital of Nanjing University Medical School
Jun-fei Wang
Nanjing Drum Tower Hospital, The Affiliated Hospital of Nanjing University Medical School
Xu-sheng Qiu
Nanjing Drum Tower Hospital, The Affiliated Hospital of Nanjing University Medical School
Zi-tao Zhang
Nanjing Drum Tower Hospital, The Affiliated Hospital of Nanjing University Medical School

---

Research Article

Keywords: distal radial fracture, comminution, locking plate, stability, intra-articular fracture

Posted Date: June 7th, 2021

DOI: https://doi.org/10.21203/rs.3.rs-564409/v1

Abstract

Background: Volar locking plating remains a popular method for the surgical management of distal radius fractures. Dorsal metaphyseal comminution (DMC) is a common fracture pattern which weakens the stability during fracture fixation. In this study, we aimed to compare the radiographic and functional outcome of the intra- and extra-articular distal radius fractures with DMC following volar locking plate fixation.

Materials and methods: Patients suffered from a distal radius fracture with DMC were reviewed in the clinical database of the authors' institution between Jan 2016 and Jan 2020. The included patients were classified into the extra-articular (A3) group or the intra-articular (C2 and C3) group according to the AO/OTA system. The radiological parameters, wrist range of motion, and functional outcomes were evaluated following open reduction and volar locking plate fixation.

Results: A total of 130 patients were included in this study with a mean follow-up length of 17.2 months. Compared with the A3 fracture group, no significant fracture re-displacement or reduced wrist ROMs was observed in the C2 fractures after 12-month's follow-up. However, significantly decreased volar tilt (P = 0.003) as well as the extension/flexion ROMs were observed in the C3 fractures comparing to the A3 fractures. Most of the patients achieved an excellent (n = 75) or good (n = 51) Gartland and Werley wrist score. Four patients with C3 fractures resulted in a fair functional outcome due to a significant loss of volar tilt during follow-up.

Conclusions: The volar locking plate fixation provided sufficient stability for distal radius fractures with DMC, and resulted in similar radiological and functional outcomes in the intra-articular distal radius fractures with a simple articular component (C2 fractures) as those in the extra-articular fractures. Considering the intra-articular fractures with multifragmentary articular component (C3 fracture), despite of the subsequent loss of volar tilt, the majority of the patients achieved good to excellent wrist function following volar locking plating.

Trial registration: Not applicable because the design of the study is retrospective.

Introduction

Distal radial fractures are common orthopedic injuries comprising 15% of all extremity fractures[1]. For the significantly displaced unstable distal radius fractures, volar locking plating remains one of the most popular fixation techniques because of a safe and straightforward approach, a low rate of complication, and a rapid return to function recovery[2].

Dorsal metaphyseal comminution (DMC) is the most common fracture pattern observed in 60% of the distal radius fractures[3], which weakens the fracture stability and leads to higher rates of secondary displacement following conservative treatment or percutaneous pinning[3–6]. Despite the improved strength characteristics compared with the traditional nonlocking plates, the stability provided by volar

fixed-angled locking plating has also been questioned in this fracture pattern. In vitro, biomechanical studies have testified the stability of volar locking plate in extra-articular distal radius fracture models with DMC, and an equivalent[7] or slightly less stability[8, 9] can be provide compared with dorsal plating. However, the efficacy of volar locking plating in the intra-articular distal radius fracture with DMC has not yet been adequately analyzed in biomechanical or clinical studies.

In this study, we analyzed the radiographic and functional outcome of the intra- and extra-articular distal radius fractures with DMC following volar locking plate fixation, and hence to investigate the stability of volar locking plating in these fracture patterns.

Materials And Methods

In this retrospective study, patients with distal radius fractures who received open reduction and internal fixation in the authors' institution between Jan 2016 and Jan 2020 were reviewed in the trauma database. Inclusion criteria were based on the following protocol: 1) All fractures received surgical treatment according to the indications recommended on the American Association of Orthopaedic Surgeons (AAOS) standard[10]; 2) The fracture was fixed with a single volar locking plate; 3) DMC were identified in the preoperative radiographs and computed tomographic (CT) images by the authors according to the definition in literature [11]. Patients with open fractures, delayed fractures, neurovascular injuries, additional ipsilateral upper extremity fractures, or a follow-up period of less than 12 months were excluded from the study. Besides, the patients with complex fragmentation of articular surface, volar or dorsal rim fractures, radiocarpal fracture dislocations, and those are not suitable for a single volar locking plate fixation were also excluded. The included patients were classified into the extra-articular (A3) group or the intra-articular (C2 and C3) group according to the AO/OTA system[12].

All patients were operated on by two senior attending surgeons (JX and HFS). During operation, the fracture was accessed through the modified volar Henry approach. Briefly, the skin was incised along the course of the flexor carpi radialis (FCR) tendon. The sheath of the FCR was opened and the FCR tendon and the flexor pollicis longus tendon were retracted ulnarly. The radial artery was carefully protected. The pronator quadratus was incised longitudinally and elevated to expose the distal radius. For extra-articular fractures, we applied longitudinal traction and reduced the fracture under direct visualization. For intra-articular fractures, either the radial column or the palmoulnar fragment could be reduced firstly to provide reference for the radial height and radial inclination. Dorsal ulnar fragments were then reduced to restore joint congruency and volar tilt. The joy-stick technique with percutaneous pinning from the dorsal side was used to facilitate reduction of the dorsal fragment if necessary. After temporary K-wire fixation, a satisfactory reduction of the extra- and intra-articular fracture was checked using intraoperative C-arm according to the radiographic guidelines described in literature[13]. The fracture was then fixed with the 2.4 mm volar locking plate system (Depuy-Synthes, Oberdorf, Switzerland). The distal edge of the plate was carefully positioned proximal to the watershed line to avoid prominence in this area[14]. Multiple fluoroscopic views were checked to avoid intraarticular screw penetration and dorsal screw prominence[15]. The stability of the distal radioulnar joint (DRUJ) was routinely checked and compared

with the contralateral side. Cast immobilization, radioulnar pinning, or ulnar styloid ORIF was performed based on the instability of DRUJ according to the established protocol[16, 17]. Gentle wrist active range of motion and midrange forearm rotation were allowed postoperatively. The patients were followed at 6 weeks, 3 months, 6 months, and 12 months according to our routine follow-up regime[17].

Radiological parameters, including radial inclination, volar tilt, radial height, and ulnar variance, were measured in the follow-up radiographs according to the protocols described in literature[18]. In each group, the radiological parameters measured at the 12-month follow-up were compared with those measured postoperatively using paired-sample *t* test. The fracture re-displacement (FRD), defined as the absolute value of the difference between the postoperative parameters and those taken at the 12-month follow-up, was then calculated and compared between the intra-articular and the extra-articular group using Independent t test. Clinical assessment and complications of included patients were recorded during follow-up. Patient wrist range of motion (ROMs), pain, and functional outcomes were evaluated according to the Disabilities of the Arm, Shoulder and Hand (DASH) score and the Gartland and Werley score at 12 months postoperatively. Pearson's chi-squared test was used for nonparametric data. For all statistical tests, $P < 0.05$ was considered statistically significant. SPSS software (SPSS version 18.0, SPSS, IBM Inc., Armonk, NY, USA) was used for all statistical analyses.

Results

A total of 130 patients were eligible for inclusion in this study, including 58 men and 72 women with an average age of 58 years (range, 22–83 years). The mean length of follow-up was 17.2 (12–24) months. The demographics of the patients were shown in Table 1. According to the AO/OTA system, the patients were classified into A3 (41 cases), C2 (56 cases), or C3 (33 cases) fractures.

Table 1
Patient demographics in different groups

	AO/OTA A3	AO/OTA C2	AO/OTA C3	*P* value
	(n = 41)	(n = 56)	(n = 33)	
Age (years)	58.5 ± 12.3	60.2 ± 11.8	63.1 ± 12.6	0.487†
Gender				0.519‡
Female	22	32	18	
Male	19	24	15	
Side				0.144‡
Dominant	21	29	19	
Nondominant	20	27	14	
† One-way ANOVA test.				
‡ Pearson's chi-squared test				

Fracture healing was achieved in all of the patients during follow-up. No major complications, such as nerve injury, tendon rupture, or implant failure, were recorded during follow-up. There were three cases of superficial wound infection postoperatively, wherein all of the incisions healed smoothly within three weeks after wound dressing changes and oral antibiotic treatment.

The measured radiological parameters were shown in Table 2. No statistically significant change in volar tilt, radial inclination, radial height, or ulnar variance was observed between the immediate postoperative and 12-month follow-up measurements in either of the A3 or the C2 fracture group. However, a significant change of the volar tilt was observed in the C3 fracture group comparing the immediate postoperative measurements with the 12-month follow-up data ($P = 0.037$). Comparing the FRD calculated in the intra-articular fractures to the extra-articular ones, a significant decrease of the volar tilt was observed in C3 fractures than in A3 ($P = 0.003$) fractures (Table 3). The difference between the C2 and A3 fractures, however, did not achieve statistical significance ($P = 0.540$). Considering the radial height, the ulnar variance, and the radial inclination, no significant difference of FRD was observed between the intra-articular and the extra-articular fractures (Table 3).

Table 2
Radiological parameters measured in different groups (Mean ± SD)

	Postoperatively	At 12 months	*P* value†
AO/OTA A3 fractures			
RI (°)	20.52 ± 4.08	20.16 ± 4.14	0.548
VT (°)	5.06 ± 3.36	4.83 ± 3.37	0.455
UV (mm)	0.19 ± 0.32	0.22 ± 0.27	0.231
RH (mm)	9.54 ± 4.18	9.97 ± 5.08	0.461
AO/OTA C2 fractures			
RI (°)	19.70 ± 4.19	19.33 ± 4.31	0.122
VT (°)	3.21 ± 4.46	3.72 ± 4.04	0.260
UV (mm)	0.19 ± 0.29	0.21 ± 0.33	0.441
RH (mm)	9.50 ± 4.17	9.91 ± 5.37	0.304
AO/OTA C3 fractures			
RI (°)	19.24 ± 4.34	19.73 ± 4.77	0.302
VT (°)	3.32 ± 5.42	2.06 ± 6.48	0.037*
UV (mm)	0.21 ± 0.37	0.25 ± 0.40	0.185
RH (mm)	9.15 ± 5.26	9.51 ± 5.75	0.237

RH: radial height; RI: radial inclination; VT: volar tilt; UV: ulnar variance.

† Paired samples *t* test.

* $P < 0.05$.

Table 3
Fracture re-displacement (FRD) calculated in different fracture groups (Mean ± SD).

FRD	A3	C2	*P* value†	C3	*P* value‡
RI (°)	0.36 ± 0.41	0.37 ± 0.39	0.525	0.41 ± 0.33	0.571
VT (°)	0.23 ± 0.16	0.21 ± 0.61	0.540	0.16 ± 0.90	0.003*
UV (mm)	0.03 ± 0.32	0.04 ± 0.27	0.868	0.04 ± 0.31	0.892
RH (mm)	0.5 7 ± 0.41	0.59 ± 0.49	0.832	0.64 ± 0.47	0.496
† independent-samples *t* test, comparison between the A3 and C2 groups.					
‡ independent-samples *t* test, comparison between the A3 and C3 groups.					
* $P < 0.05$.					

At 12 months postoperatively, the mean ROMs of the wrist were shown in Table 4. All of the patients achieved more than 75% recovery of extension/flexion and more than 95% recovery of pronation/supination in the injured wrist compared to the contralateral normal wrist. All of the patients achieved adequate functional ROMs according to Ryu's standard[19]. Considering the pronation/supination ROM, no significant difference was observed between the intra-articular (either C2 or C3) fractures and the extra-articular (A3) fractures. However, the C3 fracture group presented significantly decreased extension/flexion ROMs compared with the A3 fracture group. The mean DASH score was 9.8 (0–40) at 12 months follow-up. Most patients in our study achieved an excellent (n = 75) or good (n = 51) Gartland and Werley wrist score. Four patients with C3 fractures resulted in a fair functional outcome due to a significant loss of volar tilt during follow-up (Fig. 1 to Fig. 4).

Table 4
Comparison of the range of motion between the Injured and the Contralateral normal wrist at 12 months postoperatively (Mean ± SD)

Variables	Injured Side	Contralateral Side	% of contralateral wrist	*P* value†
AO/OTA A3 fractures (°)				
Extension	81.81 ± 9.71	89.22 ± 9.90	91.7	
Flexion	80.97 ± 9.79	88.78 ± 9.65	91.2	
Pronation	82.20 ± 7.32	83.46 ± 6.93	98.4	
Supination	82.37 ± 5.48	83.51 ± 5.56	98.7	
AO/OTA C2 fractures (°)				
Extension	75.48 ± 11.40	89.39 ± 9.51	84.4	0.095
Flexion	73.41 ± 10.20	88.34 ± 9.36	83.1	0.179
Pronation	81.03 ± 6.44	83.23 ± 7.22	97.3	0.560
Supination	81.56 ± 5.27	83.97 ± 6.13	97.1	0.567
AO/OTA C3 fractures (°)				
Extension	72.51 ± 17.39	88.36 ± 7.51	79.8	0.044*
Flexion	69.57 ± 19.89	88.97 ± 7.35	78.2	0.035*
Pronation	79.84 ± 8.75	82.49 ± 6.56	96.7	0.311
Supination	80.69 ± 5.96	83.18 ± 5.64	96.9	0.560
† Pearson's chi-squared test, compared with the A3 fracture group.				
* $P < 0.05$.				

Discussion

In this study, we analyzed the efficacy of volar locking plating in the distal radius fractures with DMC. Compared with the extra-articular fracture group, no significant fracture re-displacement or reduced wrist ROMs was observed in the intra-articular distal radius fractures with a simple articular component (C2 fractures). However, a significant decrease of the volar tilt as well as the extension/flexion ROMs were observed in the intra-articular fractures with multi-fragmentary articular component (C3 fracture) during follow-up.

Previously, biomechanical studies using extra-articular fracture models have confirmed that the volar locking plating could provide an equivalent or slightly less stability compared with dorsal plating in distal

radius fractures with DMC[7–9]. In clinical studies, Guillou reported 22 patients with a dorsally comminuted extra-articular distal radius fracture fixed with volar locking plate. Most (95.4%) of the patients maintained the stability without secondary displacement at 6 months postoperatively[20]. We observed similar radiological results in our study, wherein no significant radiographic change in volar tilt, radial inclination, radial height, or ulnar variance was found in the A3 fracture group during the 12 months' follow-up. Our findings provided extra clinical evidence for the application of volar locking fixation in the extra-articular distal radius fractures with DMC.

Considering the intra-articular fractures with DMC, no straightforward biomechanical studies could be found in literature. In clinical studies, Khamaisy compared the outcome of volar locking plating in the dorsally comminuted (DC) and the dorsally intact (DI) distal radius fractures[21]. The vast majority of the cases included in Khamaisy's study were AO/OTA type C fractures, and a satisfied fracture reduction was preserved in the DC fractures compared to the DI ones with no significant difference observed in radial inclination, volar tilt, and radial length. These results implied that volar locking plating could provide sufficient stability for the intra-articular fractures despite of the occurrence of DMC. However, the authors didn't compare the outcome among different sub-types of intra-articular fractures due to limited sample size. In our study, volar locking plating was testified to preserve fracture reduction in the C2 fractures, but not in the C3 fractures.

Our results were in contrast to Chou's study, wherein 41 patients with AO/OTA C3 dorsally comminuted distal radial fractures were treated using either dorsal (n = 22) or volar (n = 19) locking plate [15]. In both groups, no significant re-displacement was observed in terms of radial inclination, volar tilt, and ulnar variance. Compared with Chou's study, a larger number of cases were included in our study, and the significant loss of volar tilt in the C3 fractures in our study was possibly caused by a compromised subchondral support of the thin and displaced dorsal fragment provided by the distal row of screws with inadequate length (Fig. 3)[22–24]. The subsequent loss of fracture reduction was also observed by Gogna's study, wherein 33 dorsally comminuted distal radius fractures were fixed with volar locking plate and followed for over a year[15, 20, 25]. Totally three cases of C3 fractures (18.7%) were reported to present a dorsal subluxation of the carpus or a loss of dorsal tilt after one-year follow-up. These results were comparable with our study, and called for attention to the usage of volar locking plate in the C3 fractures with DMC, especially for the fractures with the occurrence of radiocarpal fracture dislocation or dorsal rim fractures[26].

To prevent the loss of reduction in C3 fractures, different solutions were reported in literature. An appropriate length of the distal row of locking screws was proven crucial for the single volar plating construct[24]. However, the risk of extensor tendon irritation would increase with longer distal radius screws[27]. Multi-row of volar locking screws was considered more stable than the single row screw construct. However, little evidence was provided to support the use of two rows of distal screws over one row in the fixation of distal radius fractures[27]. Besides, the combined usage of volar and dorsal plating was recommended to provide extra buttress for the dorsal fragment[9, 28, 29].

With regard to the recovery of wrist function, Chou reported a progressive improvement of wrist range of motion following volar plating of C3 dorsally comminuted distal radius fractures[15]. After one-year follow-up, the patients showed an 89% recovery of flexion-extension and a 97% recovery of supination-pronation compared with that of the contralateral healthy wrists. Compared with Chou's study, the patients with C3 fractures achieved comparable recovery of supination-pronation range of motion in our study. The relatively lower percentage of flexion-extension recovery in our study was possibly associated with the loss of volar tilt in radiological findings. Even so, the majority (87.9%) of the patients with C3 fractures achieved an excellent or good Gartland and Werley wrist score. Four patients (3.1%) with a significant loss of volar tilt resulted in decreased flexion-extension range of motion and a fair functional outcome (Fig. 4). This was consistent with Gupta and Perugia's findings that volar tilt was one of the most important radiographic parameters affecting the functional outcome of distal radius fractures [30, 31].

There are several limitations to our study. First, the study was based on retrospective data, which could harbor confounding sources of bias. Second, the length of the follow-up in our study was reported to be sufficient for the conclusion of radiological and functional outcome, but relatively short for the record of long-term complications[32].

In conclusion, the volar locking plate fixation provided sufficient stability for distal radius fractures with DMC, and resulted in similar radiological and functional outcomes in all of the C2 fractures as those in the extra-articular fractures. Considering the C3 fractures, despite of the subsequent loss of volar tilt, the majority of the patients achieved good to excellent wrist function following volar locking plating. Attention should be paid to the subchondral support of the thin and displaced dorsal fragment using locking screws with appropriate length.

Abbreviations

DMC: Dorsal metaphyseal comminution

AAOS: American Association of Orthopaedic Surgeons

FCR: Flexor carpi radialis, DRUJ: distal radioulnar joint

ORIF: Open reduction and internal fixation

FRD: The fracture re-displacement

ROM: Range of motion

DASH: Disabilities of the Arm, Shoulder and Hand score

SPSS: Statistical Product and Service Solutions

DC: The dorsally comminuted distal radius fracture

DI: The dorsally intact distal radius fracture

Declarations

Ethics approval and consent to participate

This study was conducted in accordance with the Declaration of Helsinki and with approval from the institutional review board (IRB) of Nanjing Drum Tower Hospital. Written informed consent was obtained from all participants.

Consent for publication

Not applicable.

Availability of data and materials

The datasets generated and/or analysed during the current study are not publicly available due to the regulations of IRB, but can be made available from the corresponding author on reasonable request.

Competing interests

The authors declare that they have no competing interests.

Funding

This study has received financial support from the National Natural Science Foundation of China (81401793 and 81572132), the Six Talent Peeks Project in Jiangsu Province (WSW-060), and the Key Project supported by Medical Science and technology development Foundation, Nanjing Department of Health (QRX17007).

Authors' contributions

Hong-fei SHI and Yi-xin CHEN researched literature and conceived the study. All authors were involved in protocol development. Jin XIONG and Jun-fei WANG were involved in patient recruitment. Xu-sheng QIU and Zi-tao ZHANG were involved in data analysis. Xue-yang GUI and Zhao-hui CHENG wrote the first draft of the manuscript. All authors reviewed and edited the manuscript and approved the final version of the manuscript.

Acknowledgements

Not applicable.

References

1. Kennedy SA, Hanel DP: **Complex distal radius fractures**. *J Orthopedic Clinics* 2013, **44**(1):81-92.

2. Asadollahi S, Keith PP: **Flexor tendon injuries following plate fixation of distal radius fractures: a systematic review of the literature**. *Journal of orthopaedics and traumatology : official journal of the Italian Society of Orthopaedics and Traumatology* 2013, **14**(4):227-234.
3. Makhni EC, Taghinia A, Ewald T, Zurakowski D, Day CS: **Comminution of the dorsal metaphysis and its effects on the radiographic outcomes of distal radius fractures**. *The Journal of hand surgery, European volume* 2010, **35**(8):652-658.
4. Chuang PY, Yang TY, Shen SH, Tsai YH, Huang KC: **The Effects of Dorsal Cortical Comminution on Radiographic Results following Percutaneous Pinning for Extra-Articular Colles' Fracture**. *BioMed research international* 2015, **2015**:714351.
5. Mackenney PJ, McQueen MM, Elton R: **Prediction of instability in distal radial fractures**. *The Journal of bone and joint surgery American volume* 2006, **88**(9):1944-1951.
6. Wadsten MA, Sayed-Noor AS, Englund E, Buttazzoni GG, Sjoden GO: **Cortical comminution in distal radial fractures can predict the radiological outcome: a cohort multicentre study**. *The bone & joint journal* 2014, **96-b**(7):978-983.
7. Kandemir U, Matityahu A, Desai R, Puttlitz C: **Does a volar locking plate provide equivalent stability as a dorsal nonlocking plate in a dorsally comminuted distal radius fracture?: a biomechanical study**. *J Journal of orthopaedic trauma* 2008, **22**(9):605-610.
8. Willis AA, Kutsumi K, Zobitz ME, Cooney WP, 3rd: **Internal fixation of dorsally displaced fractures of the distal part of the radius. A biomechanical analysis of volar plate fracture stability**. *The Journal of bone and joint surgery American volume* 2006, **88**(11):2411-2417.
9. Disseldorp DJ, Hannemann PF, Poeze M, Brink PR: **Dorsal or Volar Plate Fixation of the Distal Radius: Does the Complication Rate Help Us to Choose?** *Journal of wrist surgery* 2016, **5**(3):202-210.
10. Lichtman DM, Bindra RR, Boyer MI, Putnam MD, Ring D, Slutsky DJ, Taras JS, Watters WC, 3rd, Goldberg MJ, Keith M *et al*: **Treatment of distal radius fractures**. *The Journal of the American Academy of Orthopaedic Surgeons* 2010, **18**(3):180-189.
11. Wadsten MA, Sayed-Noor AS, Sjoden GO, Svensson O, Buttazzoni GG: **The Buttazzoni classification of distal radial fractures in adults: interobserver and intraobserver reliability**. *Hand (New York, NY)* 2009, **4**(3):283-288.
12. Marsh JL, Slongo TF, Agel J, Broderick JS, Creevey W, DeCoster TA, Prokuski L, Sirkin MS, Ziran B, Henley B *et al*: **Fracture and dislocation classification compendium - 2007: Orthopaedic Trauma Association classification, database and outcomes committee**. *J Orthop Trauma* 2007, **21**(10 Suppl):S1-S133.
13. Nana AD, Joshi A, Lichtman DM: **Plating of the distal radius**. *The Journal of the American Academy of Orthopaedic Surgeons* 2005, **13**(3):159-171.
14. Soong M, Earp BE, Bishop G, Leung A, Blazar P: **Volar locking plate implant prominence and flexor tendon rupture**. *The Journal of bone and joint surgery American volume* 2011, **93**(4):328-335.
15. Chou YC, Chen AC, Chen CY, Hsu YH, Wu CC: **Dorsal and volar 2.4-mm titanium locking plate fixation for AO type C3 dorsally comminuted distal radius fractures**. *The Journal of hand surgery* 2011,

36(6):974-981.

16. Sammer DM, Chung KC: **Management of the distal radioulnar joint and ulnar styloid fracture**. *Hand clinics* 2012, **28**(2):199-206.
17. Chen YX, Zheng X, Shi HF, Wangyang YF, Yuan H, Xie XX, Li DY, Wang CJ, Qiu XS: **Will the untreated ulnar styloid fracture influence the outcome of unstable distal radial fracture treated with external fixation when the distal radioulnar joint is stable**. *BMC musculoskeletal disorders* 2013, **14**:186.
18. Kreder HJ, Hanel DP, McKee M, Jupiter J, McGillivary G, Swiontkowski MF: **X-ray film measurements for healed distal radius fractures**. *The Journal of hand surgery* 1996, **21**(1):31-39.
19. Ryu JY, Cooney WP, 3rd, Askew LJ, An KN, Chao EY: **Functional ranges of motion of the wrist joint**. *The Journal of hand surgery* 1991, **16**(3):409-419.
20. Guillou J, Darees M, Pougès C, Christiaens N, Guerre E, Chantelot C: **What happens to the posterior comminution in extra-articular fractures of the distal radius treated with volar locking plates?** *Hand surgery & rehabilitation* 2019, **38**(2):91-96.
21. Khamaisy S, Weil YA, Safran O, Liebergall M, Mosheiff R, Khoury A: **Outcome of dorsally comminuted versus intact distal radial fracture fixed with volar locking plates**. *Injury* 2011, **42**(4):393-396.
22. Figl M, Weninger P, Jurkowitsch J, Hofbauer M, Schauer J, Leixnering M: **Unstable distal radius fractures in the elderly patient–volar fixed-angle plate osteosynthesis prevents secondary loss of reduction**. *The Journal of trauma* 2010, **68**(4):992-998.
23. Rhee SH, Kim J, Lee YH, Gong HS, Lee HJ, Baek GH: **Factors affecting late displacement following volar locking plate fixation for distal radial fractures in elderly female patients**. *The bone & joint journal* 2013, **95-b**(3):396-400.
24. Wall LB, Brodt MD, Silva MJ, Boyer MI, Calfee RP: **The effects of screw length on stability of simulated osteoporotic distal radius fractures fixed with volar locking plates**. *The Journal of hand surgery* 2012, **37**(3):446-453.
25. Gogna P, Selhi HS, Singla R, Devgan A, Magu NK, Mahindra P, Yamin M: **Dorsally comminuted fractures of the distal end of the radius: osteosynthesis with volar fixed angle locking plates**. *ISRN orthopedics* 2013, **2013**:131757.
26. Garg R, Mudgal CS: **When a volar locking plate is not the right choice in fractures of the distal radius: Case based technical considerations**. *Journal of clinical orthopaedics and trauma* 2020, **11**(4):542-553.
27. Ramavath A, Howard N, Lipscombe S: **Biomechanical considerations for strategies to improve outcomes following volar plating of distal radius fractures**. *Journal of orthopaedics* 2019, **16**(5):445-450.
28. Day CS, Kamath AF, Makhni E, Jean-Gilles J, Zurakowski D: **"Sandwich" plating for intra-articular distal radius fractures with volar and dorsal metaphyseal comminution**. *Hand (New York, NY)* 2008, **3**(1):47-54.
29. Farhan MF, Wong JH, Sreedharan S, Yong FC, Teoh LC: **Combined volar and dorsal plating for complex comminuted distal radial fractures**. *Journal of orthopaedic surgery (Hong Kong)* 2015,

23(1):19-23.

30. Batra S, Gupta A: **The effect of fracture-related factors on the functional outcome at 1 year in distal radius fractures**. *Injury* 2002, **33**(6):499-502.
31. Perugia D, Guzzini M, Civitenga C, Guidi M, Dominedò C, Fontana D, Ferretti A: **Is it really necessary to restore radial anatomic parameters after distal radius fractures?** *Injury* 2014, **45 Suppl 6**:S21-26.
32. Hattori Y, Doi K, Sakamoto S, Yukata K: **Delayed rupture of extensor digitorum communis tendon following volar plating of distal radius fracture**. *Hand surgery : an international journal devoted to hand and upper limb surgery and related research : journal of the Asia-Pacific Federation of Societies for Surgery of the Hand* 2008, **13**(3):183-185.

Figures

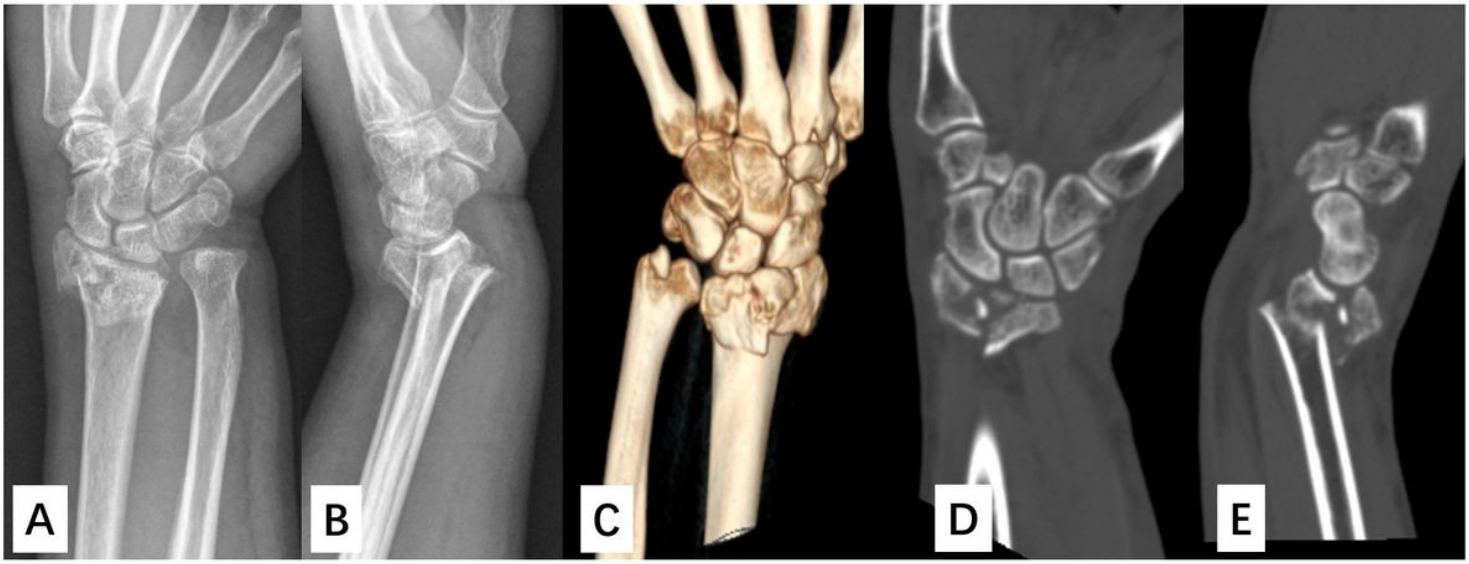

Figure 1

Case 1. A 69-year-old woman presented with an AO/OTA C3 distal radius fracture with dorsal metaphyseal comminution. A, B: Preoperative anteroposterior and lateral view radiographs. C, Three-dimensional computed tomographic image shows the dorsal metaphyseal comminution. D, E: Two-dimensional computed tomographic images confirm the multi-fragmentary articular components.

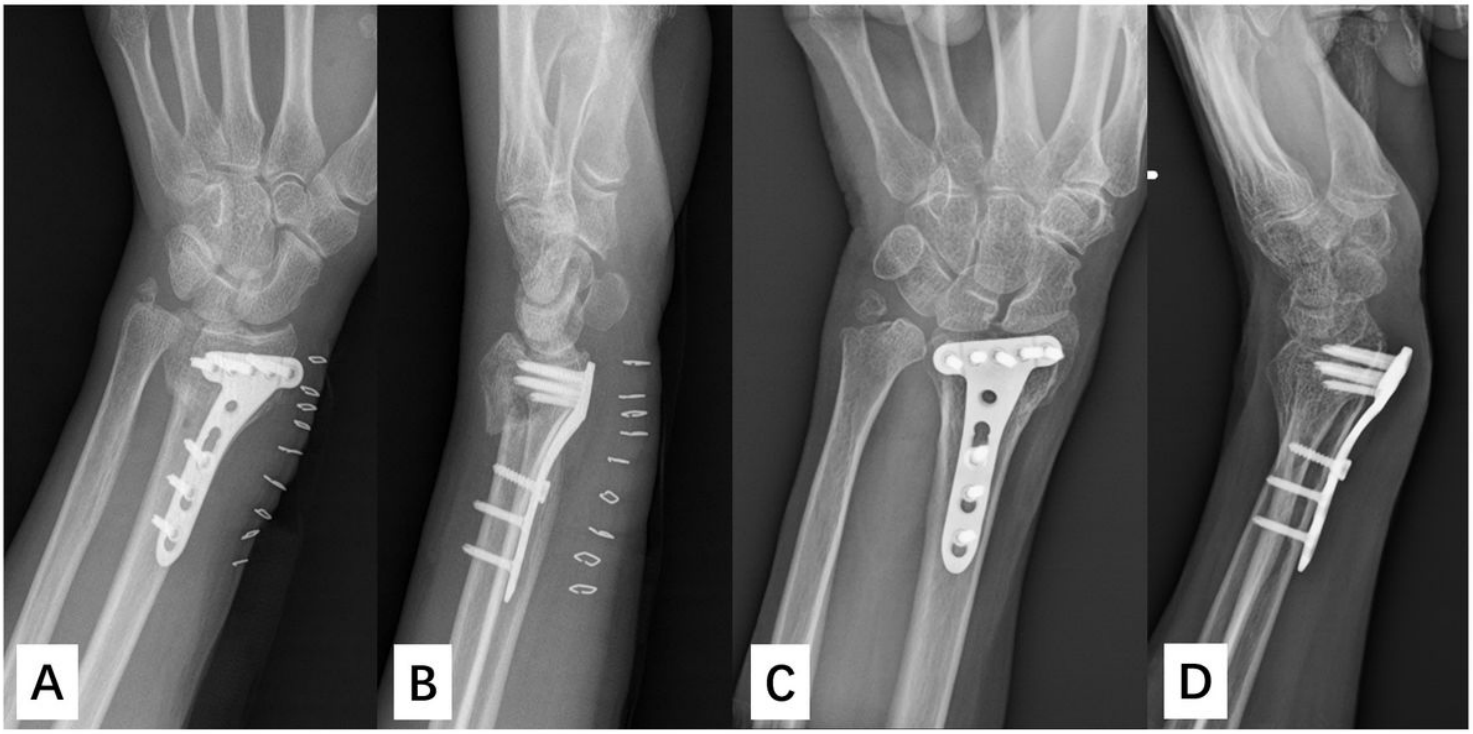

Figure 2

Case 1. Significant loss of volar tilt was observed at 12-months' follow-up. A, B: Postoperative posteroanterior and lateral radiographs. C, D: Posteroanterior and lateral radiographs at 12-months' follow-up.

Figure 3

Case 1. Postoperative computed tomographic images confirmed an inadequate support of the thin and displaced dorsal fracture provided by the distal row of locking screws. A, Sagittal view of the CT image. B, Cross-sectional CT images.

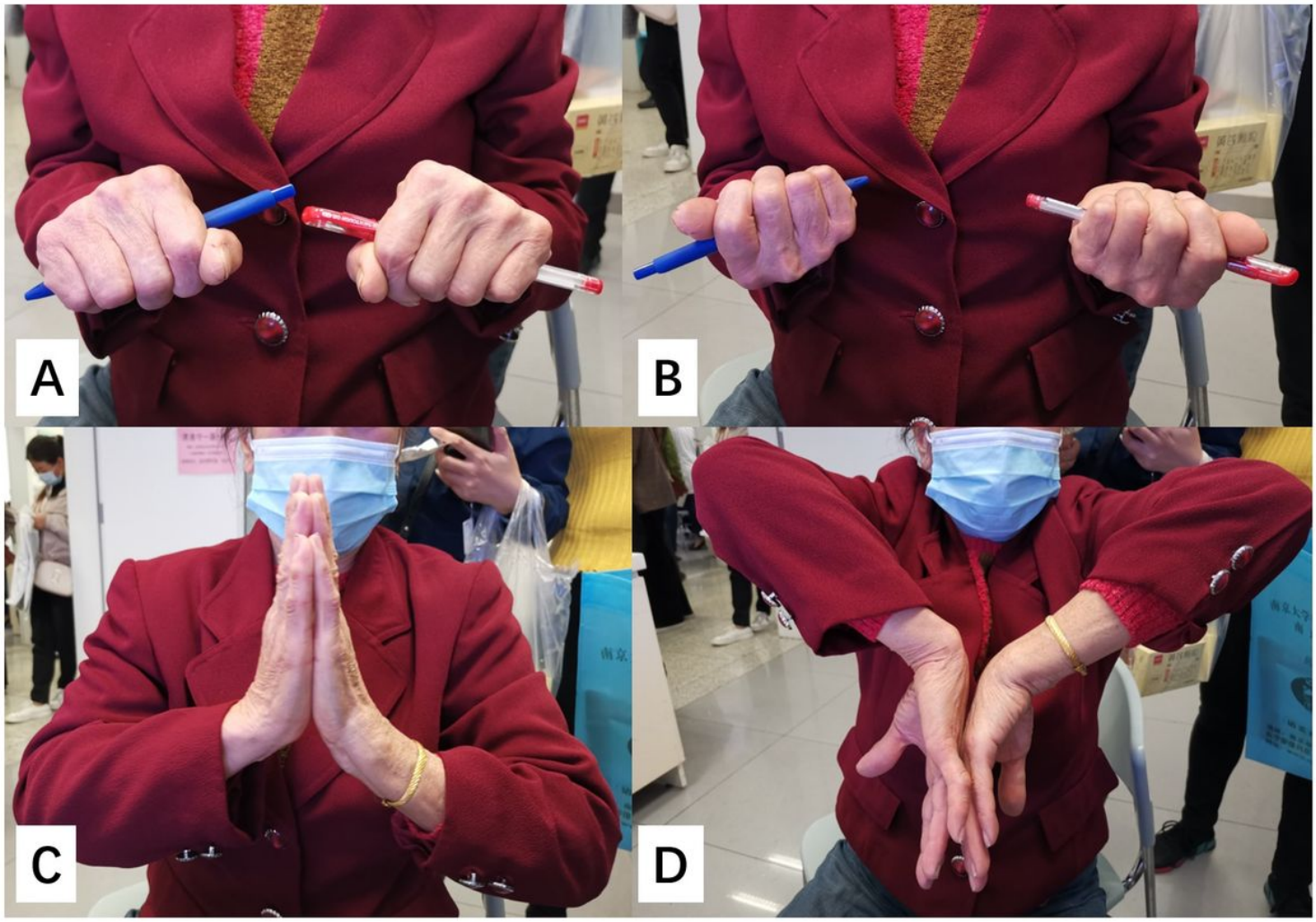

Figure 4

Case 1. Wrist range of motion at 12-months' follow-up. A, B: A 95% recovery of pronation/supination was achieved in the injured wrist. C, D: A 78% recovery of extension/flexion was achieved in the injured wrist.