Review of Clinical and radiological outcome of 3- and 4-part proximal humerus fracture managed with J nails in elderly osteoporotic individuals.

R M Chandak
Dr Baba Saheb Ambedkar Hospital: Dr Baba Saheb Ambedkar Medical College and Hospital

Mohit Sharma (drmohitsharma1989@gmail.com)
Dr Baba Saheb Ambedkar Medical College and Hospital https://orcid.org/0000-0003-1557-0375

Amrit Jha
Dr Baba Saheb Ambedkar Hospital: Dr Baba Saheb Ambedkar Medical College and Hospital

Research article

Keywords: J nail, Locking plates, Neer's 3 or 4 part

Posted Date: July 19th, 2021

DOI: https://doi.org/10.21203/rs.3.rs-568751/v1

Abstract

Introduction: Proximal humeral fracture is 3rd most common fracture in elderly population.

Selection of appropriate implant is always challenging to get optimum results in these

osteoporotic bones. Though locking plates are gold standard, major complications range from

9% to 36%. Many percutaneous fixation techniques described in the literature are associated with pin site infections, pin backout and loss of reduction.

Objective: To study clinical and radiological outcome of J nail technique for Neer's three or

four part proximal humeral fractures in patients more than 60 years age.

Materials and Method: We retrospectively studied 60 patients of 3 or 4 part proximal humeral fractures, >60 years of age treated with J nail technique from the period of 2015 to 2017. J nails were made using 2 mm 12 inches blunt tip L (Lambrinudi) wires. At final follow-up, clinical outcome was assessed using Constant Score and radiological evaluation was done according to the Bahr criteria. Statistical analysis was performed.

Results: The mean Constant Score at final follow-up was 90. The postoperative reduction was excellent in 98% of patients and remained excellent in 90%. The mean postoperative neck shaft angle was 135.0° and final neck shaft angle was 131.4°. No deep infection was seen. No avascular necrosis of humeral head was found till follow up upto 2 yrs.

Conclusions: Our study suggests that the functional and radiological outcomes obtained with J nailing are excellent and similar to locking plates and percutaneous Kirschner wire fixation with many other advantages of being simple, minimally invasive, avoiding muscle transfixation and no pin site infections. This surgical technique can be considered as one of the effective technique for fixation of proximal humeral fractures in elderly osteoporotics.

Introduction

Proximal humeral fracture is 3rd most common fracture in elderly population. More than 70% of patients with proximal humeral fractures are in age of 60 years and above.(1) Minimally displaced or impacted fractures do well with conservative therapy. The incidence of three and four part fracture is 21% to 23% of all proximal humerus fractures.(2) Closed reduction with non operative management is an option in such cases also, but the functional results tend to be poor with Constant scores ranging from 47 to 62.(3)

Selection of appropriate implant is always challenging to get optimum results in these

osteoporotic bones. Though locking plates are gold standard, major complications such as deep infection, screw cutout, avascular necrosis range from 9% to 36%.(3)

Many percutaneous fixation techniques have been described in the literature. But these are

associated with 10 to 21 % complication rates, which include pin site infections, pin backout and loss of reduction.(4)

A surgical procedure using three intramedullary nails (J-nails) to fix unstable proximal humeral fractures had been described by Takeuchi et al.(5), to minimize the disadvantages of operative treatment.

Our objective of this study is to evaluate clinical and radiological outcome of J nail technique for Neer's three or four part proximal humeral fractures in patients more than 60 years age.

Materials And Methods

Retrospectively we studied patient of 3 or 4 part unstable displaced fracture of proximal humerus as per Neer's classification. Neer defined an unstable fracture as a fracture that is displaced by more than one centimeter and/or angulated more than 45 degrees. 69 patients were operated in between January 2015 to December 2017. Patients with atleast two year of follow up were included in the study. 8 patients lost follow up, while one case went in nonunion, so excluded from study. So we studied 60 patients from age 61 to 82 years, with 32 female and 28 male.

Patients with associated shaft fracture, fracture dislocation, fracture with split of head,

pathological fracture, nonunion or neglected fractures were excluded.

Surgical Technique:

All patients were taken under regional block anesthesia, in supine on radiolucent table. J nails

were made up of 2 mm & 12 inches Lambrinudi wires (Blunt tip K wires). 2.5 to 3 cm incision at mid arm anterolateral aspect were taken just distal to deltoid insertion. 3 or 4 J nails were used in each case (Fig. 1). Placement of j nail was planned as per varus or valgus fracture pattern (Fig. 2,3). All fractures were reduced with standard reduction maneuver. If greater tuberosity (GT) found displaced, was reduced percutaneously and fixed separately with one or two 2 mm k wires All patients were discharged next day with arm sling. Passive exercises started immediately post op. Stitches removal was done on 10th day. If GT was fixed, its k wires were removed under local anaesthesia at six weeks. Active ROM exercises and strengthening exercises started at 6 weeks. Anteroposterior and axial radiographs were taken at day 1, 6 weeks, 3 months, 6 months,1 year and at latest follow up. All hardware were removed by 9 to 12 months.

At final follow up, all patients were evaluated clinically with constant score, which includes Pain (0-15), Activity of daily living (0-20), Range of Motion (0-40), Strength (0-25).(6) The shoulder function was tested with a goniometer and the muscle power with a spring balance as described by Constant et al.(6)

Also patients were evaluated radiologically with the Bahrs' criteria, which includes Greater

tuberosity with displacement <5 mm, No increased varus or valgus (±15°) of the head fragment in the A.P. view, No increased retro or antetorsion (±15°) of the head fragment in the axillary view.(2) We compared it with average normal value in population, humeral neck shaft angle is 135° and retroversion is 21°.(2) If all three criteria were met, it considered excellent; if two were met, it considered good; if one was met, it considered fair and if none was met, it considered poor result.(2)

Statistical Analysis:

Comparative statistical analyses between genders were made using the paired t-test for

parametric continuous data. Linear regression analysis was performed to determine correlation of age, gender and clinical outcome. A p value of <0.05 was considered as statistically significant.

All analysis was performed using SPSS 20.0 software.

Results

Out of 60 patients, 32 were female with mean age 70.75 years and 28 were male with mean age 69.32 years (Table 1). Mean follow up of patients was 30 months with minimum 24 months and maximum 44 months. 40 patients had 3 parts fracture and 20 had 4 parts fracture (Table 2).

Clinical evaluation:

Mean constant score was found to be 84.5 with 79.12 in female and 89.57 in male ($p<0.05$)

(Table 3). Mean constant score was 84.8 in 3 part fractures and 84.1 in four part fracture with

$p>0.05$ (Table 4). Constant score had shown negative correlation with the age of patient (Fig.3).

None of the patient developed superficial or deep infection.

Radiological evaluation:

All fractures healed uneventfully. None of the case developed avascular necrosis of humeral

head. Average humeral neck shaft angle was 135° at immediate post op and 131.4° at last follow up. As per Bahr's criteria 54 had excellent outcome, 4 had good outcome and 2 had fair outcome

(Table 5).

Discussion

The incidence of displaced 3 part and 4 part proximal humeral fractures is growing, particularly in the elderly population.(3) Treatment options ranges from conservative treatment, fixation with percutaneous techniques, intramedullary nails, locking plates and arthroplasty.(14) All methods are having their

advantages and disadvantages. There is no clear evidence-based treatment of choice. The surgeon needs to consider their experience and expertise with various procedures during the decision-making process.

In young patients with good bone quality, locking plates allow early and more aggressive

rehabilitation.(10) However in the elderly, they may fail due to an insufficiency of the bone–

metal-interface during cyclic loading. On other hand, elastic implants may reduce the strain on the interface by absorbing part of the energy.(11) Locking plates are also associated with 9-16% major complications including deep infections, avascular necrosis, screw cut out, nonunion.(3)

Various percutaneous pinning techniques described in literature have the advantage of being less invasive and a simple procedure, but are associated with pin site infections, pin back out, pin cut out, loss of reduction, muscle trans-fixation, pin migration and the possibility of neurovascular injury.(4,7,13)

In our study, we fixed all fractures with J nail technique, described by Takeuchi et al.(5), with

some modifications. We did not encounter any superficial or deep infection. There was no

backing out of J nail. No avascular necrosis was seen. Locking plate fixation is thought to have a higher risk of avascular necrosis secondary to periosteal stripping.(14) Even after traditional pinning incidence of avascular necrosis of the humeral head ranges from 4% to 14%.(7,8)

Migration of K wires is a major complication with percutaneous pinning, but we could avoid that complication by making oblique entry holes in humerus shaft as described by Takeuchi et al.(5,13)

Early callus formation was seen in almost all cases, as early as 6 weeks. One case of 3 parts

fracture went into nonunion, which healed with ORIF and bone grafting. Around 6 % non union rate is described with proximal humerus locking plate.(12)

Our clinical & radiological results are comparable to other case series described in literature for fixation of proximal humeral fractures. In accordance with the literature, we also found an

association between age and functional outcome.(9) Constant scores were declining significantly with age (Fig. 4) Mean Constant score was 90 in male and 80 in female. Radiologically 90% patient had excellent outcome in follow up.

There are few limitations in our study. We did not perform comparative study of our method

with locking plate or other percutaneous techniques. It was single centric, retrospective study. To generalize the results, further prospective multicenteric study with large number of cases is advisable.

Conclusion

J nailing for a proximal humeral osteoporotic 3 and 4 part fracture is a promising technique.

Outcome is comparable with locking plates and other percutaneous pinning methods. Percentage of complication rate is quite lower.

Abbreviations

L wire: Lambrinudi.

ORIF: Open Reduction and Internal fixation.

K wire: Kirschner's

GT: Greater tuberosity

Declarations

Ethics approval and consent to participate- This study was approved by the ethics committee.
Consent for publication: Written informed consent was obtained from each patient to authorize the publication of their data.
Availability of data and materials: All the data will be available upon motivated request to the corresponding author of the present paper..
Competing interests: The authors declare that they have no competing interests.
Funding:Nil/Not applicable
Authors' contributions:

Dr R M Chandak- Primary Surgeon

Dr Mohit Sharma- Assistant Surgeon and helped with literature review and figures.

Dr Amrit Jha-Statistical analysis and Tables and references.

References

1. Lauritzen JB, Schwarz P, Lund B, McNair P, Transbol I. Changing incidence and

residual lifetime risk of common osteoporosis-related fractures. Osteoporos Int.

1993;3:127–132.

2. Bahrs C, Rolauffs B, Dietz K, Eingartner C, Weise K. Clinical and radiological evaluation of minimally displaced proximal humeral fractures. Arch Orthop Trauma Surg 2010;130:673-9. http://dx.doi.org/ 10.1007/s00402-009-0975-9

3. Olerud P, Ahrengart L, Ponzer S, Saving J, Tidermark J. Internal fixation versus nonoperative treatment of displaced 3-part proximal humeral fractures in elderly patients: a randomized controlled trial. J Shoulder Elbow Surg. 2011;20(5):747-755. doi:10.1016/j.jse.2010.12.018.

4. Carbone S, Tangari M, Gumina S, Postacchini R, Campi A, Postacchini F. Percutaneous pinning of three- or four-part fractures of the proximal humerus in elderly patients in poor general condition: MIROS® versus traditional pinning. Int Orthop 2012;36:1267-73. http://dx.doi.org/ 10.1007/s00264-011-1474-5

5. Takeuchi R., Koshino T., Nakazawa A, Numazaki S, Sato R., Saito T. Minimally Invasive Fixation for Unstable Two-Part Proximal Humeral Fractures: Surgical Techniques and Clinical Results Using J-Nails. J Orthop Trauma, Vol. 16, No. 6, 2002.

6. Constant CR, Murley AH. A clinical method of functional assessment of the shoulder. Clin Orthop Relat Res 1987;(214):160-4.

7. Jaberg H, Warner JP, Jacob RP (1992) Percutaneous stabilization of unstable fractures of the humerus. J Bone Joint Surg Am 74:508–514

8. Soete PJ, Clayson PE, Costenoble H (1999) Transitory percutaneous pinning in fractures of the proximal humerus. J Shoulder Elbow Surg 8:569–573

9. Gaebler C, McQueen MM, Court-Brown CM (2003) Minimally displaced proximal humeral fractures: epidemiology and outcome in 507 cases. Acta Orthop Scand 74(5):580–585.

10. Kralinger F, Gschwentner M, Wambacher M, et al. Proximal humeral fractures: what is

semi-rigid? Biomechanical properties of semi-rigid implants, a biomechanical cadaver based evaluation. Arch Orthop Trauma Surg 2008;128:205–10.

11. Lill H, Hepp P, Korner J, et al. Proximal humeral fractures: how stiff should an implant be? A comparative mechanical study with new implants in human specimens. Arch Orthop Trauma Surg 2003;123:74–81.

12. Majed A, Macleod I, Bull AM, Zyto K, Resch H, Hertel R, et al. Proximal humeral fracture classification systems revisited. J Shoulder Elbow Surg 2011;20:1125-32. http://dx.doi.org/10.1016/j.jse.2011.01.020

13. Resch H, Hübner C, Schwaiger R. Minimally invasive reduction and osteosynthesis of articular fractures of the humeral head. Injury 2001;32:SA25-32.

14. Schumaier and Grawe. Proximal Humerus Fractures: Evaluation and Management in the Elderly Patient. Geriatric Orthopaedic Surgery & Rehabilitation Volume 9: 1-11, 2018.

Tables

Table 1 : Mean age of patients in the study

	Total	Female	Male
Number	**60**	**32**	**28**
Age: Mean ± SD (Range)	**70.23 ± 5.22 (61-82)**	**70.75 ± 5.81 (61-82)**	**69.32 ± 4.65 (62-80)**

Table 2: Fracture pattern among male and female

	3 part #	4 part #
Total	40	20
Female	22	10
Male	20	8

Table 3: Mean constant score among male and female

	Total	Female	Male
Score : Mean ± SD (Range)	84.5 ± 5.99 (74-93)	79.12 ± 3.45 (74-86)	89.57 ± 2.11 (84-93)

p value <0.05

Table 4: Mean constant score among fracture pattern

	Total (60)	3 part # (40)	4 part # (20)
Score : Mean ± SD	84.5 ± 5.99 (74-93)	84.8 ± 5.67 (75-93)	84.1 ± 5.34 (74-92)

p value > 0.05

Table 5: Radiological Outcome among male and female

Bahr's Criteria	Total	Female	Male
Excellent	54	28	26
Good	4	2	2
Fair	2	1	1
Poor	0	0	0

Figures

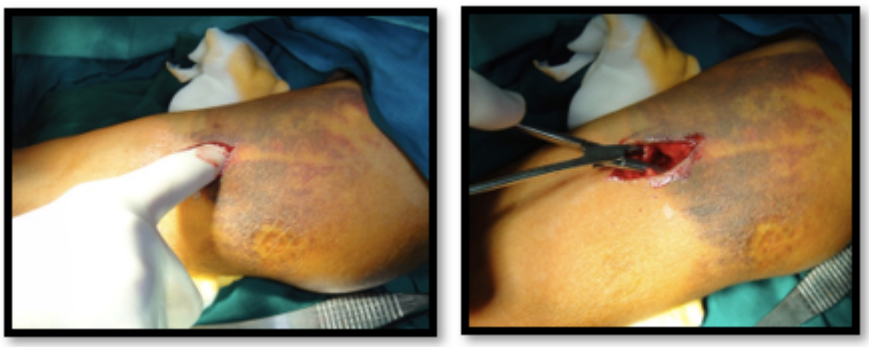

Figure 1

Incision and entry point 1 inch on lateral side of upper arm, just below distal end of deltoid muscle insertion approx. 1.5 cm long incison.

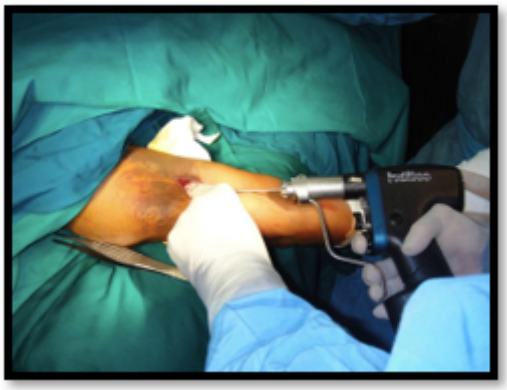

Figure 2

Keeping k wire as parallel to the shaft as possible and trying to negotiate medullary cavity.

Figure 3

Trajectory Mapping of J nail.

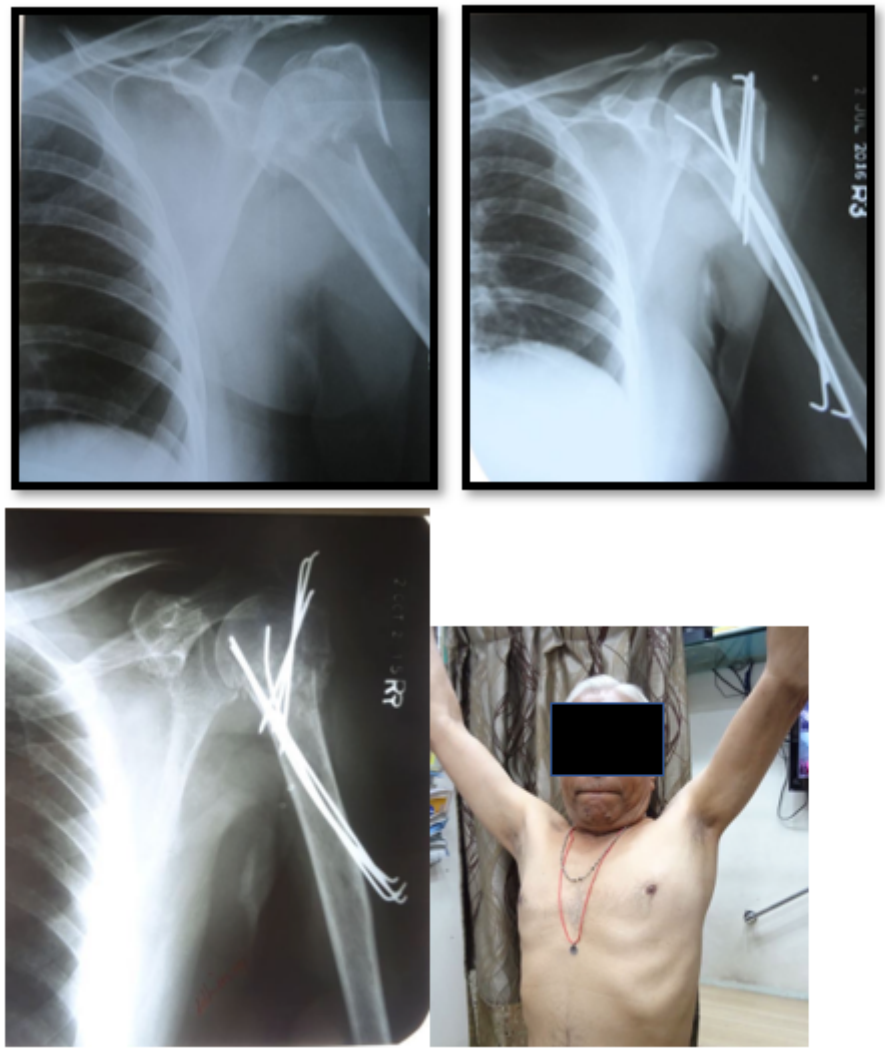

Figure 4

Case 1 Preop and Post op and follow up Radiograph with clinical picture at 6 Months

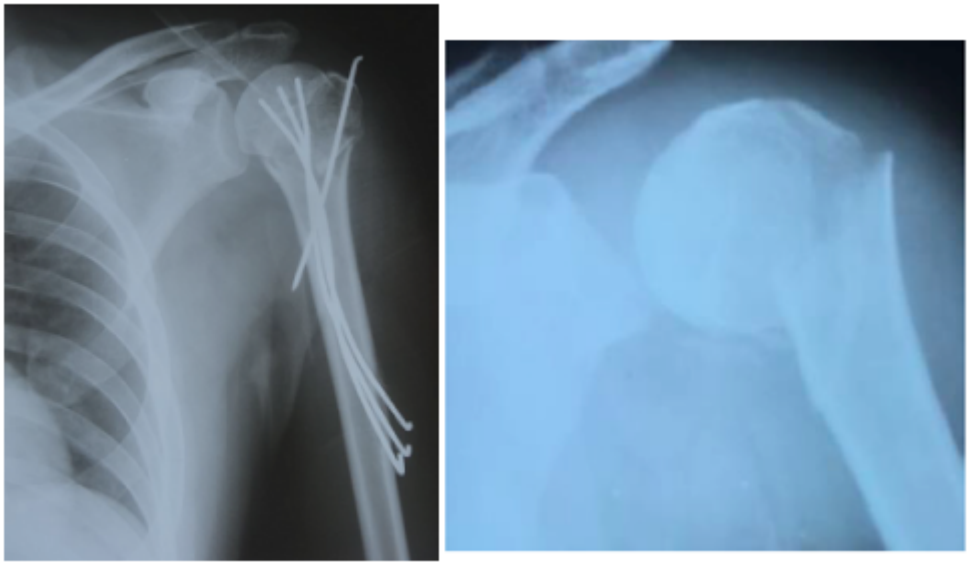

Figure 5

Case 2 Post op and Pre op xray.