Treatment Strategies for Improving Surgical Outcomes of Ruptured Abdominal Aortic Aneurysm

Yasumi Maze (ymze.19651229@gmail.com)
Ise Red Cross Hospital

Toshiya Tokui
Ise Red Cross Hospital

Masahiko Murakami
Ise Red Cross Hospital

Teruhisa Kawaguchi
Ise Red Cross Hospital

Ryosai Inoue
Ise Red Cross Hospital

Reina Hirano
Ise Red Cross Hospital

Koji Hirano
Ise Red Cross Hospital

Shuji Chino
Ise Red Cross Hospital

Ken Nakajima
Ise Red Cross Hospital

Noriyuki Kato
Mie University Hospital

Takatoshi Higashigawa
Mie University Hospital

Bun Nakamura
Mie University Hospital

Hisato Itou
Mie University Hospital

Yu Shoumura
Mie University Hospital

Research Article

Keywords: ruptured abdominal aortic aneurysm, endovascular aneurysm repair, intra-aortic balloon occlusion, abdominal compartment syndrome, open abdominal management

Posted Date: June 9th, 2021

DOI: https://doi.org/10.21203/rs.3.rs-582818/v1

Abstract

Purpose

We examined the surgical outcomes at our hospital and considered strategies for improving surgical outcomes for ruptured abdominal aortic aneurysm.

Methods

We examined 95 surgical cases of ruptured abdominal aortic aneurysm performed from January 2009 to December 2020.

We examined the preoperative characteristics hospital mortality, postoperative complications and long-term results.

Results

24 were dead in hospital (hospital mortality 25.2%). The majority of the causes of death were hemorrhage/DIC and intestinal necrosis. 10 cases required preoperative aortic clamp by thoracotomy or insertion of intra-aortic balloon occlusion and 8 of them died. 10 cases required open abdominal management and 5 of them died. Examining the long-term results of the open repair group and the EVAR group, there was no significant difference between the two groups.

Conclusions

In order to improve the surgical outcomes of ruptured abdominal aortic aneurysm, it is necessary to start surgery immediately in a situation where hemodynamics is stable. Whether to select open surgery or EVAR as the surgical method should be selected by each hospital so that it can be started immediately. In order to prevent postoperative intestinal necrosis, it is necessary to consider risk factors of acute compartment syndrome and actively introduce open abdominal management.

Introduction

With regard to elective surgical treatment for abdominal aortic aneurysm, stable outcomes have been obtained for open repair and endovascular aneurysm repair (EVAR). However, for ruptured abdominal aortic aneurysm (r AAA), the outcomes are still poor, and improvement of treatment outcomes is an issue. In surgical treatment of r AAA, recently it has been reported that EVAR has improved the surgical outcomes [1)~5)]. Moreover, it has been reported that EVAR is not only survival advantage, but also cost-effectiveness [6)]. EVAR is performed by a radiologist at our hospital. Until a few years ago, there were few full-time radiologists, and even if EVAR was indicated, there were some cases in which EVAR could not be performed. We have reported the surgical outcomes for r AAA at our hospital and discussed treatment strategies for improving the surgical outcomes.

Materials And Methods

All operations and data collection were performed in Ise Red Cross Hospital, Ise, Japan. Clinical outcome data was obtained from hospital's patient records or information from the patient's family doctor. This study was approved by the Institutional Review Board of Ise Red Cross Hospital and the need for informed consent was waived due to the retrospective nature of the study. All methods were performed in accordance with the relevant guidelines and regulations.

From January 2009 to December 2020, 555 cases of abdominal aortic aneurysm surgery were performed in Ise Red Cross Hospital (open repair 371cases, EVAR 173 cases and others 11 cases), of which 95 cases of r AAA was targeted. We defined open repair as a case of abdominal aneurysm replacement with artificial graft in situ. The choice of surgical procedure for each case was determined by a vascular surgeon who was familiar with EVAR. Since the EVAR is performed by the radiologist in our hospital, even if the EVAR is indicated, open repair was performed if the radiologist could not come to the hospital immediately. Therefore, the surgical procedure should be selected according to the patient's general condition, the operating room readiness, and the arrival time of the vascular surgeon and radiologist.

The purpose of this study is not only to evaluate in-hospital mortality and morbidity after surgery for r AAA, but also to compare the preoperative situation of dead cases and surviving cases, and to investigate the causes of death in dead cases. We examined the details of cases in which open abdominal management was performed to prevent abdominal compartment syndrome (ACS). Furthermore, we compared and examined the preoperative status, surgical outcomes and long-term survival of both the EVAR and open repair groups.

Statistical analysis

All statistical analysis was performed using statistical software: EZR (Easy R) on R commander [7)]. Continuous variables were presented as mean ± standard deviation and were compared using a student t-test. Categorical variables were presented using numbers and percentages and were compared using a χ^2 test. Kaplan-Meier survival curves were created to assess difference in survival between the EVAR group and the open repair group. Survival distributions were compared with the long-rank test. P values of < .05 were considered significant.

Results

71 cases were alive, 24 were dead in hospital, and the hospital mortality rate was 25.2%. The details of 71 surviving cases were 53 males, 18 females, age 47–91 years (75.8 ± 9.8), and surgical procedures were open repair in 53 cases, EVAR in 14 cases, and others 4 cases. The details of 24 dead cases were 22 males, 2 female, age 65–93 years (75.9 ± 7.6), and surgical procedures were open repair in 20 cases and others 4 cases. Comparing the preoperative conditions of surviving cases and dead cases, the cases with preoperative shock (systolic blood pressure < 80mmHg), cases requiring aortic clamp by thoracotomy or

insertion of an intra-aortic balloon occlusion (IABO) were significantly higher in the dead cases. In the evaluation of the type of rupture by Fitzgerald classification [8)], type Ⅲ was significantly more common in dead cases. There was no difference in door to procedure time between surviving cases and dead cases. There was no EVAR in the dead cases (Table 1).

Therefore, when comparing the EVAR group and the open repair group, the EVAR group was significantly elderly and there were significantly more cases preoperative shock in the open repair group. There was no difference between the two groups in Fitzgerald classification and door to procedure time (Table 2).

Examining the causes of death in 24 dead cases were hemorrhage/DIC (disseminated intravascular coagulation) in 10 cases, postoperative intestinal necrosis in 9 cases, lower limb compartment syndrome in 2 cases, brain death in 2 cases and ARDS (acute respiratory distress syndrome) in one case (Table 3). The majority of the causes of death were hemorrhage/DIC and intestinal necrosis. 10 cases required preoperative aortic clamp by thoracotomy or insertion of IABO to maintain hemodynamics, and 8 of them died. Of the 10 cases in which hemorrhage and DIC were the causes of death, insertion of IABO was performed in 3 cases and aortic clamp by thoracotomy was performed in 2 cases before surgery. In addition, 10 cases required open abdominal management to prevent ACS, half of them, 5 cases died. Of the 5 deaths, 4 cases died within 4 days after surgery. In other words, in many cases requiring open abdominal management, life could be saved if the patient survived the acute phase.

The overall mean follow-up period was 22.1 ± 32.6 (median 6, range 0.02–127) months. The mean follow-up period was 15.3 ± 18.8 (median 8.5, range 0.5–64) months in EVAR group. The mean follow-up period was 24.4 ± 34.4 (median 7, range 0.02–127) months in open repair group. Examining the long-term results of the open repair group and the EVAR group, 1-year survival rate (65.9 ± 5.9% in the open repair group, 61.4 ± 15.2% in the EVAR group), 5-year survival rate (58.4 ± 7.2% in the open repair group, 61.4 ± 15.2% in the EVAR group), there was no significant difference between the two group (Fig. 1).

Discussion

Surgical outcomes for r AAA have improved, but mortality is still high at 20–30% [9),10)]. In our study, out of 95 cases of r AAA, 24 were dead in hospital and the hospital mortality rate was 25.2%.

Examining the causes of death in the 24 dead cases, hemorrhage control difficulties and postoperative intestinal necrosis were account for the majority. Therefore, controlling and overcoming both of these may contribute significantly to improve surgical outcomes.

First of all, regarding hemorrhage control, it is important to start of surgery while hemodynamic is stable. In our study, among the dead cases, there were significantly more cases preoperative shock and 7 of the 10 cases who died from DIC or hemorrhage required IABO insertion or aortic clamp by thoracotomy or cardio pulmonary resuscitation (CPR). In other words, if hemodynamics is disrupted, surgical outcomes will deteriorate.

The first touch for r AAA is a vascular surgeon at our hospital. In addition, EVAR is performed by radiologist at our hospital. Therefore, even in cases where EVAR is possible, open repair may have to be selected if there is no time to arrive at the radiologist who performed EVAR.

In recent years, it has been reported that EVAR has a better performance as a surgical procedure [1)–5)]. But comparing EVAR with open repair, there are many preoperative high-risk cases in open repair group. The difference is reflected in the results of mortality and morbidity. Considering the preoperative risk, there is no difference in long-term mortality between EVAR and open repair, or rather, in the high-risk group, EVAR has a higher mortality rate [10)]. In our study, there were no deaths in the EVAR cases, and all deaths were open repair cases. Mortality was significantly higher in the open repair group than in the EVAR group (0/14 in the EVAR group, 20/73 in the open repair group, $p = 0.033$). However, among EVAR cases, there were few cases with preoperative shock, and there were no cases requiring aortic clamp by thoracotomy or IABO insertion due to hemodynamic failure. Robinson et al. have made a similar report [10)], EVAR does not independently reduce long-term mortality compared with open repair. Furthermore, time from symptom onset to incision and the time from hospital admission to incision were significantly longer for EVAR in comparison to open repair. In our study, there was no difference in door to procedure time between the EVAR group and the open repair group. Looking at the long-term results of EVAR and open repair, there was no difference between the two groups. From the above, we cannot conclude that EVAR is superior to open repair for the treatment of r AAA, the surgical procedure should be selected according to the circumstances of each institution as well as aneurysm anatomy. At our hospital, if it took a long time for the radiologist to arrive at the hospital and EVAR could not be started immediately, we sometimes had no choice but to select open repair.

If hemodynamics disrupted before surgery, it is recommended to perform surgery after aortic clamp by thoracotomy or IABO insertion to stabilize hemodynamics [11),12)]. Judging from our study, the prognosis is poor if such a hemodynamic failure occurs. IABO is a procedure that is generally used in the trauma area [13)], but it should be known as a treatment option even for r AAA. Aortic clamp by thoracotomy and IABO insertion are the last resort, and it is important to start surgery before such a procedure is needed. In other words, the most important thing is how stable the surgery can be started.

Of the 10 cases who required aortic clamp by thoracotomy or IABO insertion due to hemodynamic failure, 2 had IABO insertion and 1 had left thoracotomy aortic clamp at the emergency room. In these three cases, hemodynamic failure occurred before considering the indication for EVAR, so it was necessary to transport them the operating room and open abdomen very quickly. However, all three cases could not be saved. In addition, although he entered the angiography room for the purpose of EVAR, he inserted IABO due to hemodynamic failure, but he abandoned EVAR due to an access route and was rushed to operating room for open repair. However, he could not be saved. Preoperative hemodynamic failure is fatal, and can lead to hemorrhage control difficulties during and after surgery, lead to death.

Regarding surgical procedures after laparotomy, it is important to avoid touching the retroperitoneum where hematoma is detected on preoperative CT scan. In the unlikely event that hematoma ruptures and

blood squirts from the rupture hole due to touching retroperitoneum hematoma, an assistant presses the rupture hole to control hemorrhage, a surgen should peel off the area near the renal artery quickly and clamp of abdominal aorta. There is a report that vena cava, left renal vein, left renal artery, pancreaticoduodenal vein, spleen were damaged by aortic clamp [11)], so caution is required. There is also a method of controlling hemorrhage by inserting an occlusion balloon into the rupture hole, but care must be taken so that the balloon insertion takes time and hemodynamics breakdown does not occur. In addition, cutting and transection of the left renal vein expands the field of view and reduces unnecessary hemorrhage. We have not experienced any complications due to transection of the left renal vein.

Next, regarding how to prevent postoperative intestinal necrosis, there is a close relationship between ACS and intestinal ischemia, and morbidity and mortality increase when ACS occurs [14)–17)]. Preoperative hypotension, preoperative consciousness disorder, intraoperative massive bleeding (5L or more), and use of IABO are said to be risk factors for ACS [17),18)]. Intra-abdominal pressure (IAP) is most easily measured by means of bladder pressure through a urinary catheter. IAP normally runs in the range of 5 to 7 mmHg in critically ill patients [19)]. Postoperative r AAA may result in an IAP ≧ 12mmHg. In some cases, IAP12mmHg or higher causes organ dysfunction such as decreased renal function. In general, it is said that when it exceeds IAP 20mmHg, it causes organ failure [20)]. Paty et al.[21)] suggest that IAP should be measured hourly and decompressive laparotomy should be performed when it exceeds IAP 20mmHg with end-organ dysfunction such a reduced urinary output or ventilator difficulties with peak airway pressure. It has been reported that open abdominal management for ACS prevention reduces intestinal ischemia and excision and improves mortality [22),23)]. We are also actively introducing open abdominal management for ACS prevention for the last few years. Five out of 10 cases were saved, and if they survive the acute phase, they will be hospitalized for a long time, but there is a high possibility that they will be saved. Acosta et al. [23)] reported that the management of open abdomen at the time of the first surgery has a better prognosis than the management of open abdomen in the second term. Even if abdominal wall can be closed, our policy is to not force the abdominal wall to close in consideration of the risk factors of ACS mentioned above. If necessary, we will actively do open abdominal management. There is also a report that it should be noted that the diagnosis of ACS may be delayed in EVAR cases [24)]. By avoiding ACS, intestinal ischemia/necrosis can be prevented and the mortality rate can be reduced. For that purpose, it is necessary to do open abdominal management without hesitation. Open abdominal management requires long-term hospitalization and strict systemic management. Not only infection control and nutritional management, but also a close relationship with the gastrointestinal surgeon is important. IAP should be measured, be careful with ACS. The intestinal tract status should be monitored, and if necessary, intestinal resection and closing abdominal wall should be performed at an appropriate time.

Figure 2 shows yearly changes in abdominal aortic aneurysm surgical procedure at our hospital, including elective surgery and emergency surgery. Recently, the number of full-time radiologist at our hospital has been increased. Therefore, in the future, EVAR may increase as a surgical procedure for r AAA. If this happens, it will be necessary to observe in the future whether or not the surgical outcome will improve compared to now.

Conclusions

In order to improve the surgical outcomes for r AAA, it is necessary to start surgical procedure immediately in a situation where hemodynamics is stable. Whether to select EVAR or open repair, it should be decided not only for aneurysm anatomy but also for situation of each institution. In order to prevent postoperative intestinal necrosis, it is necessary to consider risk factor of ACS and actively introduce open abdominal management.

Declarations

Author contributions

Study conception and design: Y.M., T.T., N.K., H.I., Y.S. Main manuscript text writing: Y.M. Data extraction: Y.M., M.M., T.K., R.I., R.H., K.H., S.C., K.N., T.H., B.N., Results analysis: Y.M. Table and Figure preparation: Y.M. All authors reviewed the manuscript before submission.

Competing interests

The authors declare no competing interests.

References

1. Cupta AK, Dakour-Aridi H, Locharm S, Nejim B, Veith FJ, Malas MB. Real-world evidence of superiority of endovascular repair in treating ruptured abdominal aortic aneurysm. *J Vasc Surg* **68**, 74–81 (2018).
2. Faizer R, Weinhandl E, Hang SE, Jeune SL, Apostolidou I, Shafli SM, et.al. Decreased mortality with local versus general anesthesia in endovascular aneurysm repair for ruptured abdominal aortic aneurysm in the Vascular Quality Initiative. *J Vasc Surg* **70**, 92–101 (2017).
3. Van Beek SC, Conijn AP, Koelemey MJ, Balm R. Editor's Choice-Endovascular aneurysm repair versus open repair for patients with a ruptured abdominal aortic aneurysm: a systematic review and meta-analysis of short-term survival. *Eur J Vasc Endovasc Surg* **47**, 593–602 (2014).
4. Tan T-W, Eslami M, Rybin D, Doros C, Zhang WW, Farber A. Outcomes of endovascular and open surgical repair of ruptured abdominal aortic aneurysm in elderly patients. *J Vasc Surg* **66**, 64–70 (2017).
5. Varkevisser RRB, Swerdlow NJ, de Cuerre LEVM, Dansey K, Stangenberg L, Ciles KA, et al. Five-year survival following endovascular repair of ruptured abdominal aortic aneurysms is improving. *J Vasc Surg* **72**, 105–113 (2020).
6. IMPROVE Trial Investigators. Comparative clinical effectiveness and cost effectiveness of endovascular strategy v open repair for ruptured abdominal aortic aneurysm: three year results of the IMPROVE randomized trial. *BMJ* **359**, j4859 (2017).

7. Kanda Y. Investigation of the free available easy-to-use software 'EZR' for medical statistics. *Bone Marrow Transplant.* **48**, 452–458 (2013).
8. Fitzgerald JF, Stillman RM, Powers JC. A suggested classification and reappraisal of mortality statistics for ruptured atherosclerotic infrarenal aortic aneurysms. *Surg Gynecol Obstet.* **146**, 344–346 (1978).
9. Vascular Quality Initiative. Available at:http://www.vascularqualityinitiative.org/. Accessed November 5,2013.
10. Robinson WP, Schanzer A, Aiello FA, Flahive J, Simons JP, Doucet DR, et al. Endovascular repair of ruptured abdominal aortic aneurysms does not reduce later mortality compared with open repair. *J Vasc Surg* **63**, 617 – 24 (2016).
11. Raux M, Marzelle J, Kobeiter H, Dhonneur G, Allaire E, Cochennec F, et al. Endovascular balloon occlusion is associated with reduced intraoperative mortality of unstable patients with ruptured abdominal aortic aneurysm but fails to improve other outcomes. *J Vasc Surg* **61**, 304–308 (2015).
12. Bath J, Leite JO, Rahimi M, Ciglia J, Jain A, Shelton K, et al. Contemporary outcomes for ruptured aortic aneurysm using endovascular balloon control for hypotension. *J Vasc Surg* **67**, 1389–1396 (2018).
13. King DR. Initial care of the severely injured patient. *N Engl J Med* **380**, 763–770 (2019).
14. Karkos CD, Menexes GC, Patelis N, Kalogirou TE, Giagtzidis IT, Harkin DW. A systematic review and meta-analysis of abdominal compartment syndrome after endovascular repair of ruptured abdominal aortic aneurysms. *J Vasc Surg* **59**, 829–842 (2014).
15. Rubenstein C, Bietz G, Davenport DL, Winkler M, Endean ED. Abdominal compartment syndrome associated with endovascular and open repair of ruptured abdominal aortic aneurysms. *J Vasc Surg* **61**, 648–654 (2015).
16. Gidlund KD, Wanhainen A, Bjorck M. Intra-abdominal hypertension and abdominal compartment syndrome after endovascular repair of ruptured abdominal aortic aneurysm. *Eur J Vasc Endovasc Surg* **41**, 742–747 (2011).
17. Mehta M, Darling RC, Roddy SP, Fecteau S, Ozsvath KJ, Kreienberg PB et al. Factors associated with abdominal compartment syndrome complicating endovascular repair of ruptured abdominal aortic aneurysms. *J Vasc Surg* **42**, 1047–1051 (2005).
18. Ersryd S, Gidlund KD, Wanhainen A, Bjorck M. Editor's choise - Abdominal compartment syndrome after surgery for abdominal aortic aneurysm: a nationwide population based study. *Eur J Vasc Endovasc Surg* **52**, 158–165 (2016).
19. Malbrain ML, Cheatham ML, Kirkpatrick A, Sugrue M, Parr M, Waele JD, et al. Results from the international conference of experts on intra-abdominal hypertension and abdominal compartment syndrome. I. Definitions. *Intensive Care Med.* **32**, 1722–1732 (2006).
20. Loftus IM, Thompson MM. The abdominal compartment syndrome following aortic surgery. *Eur J Vasc Endovasc Surg* **25**, 97–109 (2003).

21. Paty P, Mehta M. Abdominal compartment syndrome after rEVAR. *Endovascular Today* **March**, 71 – 3 (2015).
22. Mayer D, Rancic Z, Meier C, Pfammatter T, Veith FJ, Lachat M et al. Open abdomen treatment following endovascular repair of ruptured abdominal aortic aneurysms. *J Vasc Surg* **50**, 1–7 (2009).
23. Acosta S, Seternes A, Venermo M, Vikatmaa L, Sorelius K, Wanhainen A et al. Open abdomen therapy with vacuum and mesh mediated fascial traction after repair: an international multicentre study. *Eur J Vasc Endovasc Surg* **54**, 697–705 (2017).
24. Ersryd S, Gidlund KD, Wanhainen A, Smith L, Bjorck M. Editor's choice – Abdominal compartment syndrome after surgery for abdominal aortic aneurysm: subgroups, risk factors, and outcome. *Eur J Vasc Endovasc Surg* **58**, 671 – 79 (2019).

Tables

Due to technical limitations, table 1,2,3 is only available as a download in the Supplemental Files section.

Figures

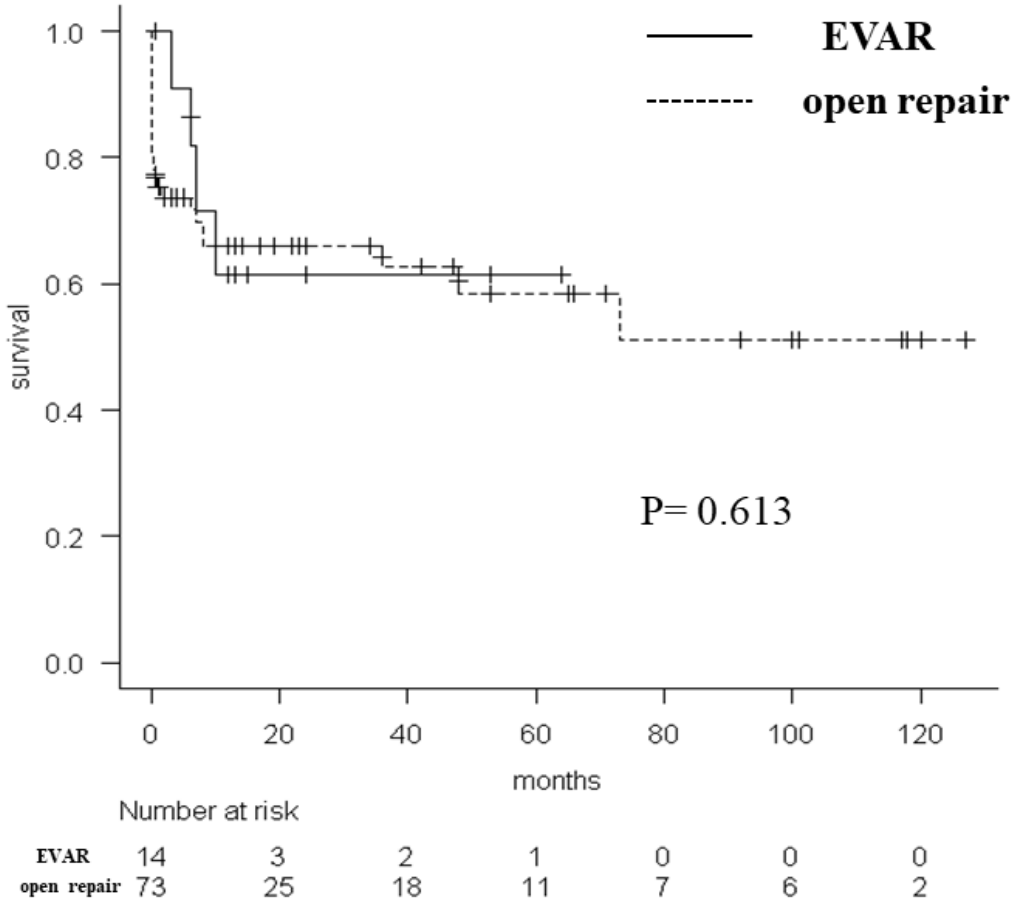

Figure 1

Comparison of 5-year survival between EVAR and open repair for ruptured abdominal aortic aneurysms

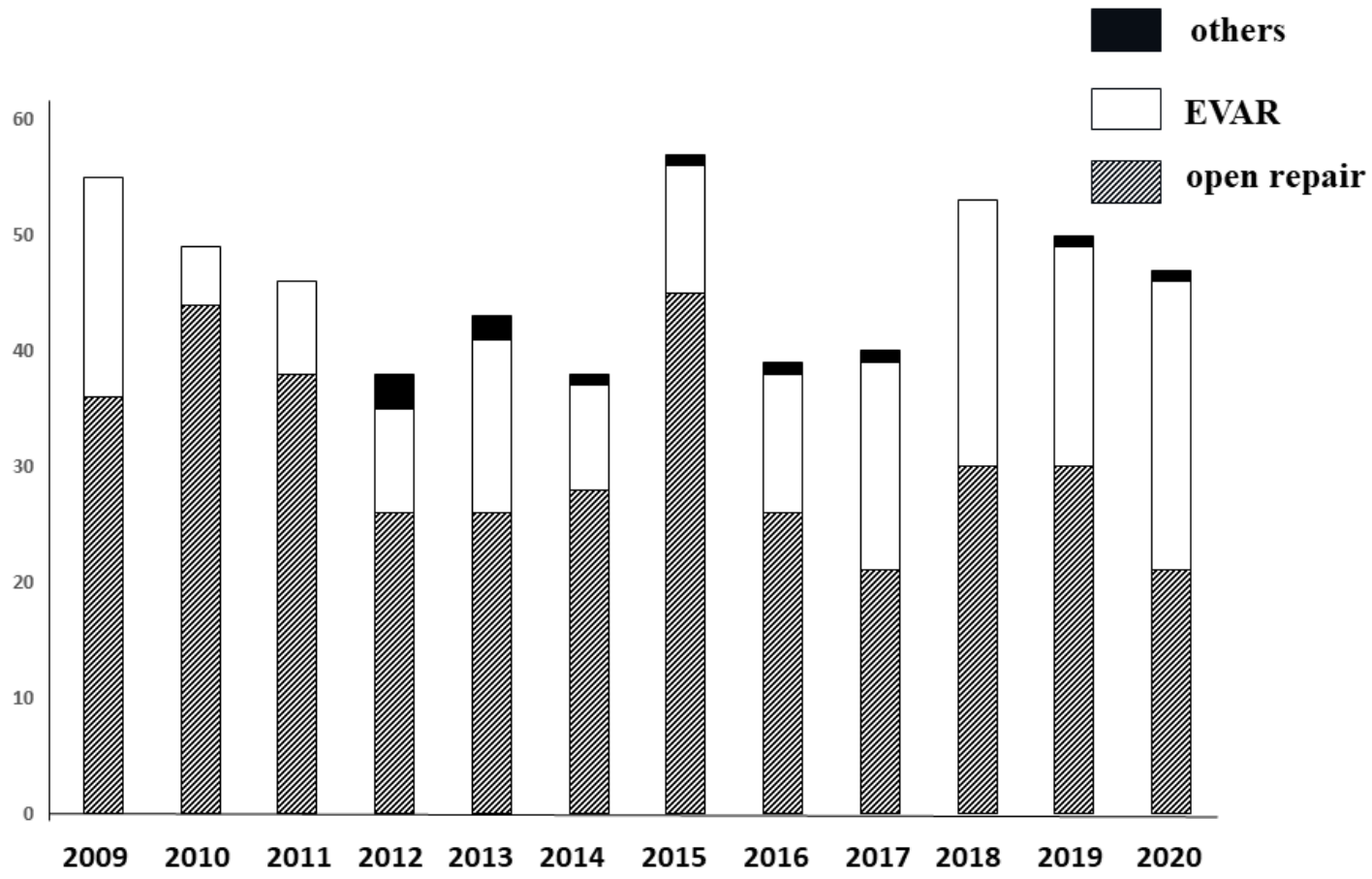

Figure 2

Changes in surgical procedures by year at our hospital

Supplementary Files

This is a list of supplementary files associated with this preprint. Click to download.

- Table1.jpg
- Table2.jpg
- Table3.jpg