SyncoPE: A Rare Presentation of Pulmonary Embolism - A Case Report

Ammar Hasnie (ammarhasnie@uabmc.edu)
University of Alabama Hospital: UAB Hospital https://orcid.org/0000-0003-1723-3196

Mauricio Kahn
University of Alabama Hospital: UAB Hospital

Gustavo Heudebert
University of Alabama Hospital: UAB Hospital

Research Article

Keywords: ECG, Pulmonary Embolism, Syncope, Case Report

Posted Date: July 30th, 2021

DOI: https://doi.org/10.21203/rs.3.rs-582851/v1

Version of Record: A version of this preprint was published at SN Comprehensive Clinical Medicine on December 1st, 2021. See the published version at https://doi.org/10.1007/s42399-021-01110-z.

Abstract

Introduction: The S1Q3T3 pattern is neither sensitive nor specific for pulmonary embolisms; however, it can help guide clinical management in a patient with a vague presentation including syncope.

Case Presentation: An elderly male presented to the hospital after an unwitnessed syncopal event. His initial EKG on admission revealed an S1Q3T3 pattern which prompted concern for a possible pulmonary embolism as the cause of his syncopal event. Further imaging confirmed the diagnosis.

Conclusion: Syncope offers a long list of possible causes, but pulmonary embolism is commonly missed on the differential diagnosis. Our patients' acute EKG findings ultimately helped guide our management to correctly diagnose our patient with a newfound pulmonary embolism as the cause of his syncopal event.

Introduction

An electrocardiogram (EKG) is commonly done when evaluating patients with concern for a pulmonary embolism (PE). However, most findings on EKG have both low sensitivity and specificity for a PE. EKG findings can vary but the most common finding is sinus tachycardia secondary to increased adrenergic drive. Rarely, we may see evidence of right ventricular strain with an S1Q3T3 pattern which can raise concern for a pulmonary embolism.

Case Presentation

A 76-year-old African American male with a past medical history significant for coronary artery disease, diabetes mellitus, unilateral severe carotid artery stenosis, and chronic kidney disease stage IIIb presented to the emergency department after an unwitnessed syncopal event. He was making breakfast when he lost consciousness. He denied any palpitations or prodromal symptoms. He regained consciousness almost immediately and denied postictal confusion. He also denied any tongue biting or loss of bowel/bladder contents.

He was afebrile with a blood pressure of 113/61 mmHg, heart rate of 67 beats per minute, respiratory rate of 18 and his oxygen saturation was 99% on room air. On physical exam lungs were clear to auscultation bilaterally. His heart had a regular rate and rhythm, normal S1 and S2 without any murmurs appreciated.

His initial labs were notable for a Cr of 2.3 mg/dL (baseline 2.1 mg/dL), platelets of 142,000/mm^3, and a hemoglobin of 10g/dL. Telemetry noted consistent sinus rhythm. Initial electrocardiogram (ECG) revealed sinus rhythm, rate of 78 beats per minute, with a large prominent S wave in lead 1 along with a Q wave and an inverted T wave in lead III (Figure 1). D-dimer was elevated at 606 ng/ml (ULN 225 ng/ml). Given his renal dysfunction, a V/Q scan was ordered which detected a mismatch in the right upper lobe consistent with a pulmonary embolism (PE). Doppler ultrasound of his lower extremities was negative for

any deep vein thrombosis. He was started on oral anticoagulation and discharged with a Holter monitor with plans to follow up with his primary care provider.

Conclusion

Syncope is total loss of consciousness that results from cerebral hypoperfusion. The etiology of a syncopal event can be split into reflex syncope, orthostatic hypotension and cardiopulmonary causes including arrhythmia, structural etiology, and PE.[1]

In general, acute PE is common in clinical practice; however, they are rapidly fatal and require a high degree of clinical suspicion to ensure prompt diagnosis and treatment. Clinical presentation varies widely from being asymptomatic to sudden death. In most cases patients tend to present with some pulmonary symptoms such as dyspnea or pleuritic chest pain. Syncope is an unusual presenting symptom for PE occuring in roughly 10% of patients. [2] While ECG abnormalities are commonly seen, they are often nonspecific. The most common ECG finding in a patient with PE is sinus tachycardia.[3] The “S1Q3T3" pattern also known as McGinn-White Sign can indicate acute right heart strain and is seen in only 10% of patients with PE.[4]

In this case, our patient presented with syncope initially concerning for a cardiac cause due to his extensive history of coronary artery disease. The S1Q3T3 pattern, that is known to be associated with pulmonary embolism, forced us to consider PE as the etiology even in the absence of respiratory distress or change in oxygen requirement making this case more challenging. This case highlights the importance of considering PE as a potential etiology for a syncopal episode— even in cases where there is no new oxygen requirement.

Declarations

Funding: None

Conflict of Interest: All authors have no disclosures

Ethics Approval: This case does not include any PHI and is exempt from IRB protocol at this institution.

Consent to participate: All individual have consented to participate in this clinical case

Consent for publication: All authors had full access to the data when designing and drafting the manuscript.

Availability of data and material (data transparency): Not applicable

Code availability (software application or custom code): Not applicable

Authors' contributions: AH and MK wrote the clinical case. GH supervised and provided edits to the final draft.

References

1. Brignole M, Moya A, de Lange FJ, et al. 2018 ESC Guidelines for the diagnosis and management of syncope. *Eur Heart J*. 2018;39(21):1883-1948. doi:10.1093/eurheartj/ehy037
2. Stein PD, Terrin ML, Hales CA, et al. Clinical, laboratory, roentgenographic, and electrocardiographic findings in patients with acute pulmonary embolism and no pre-existing cardiac or pulmonary disease. *Chest*. 1991;100(3):598-603. doi:10.1378/chest.100.3.598
3. Castelli R, Tarsia P, Tantardini C, Pantaleo G, Guariglia A, Porro F. Syncope in patients with pulmonary embolism: comparison between patients with syncope as the presenting symptom of pulmonary embolism and patients with pulmonary embolism without syncope. *Vasc Med*. 2003;8(4):257-261. doi:10.1191/1358863x03vm510oa
4. Panos RJ, Barish RA, Whye DW Jr, Groleau G. The electrocardiographic manifestations of pulmonary embolism. *J Emerg Med*. 1988;6(4):301-307. doi:10.1016/0736-4679(88)90367-8

Figures

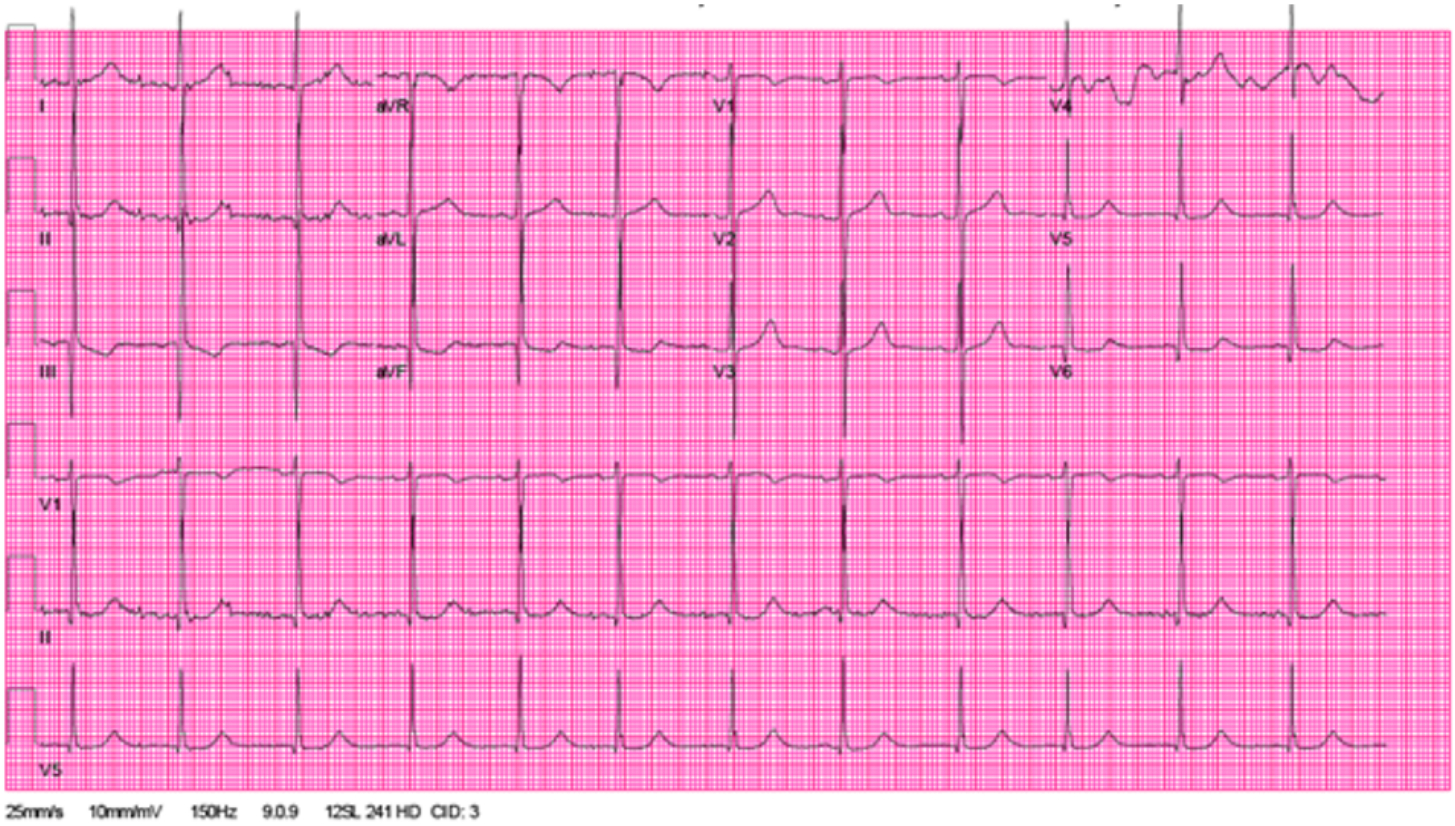

Figure 1

ECG on presentation to the emergency department. Sinus rhythm with large S wave in lead I, and both Q wave and inverted T wave in lead III.

Supplementary Files

This is a list of supplementary files associated with this preprint. Click to download.

- CAREchecklist6.1.docx