Laparoscopic Partial Gastrectomy for Large Gastric GISTs

Amr Abouzid (amrahmedabouzid@mans.edu.eg)
Mansoura University (OCMU)

Ahmed Setit
Mansoura University (OCMU)

Adel Fathi
Mansoura University (OCMU)

Mosab Shetiwy
Mansoura University (OCMU)

Research Article

Keywords: Gastrointestinal tumors, Laparoscopic gastrectomy, gastric tumors

Posted Date: June 9th, 2021

DOI: https://doi.org/10.21203/rs.3.rs-586014/v1

Version of Record: A version of this preprint was published at Journal of Gastrointestinal Cancer on July 10th, 2021. See the published version at https://doi.org/10.1007/s12029-021-00658-2.

Abstract

Background: Gastrointestinal stromal tumors (GISTs) are considered the most common mesenchymal tumors in the gastrointestinal tract and the stomach is the most frequently site affected (50–60%). The safety and feasibility of laparoscopic surgery for gastric GISTs of sizes larger than 5 cm remains unclear. It depends on the surgical skills, tumor location and the learning curve of the surgeons.

Methods: Between December 2013 and January 2021, thirty patients diagnosed with gastric GISTs underwent laparoscopic partial gastrectomy. This is a retrospective study done in surgical oncology unit, Oncology Center, Mansoura University, Egypt.

Results: The most common tumor location was in the greater curvature in (46.7%). The mean tumor size was 7.2 cm (the largest was 13 cm). All of the patients underwent laparoscopic partial gastrectomy. Splenectomy was done for one patient only. The mean operative time was 152.67 minutes and the estimated blood loss (EBL) was 139.33 ml. The mean hospital stay was 3.53 days. The mean follows up period was 32.4 months.

Conclusion: Laparoscopic resection for gastric GISTs has become a feasible method. Patients with large tumors have the same favorable outcomes as small tumors. Large-sized GISTs may receive neoadjuvant therapy to downstage the disease and make it amenable for laparoscopic resection.

Introduction

Gastrointestinal stromal tumors (GISTs) are considered the most common mesenchymal tumors in the gastrointestinal tract [1] and the stomach is the most frequently site affected (50–60%), followed by the small intestines (20–30%) and rectum (10%) [2]. GISTs originates from interstitial cells of Cajal, which are implicated in the regulation of gut peristalsis. [3] Active mutations of KIT or platelet-derived growth factor receptor alpha (PDGFRA) gene are leading to uncontrolled cell proliferation by continuous tyrosine kinase activity. [4] They are ranged clinically, from small, localized, slow-growing lesions to very aggressive tumors with high metastatic potentials. [5] Treatment of early tumors includes surgical removal with safety margins from the surrounding healthy tissue [6]. Removal of the regional lymphatic tissue is not indicated, as lymph nodes metastasis is rarely observed. [7]

In the last three decades, laparoscopy use in surgical oncology has gained much popularity in the treatment of both benign and malignant tumors. Laparoscopic resection of a gastric GIST was first done in 1992 [8]. Several studies and meta-analyses have shown that laparoscopic treatment for gastric GISTs is a safe and effective method with less blood loss, less morbidity, and early recovery [9]. The main obstacles to perform minimally invasive resection of gastric GISTs include tumor size larger than 5 cm, invasion into adjacent vital organs, and certain locations such as gastroesophageal junction [10]. Most cohort studies focused on laparoscopic surgery for smaller gastric GISTs; few have been designed for large-sized GISTs (> 5 cm) [11].

The safety and feasibility of laparoscopic surgery for gastric GISTs sized > 5 cm remains unclear. It depends on the surgical skills, tumor location and the learning curve of the surgeons [12]. Few Asian studies reported that laparoscopic resection is superior to open surgery for gastric GIST. However, most of these studies were conducted in patients with lower BMI, compared to the Western population. Our study aims to asses the feasibility and efficacy of laparoscopic surgery in patients with gastric GISTs and its application for large-sized tumors.

Patient And Methods

Study design

This is a retrospective study done in the Surgical Oncology Unit, Oncology Center, Mansoura University, Egypt. After obtaining approval from the Institutional Review Board (IRB) of Faculty of Medicine, Mansoura University code (R.21.03.1266), thirty patients with gastric GISTs were enrolled in this study between December 2013 and January 2021. Patients diagnosed by Computerized Tomography (CT) of the chest and abdomen, endoluminal ultrasound (EUS) with fine needle aspiration biopsy. Patient with sizable GISTs not amenable to laparoscopic resection received neoadjuvant tyrosine kinase inhibitors to downsize the tumor. Patients with metastatic GISTs were excluded from this study. Informed consent was obtained from all patients before inclusion in this study. Laparoscopic partial gastrectomy was performed without lymphadenectomy. The resected specimens were sent for pathological examination and assessment of the free surgical margins. High risk tumors with aggressive criteria of recurrence received adjuvant imatinib according to the NCCN Guidelines.

Procedures

All patients were operated in the supine position with their legs apart (French position). A 12-mm infraumbilical trocar was placed for the camera and 2 additional ports were used (working ports) and one additional 12-mm trocar was used for liver retraction especially in lesser curvature tumors. The tumor location was identified by mobilization and dissection of the stomach away from any adhesion (Figure. 1a). Traction was applied on the omentum surrounding the tumor or the stomach wall to avoid tumor spillage (Figure. 1b). Two intracorporeal stay sutures for traction on the proximal and distal attachments of the tumor were sometimes used (Figure. 1c).

An articulating laparoscopic linear stapler (Echelon® flex 60 mm) was used for gastric resection (Figure. 1d). After resection intracorporeal seromuscular sutures were placed and the specimen was retrieved by the Endocatch® through extension of the infraumbilical port (Figure. 2).

Study Outcomes

Patients demographics and tumor characteristics, surgical outcomes, postoperative outcomes, and patient’s follow-up were collected and assessed.

Statistical analysis

Analysis of data was performed using Statistical Package for Scientific Studies (SPSS) v.26 for MacOS v11.3. Numerical data was expressed as means ± standard deviation (SD). The Kaplan-Meier method was used to estimate the disease-free survival (DFS).

Results

Study Population

Between December 2013 and January 2021, thirty patients with gastric GISTs underwent laparoscopic partial gastrectomy in the Oncology Center, Mansoura University. The mean age was 53.67 years, and the mean BMI was 32.50 kg/m2 (Table 1). Most patients were male (56.7%) and had ASA score I (93.3%). DM, hypertension and liver disease were the common comorbidities with (10 % each). Half of the patients in this study, complained from dyspepsia (50%). The mean preoperative tumor size was 9.20 cm and (36.7%) of the patients received neoadjuvant imatinib. The largest size of the tumor in these patients was (17 cm) and was downsized to (6 cm) after 12-month of neoadjuvant treatment.

Table 1
Baseline characteristics of the patients who underwent laparoscopic partial gastrectomy for gastric GISTs:

	Patients, *n* = 30 (%)
Age, years (mean ± SD)	53.67 ± 11.006
BMI, kg/m2 (mean ± SD)	32.50 ± 5.412
ASA score:	28 (93.3%)
I	2 (6.6%)
II	
Gender: Male	17 (56.7%)
Female	13 (43.3%)
Comorbidities:	20 (66.7%)
-None	3 (10%)
-DM	3 (10%)
-HTN	3 (10%)
-Hepatic	1 (3.3%)
-Combined	
Complaint:	4 (13.3%)
-Asymptomatic (incidental)	15 (50%)
-Dyspepsia	11 (36.7%)
-Bleeding	
Neoadjuvant treatment:	19 (63.3%)
-No	11 (36.7%)
-Yes	
Tumor size at diagnosis (cm; mean ± SD)	9.20 ± 4.215

HTN: hypertension, **DM**: Diabetes Mellitus, **BMI**: Body Mass Index, **ASA**: American Society of Anesthesiology.

Intraoperative Parameters

The operative details are shown in (Table 2). The commonest tumor location was in the greater curvature in (46.7%). All of the patient underwent laparoscopic partial gastrectomy and associated splenectomy was needed in only one patient with tumor infiltrating the splenic hilum. There was no conversion to

laparotomy. The mean operative time was 152.67 min and the estimated blood loss (EBL) was 139.33 ml. Blood transfusion was needed in one patient and there was no intraoperative complication or intrabdominal tumor rupture.

Table 2
Surgical characteristics of patients who underwent laparoscopic partial gastrectomy for gastric GISTs:

	Patients, *n* = 30 (%)
Tumor location:	7 (23.3%)
- Cardia	7 (23.3%)
-Lesser curvature	14 (46.7%)
- Greater curvature	2 (6.7%)
- Antrum	
Extent of gastrectomy:	29 (96.7%)
-Partial gastrectomy	1 (3.3%)
-Partial gastrectomy and splenectomy	
Conversion rate	0 (0%)
Operation time (min; mean ± SD)	152.67 ± 56.213
EBL (ml)	139.33 ± 58.128
Blood transfusion:	29 (96.7%)
- No	1 (3.3%)
-Yes	
Operative complications:	30 (100%)
No	

EBL: Estimated Blood Loss.

Postoperative outcome

In total of 30 patients, two patients had grade II postoperative morbidities (according to Clavien and Dindo classification) requiring blood transfusion due to anemia (Table 3). One patient had grade III morbidity due chest tube insertion for pneumothorax. No patients needed ICU admission, postoperatively. We also reported no postoperative mortality. Most of the patients started oral intake in day 1 postoperatively and the mean duration of the hospital stay was 3.53 days.

Table 3
Postoperative Outcome of patients who underwent laparoscopic partial gastrectomy for gastric GISTs:

	Patients, *n* = 30 (%)
POP Complications (CD classification):	27 (90%)
-CD I	2 (6.7%)
-CD II	1 (3.3%)
-CD III	
30-day mortality:	30 (100%)
No	
Ambulation (day; mean ± SD)	0.07 ± 0.254
Oral intake (day; mean ± SD)	0.97 ± 0.490
Hospital stay (day; mean ± SD)	3.53 ± 1.137
ICU stay (day)	0 (0%)
POP: Postoperative, **CD**: Clavien Dindo	

Histopathological outcomes

The common pathological tumor size was (5–10 cm) in (66.7%), while four patients (13.3%) had a tumor size larger than 10 cm. The largest tumor size was 13 cm (Table 4). Spindle cell tumors were the commonest morphological type (66.7%) with low mitotic index in the majority of patients (83.3%). Tumor necrosis was found in only three patients (10%). Immunohistochemical markers (CD117, CD34, DOG1) were reported positive in 96.7%, 93.3% and 100%, respectively. According to the National Institute of Health (NIH), the risk stratifications of GISTs in most of the tumors (53.3%) were of intermediate risk.

Table 4
Histopathological characteristics of the patients who underwent laparoscopic partial gastrectomy for gastric GISTs:

	Patients, *n* = 30 (%)
Tumor size:	0 (0%)
-< 2 cm	6 (20%)
-2-5 cm	20 (66.7%)
-5-10 cm	4 (13.3%)
->10 cm	
Tumor Morphology:	19 (63.3%)
-Spindle	3 (10%)
-Epithelioid	7 (23.3%)
-Mixed	
Mitotic index per 50 HPF:	25 (83.3%)
-Low (< 5/5 mm)	5 (16.7%)
-High (> 5/5 mm)	
Necrosis:	27 (90%)
- No	3 (10%)
-Yes	
CD117:	1 (3.3%)
-Negative	29 (96.7%)
-Positive	
CD34:	2 (6.7%)
-Negative	28 (93.3%)
-Positive	
DOG1	30 (100%)
-Positive	

NIH: National Institute of Health, **HPF**: High Power Field

	Patients, *n* = 30 (%)
NIH risk:	0 (0%)
-Very low	7 (23.3%)
-Low	16 (53.3%)
-Intermediate	7 (23.3%)
-High	
NIH: National Institute of Health, **HPF**: High Power Field	

Follow Up

Follow up data were summarized in (Table 5). The mean follow up period was 32.4 months. Postoperative (adjuvant) therapy with imatinib was administered in 23 (76.7%) patients, ten of them received neoadjuvant treatment. The mean duration of adjuvant treatment was 20.78 months. Local recurrence developed in one patient (3.3%) with hepatic and peritoneal disease after 48 months of the primary diagnosis.

Table 5
Follow-up data on the patients who underwent laparoscopic partial gastrectomy for gastric GISTs:

	Patients, *n* = 30 (%)
Adjuvant treatment:	7 (23.3%)
No	23 (76.7%)
Yes	
Adjuvant duration (months; mean ± SD)	20.78 ± 14.541
Overall Survival (months; mean ± SD)	32.40 ± 22.269
Disease free Survival (months; mean ± SD)	32.13 ± 22.023
Recurrence:	29 (96.7%)
No	1 (3.3%)
Yes	

Discussion

This study demonstrates the feasibility of laparoscopic partial gastrectomy for gastric GISTs. The large-sized GISTs that are not feasible for laparoscopic resection or may be associated with multi-organ

resection may receive neoadjuvant therapy to be downsized, thus making them suitable for resection and avoid intrabdominal spillage and dissemination.

Laparoscopic resection of gastric GISTs has been recently adopted, because the prognosis of GISTs depends mainly on the tumor size and morphological features rather than the wide margins of resection [13].

Laparoscopic surgeries have many advantages over the traditional open surgery. Laparoscopy reduces the intraoperative blood loss, postoperative pain, and allows the early recovery of the patient with the oral intake and shorten the hospital stay [14].

The European Society for Medical Oncology (ESMO), indicated laparoscopic resection of small-sized GISTs. The treatment of large sized tumors with minimally invasive surgeries is not preferred due to the risk of intra-operative spillage [15], which is considered a significant factor for tumor recurrence.

Recent data from the National Comprehensive Cancer Network (NCCN) have indicated laparoscopic or laparoscopic-assisted resection of gastric GISTs larger than 5 cm. [16] Nowadays, there is no cutoff tumor size for safe laparoscopic surgery. It is suggested to be around 4–5 cm.

A study by Melstrom et al. [17], the mean tumor size in 17 patients was 4.3 cm (range 1.5–9.1 cm). In the current study, the mean tumor size was 7.2 cm (range 2.5–13 cm) and all patients underwent total laparoscopic resection without single intra-operative tumor rupture.

Many authors demonstrated their experience of safe laparoscopic resection of large sized GISTs > 5 cm without any complications [12]. Large tumor resection requires longer operative times, and may be associated with more significant blood loss. Tumor size is not the only difficulty with laparoscopic resection of gastric GISTs, but also the tumor location as in the gastroesophageal junction, the gastric antrum or posterior gastric wall. The most common tumor location in our study was in the greater curvature of the stomach (46.7%) which made it easier for resection laparoscopically.

Bischof et al. [18] reported a mean operative time of 157 minutes which is comparable to that in our study (153 minutes). Roggin and Posner presented results from five reports on the laparoscopic resection of GISTs and the conversion rates ranged from 0 to 6.5% [19]. However, we reported no intraoperative complications nor conversion into laparotomy in our study.

Oral intake was started in most of the patients in our study in POD 1, thus the mean hospital stay was 3.53 days. In the study by Chi. et.al, oral intake was 3.5 days but the mean hospital stay was 6.1 days [20]. In our series, patients had a smooth postoperative course apart from blood transfusion for two cases due to anemia and another had pneumothorax necessitating chest tube insertion. We had no postoperative mortality in our study. Gertsen et al [21], reported that 6 patients (27%) had postoperative morbidity. One patient was re-operated for anastomotic leakage. Two patients developed pneumonia, one had postoperative cardiac complications, and another had urologic complication. There was no postoperative mortality.

Most of the tumors in our study were large-sized (5 to 10 cm) and only four patients had a tumor size more than 10 cm. The largest tumor size was 13 cm (2 patients) and the mean tumor size was 7.2 cm. All patients had total laparoscopic resection with delivery of specimens through extension of the infraumbilical port without the need for a mini-laparotomy. Immunohistochemical examination was done for all patients revealing positive CD117, CD34, DOG1 for 96.7%, 93.3% and 100% patients, respectively, and most of the tumors were of intermediate risk. In another study, the tumor size was 4 cm and the largest was 5.5 cm and the immunohistochemical examination was CD 117 (97.1%), CD 34 (70.6%), DOG1 (26.5%). Their NIH tumor risk was low in 50% of the cases. [22]

Adjuvant therapy was given to 23 patients, in our study. These patients were with intermediate and high-risk tumor features. Patients were followed up within a mean period of 32.4 months. Clinical and radiological assessment were done. Local recurrence developed in one patient (3.3%) with hepatic and peritoneal disease after 48 months. This patient had a tumor with high risk features (mitotic index > 5) and received both neoadjuvant and adjuvant therapy (Fig. 3). The recurrence rate after laparoscopic resection of gastric GISTs was reported to be ranged from 4.8 to 18% [23].

Another study found no significant difference in terms of disease-free survival and overall survival between the laparoscopic and the open resections for gastric GISTs. In the laparoscopic group, six patients had either local recurrence or distant metastasis and four of these patients died, while, in the open group, ten had either local recurrence or distant metastasis and five of them died. These results indicate that laparoscopic surgery for gastric GISTs has oncologic outcomes similar to that of open surgery [20].

Conclusion

This study demonstrated the feasibility of laparoscopic resection for large gastric GIST. Patients with large tumors have the same favorable outcomes as small tumors. However, large-sized GISTs may benfit from neoadjuvant therapy making them more amenable to laparoscopic resections.

Declarations

Author’s Contributions

All authors have made substantial contributions to conceptualization, methodology, validation, formal analysis, investigation, resources, writing – original draft, writing – review and editing,

visualization, and project administration. All authors have approved the submitted version of the article.

Conflict of Interest

The authors declare no conflict of interest.

Funding: none

Ethics approval: approval from the Institutional Review Board (IRB) of Faculty of Medicine, Mansoura University code (R.21.03.1266)

References

1. Koh, Y. X., Chok, A. Y., Zheng, H. L., Tan, C. S., Chow, P. K., Wong, W. K., & Goh, B. K. (2013). A systematic review and meta-analysis comparing laparoscopic versus open gastric resections for gastrointestinal stromal tumors of the stomach. Annals of surgical oncology, 20(11), 3549-3560.
2. DeMatteo, R. P., Lewis, J. J., Leung, D., Mudan, S. S., Woodruff, J. M., & Brennan, M. F. (2000). Two hundred gastrointestinal stromal tumors: recurrence patterns and prognostic factors for survival. Annals of surgery, 231(1), 51.
3. Nishida, T., & Hirota, S. (2000). Invited Reviews-Biological and clinical review of stromal tumors in the gastrointestinal tract. Histology and histopathology, 15(4), 1293-1302.
4. Shinomura, Y., Kinoshita, K., Tsutsui, S., & Hirota, S. (2005). Pathophysiology, diagnosis, and treatment of gastrointestinal stromal tumors. Journal of gastroenterology, 40(8), 775-780.
5. Walędziak, M., Różańska-Walędziak, A., Kowalewski, P. K., Janik, M. R., Brągoszewski, J., & Paśnik, K. (2017). Bariatric surgery and incidental gastrointestinal stromal tumors–a single-center study: VSJ Competition, 1st place. Videosurgery and Other Miniinvasive Techniques, 12(3), 325.
6. Zhao, X., & Yue, C. (2012). Gastrointestinal stromal tumor. Journal of gastrointestinal oncology, 3(3), 189.
7. Sicklick, J. K., & Lopez, N. E. (2013). Optimizing surgical and imatinib therapy for the treatment of gastrointestinal stromal tumors. Journal of gastrointestinal surgery, 17(11), 1997-2006.
8. LUKASZCZYK, J. J., & PRELETZ Jr, R. J. (1992). Laparoscopic resection of benign stromal tumor of the stomach. Journal of laparoendoscopic surgery, 2(6), 331-334.
9. Goh, B. K., Chow, P. K., Chok, A. Y., Chan, W. H., Chung, Y. F. A., Ong, H. S., & Wong, W. K. (2010). Impact of the introduction of laparoscopic wedge resection as a surgical option for suspected small/medium-sized gastrointestinal stromal tumors of the stomach on perioperative and oncologic outcomes. World journal of surgery, 34(8), 1847-1852.
10. De Vogelaere, K., Van Loo, I., Peters, O., Hoorens, A., Haentjens, P., & Delvaux, G. (2012). Laparoscopic resection of gastric gastrointestinal stromal tumors (GIST) is safe and effective, irrespective of tumor size. Surgical endoscopy, 26(8), 2339-2345.
11. Lin, J., Huang, C., Zheng, C., Li, P., Xie, J., Wang, J., & Lu, J. (2014). Laparoscopic versus open gastric resection for larger than 5 cm primary gastric gastrointestinal stromal tumors (GIST): a size-matched comparison. Surgical endoscopy, 28(9), 2577-2583.
12. Khoo, C. Y., Goh, B. K., Eng, A. K., Chan, W. H., Teo, M. C., Chung, A. Y., ... & Wong, W. K. (2017). Laparoscopic wedge resection for suspected large (≥ 5 cm) gastric gastrointestinal stromal tumors. Surgical endoscopy, 31(5), 2271-2279.

13. Dematteo, R. P., Heinrich, M. C., Wa'el M, E. R., & Demetri, G. (2002). Clinical management of gastrointestinal stromal tumors: before and after STI-571. Human pathology, 33(5), 466-477.
14. Pędziwiatr, M., Matłok, M., Kisialeuski, M., Major, P., Migaczewski, M., Budzyński, P., ... & Budzyński, A. (2014). Enhanced recovery (ERAS) protocol in patients undergoing laparoscopic total gastrectomy. Videosurgery and Other Miniinvasive Techniques, 9(2), 252.
15. ESMO/European Sarcoma Network Working Group. (2014). Gastrointestinal stromal tumours: ESMO Clinical Practice Guidelines for diagnosis, treatment and follow-up. Annals of oncology: official journal of the European Society for Medical Oncology, 25, iii21-iii26.
16. Demetri, G. D., Von Mehren, M., Antonescu, C. R., DeMatteo, R. P., Ganjoo, K. N., Maki, R. G., ... & Wayne, J. D. (2010). NCCN Task Force report: update on the management of patients with gastrointestinal stromal tumors. Journal of the National Comprehensive Cancer Network, 8(Suppl_2), S-1.
17. Melstrom, L. G., Phillips, J. D., Bentrem, D. J., & Wayne, J. D. (2012). Laparoscopic versus open resection of gastric gastrointestinal stromal tumors. American journal of clinical oncology, 35(5), 451-454.
18. Bischof, D. A., Kim, Y., Dodson, R., Jimenez, M. C., Behman, R., Cocieru, A., ... & Pawlik, T. M. (2014). Open versus minimally invasive resection of gastric GIST: a multi-institutional analysis of short-and long-term outcomes. Annals of surgical oncology, 21(9), 2941-2948.
19. Roggin, K. K., & Posner, M. C. (2012). Modern treatment of gastric gastrointestinal stromal tumors. World journal of gastroenterology: WJG, 18(46), 6720.
20. Chi, J. L., Xu, M., Zhang, M. R., Li, Y., & Zhou, Z. G. (2017). Laparoscopic versus open resection for gastric gastrointestinal stromal tumors (GISTs): a size–location-matched case–control study. World journal of surgery, 41(9), 2345-2352.
21. Gertsen, E. C., van Boxel, G. I., Brosens, L. A., Ruurda, J. P., & van Hillegersberg, R. (2020). Minimally Invasive Resection of Large Gastric Gastrointestinal Stromal Tumors. Digestive Surgery, 37(6), 441-446.
22. Stanek, M., Pisarska, M., Budzyńska, D., Rzepa, A., Pędziwiatr, M., Major, P., & Budzyński, A. (2019). Gastric gastrointestinal stromal tumors: clinical features and short-and long-term outcomes of laparoscopic resection. Videosurgery and Other Miniinvasive Techniques, 14(2), 176.
23. Cai, J. Q., Chen, K., Mou, Y. P., Pan, Y., Xu, X. W., Zhou, Y. C., & Huang, C. J. (2015). Laparoscopic versus open wedge resection for gastrointestinal stromal tumors of the stomach: a single-center 8-year retrospective cohort study of 156 patients with long-term follow-up. BMC surgery, 15(1), 1-10.

Figures

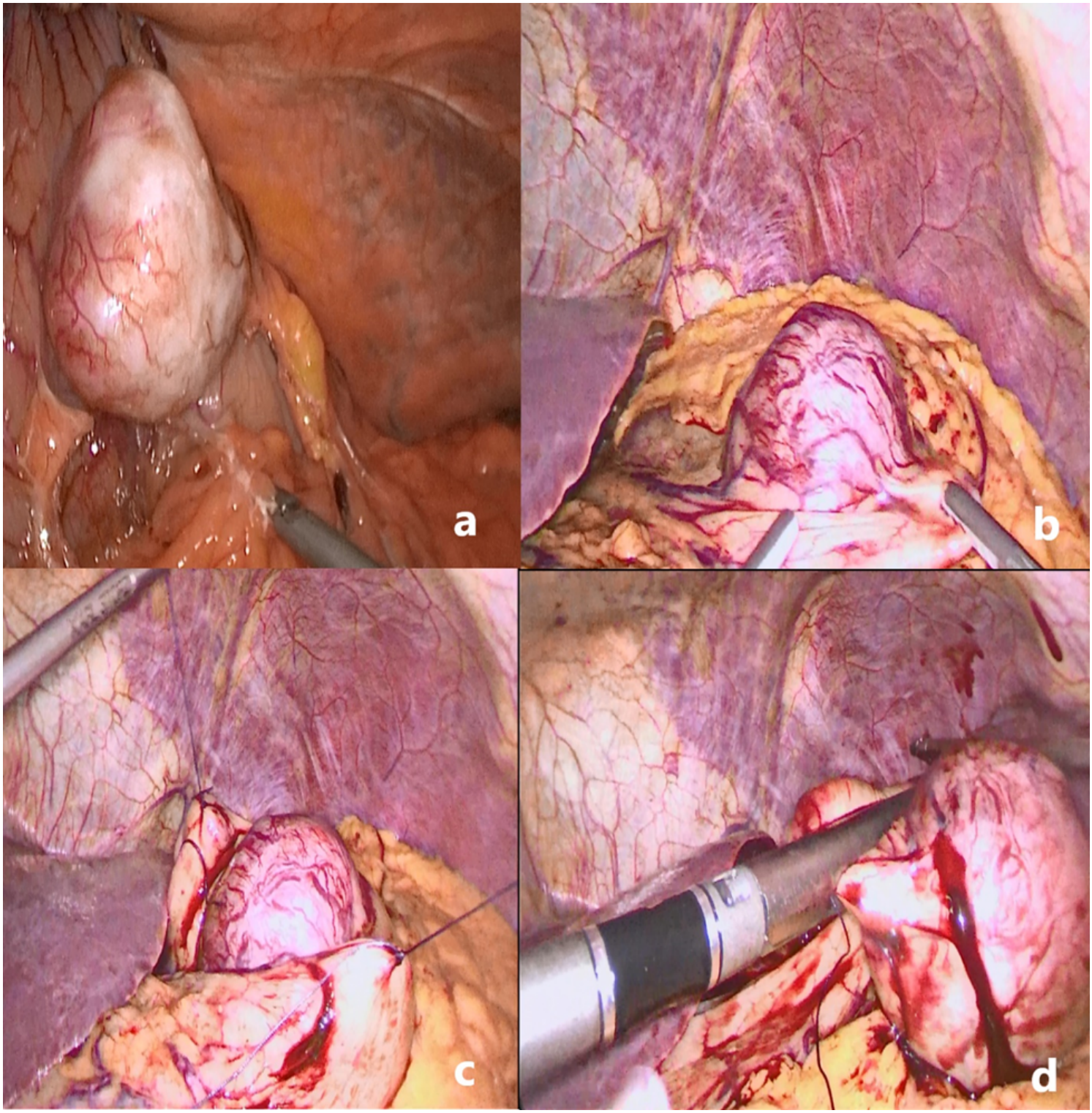

Figure 1

Steps of laparoscopic partial gastrectomy for gastric GISTs: (a) Dissection of the tumor from the surrounding tissue. (b) Traction on the gastric wall for tumor mobilization. (c) Two intracorporeal sutures on the nearby gastric wall for tumor traction. (d) laparoscopic resection of the gastric GISTs using linear stapler.

Figure 2

Delivery of the mass within the Endocatch® through the infraumbilical port.

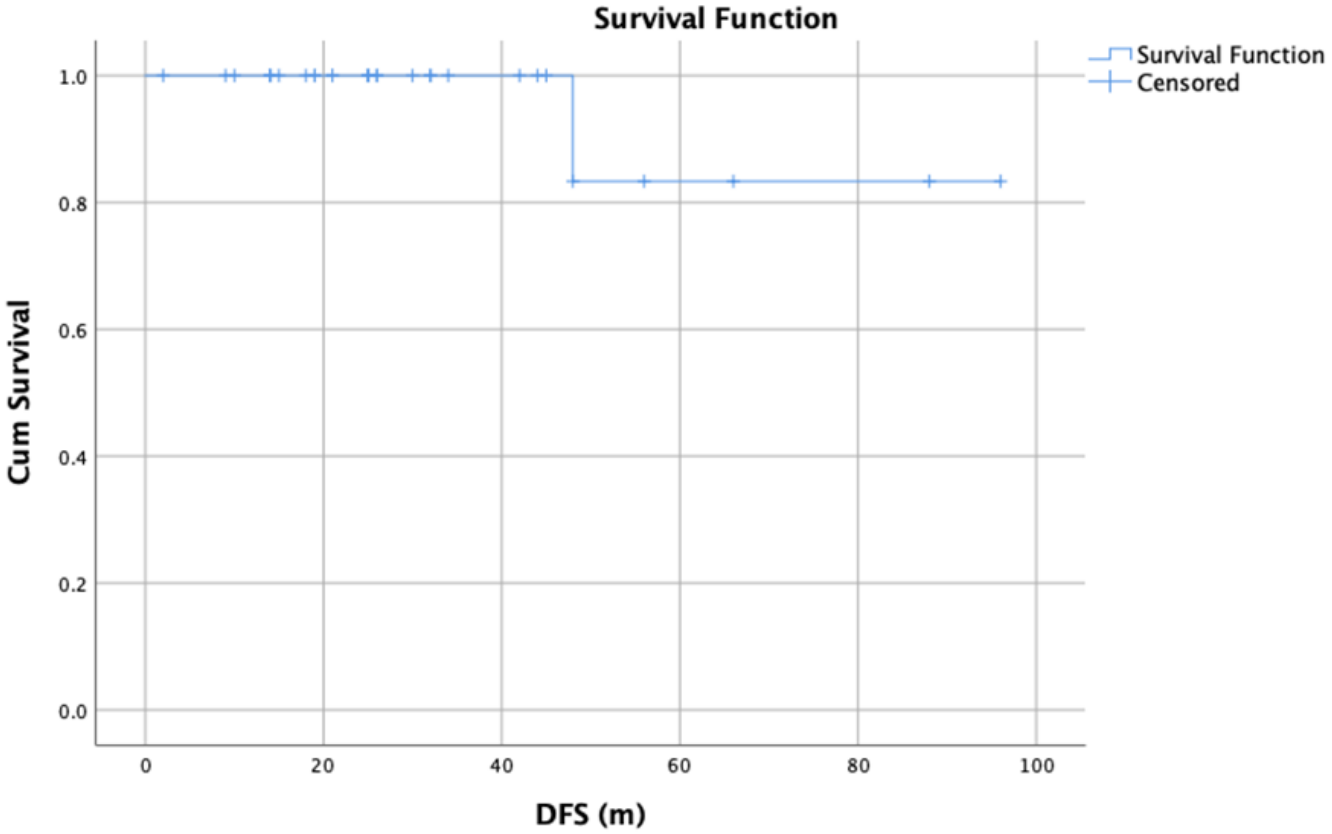

Figure 3

Kaplan-Meier survival of patients who underwent laparoscopic partial gastrectomy for gastric GISTs