Various radiological findings in Indonesian patients with COVID-19: a case series

Theresia Riawati (riabagus@yahoo.com)
RS Panti Rapih Yogyakarta

Wikan Indrarto
RS Panti Rapih Yogyakarta

Aditya Rifqi Fauzi
FK-KMK UGM

Gunadi (drgunadi@ugm.ac.id)
FK-KMK UGM https://orcid.org/0000-0002-4707-6526

Case Report

Keywords: abnormality findings, COVID-19, ground glass opacity, plain chest x-ray, thoracic CT scan

Posted Date: September 17th, 2020

DOI: https://doi.org/10.21203/rs.3.rs-58947/v1

Abstract

Background: Plain chest X-rays (CXRs) are considered more effective and useful for the initial screening and follow-up of patients with COVID-19. Moreover, radiological evaluation of suspected COVID-19 patients is required for early detection of thoracic involvement, particularly in emergency units, while waiting for definitive diagnosis by real-time reverse transcription polymerase chain reaction (RT-PCR). Here, we report a case series of CXR findings in Indonesian patients with COVID-19 in our institution.

Case presentations: We included 7 patients with COVID-19 confirmed by RT-PCR, including 4 females and 3 males, with ages ranging from 36–71 years. All patients showed abnormal findings on CXR when admitted to the hospital, except one, composed of ground glass opacity (GGO) (n=1), consolidation (n=3), and both (n=2). Both and one side of the lung were affected in three and three (left side=2; right side=1) patients, respectively. Pneumonia degrees of mild, moderate and severe were observed in three, one, and two patients, respectively. All patients eventually recovered.

Conclusions: CXR showed various abnormality findings in patients with COVID-19, including the type, location, and degree of pneumonia.

Introduction

Severe acute respiratory syndrome coronavirus 2 (SARS-CoV-2), which causes coronavirus disease 2019 (COVID-19), has become a global pandemic that has infected nearly 11 million people and claimed 523,011 lives as of July 4, 2020 [1,2].

The first two cases in Indonesia were declared on March 2, 2020. Since it was first announced in Indonesia, COVID-19 cases have increased rapidly over time, thus requiring continued attention. On July 5, Indonesia recorded 63,749 COVID-19 infections [3]. Until now, radiological examinations have an important role in the management of COVID-19, especially for screening tests, working diagnosis and monitoring pneumonia [4,5].

Plain chest X-rays (CXR) and computerized tomography (CT) scans are key radiological or imaging examinations in confirming COVID-19 diagnosis. CT scans are reported to be more sensitive in diagnosing COVID-19 than CXR [6]. However, its use is limited due to its expense and is not widely available, especially in developing countries. Therefore, CXR is considered more effective and useful for the initial screening and follow-up of patients with COVID-19 [7,8]. Moreover, radiological evaluation of suspected COVID-19 patients is required for early detection of thoracic involvement, particularly in emergency units, while waiting for definitive diagnosis by real-time reverse transcription polymerase chain reaction (RT-PCR) [9]. In Indonesia, there is no consensus on the use of chest CT scans for COVID-19 cases, but it depends on the availability of tools, facilities, and human resources in most hospitals. Chest CT scanning is not recommended for screening tests and in patients with mild and asymptomatic symptoms but is indicated in patients with negative RT-PCR; however, they show worsening clinical signs

and severe pneumonia with complications. Here, we report a case series of CXR findings in Indonesian patients with COVID-19.

Case Presentation

There were 7 patients diagnosed with COVID-19 according to positive RT-PCR results in our hospital. They consisted of 4 females and 3 males, with ages ranging from 36–71 years. Informed consents were obtained from the patients.

Case 1: A 59-year-old female presented with cough with phlegm, runny nose, fever, and shortness of breath 3 days before admission. The patient was taking self-medication using decongestant drugs, but her complaints did not improve. There was no history of traveling to areas with COVID-19 local transmission. A CXR was performed, and the results showed bilateral consolidation in the basal lung (Fig. 1). The patient was then hospitalized with a diagnosis of bronchial asthma. Later, an RT-PCR test for COVID-19 was performed, and the results were positive. During treatment, the patient received therapy antibiotic therapy, namely, ceftazidime and levofloxacin, while she also received medication for her asthma.

Case 2: A 61-year-old female presented with fever, shortness of breath, and cough. Complaints of shortness of breath felt worse starting 1 day before admission. The patient was brought to the emergency room, and a CXR was performed. The result showed consolidation in the basal lung sinistra (Fig. 2). The patient had comorbid diabetes mellitus and chronic renal failure. RT-PCR swab tests were performed, and the results were positive. The patient was diagnosed with COVID-19, chronic kidney disease and diabetes mellitus. After admission, the patient received antibiotics and antiviral therapy based on the COVID-19 Prevention and Control guidelines by the Indonesian Ministry of Health, namely, hydroxychloroquine and oseltamivir for his COVID-19, while she also received medication for her chronic renal disease, hypertension, and diabetes.

Case 3: A 40-year-old male with complaints of fever 11 days before admission, accompanied by cough, runny nose, shortness of breath, dizziness, and nausea, came to our hospital. The patient had a history of asthma, diabetes and hypertension that was controlled with routine medication. The patient had comorbidities of diabetes mellitus and hypertension. A CXR was performed, and the results showed ground glass opacities (GGOs) in the periphery of the left lung and consolidation in the bilateral parahilar and paracardial regions of the lung (Fig. 3). RT-PCR swab examination was carried out, and the result was positive for COVID-19. After admission, the patient received antibiotics and antiviral therapy based on the COVID-19 Prevention and Control guidelines by the Indonesian Ministry of Health, namely, hydroxychloroquine and oseltamivir for his COVID-19, while also receiving medication for his diabetes and hypertension.

Case 4: A 48-year-old female presented with fever 10 days before admission, complaint accompanied by cough and vomiting. Her husband had a history of traveling from a local transmission area. The patient had comorbid diabetes mellitus. A CXR was carried out, showing the appearance of GGO in the periphery

of both the lung and multifocal consolidation parahilar and paracardial in the right lung (Fig. 4). RT-PCR for COVID-19 was carried out, and the results were positive. After admission, the patient received antibiotics and antiviral therapy based on the COVID-19 Prevention and Control guidelines by the Indonesian Ministry of Health, namely, lopinavir/ritonavir, oral levofloxacin, and oral hydroxychloroquine for her COVID-19 diagnosis, while also receiving medication for the possibility of bacterial infection.

Case 5: A 36-year-old female with the chief complaint of fever 4 days before admission. There was no history of contact with suspected or confirmed COVID-19 patients. A CXR showed GGO in the periphery of the left lung. RT-PCR for COVID-19 was carried out, and the results were positive. After admission, the patient received antibiotics and antiviral therapy based on the COVID-19 Prevention and Control guidelines by the Indonesian Ministry of Health, namely, lopinavir / ritonavir, hydroxychloroquine, azithromycin, and oseltamivir.

Case 6: A 57-year-old male came to our hospital without complaints. He brought the RT-PCR COVID-19 swab results, which showed that he was positive. He had a history of traveling to the local transmission area. The patient had no comorbidities. A CXR revealed consolidation in the basal right lung (Fig. 6). Patients were hospitalized, and after admission, the patient received antibiotics and antiviral therapy based on the COVID-19 Prevention and Control guidelines by the Indonesian Ministry of Health, namely, azithromycin, chloroquine, methisoprinol, and oseltamivir.

Case 7: A 71-year-old male presented with a complaint of pain in his right leg, and the patient was asked to be treated. The patient had a history of living with his children who did not comply with the COVID-19 prevention health protocol. His CXR was within normal limits (Fig. 7). The patient had a history of diabetes mellitus. The patient underwent an RT-PCR swab examination for COVID-19, and the results were positive. The patient was treated with a diagnosis of COVID-19, anemia and diabetes mellitus, and diabetic ulcer on his left foot. After admission, the patient received antibiotics and antiviral therapy based on the COVID-19 Prevention and Control guidelines by the Indonesian Ministry of Health, namely, azithromycin, chloroquine and oseltamivir, while he also received therapy for his diabetes and diabetic ulcer.

Discussion

To date, confirmation of the diagnosis of COVID-19 requires viral nucleic acid detection from throat swabs using RT-PCR, although this test is considered only specific but not sensitive. Current studies have shown that lung imaging can manifest earlier than clinical symptoms. Therefore, detecting the disease quickly and accurately is of great significance, and imaging is playing a key role in preclinical screening [6,10].

CXR is the most common radiological examination for patients with respiratory disorders, including COVID-19 [11]. Since it is readily available in almost all health care facilities, particularly in developing countries, and less expensive, CXR is considered more effective and useful for initial screening and follow-up of the progress of patients with COVID-19 [7,8].

The typical CXR in patients with COVID-19 is GGO. In addition, consolidation is usually multifocal, peripheral and bilateral, but in the early stages of the disease, it can be unifocal and is most often seen in the inferior lobe of the right lung. Pleural effusion and hilar lymphadenopathy are rare. This bilateral pulmonary involvement differentiates COVID-19 from bacterial pneumonia [11]. These findings are compatible with our patients.

Moreover, the degree of pneumonia based on CXR consists of no abnormality/normal, focal-unilateral/mild, bilateral/moderate focal, and multifocal-bilateral/severe [12]. Most of our patients with COVID-19 showed bilateral, multifocal, and severe pneumonia.

The imaging manifestation of COVID-19 is similar to viral pneumonia but also has its own characteristics, such as multiple plaque shadows and interstitial changes that are mostly seen in peripherals and subpleural areas, as well as shadow infiltration in both lungs. In severe cases, it can appear as a consolidation with a "white lung" image [12]. Commonly seen patterns are GGO, with ill-defined margins, air bronchograms, smooth or irregular interlobular or septal thickening, and thickening of the adjacent pleura, with predominance in the right lower lobe [13]. These findings are quite similar to the radiographic images of SARS infection [14], except SARS shows more unifocal rather than bilateral involvement in COVID-19. Middle-east respiratory syndrome (MERS) pneumonia also shares similarities in subpleural and basilar airspace lesions, with extensive GGO and consolidation [15].

Even though CXR is less sensitive than CT scanning to diagnose COVID-19, it has a significant role in the management of the outbreak [16,17]. Additionally, CT scans have a very low specificity to detect the peculiar findings of pneumonia due to COVID-19 [17,18]. Other advantages of CXR over CT scans are as follows: 1) it is easier to operate the X-rays, particularly the procedure of disinfection that should be performed after each examination, and 2) it can be conducted at the bedside of patients, therefore minimizing the cross-infection risk in the radiology department [9]. In conclusion, CXR shows various abnormality findings in patients with COVID-19, including the type, location, and degree of pneumonia.

Declarations

Ethics approval and consent to participate

The Medical and Health Research Ethics Committee of the Faculty of Medicine, Public Health and Nursing, Universitas Gadjah Mada/Dr. Sardjito Hospital ruled the study exempt from approval because this study was a case series. The authors attest that full and informed consent was obtained from the patients who had undergone medical treatment in our hospital.

Consent for publication

Written informed consent was obtained from the patients for publication of this case report and the associated images.

Availability of data and material

The datasets used and/or analyzed during the current study are available from the corresponding author on reasonable request.

Competing interests

The authors declare that they have no competing interests.

Funding

The authors declare that they have no funding source.

Authors' contributions

TR, WI and G conceived the study. ARF and G drafted the manuscript, and TR and WI critically revised the manuscript for important intellectual content. TR, WI and G facilitated all project-related tasks. All authors have read and approved the manuscript and agreed to be accountable for all aspects of the work in ensuring that questions related to the accuracy or integrity of any part of the work are appropriately investigated and resolved.

Acknowledgment

We thank all staff and nursing teams who were involved in the patient's care.

References

1. World Health Organization. https://www.who.int/news-room/detail/27-04-2020-who-timeline---COVID-19 Accessed on July 5, 2020.
2. World Health Organization. Coronavirus Disease 2019 (COVID-19) Situation Report – 166. Geneva: WHO; 2020.
3. Ministry of Health Republic of Indonesia. https://covid-monitoring.kemkes.go.id/ Accessed on July 5, 2020.

4. Koo HJ, Lim S, Choe J, Choi SH, Sung H, Do KH. Radiographic and CT features of viral pneumonia. Radiographics. 2018;38:719–39.
5. Sheard S, Rao P, Devaraj A. Imaging of acute respiratory distress syndrome. Respir Care. 2012;57:607–12.
6. Pan Y, Guan H, Zhou S, Wang Y, Li Q, Zhu T, Hu Q, Xia L. Initial CT findings and temporal changes in patients with the novel coronavirus pneumonia (2019-nCoV): a study of 63 patients in Wuhan, China. Eur Radiol. 2020.
7. Hansell DM, Bankier AA, MacMahon H, McLoud TC, Muller NL, Remy J. Fleischner society: glossary of terms for thoracic imaging. Radiology. 2008;246:697–722.
8. Choi KW, Chau TN, Tsang O, Tso E, Chiu MC, Tong WL, Lee PO, Ng TK, Ng WF, Lee KC, et al. Outcomes and prognostic factors in 267 patients with severe acute respiratory syndrome in Hong Kong. Ann Intern Med. 2003;139:715–23.
9. Cozzi D, Albanesi M, Cavigli E, et al. Chest X-ray in new Coronavirus Disease 2019 (COVID-19) infection: findings and correlation with clinical outcome. Radiol Med. 2020;125:730-7.
10. Huang C, Wang Y, Li X, Ren L, Zhao J, Hu Y, Zhang L, Fan G, Xu J, Gu X, Cheng Z. Clinical features of patients infected with 2019 novel coronavirus in Wuhan, China. Lancet. 2020;395(10223):497-506.
11. Chen H, Ai L, Lu H, Li H. Clinical and imaging features of COVID-19. Rad Infect Dis. 2020.
12. Shi H, Han X, Jiang N, Cao Y, Alwalid O, Gu J, Fan Y, Zheng C. Radiological findings from 81 patients with COVID-19 pneumonia in Wuhan, China: a descriptive study. Lancet Infect Dis. 2020;20:425–34.
13. Ooi GC, Khong PL, Müller NL, Yiu WC, Zhou LJ, Ho JC, Lam B, Nicolaou S, Tsang KW. Severe acute respiratory syndrome: temporal lung changes at thin-section CT in 30 patients. Radiology. 2004;230:836-44.
14. Ajlan AM, Ahyad RA, Jamjoom LG, Alharthy A, Madani TA. Middle East respiratory syndrome coronavirus (MERSCoV) infection: chest CT findings. AJR Am J Roentgenol;203:782–787.
15. Hamimi A. MERS-CoV: Middle East respiratory syndrome corona virus: Can radiology be of help? Initial single center experience. Egypt J Radiol Nucl Med. 2016;47:95-106.
16. Giovagnoni A. Facing the COVID-19 emergency: we can and we do. Radiol Med. 2020;125:337–8.
17. Choi H, Qi X, Yoon SH, et al. Extension of coronavirus disease 2019 (CVID-19) on chest CT and implications for chest radiograph interpretation. Radiology. 2020 doi: 10.1148/ryct.2020200107.
18. Ai T, Yang Z, Hou HY, et al. Correlation of chest CT and RT-PCR testing in coronavirus disease 2019 (COVID-19) in China: a repost of 1014 cases. Radiology. 2020 doi: 10.1148/radiol.2020200642.

Figures

Figure 1

Plain chest X-ray showed bilateral consolidation in the basal lung.

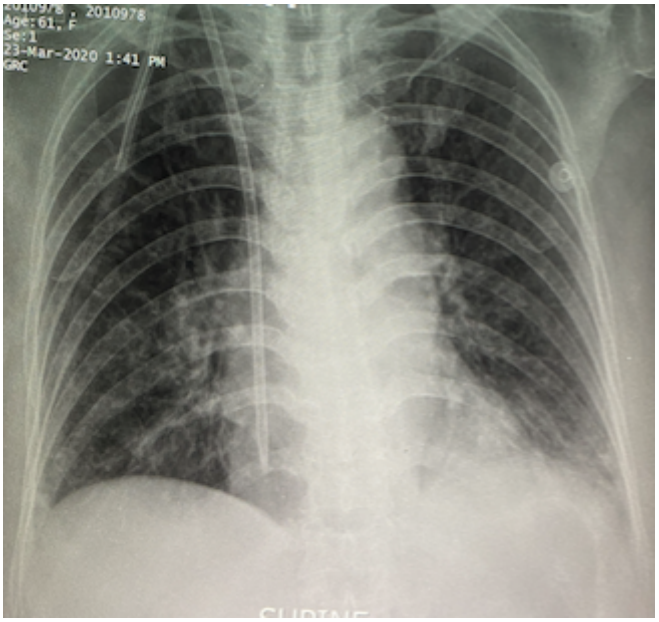

Figure 2

Plain chest X-ray revealed consolidation in the basal lung sinistra.

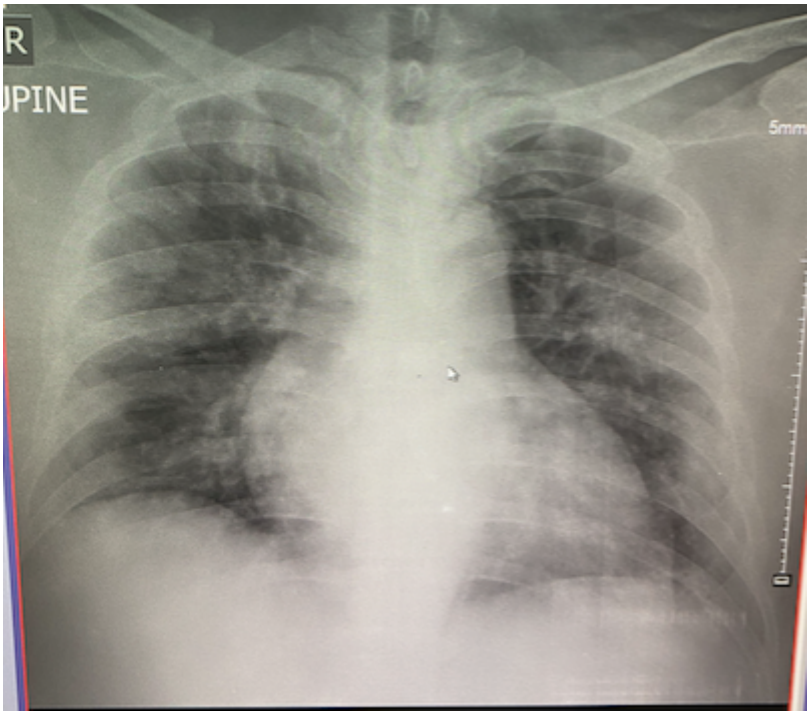

Figure 3

Figure 3. Plain chest X-ray presented GGOs in the periphery of the left lung and consolidation in the bilateral parahilar and paracardial regions of the lung.

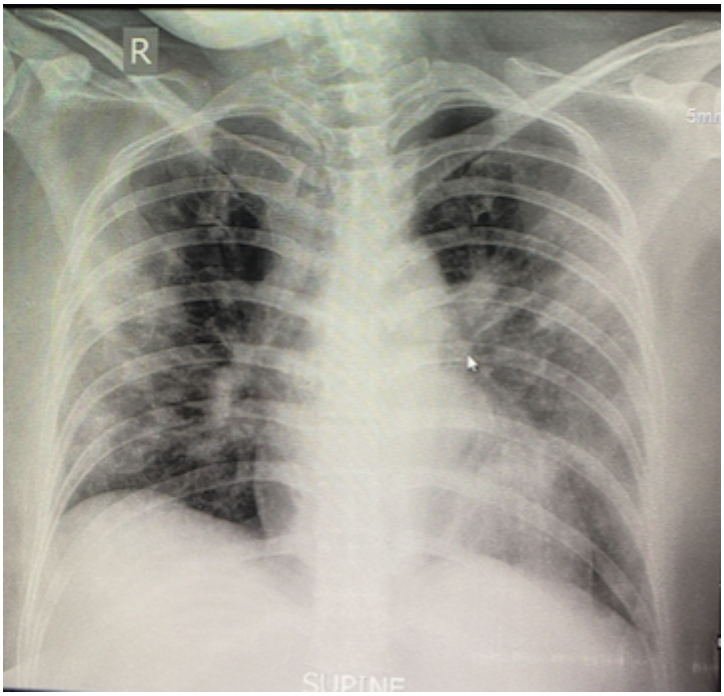

Figure 4

Plain chest X-ray showed the appearance of GGO in the periphery of both the lung and multifocal consolidation parahilar and paracardial in the right lung.

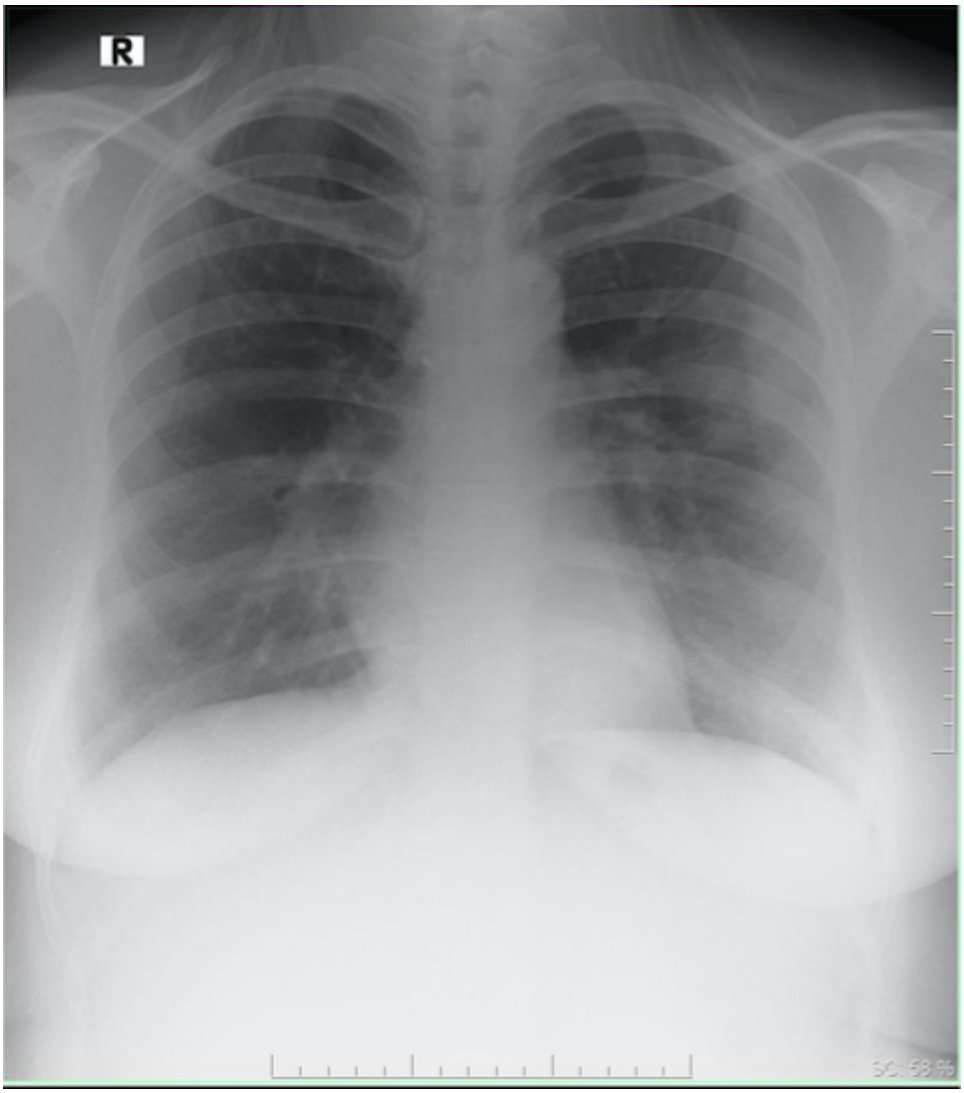

Figure 5

Plain chest X-ray displayed GGO in the periphery of the left lung.

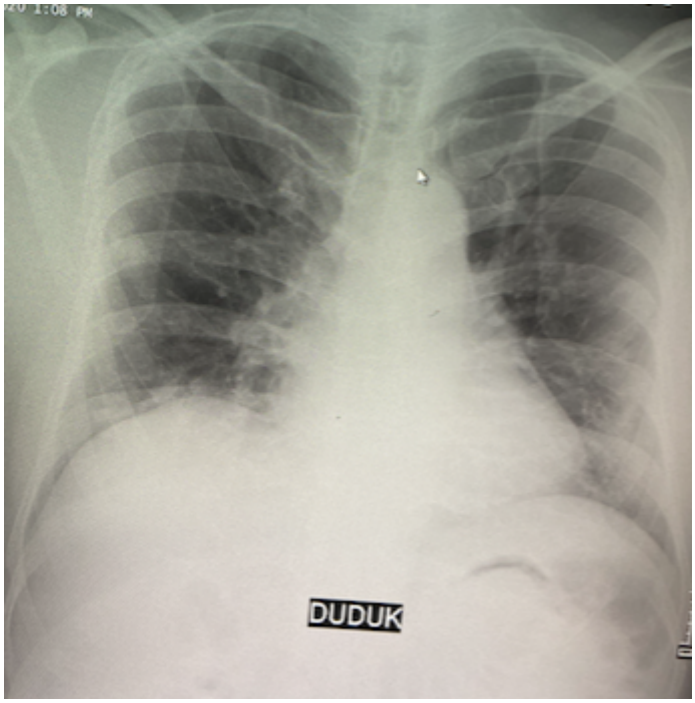

Figure 6

Plain chest X-ray demonstrated consolidation in the basal right lung.

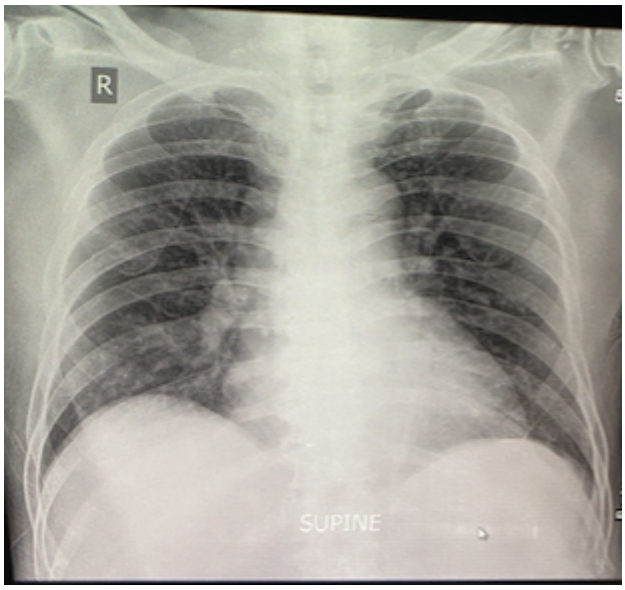

Figure 7

Plain chest X-ray was within normal limits.