A Novel Ultrasound-guided With Needle Visualization Pericardiocentesis Via Subcostal Approach

Osman Adi (osman.adi@gmail.com)
Hospital Raja Permaisuri Bainun https://orcid.org/0000-0003-4932-8907

Nurul Shaliza Shamsudin
Hospital Raja Permaisuri Bainun, Kementerian Kesihatan Malaysia

Chan Pei Fong
Hospital Raja Permaisuri Bainun, Kementerian Kesihatan Malaysia

Muhammad Faiz Baherin
Hospital Raja Permaisuri Bainun, Kementerian Kesihatan Malaysia

Azma Haryaty Ahmad
Hospital Raja Permaisuri Bainun, Kementerian Kesihatan Malaysia

---

Case report

Keywords: Cardiac tamponade, Novel Ultrasound-guided, Needle Visualization Pericardiocentesis, Subcostal Approach

Posted Date: June 9th, 2021

DOI: https://doi.org/10.21203/rs.3.rs-593387/v1

Abstract

Cardiac tamponade is a condition when fluids or blood fill the pericardial space resulting in compression of the heart and subsequently compromising hemodynamic status of the patient. It is a potentially fatal medical or traumatic emergency that requires rapid recognition and immediate treatment. Formerly, blind or surgical techniques were used to aspirate the pericardial fluid and they were associated with plenty of risks and complications. In the recent era, medical technology development has enabled us to perform the procedure safely with the assistance of ultrasound devices. The ultrasound-guided procedure is not only proven to be effective and safe, but it also has very minimal drawbacks and complications. In the literature, there are many ultrasound-guided pericardiocentesis procedures performed with different approaches at different regions. They include subcostal, parasternal, and para-apical approaches and phased array echocardiography transducers are typically preferred for the procedures. We report a case of cardiac tamponade presented with hemodynamic compromise. Ultrasound-guided pericardiocentesis was carried out using in-plane technique with high frequency linear ultrasound transducer at the subcostal region as lifesaving procedure. This particular technique provided full visualization of needle trajectory throughout the procedure. It was successfully completed with no complications and patient's hemodynamic status improved post-procedure. This article highlights the novel use of in-plane method with high frequency linear transducer at subcostal area as a safe option for pericardiocentesis in patients with cardiac tamponade.

Introduction

Cardiac tamponade is a life-threatening clinical condition caused by rapid accumulation of pericardial fluid, resulting in impaired ventricular filling, decreased cardiac output, and hemodynamic instability [1]. Prompt recognition and urgent intervention to treat of cardiac tamponade is lifesaving.

Ultrasound-guided pericardiocentesis is currently considered the gold-standard for pericardial fluid aspiration. This technique was introduced in 1979 and has become the preferred technique for cardiac tamponade management [2]. This technique has been proven to be safe and effective and has lower risks and complications compared to blind or surgical techniques [2, 3].

Since its first introduction, ultrasound-guided pericardiocentesis procedure has been refined and shaped into better techniques with different approaches [4]. The older practice used echocardiography to diagnose pericardial effusion and locate the best site for puncture [5]. This method, known as echocardiography-assisted pericardiocentesis, does not provide continuous ultrasound visualization of needle trajectory. The newer approach is a true echocardiography-guided procedure that uses ultrasound transducer to guide the needle, allowing the clinician to avoid injury to surrounding structures [5, 6].

This is a case report of our experience with a novel subcostal in-plane ultrasound-guided pericardiocentesis using linear transducer for a patient with cardiac tamponade in the emergency department (ED).

Case Report

A 50-year-old man with underlying hypertension presented to ED with shortness of breath for 1 week. His vital signs revealed a blood pressure of 85/45 mmHg, heart rate of 120 per minute, respiratory rate of 28 per minute, temperature of 37 C, and oxygen saturation (SPO2) of 82% with oxygen 12 L/min. Physical examination revealed he was in respiratory distress and he was diaphoretic. His jugular venous pressure was not raised and his cardiorespiratory system did not reveal any significant findings. He was intubated and mechanically ventilated. Electrocardiogram showed sinus tachycardia and chest radiograph revealed cardiomegaly with right pleural effusion. Bedside point-of-care echocardiography showed hyperdynamic left ventricle with massive pericardial effusion. Right ventricular collapse was also noticed during diastole and collectively, this was suggestive of cardiac tamponade [Supplementary Video 1].

Pericardiocentesis was done by the emergency physician in-charge under ultrasound guidance using subcostal approach. A high frequency linear ultrasound transducer was placed horizontally at subcostal area with the marker pointing caudally. Using in-plane technique, the needle tip was fully visualized as it was advanced into the pericardial space. 200 ml of hemoserous fluid was aspirated and a pigtail catheter was left in-situ for continuous drainage [Figure 1, Fig. 2 and Supplementary Video 2]. Post procedure, his blood pressure improved to 130/90 mmHg, he became less tachypneic and less tachycardic with a heart rate of 100 beats per minute.

Pericardial fluid cytology revealed malignant epithelial cells exhibiting large pleomorphic nuclei. A computed tomography of his whole body showed multiple metastatic lesions at the lungs, liver, right adrenal and pelvic region with unknown source of malignancy. He was ventilated in intensive care unit for 13 days, and was referred to palliative care team upon discharged.

Discussion

This case illustrated a successful pericardiocentesis procedure using subcostal approach with real-time ultrasound guidance. The contemporary use of ultrasound has allowed pericardiocentesis to be performed at any position surrounding the pericardium [4, 5]. In this case the subcostal site was chosen because this was where the image was clearest, and the pericardial collection was largest.

Traditionally, pericardiocentesis which was performed blindly using the subxiphoid approach, the older term used interchangeably with subcostal approach, had a high complication rate of 5–20% [7, 8]. Vayre et al performed ultrasound-guided subcostal pericardiocentesis with contrast study to detect accidental cardiac puncture [9]. However, a 10% rate of right ventricular puncture was still observed because the procedure was not completely done under real-time ultrasound guidance [10].

Recently, Law et al demonstrated that this technique could still be a safe procedure. He confirmed this by using long axis in-plane approach at subcostal area for pericardiocentesis. The procedure was carried out on 14 post-operative pediatric patients and no complications were observed [11]. In adult patients, the increase of depth of surrounding tissues and structures may affect angulation of the needle and it will be

more challenging. In this case, we demonstrated that in-plane subcostal approach using high frequency linear probe safe and feasible in adult patients.

Before the era of ultrasound, subxiphoid or subcostal approach was the most widely accepted method due to its high success rate to locate anatomical landmark at Larrey's triangle [12, 9]. After the introduction of ultrasound, the practice had tremendously changed and anatomical location for pericardiocentesis varies. Para-apical is the most common site (63%), followed by subcostal (15%) and parasternal (14%) [10]. The para-apical approach is preferred because it is usually where the pericardial space is closest to the probe and the fluid accumulation is maximal [5, 13]. Osman et al. demonstrated the left parasternal with medial to lateral approach which provided excellent visualization of needle trajectory. This practice avoids injury to surrounding structures making the procedure practically free from any complications [14]. Apical approach is less commonly preferred due to the risk of left ventricular perforation and left pneumothorax [15].

Conclusion

The in-plane subcostal pericardiocentesis is a safe and simple approach that can be performed in ED for patients with cardiac tamponade. We recommend this new technique as an alternative when cardiac window for other approaches cannot be visualized.

Declarations

Authors' contribution

OA and CPF , NSS , and MFB was involved in the initial conception and drafting of the manuscript. All authors contributed to the image interpretation, writing and revision of the manuscript.

Acknowledgements

We would like to thank Ipoh Emergency Critical Care Society (IECCS) for their assistance.

Competing interests

The authors declare that they have no competing interests.

Declaration

I declare that this manuscript which depicts the clinical management of patient . Contributions from respective authors have been explicitly mentioned in the respective segment. This work has not been submitted to any other publication for publishing.

Consent for publication

Written informed consent was obtained from the patient for publication of this case report and accompanying images.

Availability of data and materials

The material are available from the corresponding author on reasonable request

Funding

Authors received no funding for this clinical trial from any institution/ individual.

References

1. Spodick DH. Acute cardiac tamponade. *N Engl J Med*. 2003;349(7):684-690. doi:10.1056/NEJMra022643
2. Tsang TS, Freeman WK, Sinak LJ, Seward JB. Echocardiographically guided pericardiocentesis: evolution and state-of-the-art technique. *Mayo Clin Proc*. 1998;73(7):647-652. doi:10.1016/S0025-6196(11)64888-X
3. Maggiolini S, Bozzano A, Russo P, et al. Echocardiography-guided pericardiocentesis with probe-mounted needle: report of 53 cases. *J Am Soc Echocardiogr*. 2001;14(8):821-824. doi:10.1067/mje.2001.114009
4. Luis SA, Kane GC, Luis CR, Oh JK, Sinak LJ. Overview of Optimal Techniques for Pericardiocentesis in Contemporary Practice. *Curr Cardiol Rep*. 2020;22(8):60. Published 2020 Jun 19. doi:10.1007/s11886-020-01324-y
5. Maggiolini S, De Carlini CC, Imazio M. Evolution of the pericardiocentesis technique. J Cardiovasc Med (Hagerstown). 2018;19(6):267-273. doi:10.2459/JCM.0000000000000649
6. Nagdev A, Mantuani D. A novel in-plane technique for ultrasound-guided pericardiocentesis. Am J Emerg Med. 2013;31(9):1424.e5-1424.e1.424E9. doi:10.1016/j.ajem.2013.05.021
7. Petri N, Ertel B, Gassenmaier T, Lengenfelder B, Bley TA, Voelker W. "Blind" pericardiocentesis: A comparison of different puncture directions. Catheter Cardiovasc Interv. 2018;92(5):E327-E332. doi:10.1002/ccd.27601
8. Tsang TSM, Enriquez-Sarano M, Freeman WK, Barnes ME, Sinak LJ, Gersh BJ, Bailey KR, Seward JB. Consecutive 1127 Therapeutic Echocardiographically Guided Pericardiocenteses: Clinical Profile, Practice Patterns, and Outcomes Spanning 21 Years. 2002; 77(5):429-436, ISSN 0025-6196. https://doi.org/10.4065/77.5.429
9. Vayre F, Lardoux H, Pezzano M, Bourdarias JP, Dubourg O. Subxiphoid pericardiocentesis guided by contrast two-dimensional echocardiography in cardiac tamponade: experience of 110 consecutive patients. Eur J Echocardiogr. 2000;1(1):66-71. doi:10.1053/euje.1999.0003
10. Tsang TS, Seward JB. Letter to the Editor. Pericardiocentesis under echocardiographic guidance. Eur J Echocardiogr 2001; 2:68–69. doi:10.1053/euje.2001.0068.

11. Law MA, Borasino S, Kalra Y, Alten JA. Novel, Long-axis In-plane Ultrasound-Guided Pericardiocentesis for Postoperative Pericardial Effusion Drainage. Pediatr Cardiol. 2016;37(7):1328-1333. doi:10.1007/s00246-016-1438-z
12. Turfan M, Murat H, Akyet A, Duran M, Ornek E, Demircelik MB. Pericardiocentesis and Contemporary Practice. Eur J Gen Med 2013; 10 (Suppl 1): 6-9. https://www.ejgm.co.uk/download/pericardicentesis-and-contemporary-practice-7087.pdf
13. Tirado A, Wu T, Noble VE, et al. Ultrasound-guided procedures in the emergency department-diagnostic and therapeutic asset [published correction appears in Emerg Med Clin North Am. 2013 Aug;31(3):895. Cohen, Stephanie G [added]]. Emerg Med Clin North Am. 2013;31(1):117-149
14. Osman A, Wan Chuan T, Ab Rahman J, Via G, Tavazzi G. Ultrasound-guided pericardiocentesis: a novel parasternal approach. Eur J Emerg Med. 2018;25(5):322-327. doi:10.1097/MEJ.0000000000000471
15. Ozer HO, Davutoğlu V, Cakici M, et al. Ekokardiyografi rehberliğinde apikal yaklaşimla perikardiyosentez [Echocardiography-guided pericardiocentesis with the apical approach]. Turk Kardiyol Dern Ars. 2009;37(3):177-181. PMID: 19553741

Figures

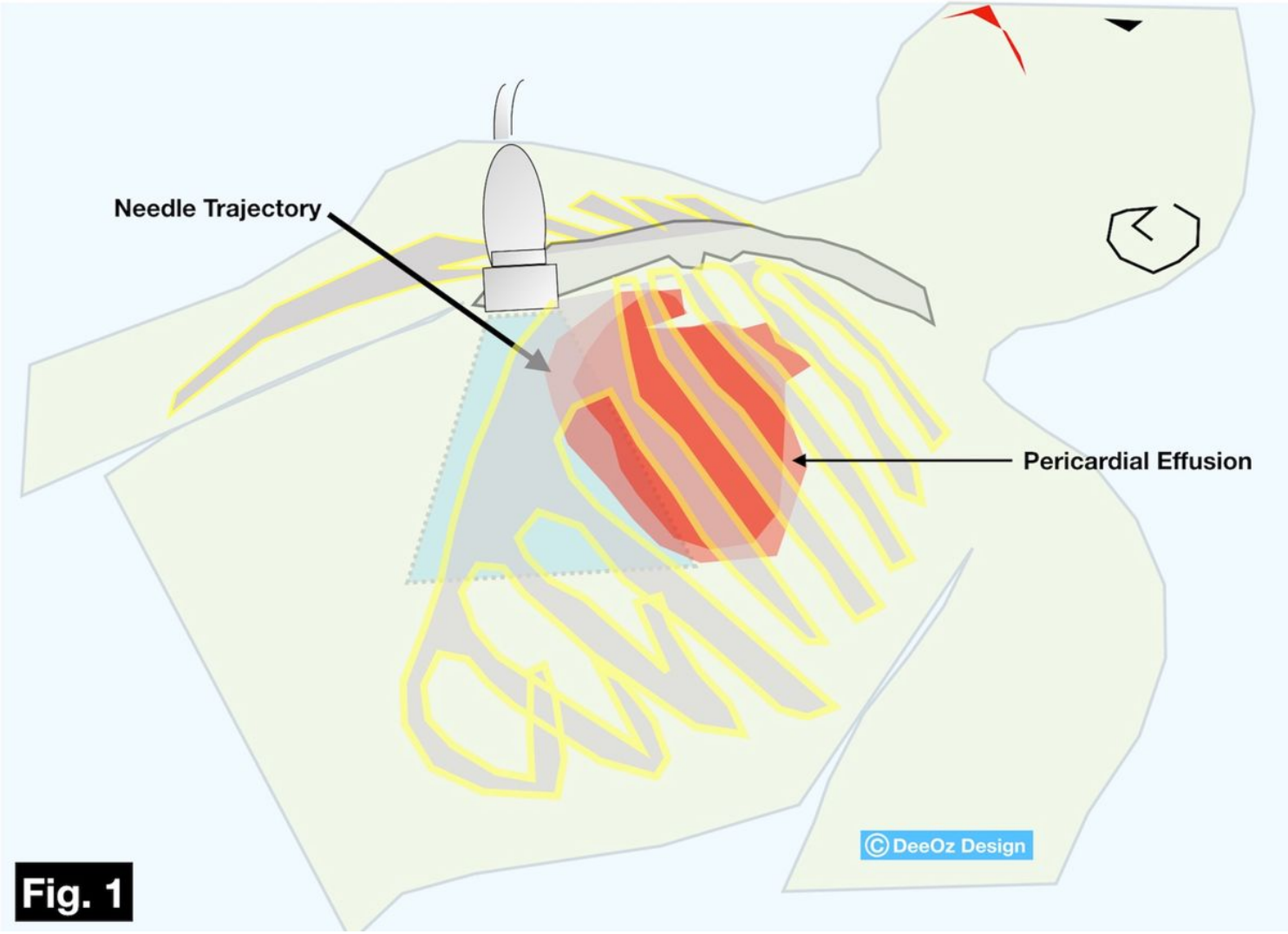

Figure 1

A high frequency linear ultrasound transducer was placed horizontally at subcostal area with the marker pointing caudally

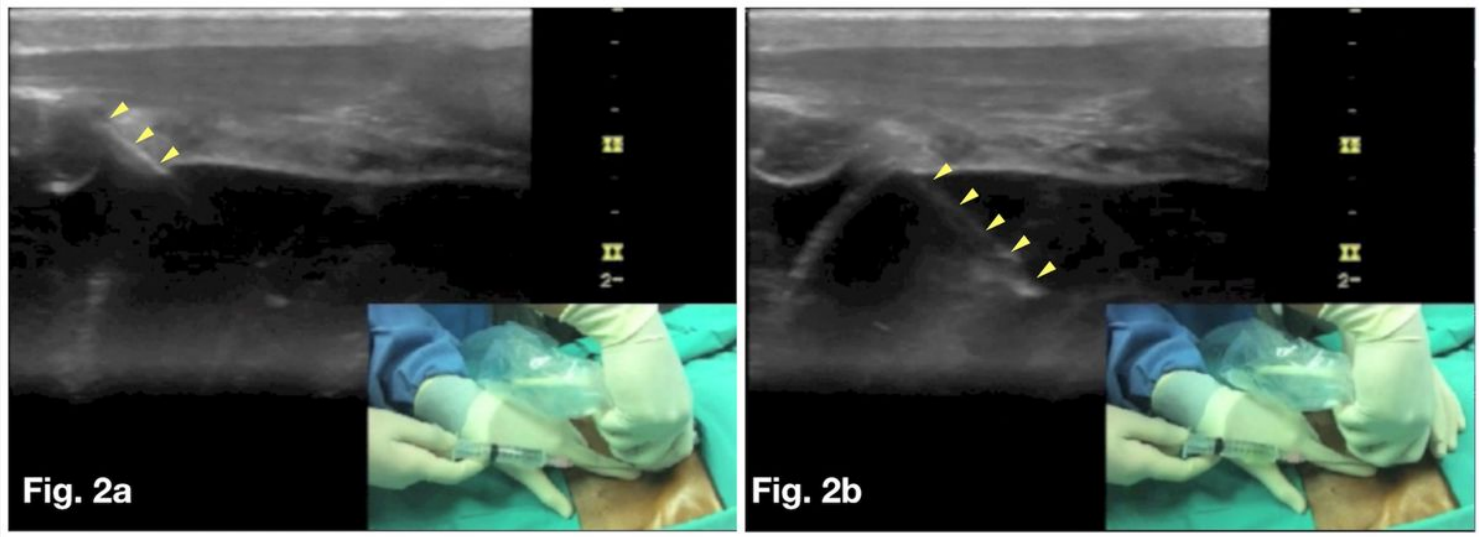

Figure 2

Using in-plane technique, the needle tip was fully visualized as it was advanced into the pericardial space. 200 ml of hemoserous fluid was aspirated and a pigtail catheter was left in-situ for continuous drainage

Supplementary Files

This is a list of supplementary files associated with this preprint. Click to download.

- SuppVideo1.mov
- SuppVideo2.mov