Clinical study of ultrasound-guided microwave ablation in the treatment of non-lactating mastitis

Ying Zhou
Hebei Medical University College of Traditional Chinese Medicine

Shu-Rong Wang
Hebei Medical University College of Traditional Chinese Medicine

Dong Xu (xudong@zjcc.org.cn)
Zhejiang Cancer Hospital

Research

Keywords: Ultrasound-guided microwave ablation, non-lactating mastitis, plasma cell mastitis, granulomatous mastitis

Posted Date: June 9th, 2021

DOI: https://doi.org/10.21203/rs.3.rs-596923/v1

Abstract

Background

To investigate the clinical value of ultrasound-guided microwave ablation for non-lactating mastitis.

Methods

A total of 53 patients who were confirmed with non-lactating mastitis and all underwent ultrasound-guided microwave ablation from January 2019 to January 2020 were enrolled, including 31 patients with Plasma Cell Mastitis (PCM) and 22 patients with Granulomatous Mastitis (GM). There were a total of 58 lesions, including 32 plasma cell mastitis lesions and 26 granulomatous mastitis lesions. Hospital stay, duration of postoperative lesion reduction, effective rate and recurrence were recorded to observe the clinical efficacy.

Results

In this study, the total effective rate of ultrasound-guided microwave ablation was 98.1 % (52/53). The recurrence rate after 12 months of follow-up was 1.9 %. The average length of hospital stay was (6.3 ± 2.4) days. After treatment, 38 cases were excellent in breast appearance evaluation, and 14 cases were good and accounted for 98.1%. Patients with abnormal preoperative white blood cell results had lower postoperative breast appearance scoring, and there was significant difference in the effect of postoperative breast appearance between normal and abnormal white blood cells ($P < 0.05$). The average time of lesion volume reduction to 50 % was (28.4 ± 12.7) days, and reduction to 100% was (75.8 ± 31.7) days. There was significant difference in the time of lesion volume reduction between different clinical stages ($P < 0.05$).

Conclusion

Ultrasound-guided microwave ablation has a high efficiency in the treatment of non-lactating mastitis and the lesion is completely absorbed within a short time, which provides a new idea and better treatment for non-lactating mastitis.

Background

Non-lactating mastitis mainly consists of Plasma Cell Mastitis (PCM) and Granulomatous Mastitis (GM).

Plasma Cell Mastitis (PCM) is a non-lactating mastitis that occurs in 30 to 40 year-old female. The incidence of PCM accounts for 4%-5% of benign breast diseases [1] according to previous literature, while the incidence has increased and it is prone to younger female[2] for recent years. The cause of PCM has

not been clear so far, and the pathology shows a large number of plasma cell invasion in the lesion area. GM is mastitis with lobule and pathologically-featured in granuloma, and the average age of onset is 30 years old. In 1972, Kessler [1] first found that it was easily confused with plasma cell mastitis.

The treatment of PCM and GM has been seen as a major problem in surgery all the time, and the main treatment methods are conservative treatment and traditional surgical treatment. Conservative treatment includes antibiotics[3], anti-tuberculosis drugs[4], immunosuppressants [5], endocrine therapy [6] and traditional Chinese medicine treatment. However, the effect of conservative treatment is slow and the therapeutic effects are different. Up to now, most scholars at home and abroad still advocate surgical resection [7] which mainly includes mass resection [8], incision and expansion surgery, incision and drainage [9] and so on. Some scholars believed that the incision and drainage method should not be adopted on patients in abscess stage, because it may form a prolonged unhealed sinus [10], and then the surgical operation was improved. Patients in abscess stage were treated with supersegmental resection and primary suture [11]. Moreover, suture scar after surgery would affect patients' appearance so as to increase their physical and mental wound, while surgical complications and postoperative recurrence rate might be still high. As a consequence, new methods for the treatment of PCM and GM have been looking for actively.

Materials And Methods

General information

This study was approved by medical ethics review, and patients were fully informed and signed informed consent. A total of 53 patients who were confirmed with plasma cell mastitis or granulomatous mastitis by puncture pathology before operation in this study in Hebei Chinese Medicine Hospital and Zhejiang Cancer Hospital from January 2019 to January 2020 were enrolled.

Case selection and criteria

Inclusion criteria : □non-lactating mastitis patients with breast masses associated with clinical manifestations such as redness and pain or prolonged refractory after rupture; □ Patients confirmed with plasma cell mastitis or granulomatous mastitis by preoperative coarse needle biopsy; □patients with no severe underlying diseases (e. g., hypertension, coronary heart disease, etc.), able to tolerate surgical; □Patients who voluntarily participated after full notification.

Exclusion criteria: □Patients with breast cancer, breast nodules and other diseases; □Patients with lactation mastitis; □Patients with severe coagulation disorder and/or important organ dysfunction; □Patients with surgery and / or anesthesia intolerance.

Treatment and methods

All patients underwent ultrasound-guided microwave ablation. Ultrasound instrument model: EPIQ 7, probe model: L2-5 (Philips Ultrasound Co., Ltd., WAshington, USA). Microwave Instrument model: KY-2000, ablation needle model: KY-2450A-1 (Nanjing Kangyou Medical Equipment Co., Ltd., Nanjing, China).

Ablation process:

Posture and location

Patients were taken in supine position with ECG monitoring started. The size, shape, internal echo, blood flow signal and number of lesions were detected by ultrasound to be classified, recorded and marked in detail.

Anesthesia and disinfection: disinfection and spreadsheet, intravenous anasthesia + 1% lidocaine local anesthesia.

Treatment procedure

Under ultrasound-guided monitoring, the lesions were isolated from skin and muscular layer by saline infusion.The pus was extracted, and saline and ornidazole injection were performed, and then a microwave ablation needle a power of 35 W was placed into the lesion. The ablation range included almost 3 mm around the lesion. Heterogeneous echo changes on lesions after ablation occurred under two-dimensional ultrasound. Some patients can extrude tofu-like substances through the ablation needle and sinus orifice after ablation. Residual or bleeding was checked. The above operation was completed by the chief physician with more than 10 years of ultrasound intervention experience.

Observation indexes

Hospital stay (days), the total effective rate of 3months after surgery, the recurrence rate within 12 months of follow-up, the evaluation of breast shape effect and the time for lesion volume reduction to 50 % and 100 % (lesions absorbed completely).

Evaluation criteria

The patients were followed up for 12 months after treatment, and the hospital stay was recorded. The total effective rate of treatment was evaluated by color Doppler ultrasound and breast specialist examination at 3 months after operation. The breast appearance was evaluated according to Harris [12] standard. The time for lesion volume reduction to 50 % and 100 % (complete absorption) was recorded in detail.

Harris evaluation

Excellent: The size and appearance of the breast after treatment are almost the same as the breast the other side .

Good: Breast retraction and/or skin changes less than 1/4 of the original one.

Acceptable: Breast retraction and/or skin changes involved 1/2 – 1/4 of the original one.

Poor : Breast deformity involved more than 1/2 of the original one.

Therapeutic effect evaluation criteria [13] :

Recovery: Mass and effusion disappeared, fistula healed.

Improvement: Masses improved, fluid leakage reduced, other red, swelling and other clinical symptoms improved slightly.

Invalidity: The mass worsened and the effusion increased.

The total effective rate of treatment = (recovery cases + improvement cases) / total number of cases×100%.

Staging criteria[14]:

Mass stage: breast mass with hard texture, irregular shape and unclear boundary; the breast with general activity, pain, not red or slightly red surface skin; local skin with slightly higher temperature; no systemic fever, few with axillary lymph node enlargement.

Abscess stage: the mass gradually increase, the redness, swelling, heat and pain are all aggravated, which might involve multiple quadrants; there is a sense of fluctuation when pressing it; there is pus aspiration after puncture; systemic symptoms such as fever, and swollen lymph nodes under the arm.

Sinus stage: Breast abscess is mature and ulcerated to produce pus, or ,the pus doesn't come out smoothly after incision and drainage, and the wound does not close for a long time to heal, forming sinus tract or local stiffness.

Statistical Methods

The data was collected and recorded and input in Excel. SPSS 23.0(IBM Corp. Released 2015. IBM SPSS Statistics for Windows, Version 23.0 IBM Corp., Armonk, NY, USA) software was used for statistical analysis. Measurement data expressed as $x \pm s$, using t test, rank sum test, categorical count data expressed as rate (%), using$\chi 2$ test. Grade data were tested by nonparametric test. $P < 0.05$ for significant difference, $P > 0.05$ for no significant difference.

Results

In this study, a total of 53 cases were confirmed to be PCM or GM by puncture pathology, among which there were 31 PCM patients and 22 GM patients. There were 43 unilateral cases which included 22 left breast cases and 21 right breast case and 5 cases of bilateral breast symptom, all of which were non-

synchronous. In this study, there were no patients with bilateral breast disease at the same time. There were 58 lesions, including 50 cases of single lesion, 1 case of double lesions, and 2 cases of three lesions. According to the staging criteria, the patients were divided into mass stage with 18 cases (10 cases of PCM, 8 cases of GM), abscess stage with 27 cases (17 cases of PCM, 10 cases of GM), sinus stage with 8 cases(4 cases of PCM, 4 cases of GM). There were 45 cases of papillary deformity (nipple retraction, flat nipple), including 28 cases of PCM, 17 cases of GM. Forty-eight cases had history of birth and lactation (29 cases of PCM, 19 cases of GM). All the patients were female, aged between 20 and 42 years old (with mean age of 31.4 ± 5.2 years old). Laboratory result showed that white blood cell abnormalities in 10 cases (18.9%), erythrocyte sedimentation rate abnormalities in 40 cases (75.5%), rheumatoid factor abnormalities in 3 cases (5.7%) and C-reactive protein abnormalities in 28 cases (52.8%). The success rate of operation was 100 %. After liquefaction of necrotic tissue in mass stage and abscess stage, some of them were drained by ablation needle or puncture needle aspiration, and some of them were absorbed and metabolized by themselves.The preoperative and postoperative comparison was shown in Fig. 1and Fig. 2.

Postoperative recurrence and treatment efficacy.

All patients were followed up for more than one year, and only one case was found recurrence after 12 months of follow-up, that who was a PCM abscess patient. The total recurrence rate was 1.9 %.

After 3 months of follow-up, the total effective rate(recovery + improvement) was 98.1% (52/53), of which the total effective rate of PCM was 96.8 % (30/31), and that of GM was 100% (22/22). There was no significant difference between the two ($p > 0.05$).There was no significant difference in the effective rate among the three clinical periods ($p > 0.05$). (Table 1)

Table 1
Effective rate of treatment

Stage	**Mass**		**Abscess**		**Sinus**	
Cases	PCM	GM	PCM	GM	PCM	GM
Recovery	10	8	14	7	3	4
Validity	0	0	2	3	1	0
Ineffective	0	0	1	0	0	0
Total effective rate		100%		96.3%		100%
χ^2		4.589				
P		0.101				

Hospital stay

The average hospital stay was (6.3 ± 2.4) days, PCM (6.2 ± 1.8) days and GM (6.5 ± 3.2) days. The tumor stage was (6.2 ± 3.6) days, the abscess stage (6.3 ± 1.7) days, and the sinus stage (6.4 ± 1.4) days, with no statistically significant difference (P > 0.05).

Clinical stage and age distribution

The age of patients ranged from 20 to 42 years old, with the mean age of (31.4 ± 5.2) years old, and the median age was 31 years old. There was no significant correlation between age and clinical stage of the disease (P > 0.05). (Table 2)

Table 2 Clinical stage and age distribution

Clinical stage	cases	average age	*t value*	*P value*
Mass	18	31.3±4.7	0.71	0.496
Abscess	27	30.9±5.5		
Sinus	8	33.4±5.0		

Correlation between postoperative breast appearance and white blood cell abnormalities:

According to Harris evaluation system, 38 cases (71.7%) were excellent, 14 cases (26.4%) were good, and 1 case (1.9%) was acceptable. The results of rank sum test showed that the Harris score of patients with abnormal white blood cell results before operation was lower, and the normal and abnormal white blood cells were statistically significant in the postoperative breast shape effect (P < 0.05). (Table 3).

Table 3
Correlation between postoperative breast shape and white blood cell abnormalities

White blood cell	Excellent	Good	Acceptable	Poor	*Z*	*P*
Normal	34	10	0	0	-2.118	0.034
Abnormal	4	4	1	0		

The time for postoperative lesion volume reduction

The mean time for lesion volume reduction to 50% was (7-90days) days (mean days:28.4 ± 12.7), PCM with (29.2 ± 17.9) days and GM with (27.3 ± 14.5) days. The average tumor stage was (20.1 ± 10.1)

days, the average abscess stage was (32.4 ± 13.3) days, and the average sinus stage was (33.6 ± 6.4) days. The time for lesion volume reduction to 100 % (i.e. complete disappearance) was 20–190 days, with an average of (75.8 ± 31.7) days, PCM (76.6 ± 41.1) days and GM (74.7 ± 40.6) days. The average tumor stage was (50.7 ± 25.5) days, the average abscess stage was (85.6 ± 32.7) days, and the average sinus stage was (99.5 ± 15.2) days.

There was no significant difference in the time for lesion reduction between PCM and GM ($P > 0.05$). The time of lesion volume reduction in mass stage was significantly shorter than that in abscess stage and sinus stage, and the difference was statistically significant ($P < 0.05$). (Fig. 3 and Fig. 4).

Discussion

Plasma cell mastitis and granulomatous mastitis are both benign inflammatory diseases of breast, while their etiology, pathogenesis, clinical manifestations, ultrasonic manifestations and clinical manifestations at the beginning of the disease are definitely different. When the disease develops to the next stage, it is difficult to distinguish between PCM and GM in clinical manifestations and ultrasound imaging. In the follow-up treatment, anti-inflammatory, the main methods include swelling, drainage and surgical resection. Due to individual differences, the sensitivity to treatment is different, as well as the treatment cycle. In clinical practice, conservative treatment includes antibiotics, anti-tuberculosis, immunosuppression, endocrine and traditional Chinese medicine. However, conservative treatment has slow and different therapeutic effects. Therefore, surgical resection is still the main treatment for PCM and GM. However, each method for treatment owns its limitations. Antibiotic treatment is usually ineffective [15, 16], and anti-tuberculosis treatment and traditional Chinese medicine treatment have long course of treatment and slow effect [17]. Hormone therapy has a rapid effect, but the recurrence rate is high, and the recurrence area is heavier than that of the primary lesion after withdrawal. A recent report in Germany [18] introduced 13 patients diagnosed as GM treated with prednisone at a high dose of 1 mg/kg/day. The duration of application was between 2 and 6 months, and the recurrence rate was 15%. In the analysis of Lei et al.[19], the reported recurrence rate of oral steroid therapy was 20%; The surgical treatment is relatively thorough. The recurrence rate of periareolar inflammation can reach 79% without excision of the mammary duct by incision and drainage alone. After segmental excision of the mammary duct, the recurrence rate decreases to 28% [20]. However, it is not easy to be accepted by the majority of female patients because of its large damage, long time of postoperative liquefaction dressing change, partial loss of gland function, and beautiful incision [21].

In recent years, ultrasound-guided microwave ablation for benign breast nodules [22–24] and malignant breast tumors [25, 26] has been more in-depth and achieved good therapeutic effect, but the treatment of non-lactating mastitis has not been reported. In this study, 53 patients with non-lactating mastitis were treated with ultrasound-guided microwave ablation, and the therapeutic effect was observed.

The results of this study showed that non-lactating mastitis was more common in young women aged 31–35 with lactation history, and the incidence tended to be younger. The average hospitalization time of

patients was (6.3 ± 2.4) days, and that of traditional surgery was (15.87 ± 2.42) days [12]. The course of acute phase and stress response after microwave ablation was short, showing small trauma and stability of postoperative course, saving medical cost and time of patient's family escort. After 3 months of follow-up, the total effective rate was 98.1 % (52/53), and all patients were followed up for more than one year. Only one case of recurrence was found after 12 months of follow-up. This case was a PCM abscess patient, and the recurrence rate was 1.9% (1/53). According to literature [27], the highest effective rate was 94.44 % (34/36) and the lowest recurrence rate was 5.66 % (2/36) in traditional surgical methods, such as segmental resection.Compared with traditional surgery, ultrasound-guided microwave ablation has higher efficiency and lower recurrence rate. The patient with recurrence was followed up for 3 months after operation, and the treatment effect was not good. The recurrence of the same lesion was 4 months after operation, which was characterized by redness, swelling, pain and ulceration in the operation area, and bean curd-like pus. Therefore, ' segmental resection ' was performed. After operation, the suture mouth was not cured for a long time, and repeated redness and abscess around the incision. One year later, the same side of the recurrence, because of the small area, and because of the past history of recurrence, the patient's family requires conservative oral Chinese medicine treatment, is still in treatment. The reason for the patient's previous history of mania was analyzed, and the patient was given " haloperidol tablets " for 3 years. Considering that this special case was related to its underlying diseases and medication, and the patient's condition was unclear due to mental illness, so it was impossible to detect the change of the condition in time and delay the best treatment opportunity, so the treatment effect was poor. According to the Harris score results, 38 cases were excellent and 14 cases were good, accounting for 98.1 %. The Harris score of patients with abnormal white blood cell results before operation was lower. However, due to the small number of specimens, the number of patients with normal white blood cell results was significantly different from that of patients with abnormal white blood cell results. Therefore, it cannot be explained that Harris score was absolutely related to abnormal white blood cell. In clinical practice should also find better laboratory observation indicators to further assess whether there is a direct correlation with postoperative breast appearance. The excellent rate of patients in mass stage and abscess stage was higher than that in sinus stage. The reason was that the skin ulceration and scar formation in sinus stage, and the appearance of breast was affected during the recovery process, so the score was lower. In terms of the time used for postoperative lesion volume reduction, the tumor stage was shorter than the abscess stage and sinus stage, and the cure time was shorter no matter the time used for 50% reduction or 100% reduction. Therefore, it is further confirmed that ultrasound-guided microwave ablation is more effective in the treatment of non-lactating mastitis in mass stage.

In summary, ultrasound-guided microwave ablation has a high efficiency in the treatment of non-lactating mastitis. At the same time, it can greatly shorten the hospital stay and treatment time of patients, and can achieve better cosmetic results. It is especially suitable for patients with mass stage of non-lactating mastitis, which is worthy of extensive promotion and application in clinic.

However, the sample size observed in this study is small and the follow-up time is short. There is no theory of microwave ablation for mastitis based on pathology and physiology. Therefore, in order to better guide clinical practice,it is necessary to expand the sample size, find better observation and evaluation indicators, pay attention to the observation of long-term efficacy and recurrence rate, and improve the pathophysiology of non-lactating mastitis by microwave ablation.

Conclusion

Our results suggested that ultrasound-guided microwave ablation has a high efficiency in the treatment of non-lactating mastitis and the lesion is completely absorbed within a short time, which provides a new idea and better treatment for non-lactating mastitis.

Abbreviations

Plasma Cell Mastitis
PCM
Granulomatous Mastitis
GM

Declarations

Ethics declarations

Ethics approval and consent to participation

The study has been approved by Hebei Provincial Hospital of Traditional Chinese Medicine and Zhejiang Provincial Cancer Hospital. Informed consent was obtained from all participants.

Consent for publication

Informed consent for publication was obtained from all participants.

Availability of data and materials

All data generated or analyzed during this study are included in this published review.

Competing interests

All authors declare no conflicts of interest.

Funding

This study is funded by National Natural Science Foundation of China(No.82071946) and Zhejiang Provincial Natural Science Foundation of China(No.LSD19H180001).

Authors’contributions

Ying Zhou searched the relevant literature and wrote the manuscript. Dong Xu and Shu-Rong Wang conceptualized the article structure and revised the manuscript. All authors read and approved the final manuscript.

Acknowledgement

Not applicable.

References

[1] KESS LER E WOO LLOCH Y.Granulom atous mastitis a lesionc linicallys imulating carcinoma J. AmJ C lin Pathol 1972 58 642-643, https://doi.org/10.1093/ajcp/58.6.642.

[2] Qinyan Wang. Observation on the effect of surgery combined with Shengyang Yiwei Decoction and Yanghe Decoction in the treatment of plasma cell mastitis J Henan Journal of Surgery 2018 24(3) : 74, https://doi.org/10.16193/j.cnki.hnwk.2018.03.042 .(Chinese)

[3] Qi Wang.Pay attention to the diagnosis, treatment and research of non-lactating mastitis [J/CD]. Chinese Journal of Breast Disease(Electronic Edition), 2013, 7(3): 154-156, https://doi.org/10. 3877 /cma. j. issn. 1674 0807. 2013. 03. 001.(Chinese)

[4] Bolin Zhu, Pengfei Li, Pengbin Zhang. Progress in the diagnosis and treatment of plasma cell mastitis. [J] Zhejiang Medical Journal, 2019, 41(5): 497,https://doi.org/10.12056/ j.issn.1006-2785.2019.41.5.2017- 2918. (Chinese)

[5] Omranipour R, Mohammadi SF, Samimi P. Idiopathic granulomatous lobular mastitis-report of 43 cases from iran; introducing a prelimi-nary clinical practice guideline [J] . Breast Care (Basel), 2013, 8(6):439-443, https://doi.org/10.1159/000357320.

[6] Lu Chen. Application of glucocorticoid and surgical treatment in patients with granulomatous mastitis[J]. Journal of Guangxi Medical University. 2020,37(06):1164-1168,https://doi.org/10.16190/j.cnki.45-1211/r.2020.06.031. (Chinese)

[7] Bani-Hani KE Yaghan RJ Matalka et al Idiopathic granu-lomatousmastitis: time to avoid unnecessary mastectomies J Breast 2004 10(4) : 318-322,https://doi.org/10.1111/j.1075-122X.2004.21336.x.

[8] Qingxia Yang, Biao Wu. Progress in diagnosis and treatment of plasma cell mastitis [J]. Chinese Journal of Breast Disease(Electronic Edition), 2015,9(2): 115-118, https://doi.org/10. 3877 /cma. j. issn. 1674 0807. 2015. 02. 009.(Chinese)

[9] Yongling Wang，Qiufeng Zhao et.al. Clinical study of MRI location classification and surgical plan selection for plasma cell mastitis [J]. Chinese Imaging Journal of Integrated Traditional and Western Medicine，2015，13，6): 598-600, https://doi.org/10.3969/j.issn.1672-0512.2015.06.003.(Chinese)

[10]Yajun Gao,Xiangjun Ma, Jie Wang, et al. Non-surgical treatment of abscess, sinus and fistula plasma cell mastitis [J/ CD]. Chinese Journal of Breast Disease(Electronic Edition), 2013, 7(5): 379-380, https://doi.org/10. 3877 /cma. j. issn. 1674-0807. 2013. 05. 017.(Chinese)

[11] Xiaohong Zheng,Huiling Huang, Shaobo Zhang. Analysis of curative effect of supersegmentectomy combined with primary suture in the treatment of abscess plasma cell mastitis[J].Chinese Journal of Current Advances in General Surgery. 2018,21(04): 302-304, https://doi.org/10.3969/j.issn.1009-9905.2018.04.013.(Chinese)

[12] Zhiying Tang, Xiaohong Wang.Surgical treatment of plasma cell mastitis[J]. Zhejiang Journal of Traumatic Surgery. 2019,24(04) : 806-807, https://doi.org/10.3969/j.issn.1009-7147.2019.04.077. (Chinese)

[13] Yu Zeng，Hao Huang. Combined treatment of plasma cell mastitis with Mammotome,tamoxifen and dexamethasone[J].Journal of Mudanjiang Medical University. 2020,41(02):107-109， https://doi.org/10.13799/j.cnki.mdjyxyxb.2020.02.025.(Chinese)

[14] Jinzhou Zheng, Sheng Liu, Xiqiu Zhou et al.Clinical Experience of Staged Comprehensive Treatment for Granulomatous Mastitis[J]. Journal of Liaoning University of Traditional ChineseMedicine. 2019,21(11),https://doi.org/10.13194/j.issn.1673-842x.2019.11.043.(Chinese)

[15]Elzahaby IA, Khater A, Fathi A, et al: Etiologic revela-tion and outcome of the surgical management of idio-pathic granulomatous mastitis; an Egyptian centre ex-perience. Breast Disease 2016;36:115–122,https://doi.org/10.5812/ircmj.33982.

[16] Bashir MU, Ramcharan A, Alothman SB, et al: The enigma of granulomatous mastitis: a series. Breast Dis 2017;37:17–20,https://doi.org/10.3233/BD-160261.

[17] Lamy PJ，Roques S，Viglianti C，et al， HE4，a novel marker for epithelial ovarian cancer: evaluation of analytical perfomances [J]， Ann Biol Clin (Paris) ，2010,68(3) : 325-329,https://doi.org/10.1684/abc.2010.0435.

[18] Keller K, Meisel C, Petzold A, Wimberger P: Granulo-matöse Mastitis– möglicher diagnostischer und thera-peutischer Ablauf anhand von Fallbeispielen. Senolo-gie 2018;15:e23, https://doi.org/10.1055/s-0038-1651735.

[19] Lei X, Chen K, Zhu L, et al: Treatments for idiopathic granulomatous mastitis: systematic review and meta-analysis. Breastfeed Med 2017;12: 415–421,https://doi.org/10.1089/bfm.2017.0030.

[20] V ersluijs-Ossewaarde FN, Roumen RM, Goris RJ. Sub-areolar breast abscesses: characteristics and results of surgical treatment. Breast J 2005;11:179–82,https://doi.org/10.1111/j.1075-122X.2005.21524.x.

[21] Qi Yu，Gangle Wang. Study on clinical diagnosis and treatment of non-lactating mastitis [L]. Journal of Clinical Surgery，2019, 27(3):201-203, https://doi.org/10.3969/j.issn.1005-6483.2019.03.007.(Chinese)

[22] Han Wu, Baohua Chen, Ping Liang, et al. Observation on the effect of ultrasound guided percutaneous microwave ablation on benign breast nodules [J].Academic Journal of Chinese PLA Medical School. 2017,38(10). 917-921+934, https://doi.org/10.3969/j.issn.2095-5227.2017.10.004. (Chinese)

[23] Nan Zhou, Liyuan Qian.Current status and progress of microwave ablation therapy for benign breast lesions [J]. Chinese Journal of Minimally Invasive Surgery. 2020, 20(04): 369-372, https://doi.org/10.3969 /j.issn.1009，6604.2020.04.020.(Chinese)

[24] Yang Li, Song Zhao, Liang Ji, et al. Comparison of ultrasound-guided microwave ablation and traditional open surgery for multiple benign breast nodules [J]. Chinese Journal of Minimally Invasive Surgery 2018,18(10): 911-914+919, https://doi.org/ 10.3969 /j.issn.1009，6604.2018.10.014.(Chinese)

[25] Cai Zhang，Zhibiao Wang，Qiang Ding.Minimally noninvasive ablation technique for early breast cancer [J]. Chinese Journal of Surgical Oncology. 2020,12(04):329-333, https://doi.org/10.3969 /j.issn.1674，4136.2020.04.010.(Chinese)

[26] Xiaoqing Yang, Chunxin Qin, Shaojie Zhou. Microwave ablation therapy for locally advanced breast cancer [J]. Journal of Regional Anatomy and Operative Surgery.2018,27(11): 845-847, https://doi.org/10.11659 /jjssx. 07E018053.(Chinese)

[27] Zhanlin Zhu，Zhipeng Hhua.The effect of segmentectomy on non-lactating mastitis [J]. Chinese and Foreign Medical Research. 2019,17(34): 27-29, https://doi.org/10.14033/j.cnki.cfmr.2019.34.011. (Chinese)

Figures

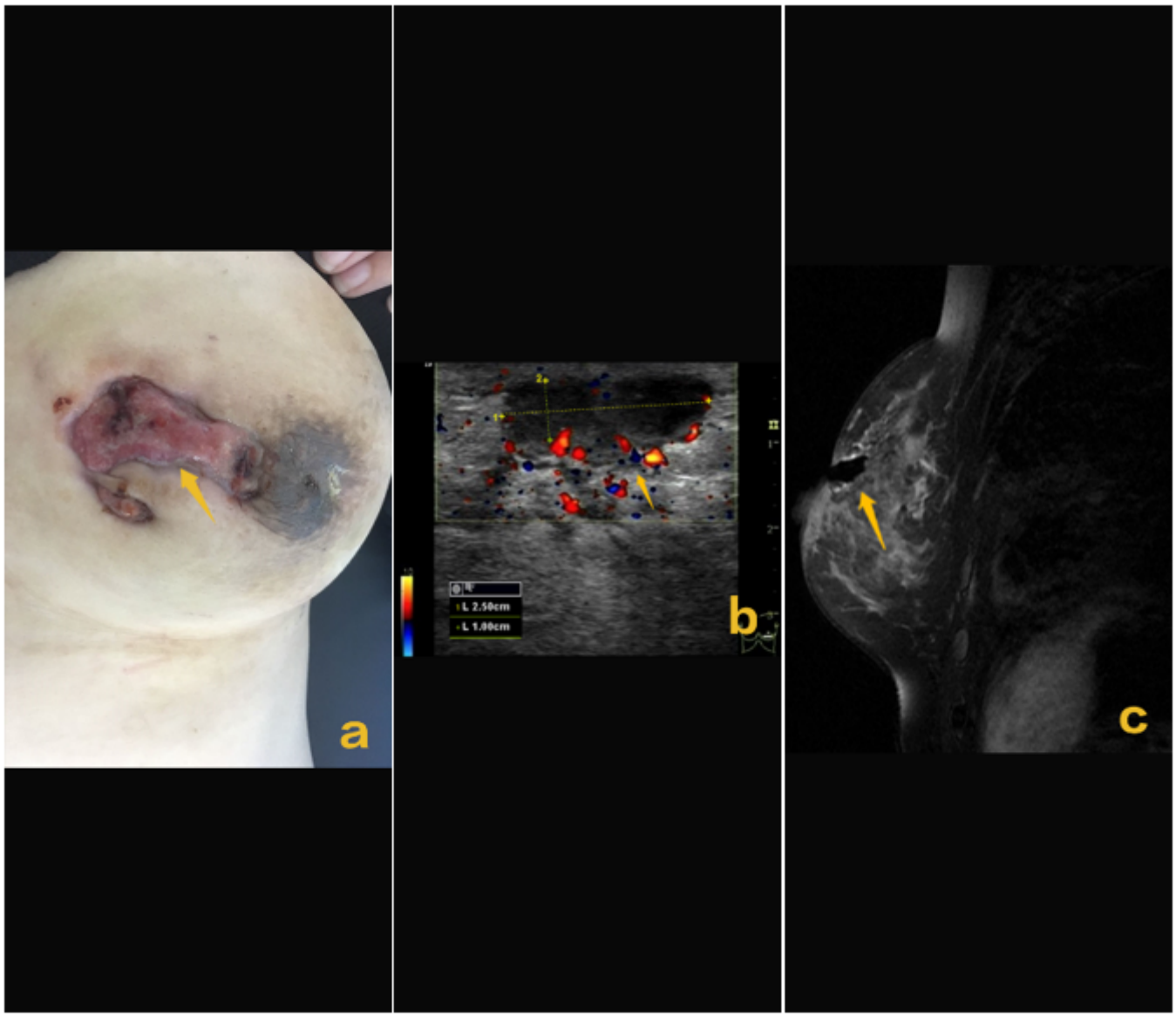

Figure 1

Preoperative GM sinus stage. Figure 1 legends:A 31-year-old woman with left breast lesion for 4 months. a: Breast appearance; b: Preoperative ultrasound, c: preoperative MRI; arrow refers to the lesion area

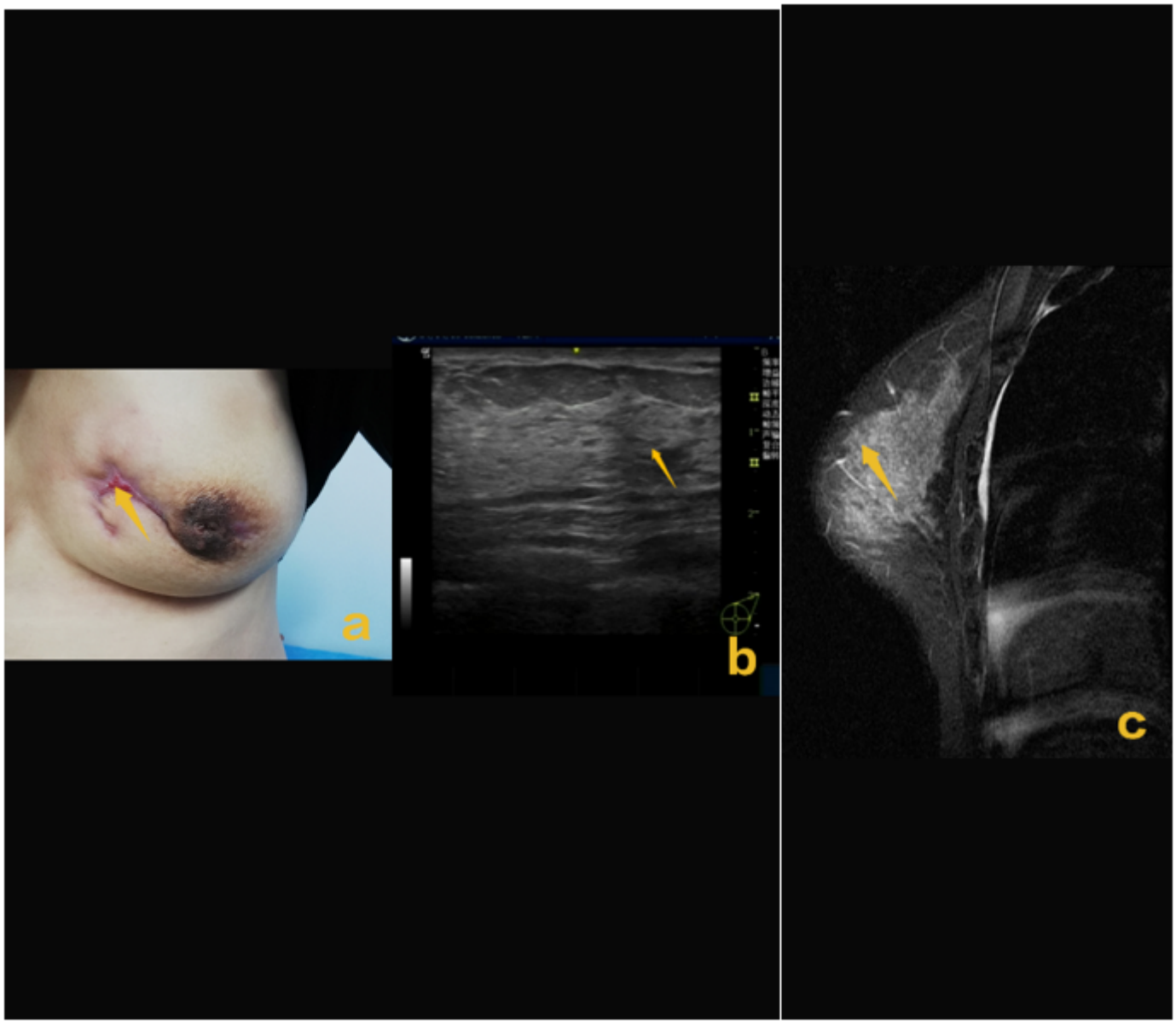

Figure 2

82 days after ablation Figure 2 legends: a Breast appearance; b Postoperative ultrasound; c postoperative MRI;arrow refers to the postoperative recovery area.

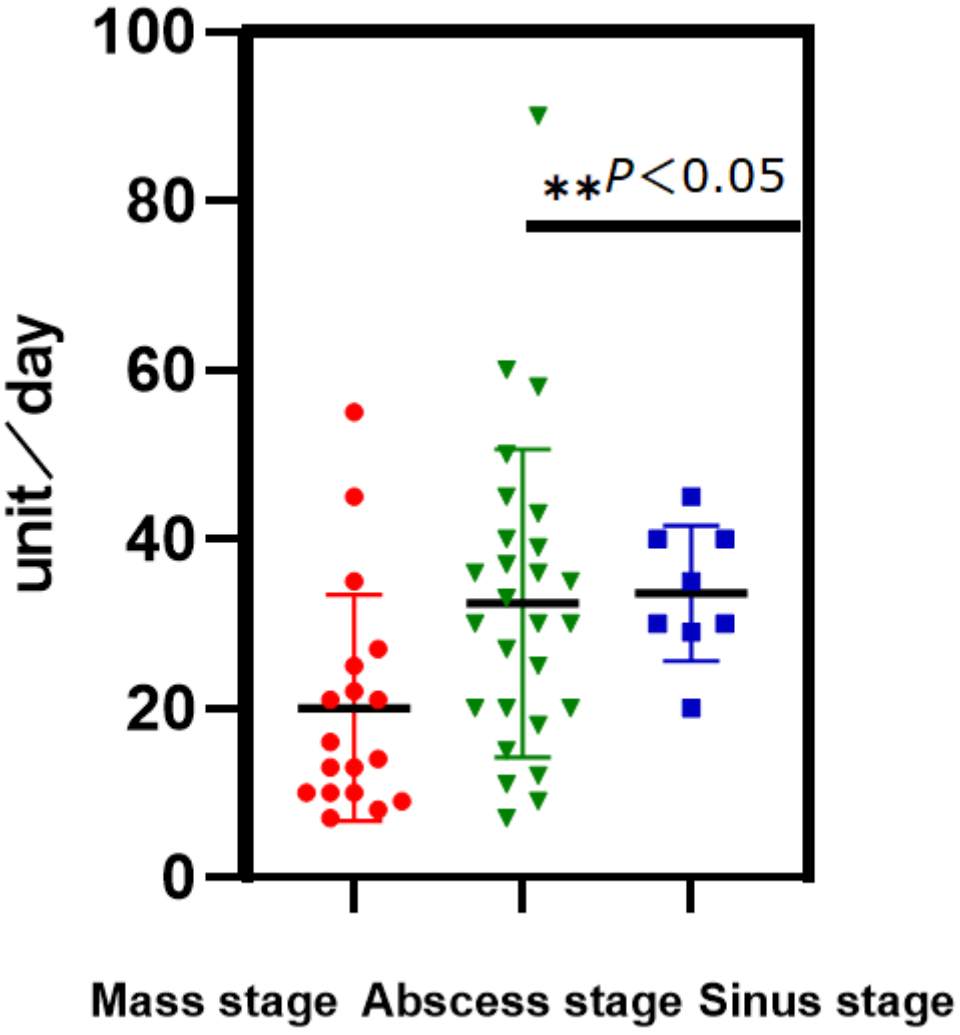

Figure 3

Time (days) of 50 % disappearance of lesion volume in three clinical stages

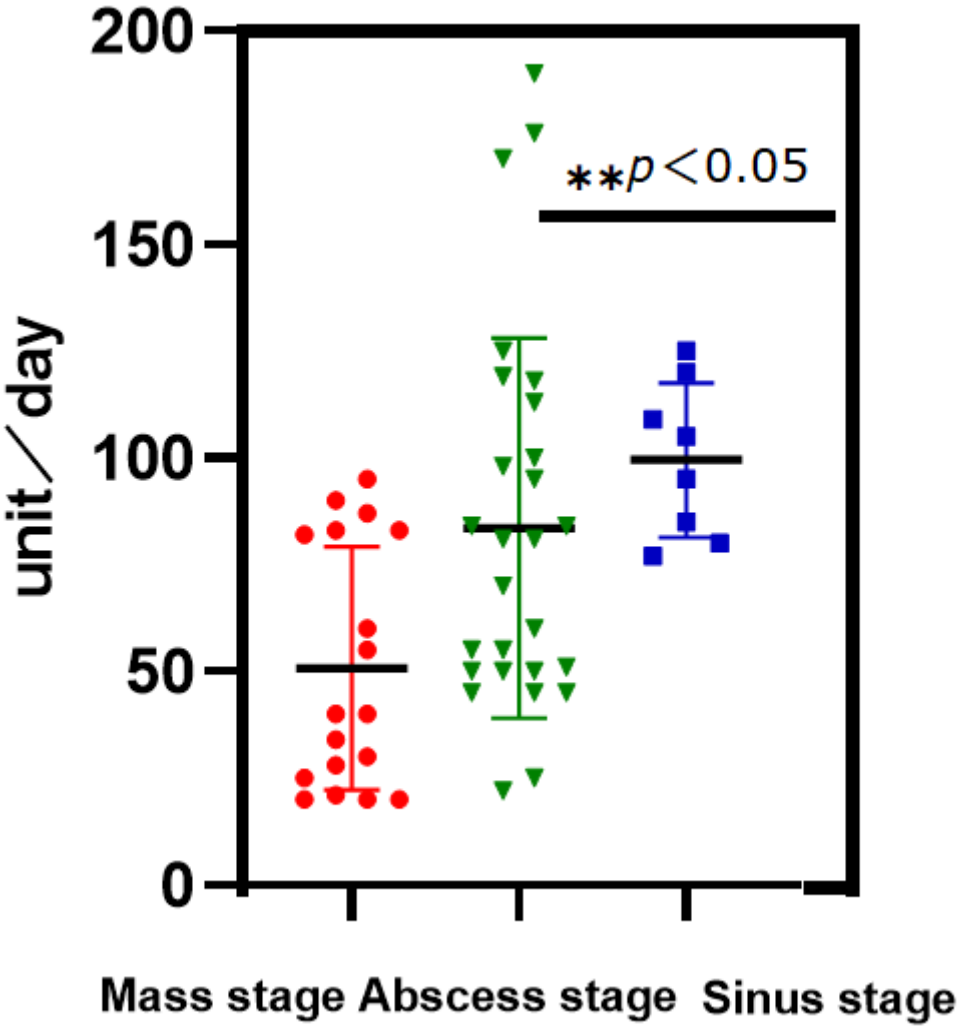

Figure 4

Time (days) for the lesion volume disappearing of 100% (lesion completely disappeared) in three clinical stages