3D Printed Template CT-Guided 125I Seed Implantation In The Treatment Of A Patient With Giant Type A Thymoma: A Case Report

Jian-Ping Liu
Central Hospital: Hopital Central https://orcid.org/0000-0002-9183-5841

Jun Zhang
Central Hospital: Hopital Central

Guang-Lin Zhang (kozihehe_2008@126.com)
Central Hospital: Hopital Central https://orcid.org/0000-0001-5894-0060

Case report

Keywords: Thymoma, 3D-printed template, 125I seed implantation

Posted Date: July 7th, 2021

DOI: https://doi.org/10.21203/rs.3.rs-598870/v1

Abstract

Background: Thymoma, as a malignant tumor with low incidence, is still recommended to be treated with surgery. For middle and advanced patients who can not be treated with surgery, it is recommended to use preoperative radiochemotherapy or chemotherapy. After the tumor regressed, the feasibility of surgical resection will be evaluated. As a new technique developed in recent years, 3D template CT-guided 125I seed implantation has achieved effective results in the treatment of a variety of solid tumors.

Case presentation: We report a case of locally advanced giant thymoma (more than 10 cm) who received 3D template CT-guided 125I seed implantation and achieved clinical complete remission.

Conclusions: It suggested that radioactive particle implantation may be a new and effective method for the nonoperative treatments of thymoma.

Background

Thymomas mostly originate from the thymus epithelial cells, and can be classified into type A, B1, B2, B3, AB and C according to the different cytological characteristics of tumor cells(1).Type A and AB are clinically considered as benign thymic tumors with low aggressiveness, while type B1, B2, B3 and C are malignant thymic tumors with high aggressiveness. The clinical incidence of thymoma is very low. According to 2016 statistics, the incidence of thymoma in China is about 0.39/100,000 people (2). Masaoka. Koga staging standard is mainly used at the staging of thymoma. For a thymoma patient, surgical resection is considered to be the main effective treatment. Studies have shown that the complete resection of the tumor has a significant impact on the local control of the tumor and the survival of the patients (3). However, for patients with advanced thymoma who cannot be surgically resected, there are many therapeutic options, including radiotherapy, chemotherapy, immunotherapy and targeted therapy. And it is no unified conclusion yet for which one to be the best.

125I radioactive seed implantation is one kind of brachytherapy, which is a new treatment method developed in modern times and different from traditional radiation therapy. It has achieved effective results in the treatment of some tumors that are difficult to resect, relapse and metastasize(4–7). In terms of the application of thymic tumor, several clinical studies have shown that 125I radioactive seed implantation has achieved a high objective remission rate for patients with postoperative recurrence (8, 9). Jian Cui et al. (10) made a statistical study of 12 thymoma patients with a bulky mass (> 10cm) in middle and late stage, and treated them with partial surgical resection combined with 125I implantation, which significantly reduced the local recurrence rate and improved the curative effect of surgical treatment. However, thymoma is relatively rare in clinical practice. For patients with initially treated and unresectable large tumor thymoma, there are few clinical reports on using 125I radioactive seed implantation alone for treatment. Therefore, we report a case of 125I seed implantation in the treatment of type A thymoma with a bulky mass.

Three-dimensional printing (TDP) has been developed in recent years, which is based on digital model files. It is an advanced technology to manufacture three-dimensional entities by using powdered metal or plastic and other adhesive materials. At present, it has been widely used in plastic surgery, orthopedics and other departments (11–13). Some researchers have applied 3D printing technology to the treatment of 125I seed implantation (14). By making a individualized guidance template from 3D printing, a reasonable injection route can be determined, and the dose of seed implantation can be precisely controlled to meet the preoperatively planned requirements. In this case, due to the huge mass of the patient, the spatial arrangement of particles may well be difficult to conform to the preoperative plan by using the traditional CT-guided puncture mode. Therefore, we combined with the 3D printing personalized template technology.

Case Presentation

A 71-year-old male was admitted to the hospital because of chest sulking, shortness of breath and fatigue in September 2017. One day before admission, his chest CT indicated a large mediastinal mass and pulmonary infection. The patient had a history of smoking and drinking for more than 40 years and was diagnosed with chronic bronchopneumonia 10 years ago. After admission his Chest CT enhancement (Fig. 1) findings : 1.A huge mass was observed in the anterior mediastinum, about 20*18cm in size, irregular and lobulated, surrounding the aorta, oppressing the right lung, unclear boundary between the tumor and the mediastinal pleura, obvious uneven enhancement, no significant enlarged lymph nodes were observed in the mediastinum, and aggressive thymotoma in the anterior mediastinum was considered. 2. Right upper lobe infection. 3. Bilateral small amount of pleural effusion. The color ultrasound of liver, gallbladder, spleen and pancreas showed no obvious abnormality. Pulmonary function examination revealed severe diffuse decline and moderate restrictive ventilation dysfunction. Blood test revealed leukocytosis: 10230/ul (normal range, 3500 to 9500/ul). Liver and kidney function test, blood coagulation function test were all basically normal. Gram-positive streptococcus was found in the sputum. Percutaneous puncture biopsy of the mediastinal tumor showed that the tissue was composed of neonatal thymus epidermal cells, which were spindle or oval in shape and had no abnormal nuclear division. A small number of non-neonatal lymphocytes were occasionally observed, which were consistent with the pathological characteristics of type A thymoma. The final diagnosis was: 1. Type A thymoma, stage IIIB; 2. COPD; 3. Right upper lung infection. The surgeon assessed that it was inoperable. The patient refused systemic chemotherapy. Considering that the patient may not be able to tolerate the adverse effects of conventional external irradiation with the poor lung function, 3D template and CT-guided 125I seed implantation was decided after multi-disciplinary consultation and consulting with the patient and his family members.

Surgical Methods: In a fixed position, a preoperative enhanced CT scan was performed with a 5mm slice distance. The images were transmitted into the particle treatment planning system (TPS). The radiologist delineated the target area of the tumor (GTV) and the planned target area (PTV) (GTV was 6 ~ 8 mm). Selected the appropriate particle activity (close to the spinal cord, large blood vessel area to choose 0.4 mCi particles, conventional area to choose 0.6mCi-0.8 mCi particles), prescription dose (dose, PD) set to

100-120Gy.The appropriate needle entry path was designed to avoid the dangerous organs and bone parts, and the particles were distributed on the needle path with spacing ranging from 5 mm to 20 mm to make the dose uniform as far as possible. and then designed the plan as a 3D printed template. In the actual operation, the antitussive drugs were taken orally first, the fixed position was consistent with the preoperative scanning, and the 3D template was placed in the designated area to determine the puncture sites. Local anesthesia with 5% lidocaine was performed at the puncture site first, then the interventional puncture needles were punctured into the tumor under the guidance of 3D template. The positions of the needle tips were adjusted by CT scan to ensure the consistency with the preoperative plan. The tips were about 0.5cm away from the distal edge of the tumor and 1.0cm away from the blood vessel. After no error, all 125I seeds were implanted as planned. Postoperative CT images were collected and input Panther Brachy 5.0 system for postoperative verification. A small amount of bleeding could be seen when the needles were pulled and stopped after local compression. The patient complained of mild pain at the puncture site, and the CT scan revealed no pneumothorax, pulmonary hemorrhage and other complications.

Results and Follow-up: Three months later after the surgery, a Chest CT(Fig. 2) reexamination of the patient showed that the tumor basically subsided, and the clinical efficacy was evaluated as CR. The pleural effusion disappeared, and the symptoms of chest tightness, shortness of breath and fatigue were basically relieved. At present, 3 years have gone, the patient is still alive. During telephone follow-up, the patient complained of mild chest tightness and fatigue, but he could live a normal life and do routine work, and at the same time refused to come to the hospital for review.

Discussion

Thymoma is a rare disease in clinic. It can be divided into malignant tumor and benign tumor according to whether it is aggressive or not. Type A thymic tumors are generally considered benign because of less aggressive. However, studies have shown that some patients with type A thymoma can have occurred recurrence and distant metastasis even after complete resection (15), indicating that they still have the characteristics of malignant tumor. Therefore, all thymomas are now considered as malignant tumors (16).For the treatment of this disease, according to the current domestic and international guidelines and expert consensus, radical surgical resection is considered as the first-line recommended plan for patients with stage I to IIIA. Postoperative adjuvant radiotherapy and chemotherapy can further reduce the probability of recurrence and metastasis according to the stage. Curran (17) et al. calculated that postoperative adjuvant radiotherapy can reduce the local recurrence rate of invasive thymocytoma after complete resection from 28–5% by multiple studies. For patients in stage IIIB-IV, the treatment is complex. It is currently recommended to perform induced radiotherapy and chemotherapy for patients who cannot be surgically excised immediately. Then the possibility of surgical excision will be evaluated after the mass is reduced. A number of articles have suggested that the indications for surgery are: no extensive invasion of intrathoracic organs, no invasion to the main vessels or the heart, technically resectable, and resistant to surgical treatment, as assessed by imaging (18–23). The principle of operation is to complete resection as far as possible. The standard operation is median sternal cleavage and total thymectomy.

Dai et al. (24) believe that tumor reduction surgery has a poor prognosis and does not significantly improve the survival of patients, unless when other treatment methods are not feasible. The patient in this case was initially diagnosed as type A thymoma, stage IIIB. Imaging examination suggested that the tumor was huge and had mediastinal pleural invasion. The surgeon's assessment remained that it was difficult to completely remove the tumor and the risk was very high.

Preoperative inductive therapy is thought to shrink the size of the tumor, reduce the stage, and gain the opportunity of surgical resection thereby, which includes neoadjuvant chemotherapy and neoadjuvant concurrent chemoradiotherapy, while the clinical data of neoadjuvant radiotherapy alone are few. The effective rate of chemotherapy for patients with thymoma is between 60% and 90% (25). Rea et al. (26) treated 32 patients with invasive thymoma with neoadjuvant chemotherapy, and the final complete surgical resection rate was 75%, and the 10-year overall survival rate was 61%. The European Organization for Research and Treatment for Cancer (EORTC) Lung Cancer Collaborative Group, treated 16 patients with advanced thymoma with combined chemotherapy, the median survival was 4.3 years (27). Thymoma is considered to be moderately sensitive to radiation(28). Wright et al. reviewed 10 cases with stage □- □A thymoma, these patients were all treated with induced chemoradiation, eventually 8 cases were complete resection, 5 years survival rate was 69% (29). In addition, a number of studies have shown that concurrent chemoradiotherapy has a good effect on inoperable locally advanced thymic tumors, with a total response rate of 69%-92% (30–32). At present, the International Thymoma Collaboration Group (ITMIG) recommends a dose of 40 ~ 64Gy for concurrent radiotherapy(33). 3D CRT, IMRT or VMAT technologies are recommended. The adverse reactions of normal organs to radiotherapy are related to the location and size of the tumor, previous treatment and the physical condition of the patient. The thymus gland is located between the two lungs, adjacent to the heart, and conventional radiotherapy techniques are likely to cause adverse reactions. Studies have shown that the radiation dose of more than 30Gy may lead to side reactions such as radiation pneumonia and radiation pericarditis, and with the increase of dose, the incidence of ADR also increased further (34, 35). The patient in this case was older and weak, with poor pulmonary function due to long-term smoking history, pulmonary infection and bilateral pleural effusion. In addition, the patient’s tumor was huge, surrounding the heart. After evaluation, the patient could be intolerant to conventional chemoradiotherapy.

125I seed which release gamma rays, can continuously kill tumor cells at a close range when implanted in tumor tissue. Compared with traditional radiotherapy, the biggest advantage of the technology is that the tissue dose is inversely proportional to the particle distance, meaning that the dose in the tumor target area close to the particle is higher, while the dose in the normal organs far away from the particle is lower(36, 37), thus reducing the adverse reactions of the normal organs. According to the statistics of some studies, the dose received in the target area of 125I particles is usually 2–3 times of the maximum prescribed dose of external radiation (38), which is more in line with the requirements of "conformal and intensity-modulated" radiotherapy. At present, this technique is widely used in China and has achieved good efficacy in the treatment of a variety of solid tumors. Moreover, it has been written into the guidelines for the diagnosis and treatment of prostate cancer of the European Association of Urology (39–43). In the treatment of thymoma, many articles have reported its effectiveness and safety (8–10).

After multi-disciplinary consultation and discussion, combined with the opinions of the patient and his family members, the patient decided to receive 125I seed implantation therapy.

3D printing technology can create a personalized guidance template according to the patient's image,to guide the implantation of 125I seeds. Zhang Hongtao and Xu Junma et al. (44, 45) compared the preoperative and postoperative dosimetric parameters of patients with particle implantation guided by 3D printing templates, the result was no significant difference. They believe that the dose of particle implantation guided by 3D printing templates could be accurately controlled. Freehand implantation mainly depends on the experience of the operator. Postoperative particle position and dose cannot be consistent with the preoperative plan, and the dose in the target area is not uniform, which can easily lead to a poor tumor control and recurrence, and a higher risk of damage to normal tissues and organs (46). Based on this, this patient decided to receive 125I seed implantation guided by 3D printing template. The operation of this patient went smoothly, the dose was 120Gy. Having used the BCCA implantation quality evaluation criteria for postoperative planning verification, the result of the implantation quality evaluation was excellent. Three months later, the patient's chest CT reexamination showed that the tumor had almost completely regressed. The pleural effusion disappeared, and the symptoms of chest tightness, shortness of breath and fatigue of the patient were basically relieved. The patient has survived for more than 3 years.

Conclusion

In this case of locally advanced giant thymoma, 125I seed implantation guided by 3D template and CT has achieved a good therapeutic effect, and no obvious adverse reactions occurred. The introduction of 3D printing template can improve the accuracy and safety of particle implantation. It is suggested that 125I seed brachytherapy may be a new choice for the treatment of thymoma in addition to the traditional radiotherapy and chemotherapy and surgical treatment. However, the follow-up time of this case is short, and further follow-up is needed to determine whether the patient can survive for 5 years or even 10 years.

Abbreviations

3D
Three-dimension
COPD
chronic obstructive pulmonary disease
TPS
treatment planning system
GTV
Gross Tumor Volume
PTV
planned target area
CR

complete remission
3D CRT
Three -Dimensional Conformal Radiation Therapy
IMRT
Intensity Modulated Radiation Therapy
VMAT
Volumetric Intensity Modulated Radiotherapy
BCCA
British Columbia Cancer Agency

Declarations

Ethical Approval And Consent To Participate

Not applicable

Consent for publication

Written informed consent was obtained from the individual for the publication of any potentially identifiable images or data included in this article.

Availability of data and materials

Data sharing is not applicable to this article as no datasets were generated or analysed during the current study.

Competing interests

The authors declare that they have no competing interests.

Funding

Not applicable

Authors Contributions

All authors made a significant contribution to the work reported, whether that is in the conception, study design, execution, acquisition of data, analysis and interpretation, or in all these areas; took part in drafting, revising or critically reviewing the article; gave final approval of the version to be published; have agreed on the journal to which the article has been submitted; and agree to be accountable for all aspects of the work.

Acknowledgements

Not applicable

References

1. Masaoka A, Monden Y, Nakahara K, Tanioka T. Follow-up study of thymomas with special reference to their clinical stages. Cancer-Am Cancer Soc. [Journal Article]. 1981 1981-12-01;48(11):2485–92.
2. Fang WT, Fu JH, Shen Y, et al. Management of thymic tumors: consensus based on the Chinese alliance for research in thymomas multi-institutional retrospective studies. Chinese Journal of Lung Cancer. 2016;19(07):414–7. 2016-07-20.
3. Regnard J, Magdeleinat P, Dromer C, Dulmet E, De Montpreville V, Levi J, et al. Prognostic factors and long-term results after thymoma resection: A series of 307 patients. The Journal of thoracic and cardiovascular surgery. 1996 1996-01-01;112(2):376–84.
4. Yuan LJ, Yu H. Progress in the study of mechanisms of lethal and malignant tumor effects by irradiation with a sustained low dose rate of particles. Qilu Med J. 2016 2016-06-02;31(02):242–5.
5. Chen Y, Yuan L. Ultrasound-guided radioactive 125I seed implantation treatment of prostatic cancer. Journal of Hubei university of medicine. 2016 2016-12-25;35(06):574–8.
6. Xiang Z, Mo Z, Li G, Gilani S, Zhong Z, Zhang T, et al. 125I brachytherapy in the palliation of painful bone metastases from lung cancer after failure or rejection of conventional treatments. Oncotarget. [Clinical Trial; Journal Article; Research Support, Non-U.S. Gov't]. 2016 2016-04-05;7(14):18384–93.
7. Li J, Zhu XL, Xie QG, et al. Research progress of CT-guided 125I seed implantation in the treatment of malignant tumors. Journal of Applied Clinical Medicine. 2015;19(21):239–42.
8. Ji YL, Zhang Y, Zhu LL, Zhu JQ, Zhu YF, Zhao H. Short-term clinical effect of intratumoral implantation with 125I seed in the treatment of local recurrent thymoma. Journal of the Second Military Medical University.2020 2020-07-20;41(07):803–7.
9. Li C. Clinical effect analysis of CT-guided 125I radioactive seed implantation in the treatment of advanced and recurrent thymic carcinoma. China Medical University; 2020.
10. Cui J, Zhang C. Short-term effect of operation combined with intraoperative implantation of 125I particles on 12 cases of malignant thymoma. Journal of Oncology. 2011;2011-11-20(11):866–7. 17(.
11. Bagaria V, Deshpande S, Rasalkar DD, Kuthe A, Paunipagar BK. Use of rapid prototyping and three-dimensional reconstruction modeling in the management of complex fractures. EUR J RADIOL. [Journal Article; Review]. 2011 2011-12-01;80(3):814–20.
12. Hurson C, Tansey A, O Donnchadha B, Nicholson P, Rice J, McElwain J. Rapid prototyping in the assessment, classification and preoperative planning of acetabular fractures. INJURY. 2007 2007-01-01;38(10):1158–62.
13. Brown GA, Firoozbakhsh K, DeCoster TA, Reyna JJ, Moneim M. Rapid prototyping: the future of trauma surgery? J BONE JOINT SURG AM. [Journal Article]. 2003 2003-01-20;85-A Suppl 4:49–55.
14. Zhang HT, Di XM, Yu HM, et al. Dose comparison before and after implantation of 125I particles guided by 3D printing template. Chinese Medical Journal. 2016 2016-03-08;96(09):712–5.
15. Mengoli MCM, Longo LM, Varini SM, Rossi GMP, Lococo FM. Invasive Medullary Type A Thymoma With Recurrent Distant Metastases. The Annals of thoracic surgery. 2017 2017-01-01;103(5):e423-5.

16. Wang H, Zhai Y. Mechanism of differentiation and development of natural regulatory T cells in the thymus. Journal of Nanjing Medical University (Natural Science). 2017 2017-01-15;37(01):15–9.
17. Curran JWJ, Kornstein MJ, Brooks JJ, Turrisi RAT. Invasive thymoma: the role of mediastinal irradiation following complete or incomplete surgical resection. J CLIN ONCOL. 1988;6(11):1722. 1988-01-01.
18. Yokoi K, Kondo K, Fujimoto K, Hara M, Kadota Y, Kawaguchi K, et al. JLCS medical practice guidelines for thymic tumors: summary of recommendations. JPN J CLIN ONCOL. 2017;47(12):1119–22. 2017-01-01.
19. Banna GL, Sheel A, Sheel V, Bille A, Routledge T, Fernando S, et al. Treatment and prognostic factors of patients with thymic epithelial tumors at first recurrence or progression. Future oncology (London, England). 2017 2017-01-01;13(27):2429–39.
20. Marulli G, Margaritora S, Lucchi M, Cardillo G, Granone P, Mussi A, et al. Surgical treatment of recurrent thymoma: is it worthwhile? dagger. Eur J Cardiothorac Surg. [Evaluation Study; Journal Article; Multicenter Study]. 2016 2016-01-01;49(1):327–32.
21. Margaritora S, Cesario A, Cusumano G, Lococo F, Porziella V, Meacci E, et al. Single-centre 40-year results of redo operation for recurrent thymomas. EUR J CARDIO-THORAC. 2011;40(4):894–901. 2011-01-01.
22. Park B, Park JS, Kim HK, Choi YS, Kim K, Shim YM, et al. Surgical management of locoregionally recurrent thymoma. THORAC CANCER. 2011;2011-01-01(4):196–200. 2(.
23. Regnard JF, Zinzindohoue F, Magdeleinat P, Guibert L, Spaggiari L, Levasseur P. Results of re-resection for recurrent thymomas. ANN THORAC SURG. [Journal Article]. 1997 1997-12-01;64(6):1593–8.
24. Dai J, Song N, Yang Y, Jiang G. Is it valuable and safe to perform reoperation for recurrent thymoma? Interact Cardiovasc Thorac Surg. [Journal Article; Review]. 2015 2015-10-01;21(4):526–31.
25. Loehrer PS, Jiroutek M, Aisner S, Aisner J, Green M, Thomas CJ, et al. Combined etoposide, ifosfamide, and cisplatin in the treatment of patients with advanced thymoma and thymic carcinoma: an intergroup trial. CANCER-AM CANCER SOC. [Clinical Trial; Journal Article; Multicenter Study; Research Support, U.S. Gov't, P.H.S.]. 2001 2001-06-01;91(11):2010–5.
26. Rea F, Marulli G, Girardi R, Bortolotti L, Favaretto A, Galligioni A, et al. Long-term survival and prognostic factors in thymic epithelial tumours. Eur J Cardiothorac Surg. [Journal Article]. 2004 2004-08-01;26(2):412–8.
27. Loehrer PS, Chen M, Kim K, Aisner SC, Einhorn LH, Livingston R, et al. Cisplatin, doxorubicin, and cyclophosphamide plus thoracic radiation therapy for limited-stage unresectable thymoma: an intergroup trial. J CLIN ONCOL. [Clinical Trial; Journal Article; Multicenter Study; Research Support, U.S. Gov't, P.H.S.]. 1997 1997-09-01;15(9):3093–9.
28. Onuki T, Ishikawa S, Yamamoto T, Ito H, Sakai M, Onizuka M, et al. Pathologic radioresponse of preoperatively irradiated invasive thymomas. J THORAC ONCOL. [Comparative Study; Journal Article]. 2008 2008-03-01;3(3):270–6.

29. Wright CD, Choi NC, Wain JC, Mathisen DJ, Lynch TJ, Fidias P. Induction chemoradiotherapy followed by resection for locally advanced Masaoka stage III and IVA thymic tumors. ANN THORAC SURG. [Journal Article]. 2008 2008-02-01;85(2):385–9.
30. Gao YM, Yang YP, Liu QF, et al. Efficacy of three-dimensional conformal radiotherapy combined with EP chemotherapy in the treatment of advanced thymic carcinoma. Modern oncology. 2014(8):1822–4.
31. Sui JG, Chen WY, Jiang QA. Short-term effect of stereotactic radiotherapy on 38 cases of thymoma. Oncology research and clinical practice. 2002 2002-02-28(01):49.
32. Loehrer SPJ, Chen M, Kim K, Aisner SC, Einhorn LH, Livingston R, et al. Cisplatin, doxorubicin, and cyclophosphamide plus thoracic radiation therapy for limited-stage unresectable thymoma: an intergroup trial. J CLIN ONCOL. 1997 1997-01-01;15(9):3093.
33. Gomez D, Komaki R, Yu J, Ikushima H, Bezjak A. Radiation therapy definitions and reporting guidelines for thymic malignancies. J THORAC ONCOL. [Journal Article]. 2011 2011-07-01;6(7 Suppl 3):S1743-8.
34. Mou H, Liao Q, Hou X, Chen T, Zhu Y. Clinical characteristics, risk factors, and outcomes after adjuvant radiotherapy for patients with thymoma in the United States: analysis of the Surveillance, Epidemiology, and End Results (SEER) Registry (1988–2013). INT J RADIAT BIOL. 2018 2018-01-01;94(5):495–502.
35. Jackson MW, Palma DA, Camidge DR, Jones BL, Robin TP, Sher DJ, et al. The Impact of Postoperative Radiotherapy for Thymoma and Thymic Carcinoma. J THORAC ONCOL. 2017 2017-01-01;12(4):734–44.
36. Wang C, Chen Z, Sun W, Yasin Y, Zhang C, Ma X, et al. Palliative treatment of pelvic bone tumors using radioiodine (125I) brachytherapy. WORLD J SURG ONCOL. 2016 2016-01-01;14(1):294.
37. Han L, Li C, Wang J, He X, Zhang X, Yang J, et al. Iodine-125 radioactive seed tissue implantation as a remedy treatment for recurrent cervical cancer. J CANCER RES THER. [Journal Article]. 2016 2016-12-01;12(Supplement):C176-80.
38. Wang JJ, Wang JJ, Yuan HS, Yuan HS, Li JN, Li JN, et al. Interstitial permanent implantation of 125I seeds as salvage therapy for re-recurrent rectal carcinoma. INT J COLORECTAL DIS. 2009;24(4):391–9. 2009-01-01.
39. Yan H, Xiang Z, Zhong Z, Mo Z, Zhang T, Chen G, et al. CT-guided 125I brachytherapy in the treatment of distant metastases in the oral cavity and maxillofacial region. TRANSL ONCOL. [Journal Article]. 2017 2017-02-01;10(1):90–8.
40. Huang H, Xu S, Li F, Du Z, Wang L. Clinical application of computed tomography-guided 125I seed interstitial implantation for head and neck cancer patients with unmanageable cervical lymph node metastases. EUR J MED RES. [Journal Article]. 2016 2016-04-27;21:18.
41. Henry AM, Rodda SL, Mason M, Musunuru H, Al-Qaisieh B, Bownes P, et al. The Effect of Dose and Quality Assurance in Early Prostate Cancer Treated with Low Dose Rate Brachytherapy as

Monotherapy. Clinical oncology (Royal College of Radiologists (Great Britain)). 2015 2015-01-01;27(7):382–6.

42. Zhu H, Guo J, Zhu G, He S, Fang W, Deng G, et al. A novel biliary stent loaded with 125I seeds in patients with malignant biliary obstruction: preliminary results versus a conventional biliary stent. J HEPATOL. 2012;56(5):1104–11. 2012-01-01.
43. Guo J, Teng G, Zhu G, He S, Fang W, Deng G, et al. Self-expandable esophageal stent loaded with 125I seeds: initial experience in patients with advanced esophageal cancer. RADIOLOGY. 2008 2008-01-01;247(2):574.
44. Xu JM, Yu YC, Liu Z, et al. Comparison of physical dosimetric parameters of 3D template combined with CT-guided 125I radioactive particle precise implantation for malignant tumors. Jiangsu medicine. 2019 2019-05-30;45(05):492–6.
45. Zhang HT, Di XM, Yu HM, et al. Dose comparison before and after implantation of 125I particles guided by 3D printing template. Chinese Medical Journal. 2016 2016-03-08;96(09):712–5.
46. Jia B, Li LS, Shi XL, Xia B, Chen ZL. Clinical application of percutaneous implantation of 125I particles in the treatment of malignant tumors. Journal of interventional radiology. 2005 2005-08-30(04):398–400.

Figures

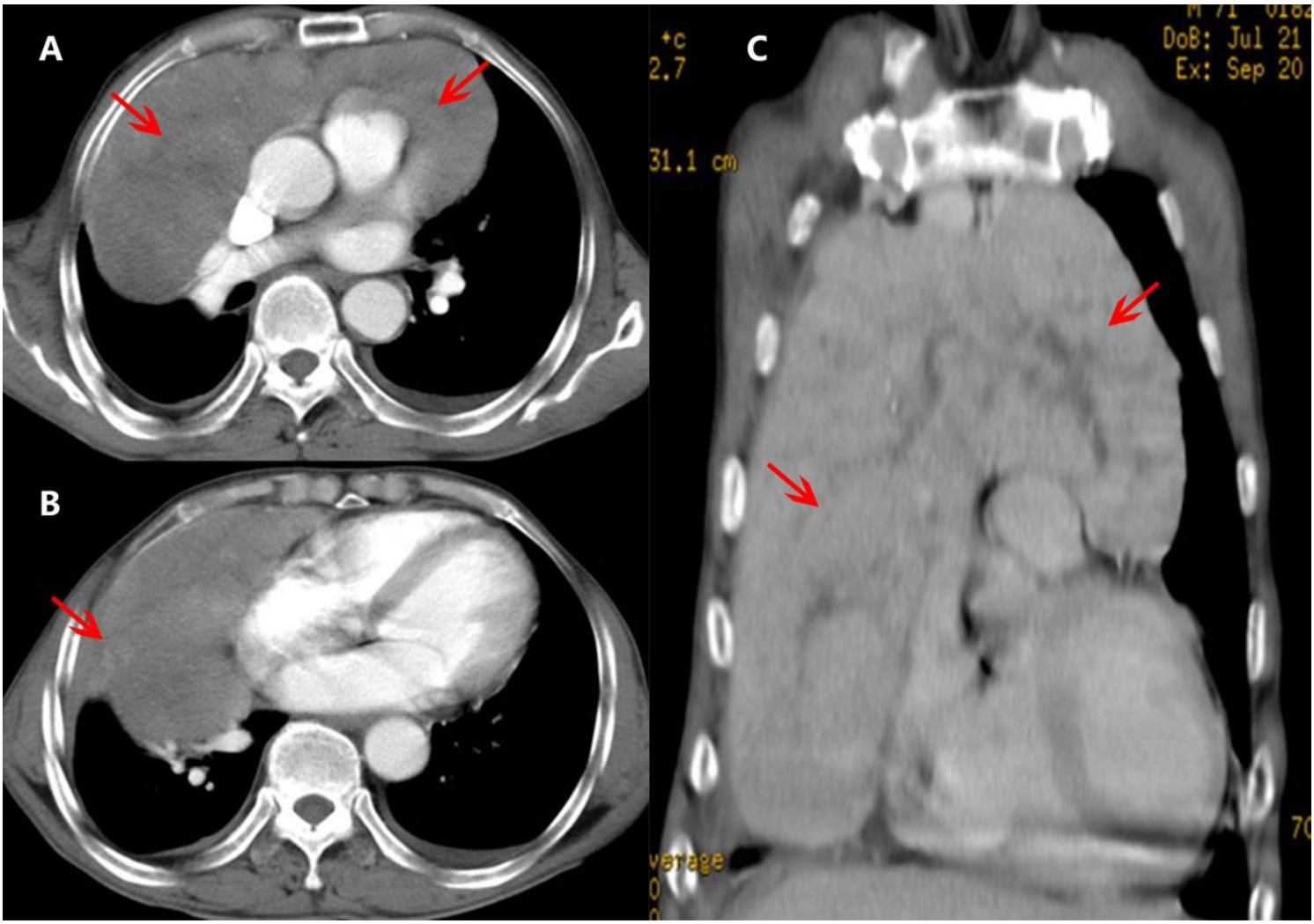

Figure 1

CT showed a mass was observed in the anterior mediastinum, about 20*18cm in size, irregular and lobulated, surrounding the aorta (A, red arrow). There was an unclear boundary between the tumor and the pleura, obvious uneven enhancement (B, red arrow). The coronal image showed the mass almost filling the right thoracic cavity, and oppressing the left lung (C, red arrow).

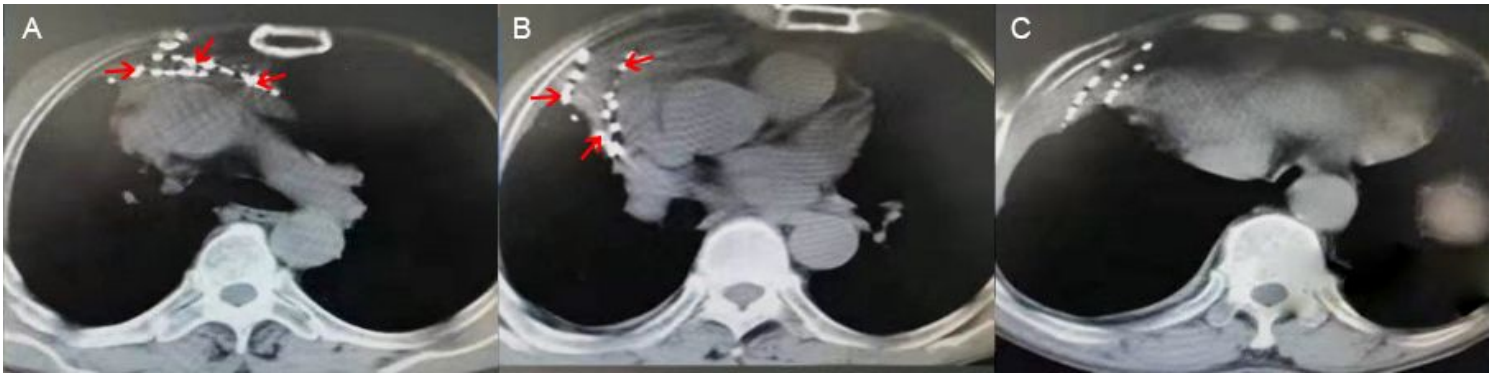

Figure 2

CT showed the I125 particles were clumped together (A and B, red arrows) as the previously huge mass retreated significantly, and the pleural effusion largely disappeared.