Simultaneous Damage to the Hepatic Artery and Common Bile Duct in a Blunt Abdominal Trauma: A Case Report

Mohsenreza Mansoorian Mansoorian
Iran University of Medical Sciences

Mohammad reza Babaei
Iran University of Medical Sciences: Tehran University of Medical Sciences

Mehdi Nikkhah
Iran University of Medical Sciences

Behrooz Seyedi Majd
Iran University of Medical Sciences

Nazanin Alibeik
Iran University of Medical Sciences, Firoozgar Hospital

Neda Rahimian
Iran University of Medical Sciences

Ramin Bozorgmehr (raminchebozorgmehr@gmail.com)
Alborz University of Medical Sciences https://orcid.org/0000-0002-8471-7978

Case report

Keywords: Blunt trauma, bile duct, extrahepatic biliary tree

Posted Date: June 28th, 2021

DOI: https://doi.org/10.21203/rs.3.rs-606279/v1

Abstract

Background: Diagnosis and management of extrahepatic duct injuries in blunt abdominal trauma is very difficult and challenging. First because these injuries are very rare. Also, in the management of abdominal blunt trauma, many patients are currently managed with non-surgical and conservative methods.

Case presentation: A 23-year-old man who referred to General Hospital in down town of Tehran due to severe trauma in rollover motorcycle accident. There was no evidence of hemodynamic instability in emergency department. There was a drop in hemoglobin in the first week of hospitalization, which could be due by hepatic artery injury. We decided to manage hepatic artery pseudo aneurysm with interventional radiology approach. On angiography, a picture of a thrombotic pseudoaneurysm was seen, which was embolized by passing a catheter and endovascular *coiling*. Four days later, he presented with severe abdominal distension. In the study, the abdomen was full of fluid, which was emptied, and about 5 liters of bile were expelled**.** Twenty-four days after the accident, the patient underwent ERCP and a clear leak of proximal part CBD was evident. CBD stent was inserted under the guide of fluoroscopy. The patient underwent complete intravenous nutrition and the volume of discharge did not decrease during treatment. One week after starting intravenous feeding, the patient developed fever, tachycardia, and abdominal tenderness, so he underwent surgery. Severe adhesions and multiple collections were evident in the abdomen. Abdominal lavage was performed and two right and left sub-diaphragmatic drains were inserted and the abdomen was closed. Enteral feeding began 5 days after the surgery and the patient was discharged in good general condition.

Conclusions: This is a rare case of simultaneous hepatic artery and common bile duct injury at the same time which manage with interventional embolization for hepatic artery pseudoaneurysm and ERCP and stenting also total parenteral nutrition for common bile duct injury at first step. At last surgery was done due to control the sepsis and abdominal collections drainage.

Back Ground

Diagnosis and management of extrahepatic duct injuries in blunt abdominal trauma is very difficult and challenging. First because these injuries are very rare[1] [2]. Also, in the management of abdominal blunt trauma, many patients are currently managed with non-surgical and conservative methods. [3] [4]Many lesions present late, which means that even in some of these patients who undergo laparotomy, these types of injuries are not found during surgery, possibly due to emergency situation and inability to perform an intraoperative cholangiography or damage control surgery to stabilize the patient [5].

Today most of the extra hepatic bile duct injuries are happened during the laparoscopic cholecystectomy and manage endoscopic or surgical based on the amount and diagnosis time of the duct injury. Different mechanisms have been proposed to justify the cause of bile duct injury due to blunt trauma to the abdomen, which does not seem to make a difference in the management of this type of trauma. [6] [7]

The most common site of injury to the extrahepatic bile duct is where the common bile ducts enter the pancreas. [8]

Case Presentation

A 23-year-old man who referred to General Hospital in down town of Tehran due to severe trauma in rollover motorcycle accident. There was no evidence of hemodynamic instability in emergency department. At first, the patient was slightly confused, and he had Glasgow coma scale of about 14 out of 15. In the studies, he had an epidural hematoma without indication for surgical intervention. In early phase of admission, no major abnormal lab data was detected [Table 1].

Table 1
Lab data

	1st	2nd	3rd	6th	8th	15th
Hemoglobin level	14.4	12	11.3	11.3	10.5	12.2
Hct	43.4	34	32.8	32.6	30.3	34.6
WBC	13.2	10.2	9.2	9.2	9.1	5.8
Bilirubin total level	0.5	2.6		3.4	3.1	2.8
Bilirubin direct level	0.2	1.3		2.2	1.2	1.2
Alk.P	269	209		361	604	809
AST	255	157		64	87	61
ALT	176	142		52	86	82

In the initial examination, the abdomen was soft and there was no evidence in favor of peritonitis, Ultrasound sound examination was done, free fluid was found in the hepatorenal space. The patient was further examined by CT scan, which showed evidence of hepatic artery pseudoaneurysm [figure1A]. There was a drop in hemoglobin in the first week of hospitalization, which could be due by hepatic artery injury. After stabilization of the patient and treatment of epidural hematoma, about 6th day of hospital admission, we decided to manage hepatic artery pseudo aneurysm with interventional radiology approach. On angiography, a picture of a thrombotic pseudoaneurysm was seen, which was embolized by passing a catheter and endovascular coiling. [Figure 1C] There was no evidence of biliary injury in lab data till the 6th of post injury. A mild rise in indirect bilirubinemia was detected that could be due to hematoma around the pseudoaneurysm [Table1].

About 5 days after embolization, the patient is discharged without abdominal symptoms and peritonitis. Four days later, he presented with severe abdominal distension. In the study, the abdomen was full of fluid, which was emptied, and about 5 liters of bile were expelled [figure1B]. CT scans and MRI scans showed no evidence of bile leakage from the bile ducts. The decision is made to the ERCP.

After implanting the drain and discharging about 5 liters of biloma, about 200 cc of bile secretion was draining daily from the implanted drain. Due to the continuation of bile leakage and the fact that the leak was not determined by CT scan and MRCP [Figure 1B and D], we decided to evaluate the biliary tree with Endoscopic Retrograde Cholangiography. 24 days after the accident, the patient underwent ERCP and a clear leak of proximal part CBD was evident. CBD stent was inserted under the guide of fluoroscopy.

The patient underwent complete intravenous nutrition and the volume of discharge did not decrease during treatment. One week after starting intravenous feeding, the patient developed fever, tachycardia, and abdominal tenderness, so he underwent surgery. The patient's abdomen was explored with a subcostal incision and in the initial examination, severe adhesions and multiple collections were evident in the abdomen. The small intestine had a serous layer at three points of injury that was repaired with a vicryl suture. Abdominal lavage was performed and two right and left sub-diaphragmatic drains were inserted and the abdomen was closed.

Supportive treatment and broad-spectrum antibiotic therapy were performed and after controlling the patient's sepsis, intravenous feeding was resumed for the patient and the patient's biliary discharge was stopped. Enteral feeding began 5 days after the surgery and the patient was discharged in good general condition.

Discussion And Conclusion

Bile duct injuries due to Blunt trauma are very rare and therefore there is insufficient information about their diagnosis and treatment reported extrahepatic duct injury is about 0.37 %[1], as well as concomitant CBD and hepatic artery damage are rare and has been reported rarely in studies. This type of bile duct injury is usually diagnosed with a delay and this causes many complications and morbidities for the patients and medical staff. [9]

These patients present to the emergency department with two clinical conditions. In most cases, they are stable hemodynamic situations, and in other cases, they are unstable and they undergo emergency surgery. In cases undergoing conservative treatment, a delay of about 11 days in diagnosis has been reported. [8] The reason for the delay in diagnosis is probably because the bile leak is mistaken for bleeding from blunt abdominal trauma in hemodynamically stable patient. Porta hepatis hematoma reported in some cases of extra hepatic biliary tree injuries in our case Hepatic artery injury was suggested as the cause of hematoma. [8] [10] In some cases, abundant free fluid without a sharp drop in hemoglobin can be a guide to diagnosing extrahepatic bile duct damage. [8] Our patient presented with similar conditions a few days after discharge. In many of these patients, laboratory changes, such as an increase in bilirubin blood levels, are attributed to factors such as blood transfusions or the process of absorption of the hematoma. [11]

In many cases, extrahepatic bile duct injury is not found during early laparotomy in the case of unstable patient for management of trauma, and this is usually because in many cases damage control surgery

chooses to do lifesaving interventions. In many cases, the duct is damaged and ischemic, causing a delayed bile leak.

This is a rare case of simultaneous hepatic artery and common bile duct injury at the same time which manage with interventional embolization for hepatic artery pseudoaneurysm and ERCP and stenting for common bile duct injury at first step.

Abbreviations

1. ERCP: Endoscopic Retrograde Cholangiopancreatography
2. CBD: common bile duct
3. CT: computed tomography

Declarations

Ethics approval and consent to participate:

Ethics approval was obtained from the ethics committee of Iran University of medical sciences.

Consent for publication

All presentations of case reports have consent for publication and written consent was obtained from the patient.

Availability of data and materials

The datasets used in this study are available from the corresponding author whenever requested.

Competing interests

The authors testify that they have no competing interests.

Funding

Due to limited financial resources, all authors participated in writing this article voluntarily without any financial gain.

Authors' contributions

Mohsen Reza mansoorian: Attending hepatobiliary surgeon and the surgery managed with mansoorian.

Mohammad reza Babaei: Embolization was done with Babaei, radiologist interval

Mehdi Nikkhah: ERCP was done by Nikkhah.

Behrooz Seyedi Majd: Post operation visiting surgeon.

Nazanin Alibeik: Collecting data from the patient and editor.

Neda Rahimian: Final editor

Ramin Bozorgmehr: chief resident of General Surgery ward and writer of the manuscript.

Acknowledgements

Not applicable

References

1. Rodriguez-Montes, J.A., E. Rojo, and L.G. Martín, *Complications following repair of extrahepatic bile duct injuries after blunt abdominal trauma.* World J Surg, 2001. **25**(10): p. 1313-6.

2. Kaul, S., A. Homnick, and D. Livingston, *Intrapancreatic bile duct injury: case report.* Journal of Trauma and Acute Care Surgery, 2002. **52**(4): p. 786-788.

3. Mallick, M.S., A.A. Al-Bassam, and A.A. Boukai, *Non operative management of blunt bile duct injuries in children.* Saudi medical journal, 2002. **23**(3): p. 341-344.

4. Velmahos, G.C., et al., *High success with nonoperative management of blunt hepatic trauma: the liver is a sturdy organ.* Archives of surgery, 2003. **138**(5): p. 475-481.

5. Kaul, S., A. Homnick, and D. Livingston, *Intrapancreatic bile duct injury: case report.* J Trauma, 2002. **52**(4): p. 786-8.

6. Ahmed, S., *BILE DUCT INJURIES FROM NON-PENETRATING ABDOMINAL TRAUMA IN CHILHOOD.* Australian and New Zealand Journal of Surgery, 1976. **46**(3): p. 209-212.

7. Parks, R. and T. Diamond, *Non-surgical trauma to the extrahepatic biliary tract.* British journal of surgery, 1995. **82**(10): p. 1303-1310.

8. Pereira, R., T. Vo, and K. Slater, *Extrahepatic bile duct injury in blunt trauma: A systematic review.* Journal of Trauma and Acute Care Surgery, 2019. **86**(5): p. 896-901.

9. Slater, K., et al., *Iatrogenic bile duct injury: the scourge of laparoscopic cholecystectomy.* ANZ J Surg, 2002. **72**(2): p. 83-8.

10. Pereira, R., T. Vo, and K. Slater, *Extrahepatic bile duct injury in blunt trauma: A systematic review.* J Trauma Acute Care Surg, 2019. **86**(5): p. 896-901.

11. Jones, K.B. and E. Thomas, *Traumatic rupture of the hepatic duct demonstrated by endoscopic retrograde cholangiography.* The Journal of trauma, 1985. **25**(5): p. 448-449.

Figures

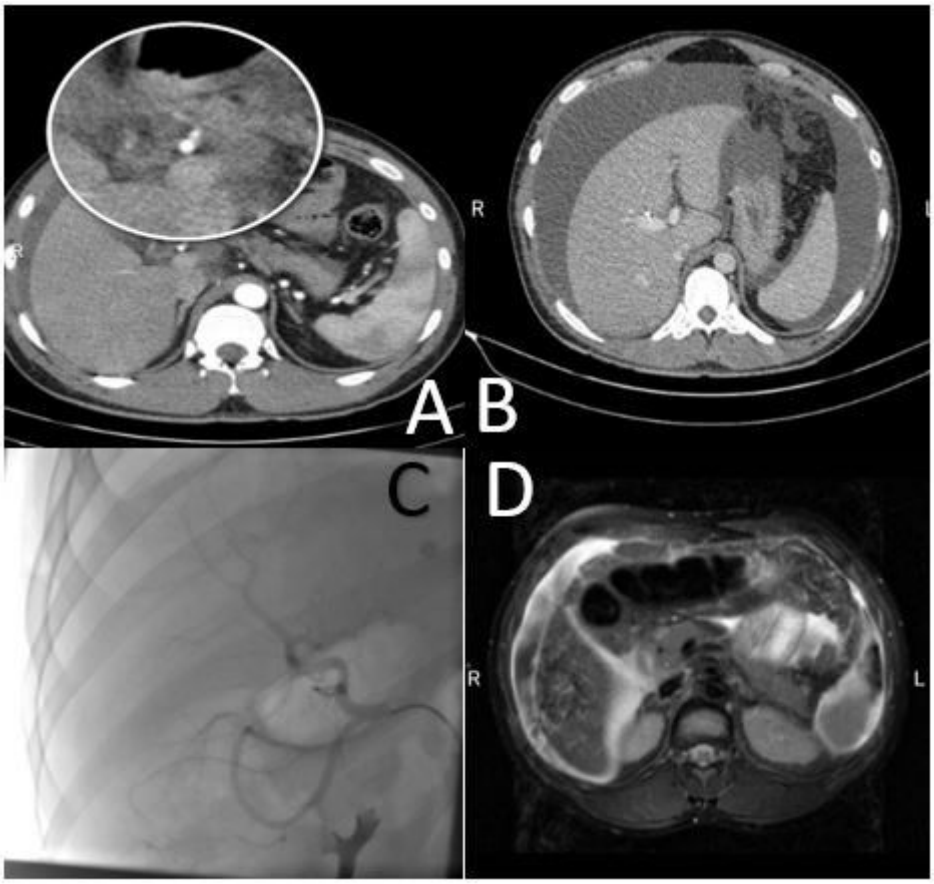

Figure 1

free fluid in the perihepatic space and hepatic artery pseudoaneurysm B biloma after fifteen days C hepatic artery is patent after embolization of vascular injury D no leak was detected in MRCP