Folded Free Vascularized Fibular Bone Graft for Segmental Femoral Bone Defect: a Retrospective Report

Yifan Wu
Wuhan University Zhongnan Hospital
Chao Jian
Wuhan University Zhongnan Hospital
Baiwen Qi
Wuhan University Zhongnan Hospital
Zonghuan Li
Wuhan University Zhongnan Hospital https://orcid.org/0000-0002-7259-5360
Aixi Yu (yuaixi@whu.edu.cn)
Wuhan University Zhongnan Hospital

Research article

Keywords: folded, vascularized fibular bone graft, femoral, bone defect, retrospective

Posted Date: June 16th, 2021

DOI: https://doi.org/10.21203/rs.3.rs-606412/v1

Abstract

Objective

Vascularized fibular bone graft is an efficient method for various segmental bone defects. The objective of this report is to introduce our experience of folded free vascularized fibular bone graft for segmental femoral bone defect.

Patients and methods

Clinical data collected by surgeons and Hospital Information System (HIS) system were screened respectively. Cases with segmental femoral bone defect repaired by folded free vascularized fibular bone graft were collected. Clinical data including demographic characteristics, defect size, coinfection, perioperative treatment and imaging data during follow up were all collected for analysis.

Results

Twelve patients (10 males and 2 females), aged from 6 to 58, were included in this report. The defect range was 3 to 10 cm, with an average of 6.2 cm. Three cases were complicated with infection, the others were not. Folded free vascularized fibular bone graft were harvested for the reconstruction of segmental femoral bone defect. The grafts were fixed with plates in 9 cases and external fixators in 3 cases. All grafts healed uneventfully with an average healing time of 5.2 months (range 4~8 months). Internal fixation failure occurred in one case. The follow up time ranged from 15 to 130 months (average 58.3 months).

Conclusion

Folded free fibula graft is one of the optional methods for segmental bone defect of femur. Through this method, patients can achieve one-time operation to reconstruct the bone defect of the affected limb.

Introduction

The clinical treatment of segmental femoral bone defect is difficult. As the main load-bearing bone of lower limb, the reconstruction of bone defect needs to consider the length of bone defect, the thickness of bone and the duration of disease[1]. Generally, segmental bone defects could be managed by several methods, such as Illizarov technique, induced membrane technique and bone graft[2]. Illizarov technique, which needs a long treatment course, has been criticized for related soft tissue and neurovascular complications. Induced membrane technique can repair long femoral defect, but it needs staged operation[3]. Moreover, this method is not indicated for segmental bone defect with infection[4, 5]. Autologous bone transplantation, especially autologous bone graft with blood supply, has been proven a better solution for the treatment of segmental bone defects[6]. We have reported the complex tibial bone, soft tissue, and main artery segmental defects reconstructed by flow-through free fibula osteocutaneous

flap in one stage[7]. In recent years, folded free vascularized fibula graft was applied to repair segmental defect of femur. And good results were achieved. Thus, we retrospectively review the cases and conduct this report.

Patients And Methods

Inclusion and exclusion criteria

Patients who met the following criteria were included: (1) patient diagnosed as femoral bone defect; (2) treated by folded free vascularized fibula graft; (3) patient with complete medical history and follow-up information.

Patients were excluded for the following reasons: (1) femoral bone defect treated by other methods: including induced membrane technique, Illizarov bone transport, non-vascularized bone graft and one barrel fibula graft; (2) severe infection of the limb out of control; (3) composite tissue defect; (4) incomplete medical history or follow-up information.

General information of included cases

A total of 12 cases of femoral bone segmental defect treated by folded free vascularized fibula graft were included. The general information was listed in Table 1. Ten were male while two were female. The average age was 25.8 years (6 to 58). Seven cases were caused by wide resection of the tumor, three by radical debridement of posttraumatic osteomyelitis. The defects were located in the femoral shaft in 7 cases and distal femur in 3 cases. The average length of defect was 6.2 cm (3 to 10 cm). The fibular vessels were anastomosed with the descending branch of the lateral circumflex femoral artery in 10 cases, and the fibular vessels were anastomosed with the lateral superior genicular vessels in 2 cases. The vessels were anastomosed end to end.

Preoperative management

After admission, routine preoperative examination, anteroposterior and lateral view film of the femur were performed. CT and MRI were performed when necessary to identify bone tumor or inflammatory boundary. Infection status of the infectious bone defect should be determined with routine blood test, C-reactive protein and erythrocyte sedimentation rate. For severe infection and poor local soft tissue conditions, multiple debridement operations are needed until the infection is controlled. Appropriate antibiotics can be selected according to the results of wound secretion culture.

Surgical technique

The patient was placed in supine position. For the femoral bone tumors, the lesions were either excised or performed with extended resection according to the nature of the lesions. For infective bone defect, first of all, radical debridement was conducted until no obvious local inflammation exist. Bone reconstruction surgery is performed at least 3 months later. The length of femoral defect was measured. Different

recipient vessels were selected according to the location of the femoral defect. If it is located in the middle or proximal femur, the descending branch of lateral circumflex femoral artery is separated. If the defect is located at the distal femur, the lateral superior genicular vessels are dissected. The recipient vessels are selected individually according to previous surgeries and local soft tissue coverage.

A longitudinal incision was made on the posterolateral side of the proximal lower leg. The gastrocnemius muscle was separated to expose the fibular vessels, and the proximal end of the fibula was cut off. The flexor pollicis longus was exposed. The interosseous membrane was excised, and the fibula was pulled outwards. The muscle sleeve of 0.5-1 cm was reserved around the periosteum. According to the length of the recipient area, the distal fibula was cut off and the fibular vessels were cut off.

The bony part of fibula flap was broken in the middle, and the integrity and continuity of soft tissue and blood vessels were preserved. The folded graft was placed in the defect of femur. Other bone substitutes were used when necessary. The arteries and veins were anastomosed to the vessels of the recipient area successively. Great saphenous vein graft for vascular bridging was adopted when there is a vascular defect. The bony structure was fixed with plate or external fixator. Generally, for infectious bone defect, if there is still low-grade infection after multiple debridement, external fixator should be used. If the local infection has been controlled after debridement, the plate can be selected to provide more stable fixation. For infective defect, vancomycin artificial bone can be used to prevent infection recurrence.

Postoperative treatment

Smoking was strictly prohibited in the surrounding environment of patients, and local warmth was maintained. Anti-inflammatory, anti-vasospasm and anticoagulant therapy were given after operation. Patients began active hip and knee joint activities after operation to avoid stiffness. Immediately after the operation and every 2-3 months after the operation, the anteroposterior and lateral films of the affected femur were reviewed to evaluate the fracture healing. The postoperative complications were recorded.

Results

Finally, twelve patients, with 10 males and 2 females, were included in this report. One patient was collected by the surgeon while the rest were retrieved from the HIS system. The demographic characteristics and the follow up information were showed in Table 1. The age range of included patients was 6 to 58 years, with an average of 25.8 years. The defect range was 3 to 19 cm, with an average of 6.2 cm. Three cases were complicated with infection, the others were not. Folded free vascularized fibular bone graft were harvested for the reconstruction of segmental femoral bone defect. The grafts were fixed with plates in 9 cases and external fixators in 3 cases. All grafts healed uneventfully with an average healing time of 5.2 months (range 4 ~ 8 months). Internal fixation failure occurred in one case. The follow up time ranged from 15 to 130 months (average 58.3 months).

Case 1

A 25-year-old man with chronic osteomyelitis of the left femur was admitted from another hospital. After several debridement operations, bone defects were left in the femur. Six months after the local infection was controlled, debridement and folded vascularized fibular graft with internal fixation were performed. The peroneal vessels were anastomosed with the descending branch of lateral circumflex femoral vessels. After 8 months, the patient fell down again and felt the pain along the thigh. The X-ray showed internal fixation failure. Then the reconstructive procedure, including fixation exchange and iliac bone graft, were performed. Now the fracture healed well, with slightly limited knee flexion. The images of this patient were showed in Fig. 1.

Discussion

This report included segmental femoral shaft defects reconstructed with folded free vascularized fibula graft. The patients were followed for 15 to 130 months. All patients achieved bone union and the union time ranged from 4 to 8 months. Internal fixation failure occurred in one case. No infection and other complications were recorded.

Though many methods have been confirmed efficient for the management of segmental femoral bone defect, it is still challenging for the surgeons. Currently, three methods are commonly used: induced membrane technique, Illizarov technique and vascular bone graft. Induced membrane technique has been confirmed efficiently for segmental defect reconstruction[8]. The bone union rate was 87.5% for reconstruction after bone tumor resection[9]. However, the results are uncertain for infectious bone defect. Morris[10] reconstructed 12 tibial bone defects with Masquelet technique and followed for 675 days. Bone union was achieved in only 5 patients after two-stage procedure. Five patients suffered infection and two cases required amputation. Renaud[4] also reported a similar bone union rate (8/19) for the management of septic non-union of the tibia. The additional surgery was required for 11 of the 19 cases.

Segmental femoral bone defects would also be repaired by Ilizarov bone transport. However, it is still challenging and may end in failure especially for periarticular bone defect[11]. Tong compared the Ilizarov bone transport and Masquelet technique for the management of infected bone defect of lower limb. Patient by Ilizarov bone transport required longer external fixation time but gained worse functional outcomes, even though the bone union results showed no significant difference [12].

In our case series, 3 of them were infectious bone defects and the bone defect located in femoral shaft. Thus, we chose the vascularized free fibula graft for the reconstruction. On one hand, the cortical bone together with internal fixation provided sufficient biomechanical support for the lower limb. On the other hand, abundant blood supply of the graft enhanced the anti-inflammatory and antibacterial activity. Meanwhile, the blood supply with the graft also accelerated the healing process of end of donor and recipient which was hindered by the surrounding hypovascular fibrotic tissue.

Erdmann et al[13] introduced a novel ipsilateral free fibula transfer for management of a segmental femoral bone defect. With this method, vessel preparation at the recipient site for microvascular

anastomosis is unnecessary, while extensive exposure at the donor site is needed. It provided an optional method for the reconstruction of femoral bone defect, especially for recipient site with multiple surgeries, healthy vessels are not available.

Free vascularized fibula grafts, for its high bone healing potential and biomechanically strong support, have been the effective treatments for the management of segmental bone defect longer than 6cm. Lee[14] reported free vascularized fibula grafts in 7 patients with segmental femoral bone defects after tumor resection. The defects were reconstructed with one-barrel fibula flap with a lateral locking plate. Stress fracture occurred in two patients. However, bone union was obtained in all patients. The mean bone union time was 24 months, the delay union might be affected by the multimodal treatment for the tumors. No donor site complications were reported.

So, which method should we choose, the one-barrel, folded-barrel or double fibula grafts? It has been reported that the incidence of stress fracture for one-barrel fibula grafts ranging from 20–40% within 1 year, especially for the bone defect of lower extremity[15, 16]. One-barrel fibula graft provides sufficient biomechanical and bone support for long bone defects including humerus, radius and ulna[17]. Double or folded fibula grafts were chosen when intermediate stress loads were applied to the resection site[18]. This method did not increase the number of microvascular anastomose, however, the twice fibula support greatly increases the strength of local mechanical support[14]. Liang[16] reconstructed the subtrochanteric bone defects with folded free vascularized fibular grafts. All cases achieved bone union and the average bone union time was 5.4 months. The results showed that FVFG was an efficient method in achieving bone union, reducing risks of complications including stress fracture and malunion. Thus, for the reconstruction of femoral bone defects, folded or double-strut fibular grafts transfer may be more appropriate by withstanding the high mechanical stress.

The conventional concept is that vascularized bone graft is best indicated for bone defects without inflammation in aseptic wounds. However, the timing of vascularized bone graft for open fractures with bone defects is still controversial[16, 19]. The premise of one-stage vascularized bone graft is limited contaminated wound, the radical debridement and the effective antibiotics control. If this premise could not be achieved, it is suggested that the vascularized bone graft should be carried out after the wound healing for 3–6 months. For the management of chronic infectious bone defect, elimination of infection is the first priority. Debridement combined with antibiotics will transform infectious bone defect into non-infectious bone defect. Three to six months after the elimination of infection, bone defects could be managed by vascularized bone graft.

This report is a retrospective review of the clinical cases. Some deficiencies should not be ignored. First, owing to the lower incidence and the diversity of the treatments, only 12 patients were included. This may primarily confirm the efficiency and safety of the folded free vascularized fibula bone graft. Secondly, although rigid including and excluding criteria were followed, clinical heterogeneity including different injury factors, infection, defect range and location should also be noted. Finally, there is no control group. This is partially due to no golden standard treatment for femoral bone defect.

Conclusion

Through this treatment method, patients can achieve one-time operation to reconstruct the bone defect of the affected limb. The course of treatment is short while the process of postoperative rehabilitation and fracture healing is facilitated. However, the compliance of patients after operation is also very important to avoid the occurrence of complications. In segmental bone defect of femor, folded free fibula transplantation can be a good candidate as a reconstructive option.

Declarations

Ethics approval and consent to participate:

This retrospective report has been approved by Ethics Committee of Zhongnan Hospital (No. 2020107). Informed consent was obtained for all cases.

Consent for publication:

Yes

Availability of data and materials:

The datasets used and analysed during the current study are available from the corresponding author on reasonable request.

Competing interests:

The authors declare that they have no competing interests.

Funding:

The study was supported by the Second Medical Leading Talents Project of Hubei Province (LJ20200405).

Authors' contributions:

YAX was responsible for designing the retrospective report. LZH and WYF was responsible for extracting and analyzing data and conducting the search. YAX, QBW, JC and LZH completed the surgeries of included cases. LZH and WYF draft the manuscript. QBW and JC contributed prepared the manuscript. All authors read and approved the final manuscript.

Acknowledgements:

Not applicable.

References

1. Azi ML, Aprato A, Santi I, Kfuri MJ, Masse A, Joeris A. Autologous bone graft in the treatment of post-traumatic bone defects: a systematic review and meta-analysis. BMC Musculoskelet Disord. 2016; 17: 465.
2. Borzunov DY, Shastov AL. Mechanical solutions to salvage failed distraction osteogenesis in large bone defect management. Int Orthop. 2019; 43: 1051-9.
3. Chimutengwende-Gordon M, Mbogo A, Khan W, Wilkes R. Limb reconstruction after traumatic bone loss. Injury. 2017; 48: 206-13.
4. Chotel F, Nguiabanda L, Braillon P, Kohler R, Berard J, Abelin-Genevois K. Induced membrane technique for reconstruction after bone tumor resection in children: a preliminary study. Orthop Traumatol Surg Res. 2012; 98: 301-8.
5. Claxton MR, Shirley MB, Bakri K, Rose PS, Moran SL, Houdek MT. Utility of the Free Vascularized Fibula Flap to Reconstruct Oncologic Defects in the Upper Extremity. Anticancer Res. 2020; 40: 2751-5.
6. Egol KA, Nauth A, Lee M, Pape HC, Watson JT, Borrelli JJ. Bone Grafting: Sourcing, Timing, Strategies, and Alternatives. J Orthop Trauma. 2015; 29 Suppl 12: S10-4.
7. Erdmann D, Bergquist GE, Levin LS. Ipsilateral free fibula transfer for reconstruction of a segmental femoral-shaft defect. Br J Plast Surg. 2002; 55: 675-7.
8. Fung B, Hoit G, Schemitsch E, Godbout C, Nauth A. The induced membrane technique for the management of long bone defects. Bone Joint J. 2020; 102-B: 1723-34.
9. Gage J, Liporace A, Egol A, McLaurin M. Management of Bone Defects in Orthopedic Trauma. Bull Hosp Jt Dis (2013). 2018; 76: 4-8.
10. Lee JE, Kim MB, Han DH, Pyo SH, Lee YH. One-Barrel Microsurgical Fibula Flap for Reconstruction of Large Defects of the Femur. Ann Plast Surg. 2018; 80: 373-8.
11. Li Z, Yu A, Qi B, Pan Z, Ding J. Flow-Through Free Fibula Osteocutaneous Flap in Reconstruction of Tibial Bone, Soft Tissue, and Main Artery Segmental Defects. Ann Plast Surg. 2017; 79: 174-9.
12. Liang K, Xiang Z, Chen S, Cen S, Zhong G, Yi M, et al. Folded free vascularized fibular grafts for the treatment of subtrochanteric fractures complicated with segmental bone defects. J Trauma Acute Care Surg. 2012; 72: 1404-10.
13. Masquelet A, Kanakaris NK, Obert L, Stafford P, Giannoudis PV. Bone Repair Using the Masquelet Technique. J Bone Joint Surg Am. 2019; 101: 1024-36.
14. Morris R, Hossain M, Evans A, Pallister I. Induced membrane technique for treating tibial defects gives mixed results. Bone Joint J. 2017; 99-B: 680-5.
15. Morris R, Hossain M, Evans A, Pallister I. Induced membrane technique for treating tibial defects gives mixed results. Bone Joint J. 2017; 99-B: 680-5.
16. Niethard M, Tiedke C, Andreou D, Traub F, Kuhnert M, Werner M, et al. Bilateral fibular graft: biological reconstruction after resection of primary malignant bone tumors of the lower limb. Sarcoma. 2013; 2013: 205832.

17. Siboni R, Joseph E, Blasco L, Barbe C, Bajolet O, Diallo S, et al. Management of septic non-union of the tibia by the induced membrane technique. What factors could improve results? Orthop Traumatol Surg Res. 2018; 104: 911-5.
18. Song HR, Kale A, Park HB, Koo KH, Chae DJ, Oh CW, et al. Comparison of internal bone transport and vascularized fibular grafting for femoral bone defects. J Orthop Trauma. 2003; 17: 203-11.
19. Tong K, Zhong Z, Peng Y, Lin C, Cao S, Yang Y, et al. Masquelet technique versus Ilizarov bone transport for reconstruction of lower extremity bone defects following posttraumatic osteomyelitis. Injury. 2017; 48: 1616-22.

Table

Table 1 The general information of included cases.

Case	Gender (male/female)	Age (years)	Diagnosis	Complicated with infection	Defect size (cm)	Fixation	Follow-up (months)
1	Male	20	Fibrous dysplasia of left femur	No	5	Plate	99
2	Male	25	Infectious bone defect of left femur	Yes	9	Plate	90
3	Male	20	Infectious bone defect of left femur	Yes (MRSA)	5	Plate	24
4	Male	58	Bone defect of right femur	No	10	Plate	24
5	Male	9	Pathological fracture of right femur	No	3	Plate	40
6	Male	28	Right femoral bone cyst	No	6	Plate	37
7	Female	53	Synovial sarcoma of left femur	No	8	Plate	48
8	Male	24	Pathological fracture of left femur, non-ossifying fibroma	No	6	External fixator	96
9	Male	6	Infectious bone defect of right femur	Yes	-	External fixator	130
10	Male	9	Aneurysmal bone cyst of right femur, pathological fracture	No	5	Plate	15
11	Male	43	Bone defect of right femur	No	-	External fixator	29
12	Female	15	Giant cell tumor of right femur, pathological fracture	No	5	Plate	67

Figures

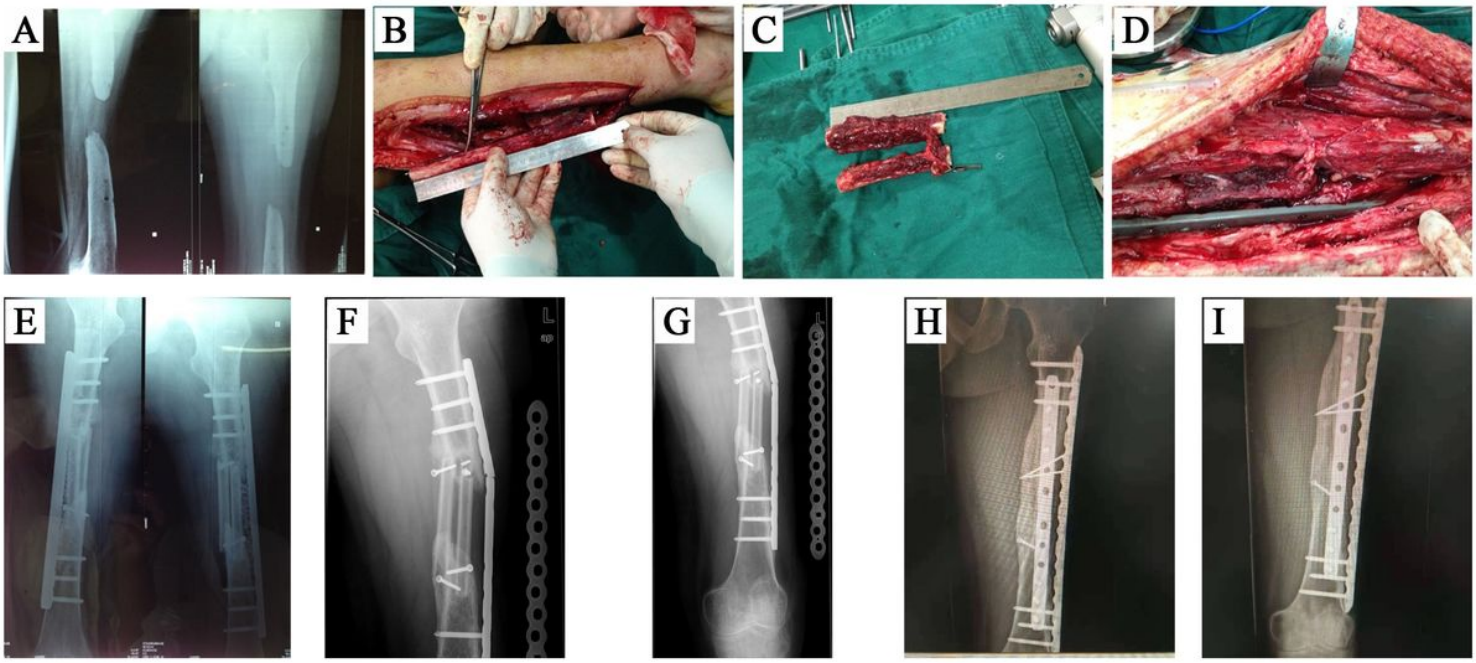

Figure 1

A 25-year-old man suffered 9 cm femoral bone defect after several debridement operations (A). Folded vascularized fibular graft with internal fixation was performed (B, C, D, E). After 8 months, the X-ray showed internal fixation failure (F, G). Internal fixation exchange and iliac bone graft were performed and the bone healed smoothly (H, I).