# A Modified Minimally Invasive Osteotomy for Hallux Valgus Allows Reduction of Malpositioned Sesamoid Bones

**Ezequiel Palmanovich**
Meir Medical Center
**Nissim Ohana**
Meir Medical Center
**Omer Slevin**
Meir Medical Center
**Viktor Feldman**
Meir Medical Center
**Yaron Brin**
Meir Medical Center
**Meir Nyska**
Tel Aviv University Sackler Faculty of Medicine
**David Segal** ( dudisegal@gmail.com )
Meir Medical Center https://orcid.org/0000-0002-2476-0739

**Research article**

**Keywords:** Hallux Valgus, Distal Metatarsal Osteotomy, Minimally Invasive Chevron and Akin, Metatarsal Sesamoid Bones, Reduction

**Posted Date:** August 19th, 2020

**DOI:** https://doi.org/10.21203/rs.3.rs-60890/v1

# Abstract

**Background:** Current minimally invasive distal metatarsal osteotomy for hallux valgus (HV) is V-shaped, which prevents correcting the rotational metatarsal head deformity and reduction of sesamoid bones.

**Methods:** We retrospectively reviewed the records of 53 patients that underwent HV surgery by a single surgeon from 2017 to 2019 to compare outcomes of three techniques: open chevron osteotomy (n=19), minimally invasive V-shaped osteotomy (n=18), and a modified, straight minimally invasive osteotomy (n=16). Sesamoid position was graded using the Hardy and Clapham method based on standing radiographs.

**Results:** Postoperative sesamoid position scores were significantly lower (better) following the modified osteotomy, compared with the two other techniques (1.44±0.81 vs 3.74±1.48 and 4.61±1.09, $P<0.001$), and mean change in score was greater ($P<0.001$). The modified technique yielded the largest improvements in inter-metatarsal and HV angles ($P<0.05$).

**Conclusion:** The modified minimally invasive osteotomy was superior in the correction of HV deformity in all planes, including sesamoid reduction.

Level of Evidence**:** IV


# Introduction

Hallux valgus (HV) surgery, also known as bunion surgery, is a common procedure that is performed by foot and ankle surgeons.[1][2] The patients present with a painful medial bump, medial deviation of the first ray, and lateral deviation and pronation of the big toe.[3] Over the years, more than 150 open surgery techniques to correct this deformity have been described.[2] In recent years, there has been a conceptual change regarding bunion surgery[4] and minimally invasive approaches have become very popular outside the USA.[1] The main advantages of these new techniques are lower morbidity and shorter recovery time.[5] However, the reported outcomes of these procedures have varied.[1, 6–9] Among these techniques, the minimally invasive chevron and akin (MICA) procedure, which was described primarily by Vernois and Redfern,[9] has become widely used. The main advantage of this procedure is that it is extra-articular, which probably reduces the incidence of postoperative complications affecting range of motion and plantar flexion power.

The success rate of HV surgeries has been correlated with the preoperative severity of the deformity. HV angles (HVA) larger than 37 or 40 degrees have been reported to be a risk factor for reccurence.[10][11] However, the HVA represents only one aspect of a three-dimensional deformity. As the first metatarsal bone (MT1) shifts medially, the tendon and ligament insertions change their orientations. As a result, the generated muscle forces abduct and pronate the hallux and rotate the MT1 internally. The MT1 head shifts further medially with respect to the hallux flexors, where the sesamoid bones are embedded. Consequently, the sesamoid bones are repositioned laterally and drift dorsally. Up to 88% of HV cases

present with an internally malrotated hallux on clinical examination.[12] The laterally displaced sesamoid bones can be clearly visualized on a dorsoplantar x-ray radiograph. Thus, in addition to the preoperative HVA, deformity recurrence has also been associated with an incomplete reduction of the laterally displaced sesamoid bones.[12] Unreduced sesamoid bones have also been associated with joint arthritis and pain while walking.[13, 14] Therefore, proper reduction of the sesamoid bones is essential in HV surgery.

As described by Vernois and Redfern, the minimally invasive distal metatarsal osteotomy is V-shaped. This configuration does not allow the surgeon to correct the rotational deformity of the MT1 head. Recently, we have developed a modification in which a straight osteotomy, perpendicular to the MT1 shaft, is done instead of the V-shaped cut (Fig. 1). This allows us to derotate the MT1 head externally and, thereby, to reduce the sesamoid bones into their normal position under the MT1 head. In this study, we compared the postoperative sesamoid bones position in three different surgical techniques: open chevron, minimally invasive V-shaped osteotomy, and the modified “straight” minimally invasive osteotomy, with aim to determine the optimal method for sesamoid bone reduction.

# Methods

We retrospectively reviewed the records of 53 patients that underwent HV surgery by a single surgeon (initials will be added in the unblinded manuscript) from 2017 to 2019. Patients were operated using one of three different surgical techniques. During 2017, an open chevron osteotomy was performed on 170 patients with mild to moderate HV, based on Nyska classification.[15] The last 19 patients that were operated by this method during 2017 were included in "group C" (“C” for chevron). During 2018, a minimally invasive V-shaped osteotomy (MICA) was performed on 18 HV patients, who were assigned to "group V". In "group M" (for modified) we included 16 HV patients that were operated at the end of 2018 and through 2019 by a modified, "straight" minimally invasive osteotomy (Figs. 1,2,3).

We included patients (male or female) who had a mature bone structure (closed physis on preoperative x-ray radiographs), between the ages of 15 and 99 years, who had had an HV deformity, underwent a surgery by one of the abovementioned techniques and had had preoperative weightbearing orthogonal foot radiographies. The exclusion criteria were patients with immature bones, patients that had previously underwent multiple foot surgeries, Charcot foot or other structural foot abnormalities beside HV, metatarsus adductus associated with HV and a recent trauma to the foot. We defined HV as an inter-metatarsal angle (IMA) greater than 8 degrees. The indication for surgery was pain that was associated with a diagnosed HV and could not be alleviated by inoperative measures.

Pre- and postoperative standing x-ray radiographs were evaluated for every patient. We used radiographs that were obtained at a mean of 12 ± 3 weeks postoperatively. Pre- and postoperative HVA and IMA were measured by a single surgeon (initials will be added in the unblinded manuscript) using PACS software (Carestream Vue PACS, Fujifilm Corporation, JAPAN).[15] We used the Hardy and Clapham method[16] to assess the position of the medial sesamoid bone on an AP radiograph of the foot. Briefly, the position of

the medial sesamoid relative to the centerline of the first metatarsal on the dorsoplantar plane was determined. Position I was considered normal, position IV was defined when the first metatarsal midline crossed the medial sesamoid midline, and a displacement (positions V-VII) was graded according to how far medially the sesamoid was located (Fig. 4).

The minimally invasive surgeries were performed by a single surgeon (initials will be added in the unblinded manuscript). The original percutaneous chevron osteotomy was described previously.[9] In the modification presented herein, the osteotomy was performed in a straight line, perpendicular to the metatarsal axis on the sagittal view, as shown in Fig. 1. Before fragment fixation, we supinated the big toe, pulling the MT1 head along with it, until the sesamoids were shown by fluoroscopy to return to the normal position under the metatarsal head. Then, the K-wires were inserted into the metatarsal head and were followed by cannulated screws fixation (Fig. 5). The postoperative regimen included immediate weight bearing with Flat DARCO shoe (MedSurg™, Huntingon WV). During the first follow-up visit, at two weeks, dressings were changed and weightbearing x-rays were taken. At 6 weeks K-wires were removed when necessary, and at twelve weeks weightbearing x-rays were taken again.

# Statistical analysis

SPSS 25 software (Chicago, IL) was used for the statistical analysis. Descriptive statistics were applied to the data. The Fisher's exact test and the Student's *t*-test were used to compare categorical and continuous variables, respectively. An ANOVA, followed by a post-hoc pairwise analysis when needed, was used in order to compare the pre- and postoperative IMA, HVA and sesamoid bone position among the three patient groups. A paired samples *t*-test was applied in order to compare the IMA and HVA and sesamoid bone positions before and after surgery within each patient group. An alpha of 0.05 was considered significant.

# Results

The age, sex, and radiographic measurements of the study population are presented in Table 1. There were no significant differences in demographic variables or in IMA among the three study groups ($P > 0.05$). The HVA was found to be the narrowest (i.e., a smaller deformity) in group C (open chevron osteotomy) ($P < 0.01$).

Table 1
Demographic and radiographic characteristics of patients that were operated for hallux valgus by three different methods (*n* = 53).

| | **Open chevron osteotomy (n = 19)** | **V-shaped MICA (n = 18)** | **Modification osteotomy (n = 16)** | **Total (n = 53)** | **Significance (P-value)** |
|---|---|---|---|---|---|
| Age (years; mean ± SD, range) | 61.11 ± 10.61, 37–74 | 56.72 ± 15.04, 17–78 | 54.31 ± 20.66, 15–72 | 57.66 ± 15.6, 15–78 | 0.4 |
| Sex (male; n, %) | 3 (15.8%) | 1 (5.6%) | 3 (18.8%) | 7 (13.2%) | 0.6 |
| Side (right; n, %) | 9 (47.4%0 | 12 (66.7%) | 6 (37.5%) | 27 (50.9%) | 0.24 |
| **Preoperative** | | | | | |
| **Sesamoid position*** | **4.63 ± 1.26** | **5.11 ± 0.96** | **5.44 ± 1.46** | **5.04 ± 1.26** | 0.16 |
| IMA | 13.63 ± 2.79 | 13.67 ± 2.97 | 13.63 ± 2.03 | 13.64 ± 2.6 | 1 |
| HVA | 30.58 ± 7.01 | 35.67 ± 8.04 | 38.75 ± 7.02 | 34.77 ± 8 | < 0.01 |
| **Postoperative** | | | | | |
| **Sesamoid position** | **3.74 ± 1.48** | **4.61 ± 1.09** | **1.44 ± 0.81** | **3.34 ± 1.75** | < 0.001 |
| IMA | 6.53 ± 2.86 | 5.06 ± 2.6 | 3.25 ± 2.35 | 5.04 ± 2.9 | < 0.01 |
| HVA | 18.79 ± 7.44 | 20.17 ± 6.61 | 15.19 ± 6.4 | 18.17 ± 7.04 | 0.1 |
| Difference (mean ± SD, P-value) | | | | | |
| **Sesamoid position** | **0.89 ± 0.99, 0.001** | **0.5 ± 0.71, 0.08** | **4 ± 1.37, < 0.001** | **1.7 ± 1.85, < 0.001** | |
| IMA | 7.11 ± 2.77, < 0.001 | 8.61 ± 2.87, < 0.001 | 10.38 ± 3.69, < 0.001 | 8.6 ± 3.3, < 0.001 | |
| HVA | 11.79 ± 9.66, < 0.001 | 15.5 ± 8.51, < 0.001 | 23.65 ± 7.13, < 0.001 | 16.6 ± 9.7, < 0.001 | |

* Sesamoid bone position is scored on a 7 point scale, which was originally presented by Hardy and Clapham.[7]

Abbreviations: SD, standard deviation; IMA, inter-metatarsal angle; HVA: hallux valgus angle.

The mean sesamoid bone position score before surgery was 5.04 ± 1.26 and did not differ significantly among the three groups (P = 0.16). Following surgery, this score was found to be significantly lower in group M (1.44 ± 0.81, P < 0.001), as compared with group C (3.74 ± 1.48) and group V (4.61 ± 1.09). While the sesamoid bone position score improved by 4 ± 1.37 points in group M, the change was only 0.89 ± 0.99 and 0.5 ± 0.71 points in groups C and V, respectively (P < 0.001) (Fig. 6). In addition, the largest improvement in IMA and HVA was obtained in group M (P < 0.01, Table 1).

# Discussion

In this study, we have shown that by the application of a modified, “straight” osteotomy through a minimally invasive approach we were able to correct the IMA and HVA in HV patients and, simultaneously, reduce the laterally displaced sesamoid bones into a non-pathological position. The modified osteotomy enabled us to address the three-dimensional configuration of the deformity and to correct its rotational aspect. As a result, more effective sesamoid reduction was achieved as compared with open chevron osteotomy or the original V-shaped MICA.

The importance of MT1 rotation during HV surgery has gained attention over the years.[17] Residual postoperative lateral displacement of sesamoids has been previously associated with HV recurrence,[10–12, 17] walking pain and arthritis.[14] Accordingly, several attempts have been made to correct the rotational element of the HV deformity and reduce the sesamoid bones into their natural position. Nyska et al.[18] studied different Ludloff osteotomy angles in order to find the optimal cut in which a correction of the pronation could be obtained. Wegner et al.[17] proposed an osteotomy technique that aimed to address the three-dimensional complexity of the HV deformity by a proximal rotational metatarsal osteotomy (PROMO). Okuda presented a proximal supination osteotomy that would simultaneously correct both the varus and the pronation of the MT1.[19] Although effective, these methods were described as open surgery techniques, thus lacking the benefits of the minimally invasive approach.

The minimally invasive technique that was introduced by Vernois and Redfern[9] is composed of three basic elements: A percutaneous V-shaped distal osteotomy, a lateral displacement of the head and a fixation of the new fragment configuration. These steps can be accompanied by a bunion osteo-resection and an akin osteotomy, and are conducted via skin cuts that are several millimeters long. The advantages of a minimally invasive technique are lower morbidity and shorter recovery time, less pain, and a better range of motion of the metatarsophalangeal joint. [5] In addition, since the skin cuts are minimal, there are less skin compilations and smaller scars.[20] The V-shaped osteotomy[9] enables to correct both mild and severe deformities, but it restricts the surgeon to a single-plane correction. The derotation of the MT1 head and, thereby, sesamoid position correction are not possible in cases where the metatarsophalangeal center of rotation shift was insufficient for sesamoid reorientation. The modification that we describe in this article eliminates the restriction that was formed by the V-shaped osteotomy and allows the correction of sesamoid bone position by a derotation of the MT1 head. In this series of 53 patients, the straight osteotomy was found to be the only technique by which we obtained a successful sesamoid

reduction. This method allowed us to combine the benefits of minimally invasive technique with the possibility to correct the three-dimensional HV configuration.

The V-shaped osteotomy offers two main advantages. First, the V shape creates a larger contact area between the two bone fragments, as compared with a straight cut. Moreover, the V-Y is presumed to be a more stable configuration compared with two flat-shaped bones, which could slide over each other. Nevertheless, we feel that these benefits of the original method were outweighed by the ability to manipulate the MT1 head in all planes in order to obtain an optimal correction. Since the two fragments were eventually fixated by two cannulated screws, the shearing and rotational movements between the two fragments were eliminated.

This study had several limitations. Its retrospective nature prevented prospective patient randomization and allocation into three groups. We used standing x-ray radiographs for sesamoid evaluation, although standing CT scans could have better demonstrated the exact sesamoid location.[17] In our hospital this is the common practice for these patients and, therefore, this was the imaging modality that was available for us in this retrospective series. Because this was a solely radiographic study, we did not present the clinical outcomes or union rates of our patients. Since the clinical follow-up is of great interest, we are planning a future study in which these data will be presented in detail.

In conclusion, the “straight” osteotomy modification of the MICA procedure allowed us to reduce the HV deformity in all planes, and was the only method by which we were able to reduce the sesamoid bones into their normal position.

# Declarations

- Ethics approval and consent to participate: The study was approved by the local institutional review board committee. No consent to participate was mandated.
- Consent for publication: where relevant, a consent for publication was obtained.
- Availability of data and material: additional data will be available per request.
- Competing interests: There are no competing interests to declare.
- Funding: This research did not receive any specific grant from funding agencies in the public, commercial, or not-for-profit sectors.
- Authors' contributions
- Acknowledgements: We thank Mr. Nitzan Konstantin for his help with writing this manuscript.

# References

1. De Prado M. Minimally invasive foot surgery: A paradigm shift. Minim. Invasive Surg. Foot Ankle. Springer London; 2011. p. 3–11.

2. Ferrari J, Higgins JPT, Prior TD. Interventions for treating hallux valgus (abductovalgus) and bunions. Cochrane database Syst. Rev. [Internet]. 2004 [cited 2020 Mar 11];CD000964. Available from: http://www.ncbi.nlm.nih.gov/pubmed/14973960
3. Fraissler L, Konrads C, Hoberg M, Rudert M, Walcher M. Treatment of hallux valgus deformity. EFORT Open Rev. British Editorial Society of Bone and Joint Surgery; 2016;1:295–302.
4. Palmanovich E, Myerson MS. Correction of moderate and severe hallux valgus deformity with a distal metatarsal osteotomy using an intramedullary plate [Internet]. Foot Ankle Clin. W.B. Saunders; 2014 [cited 2020 Mar 11]. p. 191–201. Available from: http://www.ncbi.nlm.nih.gov/pubmed/24878409
5. Maffulli N, Longo UG, Marinozzi A, Denaro V. Hallux valgus: effectiveness and safety of minimally invasive surgery. A systematic review. Br. Med. Bull. [Internet]. 2011 [cited 2020 Mar 11];97:149–67. Available from: http://www.ncbi.nlm.nih.gov/pubmed/20710024
6. Giannini S, Bevoni R, Vannini F, Cadossi M. Hallux Valgus Surgery: The Minimally Invasive Bunion Correction. Minim. Invasive Surg. Orthop. Springer New York; 2010. p. 463–71.
7. Magnan B, Pezzè L, Rossi N, Bartolozzi P. Percutaneous distal metatarsal osteotomy for correction of hallux valgus. J. Bone Jt. Surg. - Ser. A [Internet]. 2005 [cited 2020 Mar 11];87:1191–9. Available from: http://www.ncbi.nlm.nih.gov/pubmed/15930526
8. Malagelada F, Sahirad C, Dalmau-Pastor M, Vega J, Bhumbra R, Manzanares-Céspedes MC, et al. Minimally invasive surgery for hallux valgus: a systematic review of current surgical techniques. [Internet]. Int. Orthop. Springer Verlag; 2019 [cited 2020 Mar 11]. p. 625–37. Available from: http://www.ncbi.nlm.nih.gov/pubmed/30218181
9. Vernois J, Redfern DJ. Percutaneous Surgery for Severe Hallux Valgus [Internet]. Foot Ankle Clin. W.B. Saunders; 2016 [cited 2020 Mar 11]. p. 479–93. Available from: http://www.ncbi.nlm.nih.gov/pubmed/27524702
10. Deenik AR, De Visser E, Louwerens JWK, Malefijt MDW, Draijer FF, De Bie RA. Hallux valgus angle as main predictor for correction of hallux valgus. BMC Musculoskelet. Disord. 2008;9.
11. Okuda R, Kinoshita M, Yasuda T, Jotoku T, Shima H, Takamura M. Hallux valgus angle as a predictor of recurrence following proximal metatarsal osteotomy. J. Orthop. Sci. [Internet]. Springer Tokyo; 2011 [cited 2020 Mar 11];16:760–4. Available from: http://www.ncbi.nlm.nih.gov/pubmed/21818604
12. Okuda R, Kinoshita M, Yasuda T, Jotoku T, Kitano N, Shima H. Postoperative incomplete reduction of the sesamoids as a risk factor for recurrence of hallux valgus. J. Bone Jt. Surg. - Ser. A [Internet]. Journal of Bone and Joint Surgery Inc.; 2009 [cited 2020 Mar 11];91:1637–45. Available from: http://www.ncbi.nlm.nih.gov/pubmed/19571086
13. Katsui R, Samoto N, Taniguchi A, Akahane M, Isomoto S, Sugimoto K, et al. Relationship between Displacement and Degenerative Changes of the Sesamoids in Hallux Valgus. Foot Ankle Int. [Internet]. SAGE Publications Inc.; 2016 [cited 2020 Mar 11];37:1303–9. Available from: http://www.ncbi.nlm.nih.gov/pubmed/27530982

14. Suzuki J, Tanaka Y, Takaoka T, Kadono K, Takakura Y. Axial radiographic evaluation in hallux valgus: evaluation of the transverse arch in the forefoot. J. Orthop. Sci. [Internet]. Springer Japan; 2004 [cited 2020 Mar 11];9:446–51. Available from: http://www.ncbi.nlm.nih.gov/pubmed/15449119
15. Nyska M. Principles of first metatarsal osteotomies. Foot Ankle Clin. [Internet]. 2001 [cited 2020 Mar 11];6:399–408. Available from: http://www.ncbi.nlm.nih.gov/pubmed/11692489
16. Hardy RH, Clapham JCR. OBSERVATIONS ON HALLUX VALGUS. J. Bone Joint Surg. Br. [Internet]. 1951 [cited 2020 Mar 11];33-B:376–91. Available from: http://online.boneandjoint.org.uk/doi/10.1302/0301-620X.33B3.376
17. Wagner P, Ortiz C, Wagner E. Rotational Osteotomy for Hallux Valgus. A New Technique for Primary and Revision Cases. Tech. foot ankle Surg. [Internet]. Lippincott Williams and Wilkins; 2017 [cited 2020 Mar 11];16:3–10. Available from: http://www.ncbi.nlm.nih.gov/pubmed/28286430
18. Nyska M, Trnka H-J, Parks BG, Myerson MS. The Ludloff metatarsal osteotomy: guidelines for optimal correction based on a geometric analysis conducted on a sawbone model. Foot ankle Int. [Internet]. 2003 [cited 2020 Mar 11];24:34–9. Available from: http://www.ncbi.nlm.nih.gov/pubmed/12540079
19. Okuda R. Proximal Supination Osteotomy of the First Metatarsal for Hallux Valgus [Internet]. Foot Ankle Clin. W.B. Saunders; 2018 [cited 2020 Mar 11]. p. 257–69. Available from: http://www.ncbi.nlm.nih.gov/pubmed/29729800
20. Frigg A, Zaugg S, Maquieira G, Pellegrino A. Stiffness and Range of Motion After Minimally Invasive Chevron-Akin and Open Scarf-Akin Procedures. Foot Ankle Int. [Internet]. SAGE Publications Inc.; 2019 [cited 2020 Mar 11];40:515–25. Available from: http://www.ncbi.nlm.nih.gov/pubmed/30688526

# Figures

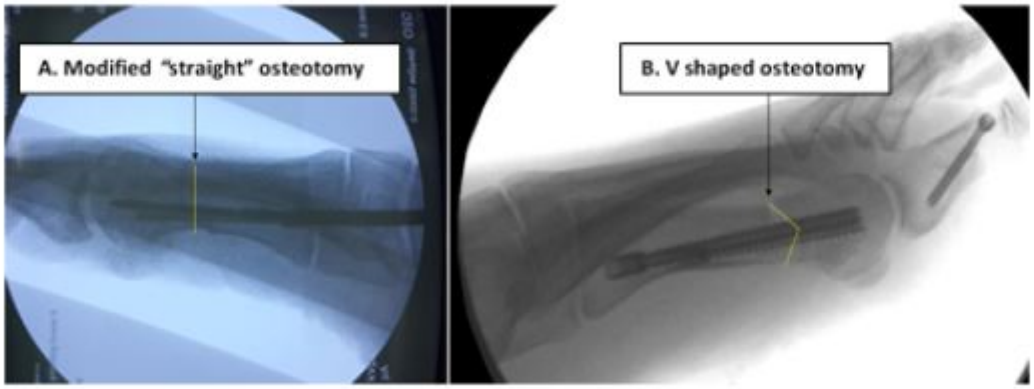


**Figure 1**

Minimally invasive osteotomy for hallux valgus. A. Modified straight osteotomy. B. V-shaped osteotomy.


**Figure 2**

Postoperative X-ray radiographs following hallux valgus surgeries. A. Open chevron osteotomy. B. Minimally invasive modified straight osteotomy. C. Minimally invasive modified straight osteotomy with akin procedure.


**Figure 3**

Minimally invasive osteotomy for hallux valgus. Av and Bv: Pre- and postoperative radiographs of V-shaped osteotomy, respectively. Am and Bm: Pre- and postoperative radiographs of modified straight osteotomy, respectively.

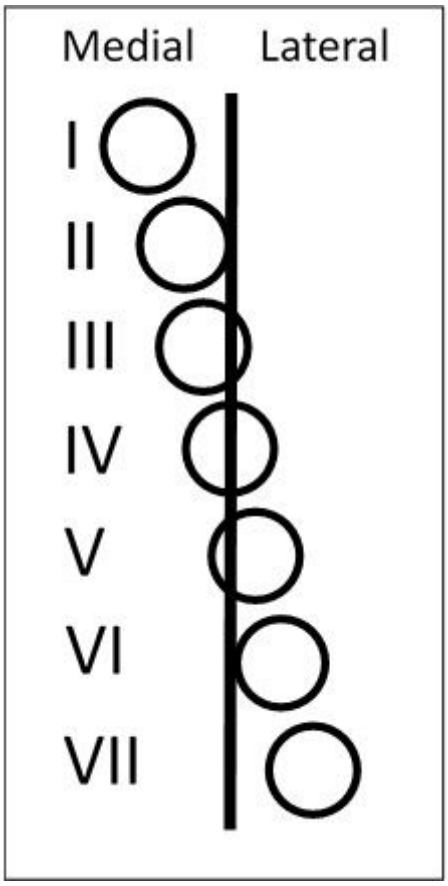


**Figure 4**

Drawing of the sesamoid bone position score introduced by Hardy and Clapham.7 The position of the medial sesamoid bone is determined in relation to the first metatarsal bone midline.

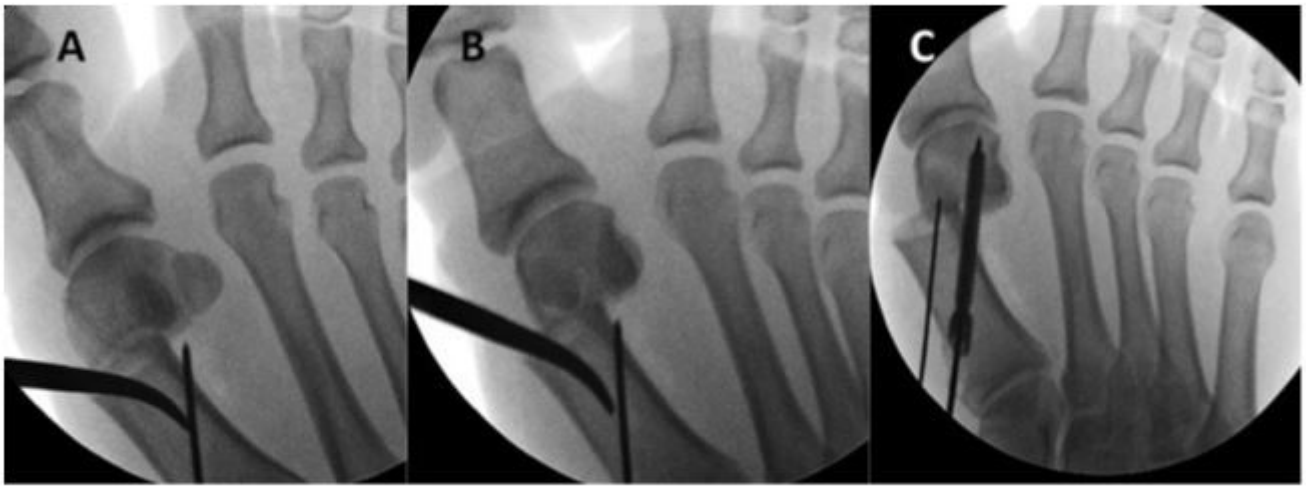


**Figure 5**

Intraoperative rotation of the metatarsal head on fluoroscopy. A. A pronated metatarsal head with subluxed sesamoid bones. B. Derotated (supinated) metatarsal head with reduced sesamoid bones. C. Screw fixation.

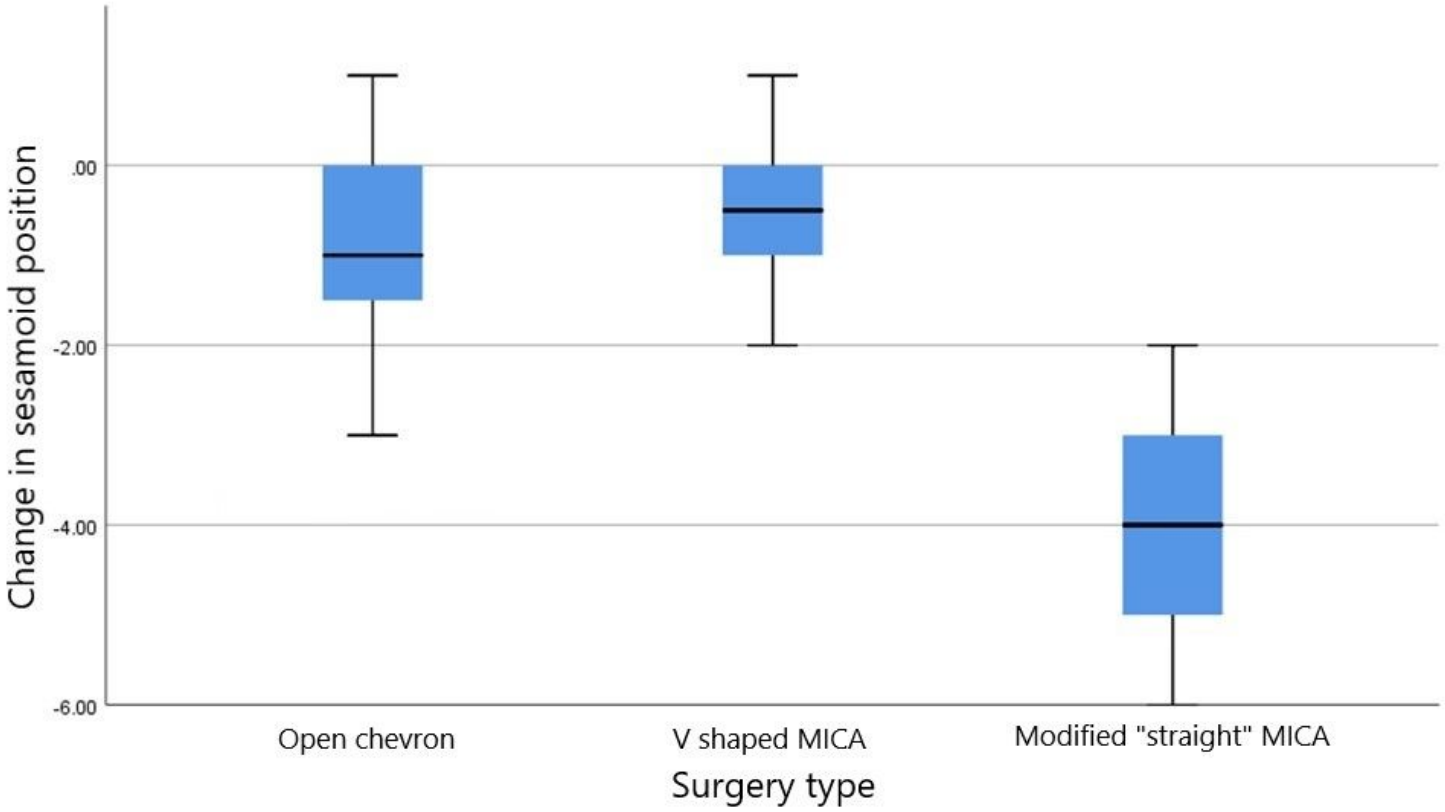


**Figure 6**

Box plot graph showing the change in sesamoid bone position following three types of hallux valgus surgeries. The sesamoid bone position was scored on a 7-point scale. Horizontal middle line denotes the median, whiskers represent the maximum and minimum values.