Marginal integrity of five different root sealers in retrograde filling following apicoectomy: An in vitro analysis with scanning electron microscope and micro-radiography

Yahya Acil
Christian-Albrechts-Universitat zu Kiel

Pinar Kiymet Karataban (pkarataban@hotmail.com)
Bahcesehir Universitesi https://orcid.org/0000-0002-2019-5728

Aydin Gülses
Christian-Albrechts-Universitat zu Kiel

Mustafa Ayna
Dürsburg

Jörg Wiltfang
Christian-Albrechts-Universitat zu Kiel

Research article

Keywords: apicoectomy, marginal gap, microradiography, scanning electron microscope

Posted Date: October 3rd, 2019

DOI: https://doi.org/10.21203/rs.2.15533/v1

Abstract

Objective The aim was to clarify the physical properties of five different root canal sealers used as retrograde filling materials on the resected root apex following apicoectomies.

Materials and Methods Apical resection was performed on 100 canals of 50 maxillary premolars in slaughtered pigs. The root end of 24 canals were retrogradely filled with Diaket ™, 37 root canals with Super-EBA ™ including 18 with Super-EBA ™ Regular and 19 with Super-EBA ™ fast, 20 canals with ProRoot® MTA and 19 canals with AH-Plus ™. For quantitative examination, scanning electron microscope (SEM) analysis and for qualitative examination microradiography was performed.

Results Diaket ™ achieved the best results with an overall average of 4.872 microns gap value. The mean values of marginal gap widths of AH - Plus ™ and Super - EBA ™ were almost the same magnitude 8.044 microns and 9.951 microns respectively, followed by Super - EBA ™ Regular with 11,560 microns. Highest marginal gap value was detected in ProRoot® MTA with 18.343 microns ($p < 0.001$) .

Conclusion According to the limited knowledge of the current in vitro study Diaket ™ achieved the best results compared to the other materials. Additional clinical studies with long term follow up period might help to determine the most appropriate root-end filling material.Clinical Relevance Among five different root canal sealers used as retrograde filling materials, in terms of its marginal integrity and material properties, Diaket ™ can be referred as the most suitable material for retrograde obturation.

Background

Recurrent periapical infection poses substantial challenge in dental practice. However, the use of novel methods and materials in periapical surgery has increased the survival rate of the teeth with periapical disease.[1] Periapical surgery comprises a host of procedures in the treatment of persistent contamination of the apical region, when traditional endodontic therapy has failed[2]. The aim of this procedure is to resect the apical root end with lateral accessory canals, remove the adjacent granulation tissues and to obtain well sealed apical region with a biocompatible root-end filling material.[3] The quality and sealing ability of the retrograde filling material plays an important role of the success of the treatment and good prognosis.

A significant number of clinical research have attempted to identify the ideal retrograde filling material. It should be biocompatible and precisely seal the apical region of the root canal to prevent bacterial leakage from the canal to the periapical tissues vice versa.[4–7]

There are variety of materials and systems for retrofilling as;

Endodontic point systems (Silver, Titanium, Ceramic, Acrylic or Gutta percha) that should be used with combination of a sealer. Sealers (Zinc phosphate-, ZOE, Glass ionomer cement, Polyketon-Based cements and Mineral Trioxid Aggregate (MTA) based cements and amalgam, gutta- percha, gold.

Diaket ™ (Espe, Dental-Medizin GmbH & Co. KG, D - 82229 Seefeld) is a polyketone based neutral, organic material which shows a high adhesive strength to dentin. It is radiopaque and dimensionally stable. It solves fats and other organic substances and absorbs remaining moisture on the canal wall during its setting.[8] It is characterized by a high adherence to intracanal walls and it also acts as a disinfectant.[9,10] Diaket ™ is the most evaluated material in the dental literature.

AH - Plus ™ (Dentsply DeTrey GmbH, D - 78467 Konstanz) is a two component epoxy-amine polymer based material. It shows minimal shrinkage during curing, and shows an outstanding long-term dimensional stability.[11,12] Unlike its predecessor, the AH26, there is no free formaldehyde leakage into the adjacent structures.[13]

Super-EBA ™ (Bosworth Company, 7227 North Hamlin Avenue, Skokie, Illinois 60076, USA) is a zincoxide-eugenol (ZOE) based root filling material. It is pH-neutral, radiopaque and has hydrophilic properties[14]. It shows satisfactory long term results regarding marginal leakage. [14,15] It has two different types according to the curing time. The “Fast Set” type can be used for easily accessible operational areas due to its shorter curing time. Retrograde root tips are usually difficult to access, so this material can be used only on a few easily accessible root tips. The “Regular Set” has a wider range of application due to its longer setting time; as it is also suitable for areas that are difficult to access.

ProRoot® MTA (Dentsply Tulsa Dental, 608 Rolling Hills Drive, Johnson City, TN 37604, USA) is mineral trioxide aggregate based, constant form, radiopaque root filling material.[16] The enclosed package contains distilled water and a powder, which forms a colloidal gel after mixing. According to Apaydin et al [17], the material could stimulate hard tissue formation in the adjacent periapical structures. Similar to Diaket ™, the properties of ProRoot® MTA were tested in numerous studies and suggested to be one of the most appropriate material for root-and root-end fillings.[18–20] Due to its high biocompatibility, and regenerative properties ProRoot® MTA resin is proclaimed to be suitable for retrograde root sealing following apicoectomy or intentional replantation.[21,22]

The success of the endodontic treatment depends on the presence of a well sealed apical region to prevent bacterial invasion from the root canal to the surrounding tissues. However, it is not yet possible to define one of the above mentioned materials as “ideal”. The aim of this study was to evaluate the marginal adaptation of five different sealers (Diaket™, AH-Plus™, Super-EBA™ regular, Super-EBA™ fast und ProRoot® MTA) following apicoectomy via scanning electron microscope (SEM) and microradiography in vitro.

Methods

Experimental subjects

The study was performed on 25 fresh cadaveric porcine mandibles of male and female pigs that were obtained from the slaughterhouse in Kiel- Wellsee- Germany. Animals were between seven and nine

months old at the time of slaughter. The heads were stored frozen after decapitation at –21°C and then thawed in the refrigerator at 4°C for 48 hours before the root resection and root canal filling was performed.

Root-end filling materials

Five different root filling materials have been studied; Diaket™, AH-Plus™, Super-EBA™ regular,

Super-EBA™ fast und ProRoot® MTA. (Table 1).

Apicoectomy and root-end filling procedure

Apical resection was performed on 100 canals of 50 maxillary premolars. 48 hours before the operation, frozen pork jaw halves were thawed in the refrigerator at 4°C. They were disinfected with Betaisodona® solution (Mundipharma GmbH, D–65549 Limburg). An incision was made with a no. 11 Scalpel and a full thickness mucoperiosteal flap was reflected. Osteotomy was performed with a ball mill (0.5 mm) under irrigation with isotonic saline solution exposing the apical third of the experimental tooth roots. The root tips were removed 2 - 3 mm away from the apex with a Lindemann cutter in vestibulo-oral direction with an angle of less than 45 °. Retrograde cavities were prepared with dental hand piece (D–88400 Biberach / Riss INTRAmatic, KaVo Dental GmbH,) and washed with 3% H_2O_2 and 70% alcohol and then dried.

The root-end of 24 canals were retrogradely filled with Diaket ™, 37 root canals with Super-EBA ™– (18 with Super-EBA ™ Regular and 19 with Super-EBA ™ fast), 20 canals with ProRoot® MTA and 19 canals with AH-Plus ™. (Table 2) All materials were prepared and applied according to the manufacturers guidelines.

Preparation of the samples for SEM

After completion of the root–end fillings, teeth were osteotomised with hammer and chisel en bloque from the bone segment (Figure 1) and stored in 4% formalin. The teeth were cut in half in vestibulo-oral direction and were placed in in phosphate buffered solution (pH 7.4 to Sörensen KH_2PO_4 / Na_2HPO_4) (Walter GmbH & Co. KG, D–24116 Kiel) for 20 minutes. The procedure was repeated three-times. The samples were trimmed with a wet grinder (Jean Wirtz, D-Düsseldorf Germany) and Siliconkarbitpaper with a grain of 400 in the transverse or longitudinal axis at a predetermined cutting plane, before the surface could be polished to a high gloss with a grain of 1200 - 4000.

Before taking an impression of the roots with Silagum® AV light, an addition-cross linked silicone (DMG Chemical Pharmaceutical Factory GmbH, D–22547 Hamburg Germany), with 30% isopropyl alcohol was

used to clean the surfaces. The impressions were prepared with epoxy resin (Stycast (TE-adhesive technology, D–30165 Hannover Germany) and left at room temperature for 24 hours.

SEM analysis

The replica models were placed on the alluminum specimen stubs (Agar Scientific Ltd., Essex CM24 8

DA, UK) of the SEM. Electronic conductivity has been reached by vapor deposition (sputtering) of the samples with a 20 micron thin gold alloy at a pressure of 0.1 bar and at a voltage of 15 mA for 90 seconds under a vacuum.

To evaluate the samples obtained from the apical portion of the root tips, 60, 190, 320 and 600 fold magnification options were required on the screen of the SEM. To determine the marginal gap value, two points were determined in the area of greatest expansion and the distance was measured in microns.

Preparation of the samples for Microradiography

After completion of the root–end fillings, teeth were osteotomised with hammer and chisel en bloque from the bone segment and stored in 4% formalin. With a band saw (Metabo, D–78822 Nürtingen Germany), the teeth were initially cut in half in vestibulo-oral direction, so that two root canals could be obtained seperately. The preparations were then placed over a period of two days in an embedder (PSI, CH–5232 Villingen) containing an alcohol series (20%, 40%, 60%, 80%, 90%, 2 times 100% for each 45 - 60 minutes and finally 100% for 6 - dehydrated 8 hours) and then were soaked in methacrylate. The samples were placed in a methacrylate solution for another two weeks before they were placed in glasses capped with methacrylate and polymerized with fresh methacrylate solution in water bath at 38°C. The composition of the embedding medium is given in Table 3.

The polymerized samples were first cut with the band saw and the surfaces of the blocks were polished to 4000 with a Siliconcarbitpaper with a grain size of 400, before the cutting plane for the actual recovery preparations was determined. Each sample was cut along its sectional plane with the band saw again, surface was polished, glued to a microscope slide and reduced with a precision hole saw (Leica GmbH, D-64625 Bensheim) to 100–200 micron thickness.

Microradiographic analysis

Via a wet grinding machine (Struers A / S, DK–2610 Rodovre) the samples were refined up to 70 - 110 micron and polished with a Silicon carbitpaper with a grain size of 800 to 4000. The samples were taken from the slide and put on high-resolution Microradiography plates in which the resolution is 2000 lines per millimeter (High Resolution plates (Kodak, Rochester, NY 14650, USA). Subsequently, the exposure was performed in a Mikroradiographiekammer Faxitron 53855A (Hewlett -Packard, McMinnville, OR

97128, USA) at a focus distance of 16 cm. The voltage was set to 25 kV at a power of 3 mAs, exposure time of 6 minutes and 30 seconds for 70 micron samples and up to 10 minutes and 30 seconds for 110 microns film thickness. The exposure time was increased by increments of one minute per 10 microns thickness of the specimen.

The plates were embedded for five minutes in Kodak® HRP developer at 20 ° C under constant movement swung (HRP developers /distilled water: 1/3). In a 1% acetic acid bath, the development was stopped after one minute. For fixation, Kodak® fixer 300A was used for 10 minutes with agitation (Kodak® fixer 3000A / distilled water:1/3). This was followed for 15 minutes by washing with water and a final rinse with Agepon® (400 mL of distilled water and 2 ml Agepon®) for one minute.The plates were air dried and then covered with cover glasses (4 x 4.5 cm) using 1 - 2 drops of n - butyl acetate (xylene substitute) and a drop of Eukitt-air for 24 hours. After a drying period of seven days under an air extractor, the preparations were digitally photographed under a light microscope at a magnification of 1:18. The evaluation was performed using an image editing program (Adobe Photoshop 7.0 for Windows)

Statistical analysis

The statistical analysis was performed by using SPSS for Windows, version 14.0 (SPSS Inc., USA). The continuous variables were analyzed using the Kolmogorov-Smirnov test with respect to their normal distribution. In analysis of the abnormal distribution of the tested variables (Kolmogorov-Smirnov test: $p < 0.05$), non-parametric tests were used.

Since the comparisons template more than two independent, not normally distributed random samples, the H-test was used by Kruskal and Wallis. A p-value <0.05 was taken as statistically significant for all statistical tests. In the graphs, which were also created using SPSS, error bars were used to illustrate the mean values.

Results

SEM

For SEM analsis, 25 maxillary premolars were examined. Overall, root end filling was carried out on 50 canals following apicoectomies: 10 canals with Diaket ™, 10 ™ with AH Plus, 20 with Super - EBA ™ - including 10 with Super - EBA ™ Regular and 10 with Super - EBA ™ - and 10 with ProRoot® MTA.

Axial and transversal cross sectional examinations were performed both on 25 canals.

Diaket ™

Longitudinal cross sections:

In Figure 2a, marginal gap was measured at four points. The values were 1.440 microns and 2.160 microns. Adjacent to the Diaket ™ -root end filling material, small bubbles were observed. This artifacts could be formed during the preparation of the material. In Figure 2b, the lower part of the apical filling margin is to be seen in x320 magnification. No marginal gap was recognized.

Transversal cross sections

Figure 3a, in the sample with retrograde Diaket ™, small bubbles can be seen. These artifacts are due to the production of the replica models. The marginal gap was measured at four points. The measured marginal gaps were sized between 3,820 and 11,500 microns. Figure 3b shows 320x magnification of the right side of the filling margin. The material adheres very well to dentin and shows a complete bonding without a marginal gap.

AH Plus™

Longitudinal cross sections:

Figures 4a and 4b showing root canals with of AH Plus™ retrograde fillings in 60x and 320x magnifications. The artefacts are thought to be formed during preparation of the replica models. The marginal gap sizes varied between 1.210 microns and 7.240 microns.

Transversal cross sections

Four marginal gaps sized between 1,810 and 3,620 microns were measured. Figure 5a and 5b show the filling margin with a very good seal in 60x and 320x magnifications.

Super-EBA™ regular

Longitudinal cross sections:

Figures 6a and 6b showing root canals with Super - EBA ™ regular retrograde fillings in 60x and 320x magnifications. In Figure 6a, only small artefacts (bubbles) can be observed, which are thought to be formed during the preparation of replica models. Moreover, in figures 6a and 6b, longitudinal cut facets and air bubbles in the material can be clearly seen. The measured values ranged between 0.608 microns and 0.540 microns.

Transversal cross sections

In Figure 7a, only small air bubbles could be seen, which are artefacts that formed during the preparation of repica models. The measured gap values were between 1.000 microns and 2,560 microns. Figure 7b is an enlargement of the upper filling margin, on the edge, no gap could be seen.

Super - EBA ™ fast

Longitudinal cross sections:

In Figure 8a, a small bubble in the middle of the specimen and small air pockets in the root end filling material (artefacts) can be seen. Figure 8b shows the left side of filling margin with 320x magnification. The measured gap sizes varied between 1.630 and 2.720 microns.

Transversal cross sections:

In Figure 9a a bubble in the center of the specimen could be observed. Super-EBA™ almost bordered the edges without a gap on all sides of the dentine. Figure 9b shows a 600x magnification of the right filling margin with longitudinal cut facets which wer emerged during polishing of the tooth surface. A marginal gap of 3.410 micron was measured.

ProRoot® MTA

Longitudinal cross sections:

Figures 10a and 10b show a sample in which the root end was filled with ProRoot® MTA in 60x and 320x magnification in the longitudinal section. The root canal is located in the center and at the apical end, an artefact can be seen. In Figure 8b, the top of the filling edge is enlarged. The measured gaps sized between 13.300 and 23.000 microns.

Transversal cross sections:

In the center, on the surface of the root canal filling small artefacts could be seen. (Figure 11a) In Figure 11b the right margin was magnificated. The measured gaps ranged between 2.180 microns and 16,900 microns.

According to the SEM results the marginal gap values varied between 4.872 microns to 18.343 microns. Diaket ™ achieved the best results with an overall average of 4.872 microns gap value compared to the other materials. The mean values of marginal gap widths of AH - Plus ™ and Super - EBA ™ are 8.044 microns and 9.951 microns respectively with almost the same magnitude, followed by Super - EBA ™

Regular with 11,560 microns. ProRoot® MTA showed the highest marginal gap value with 18.343 microns ($p < 0.001$) (Table 4,Figure 12)

Micro-Radiography

For the micro-radiographic evaluation 25 premolars were used. Apicectomies were performed on 50 canals with subsequent retrograde root end fillings: 14 canals with Diaket ™, 9 with AH-Plus, 17 with Super - EBA ™, 9 with Super - EBA ™ Regular, 8 with Super - EBA ™ fast and 10 with ProRoot® MTA.

Diaket ™

Figure 13 shows micro- radiographic analysis at 18x magnification of a retrogade filling with Diaket ™. The material adheres well to the dentin and no marginal gap was observed between the sealer and the dentin on the resected root apex.

AH - Plus ™

AH - Plus ™ appears as a non-homogeneous white - gray matter in the center. The root end is not completely filled. The material-related air pockets formed during the filling of the root canal and do not affect the adherence of the filling.(Figure 14)

Super-EBA™ regular

Similar to AH - Plus ™ production-related artefacts within the sealer can be recognized. The black, elongated structure in the right half is a part of the not completely filled root canal. The marginal integrity is only partially observed.(Figure 15)

Super - EBA ™ fast

The root filling material could be seen in the center as a whitish inhomogeneous surface with dark inclusions. The marginal integrity between the dentin and Super - EBA ™ fast is appropriate.(Figure 16)

ProRoot® MTA

ProRoot® MTA showed a non-homogeneous structure. The marginal integrity to the to dentin is superior to all other materials evaluated. (Figure 17)

The results of micro-radiographic analysis confirmed for all materials a good marginal integrity and mainly clean transitions of materials to the dentine at the resected root apex.

Discussion

In the literature, there are numerous article focusing on the short and long term clinical results of the different root-end filling materials. In addition, there have been also studies that have investigated the connective tissue response to the retrograde root end filling materials[23], neurotoxic behaviours[24] and radioopacities [25], however, a few studies that have compared the physical properties of different materialsused as root end fillings. The current study aims to clarify the physical properties of five different canal sealers used as retrofrade filling materials on the resected root apex following apicoectomies.

According to the scanning electron microscopic examination of the current study, the marginal gap values of all tested materials ranged between 4.872 and 18.343 microns and were under 30 microns, which was accepted as a acceptable limit. The comparison of five materials showed that Diaket ™ achieved the best results compared to the other materials. The mean values of marginal gap widths of AH - Plus ™ and Super - EBA ™ fast were about the same magnitude, followed by Super - EBA ™ Regular. However, the highest marginal gap value has ProRoot® MTA with 18.343 microns.

Diaket™ is one of the mostly studied material in endodontics as a retrograde root-end filling material. Lloyd et al [26] investigated the in vitro sealing ability of the root-canal sealer Diaket when used as a root-end filling material compared with of amalgam using linear micro-leakage of Indian ink and showed that Diaket provided a superior seal to amalgam irrespective of the root-end preparation. Gerhards and Wagner[10] have investigated the sealing ability of Amalgam, Harvard-Cement, Diaket, gold-leaf, and Ketac-Endo as retrograde root-end filling materials via stereomicroscope. According to their results, retrofills with Ketac-Endo showed significantly less leakage compared with amalgam. There was no significant difference between the amalgam and Diaket groups. The sealing ability of Harvard-Cement and gold foil was lower than amalgam and it was concluded that retrograde fillings with Ketac-Endo or Diaket can be considered as alternatives for amalgam.

In the literature, it has been proclaimed that microleakage is not completely inhibited with amalgam, zinc oxide eugenol cement or glass-ionomer cement.[5–7] Based on the results of the clinical and histological studies, it has been widely reported that ProRoot® MTA stands out as the gold standard retrofilling material for apical seal[27] due to its superior charactheristics such as biocompatibility, non-toxicity, osteoinduction and cementogenesis [28] It has been suggested that, MTA provides a very good seal, has excellent marginal adaptation, maintains a high pH for a long period of time, and appears to induce a favorable tissue response.[29] In addition, Maltezos et al [30] have compared the sealing properties of Resilon, ProRoot® MTA, and Super-EBA as root-end filling material and stated that ProRoot® MTA presents significantly less leakage than that with amalgam, gutta-percha and zinc oxide eugenol in a dye leakage test and showed significantly less leakage than reinforced zinc oxide eugenol cement when evaluated using a bacterial leakage system. Similarly, Tanaka et al.[31] have reported that dye leakage of root-ends

sealed without cavity preparation using 4-META/MMA-TBB resin was significantly less than that of root-end fillings using reinforced zinc oxide eugenol cement.

However, the results of the in vitro studies focusing on the marginal properties of MTA are controversial. Wu et al [4] confirmed that ProRoot® MTA has a superior marginal adaptation compared to Super - EBA ™. However, Bates et al [32], Adamo et al [15] and Scheerer et al [33] can not confirm this better property. Moreover, Adamo et al [15] have proclaimed that microleakage of MTA has been reported to increase with time. In the current study, the results obtained with ProRoot® MTA showed significantly higher values compared to other four materials.

The sealing behavior and the degree of apical leakage of different Sealers has been in the past in numerous studies with a variety of experimental methods reviewed [34]. These are:

Dye penetration test, Radioactive isotopes, Electrochemical method, Penetration test with bacteria, Air or Water pressure, Microradiography and Scanning electron microscopy.

In the literature, there are several studies [1,35] using SEM analysis in evaluation of marginal integrity of root end filling of various root canal material. In the current study, the quantification of the marginal gap analysis was performed by using SEM, whereas microradiography was used to help understanding of the qualitative examination. Similarly, the study of root canal fillings on marginal integrity was carried out as at Möhlenkamp[36] and Spiekermann[37] in a combined approach for qualitative and quantitative examination of the apical leakage by SEM and complementary microradiography. As observed in the current study and demonstrated also in the study of Möhlenkamp, a negative point of SEM analysis is that the high vacuum could result in artificial cracks and crevices.[36]

Conclusions

It is obvious that the retrograde obturation, -which mostly depends on the marginal integrity of the root-end filling material- plays a great role in the success of the apicoectomy procedure. However, soft and hard tissue responses to the retrograde root-end filling material and alterations in the physical properties in the long term, could also effect the results of the treatment.

According to the limited knowledge of the current in vitro study, it can be concluded that both in terms of its marginal integrity and material properties, Diaket ™ is the most suitable material for retrograde obturation. Additional clinical studies with long term follow up period might help to determine the most appropriate root-end filling material.

Declarations

Acknowledgements

The corrresponding author of the manuscript confirms that all authors have viewed and agreed to the submission.

Competing interest

None

Funding source None

References

1. Zerbinati LP, Tonietto L, de Moraes JF , de Oliveira MG . Assessment of marginal adaptation after apicoectomy and apical sealing with Nd:YAG laser. Photomed Laser Surg. 2012;30(8):444-50.
2. Otani K, Sugaya T, Tomita M, Hasegawa Y, Miyaji H, Tenkumo T, et al. Healing of experimental apical periodontitis after apicoectomy using different sealing materials on the resected root end. Dent Mater J. 2011;30(4):485-92.
3. *Schubert M*, *Benner KU*. Ist die *Wurzelspitzenresektion noch zeitgemäß*? *ZMK 2000*, *4: 186-190*.
4. Lamb EL, Loushine RJ, Weller RN, Kimbrough WF, Pashley DH. Effect of root resection on the apical sealing ability of mineral trioxide aggregate. Oral Surg Oral Med Oral Pathol Oral Radiol Endod. 2003;95(6):732-5
5. Bohsali K, Pertot WJ, Hosseini B, Camps J. Sealing ability of super EBA and Dyract as root-end fillings; a study in vitro. Int Endod J 1998; 31: 338-342.
6. Wu M-K, Kontakiotis EG, Wesselink PR. Long-term seal provided by some root-end filling materials. J Endod 1998; 24: 557-560.
7. Aqrabawi J. Sealing ability of amalgam, super EBA cement, and MTA when used as retrograde filling materials. Br Dent J 2000; 188: 266-268
8. Miletić I, Ribarić SP, Karlović Z, Jukić S, Bosnjak A, Anić I.Apical leakage of five root canal sealers after one year of storage.J Endod. 2002;28(6):431-2.
9. Barkhordar RA. Evaluation of antimicrobial activity in vitro of ten root canal sealers on Streptococcus sanguis and Streptococcus mutans. Oral Surg Oral Med Oral Pathol. 1989;68(6):770-2.
10. Gerhards F, Wagner W . Sealing ability of five different retrograde filling materials. J Endod. 1996 ;22(9):463-6.
11. Cobankara FK, Adanr N, Belli S. Evaluation of the influence of smear layer on the apical and coronal sealing ability of two sealers. J Endod. 2004 ;30(6):406-9
12. Kaplan AE, Picca M, Gonzalez MI, Macchi RL, Molgatini SL. Antimicrobial effect of six endodontic sealers: an in vitro evaluation. Endod Dent Traumatol. 1999 Feb;15(1):42-5

13. Koulaouzidou EA, Papazisis KT, Beltes P, Geromichalos GD, Kortsaris AH. Cytotoxicity of three resin-based root canal sealers: an in vitro evaluation.Endod Dent Traumatol. 1998;14(4):182-5.

14. Baumann M, Gerhards F.Die retrograde WurzelkanalfüllungQ uintessenz 1996; 47:1463-1475

15. Adamo HL, Buruiana R, Schertzer L, Boylan RJ. A comparison of MTA, Super-EBA, composite and amalgam as root-end filling materials using a bacterial microleakage model. Int Endod J. 1999 ;32(3):197-203

16. Laghios CD, Benson BW, Gutmann JL, Cutler CW. Comparative radiopacity of tetracalcium phosphate and other root-end filling materials. Int Endod J. 2000 ;33(4):311-5.

17. Apaydin ES , Shabahang S , Torabinejad M . Hard-tissue healing after application of fresh or set MTA as root-end-filling material. J Endod. 2004;30(1):21-4.

18. Keiser K , Johnson CC , Tipton DA . Cytotoxicity of mineral trioxide aggregate using human periodontal ligament fibroblasts. J Endod. 2000;26(5):288-91.

19. Schultz CB, Westhauser P, Nideröst B, Klaus WG. [Retrograde obturation with MTA Cement and Super-EBA after apicoectomy. Sealing ability of MTAand Super-EBA in dye penetration tests]. Schweiz Monatsschr Zahnmed. 2005;115(5):442-54

20. Hashiguchi D [1], Fukushima H , Yasuda H , Masuda W , Tomikawa M , Morikawa K , Maki K , Jimi E .Mineral trioxide aggregate inhibits osteoclastic bone resorption. J Dent Res. 2011 ;90(7):912-7.

21. Hasegawa Y, Sugaya T, Kawanami M. Effectiveness of root-end sealing using 4-META/MMA-TBB resin on healing of apical periodontitis. Jpn J Conserv Dent 2004; 47: 622-632.

22. Hasegawa Y, Tomita M, Sugaya T, Kawanami M. Healing of apical periodontitis after root-end sealing using 4-META/ MMA-TBB resin following apicoectomy. Jpn J Conserv Dent 2006; 49: 282-287

23. Regan JD [1], Gutmann JL , Witherspoon DE .Comparison of Diaket and MTA when used as root-end filling materials to support regeneration of the periradicular tissues. Int Endod J. 2002;35(10):840-7.

24. Asrari M, Lobner D. In vitro neurotoxic evaluation of root-end-filling materials. J Endod. 2003;29(11):743-6.

25. Gorduysus M, Avcu N. Evaluation of the radiopacity of different root canal sealers. Oral Surg Oral Med Oral Pathol Oral Radiol Endod. 2009 Sep;108(3):e135-40.

26. Lloyd A , Gutmann J , Dummer P , Newcombe R . Microleakage of Diaket and amalgam in root-end cavities prepared using MicroMega sonic retro-prep tips. Int Endod J. 1997;30(3):196-204.

27. Torabinejad M, Parirokh M. Mineral trioxide aggregate: a comprehensive literature review–part II: leakage and biocompatibility investigations. J Endod. 2010;36(2):190-202.

28. Parirokh M, Torabinejad M. Mineral Trioxide Aggregate: A Comprehensive Literature Review–Part I: Chemical, Physical, and Antibacterial Properties. J Endod.2010;36(1):16-27

29. Parirokh M, Torabinejad M. Mineral trioxide aggregate: a comprehensive literature review–Part III: Clinical applications, drawbacks, and mechanism of action. J Endod. 2010;36(3):400-13.

30. Maltezos C, Glickman GN, Ezzo P, He J. Comparison of the sealing of Resilon, Pro Root MTA, and Super-EBA as root-end filling materials: A bacterial leakage study. J Endod 2006; 32: 324-327

31. Tanaka,Y, Sugaya T, Tanaka S, Kawanami M. Long-term durability of root-end sealing with 4-META/MMA-TBB resin. Dent Mater J 2004; 23: 453-456.
32. Bates CF , Carnes DL , del Rio CE .Longitudinal sealing ability of mineral trioxide aggregate as a root-end filling material. J Endod. 1996 Nov;22(11):575-8.
33. Scheerer SQ , Steiman HR , Cohen J . A comparative evaluation of three root-end filling materials: an in vitro leakage study using Prevotella nigrescens. J Endod. 2001 ;27(1):40-2.
34. Schäfer E, Jochims A. Apikale Dichtigkeit von Wurzelkanalfüllungen in Abhängigkeit vom verwendeten Sealer Dtsch Zahnärztl Z 2002, 57:18-23
35. Bidar M [1], Moradi S , Jafarzadeh H , Bidad S Comparative SEM study of the marginal adaptation of white and grey MTA and Portland cement. Aust Endod J. 2007 Apr;33(1):2-6.
36. *Möhlenkamp, T. Die Randdichtigkeit verschiedener Wurzelstiftsysteme bei der Wurzelspitzenresektion im Tiermodell. Med. Dent. Diss., Kiel 2004.*
37. Spiekermann O. Die Randdichtigkeit von retrograd gefüllten Wurzelkanälen nach Wurzelspitzenresektion und unterschiedlicher Aufbereitung am Tiermodell Med dent Diss, Kiel 2008

Tables

TABLES:

Table 1 : The root filling materials according to the product names, manufacturer and composition of the material.

Product	Manufacturer	Composition	
		Component A	Component B
Diaket™	3M ESPE AG Dental Products D-82229 Seefeld	97 % Zincoxide 3 % Bismuthphosphate	76 % Propionylacetophenon 23,3 % Vinyl-Copolymer 0,5 % Dichlorophen 0,2 % Triethanolamin
AH-Plus™	DENTSPLY DETRAY GMBH D-78467 Konstanz	Epoxybisphenol Calciumwolframat Zirconoxide	Amino-Adamantan N,N-Dibenzyl-5-oxanonan Calciumwolframat Zirconoxid
Super-EBA™ regular	BOSWORTH COMPANY 7227 North Hamlin Avenue Skokie, IL 60076-3999 U.S.A.	Zincoxide Magnesiumoxide Feldspar Fluorspar	Aqua dest. Zinc Orthophosphoric acid Aluminium
Super-EBA™ fast	BOSWORTH COMPANY 7227 North Hamlin Avenue Skokie, IL 60076-3999 U.S.A.	Zincoxid Magnesiumoxid Feldspar Fluorspar	Aqua dest. Zinc Orthophosphoric acid Aluminium
ProRoot® MTA	DENTSPLY TULSA DENTAL 608 Roling Hills Drive Johnson City, TN 37604 U.S.A.	Tricalciumsilkate Tricalciumaluminate Calciumoxide Silica	Aqua dest.

Table 2 Distribution of the root-end fillings according to the material used

Material	Number			
	SEM (longitudinal section)	SEM (transversal section)	Microradiography	Total
Diaket™	5	5	14	24
AH-Plus™	5	5	9	19
Super-EBA™ regular	5	5	9	19
Super-EBA™ fast	5	5	8	18
ProRoot®-MTA	5	5	10	20

Table 3: Ingredients of the Methacrylat-solution.

Ingredients	Amount
Methacrylacid-methylester (Fluka Chemie AG, CH-9471 Buchs Germany)	500 g
α, α-Azoisobutyronidrile (Fluka Chemie AG, CH-9471 Buchs Germany)	3 g
Nonylphenyl-polyethyleneglycolacetate (Fluka Chemie AG, CH-9471 Buchs Germany)	100 ml
Phthalic acid Dibutylester (Ethicon GmbH & Co. KG, D-22851 Norderstedt Germany) and. Dibutylphthalat (Merck KG, D-64293 Darmstadt Germany)	5 ml

Table 4.Mean marginal gap values of different materials.

Material	Mean	Standard deviation	Standart error	Median	N
Diaket™	4,872	4,096	0,648	3,600	40
AH-Plus™	8,044	11,372	1,798	4,350	40
Super-EBA™ regular	11,560	16,603	2,625	4,325	40
Super-EBA™ fast	9,951	14,365	2,271	3,070	40
ProRoot® MTA	18,343	16,715	2,643	14,000	40
Total	10,554	14,074	0,995	4,610	200

Figures

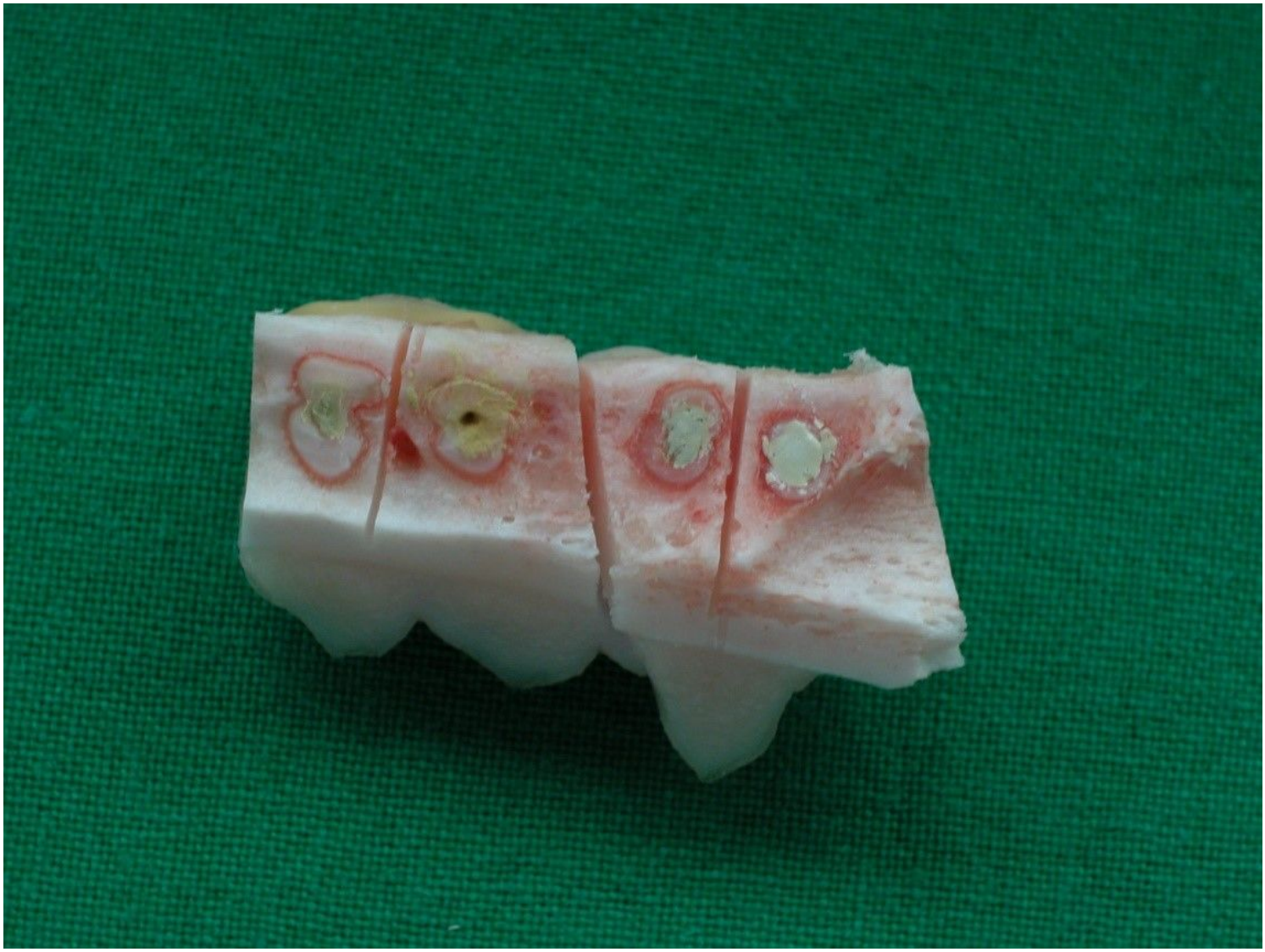

Figure 1

After completion of the root–end fillings, teeth were osteotomised with hammer and chisel en bloque from the bone segment

Figure 2a:



Figure 2b:



Figure 2

a 60 x and b 320x magnifications on longitudinal plan revealed that Diaket ™ obturates the root canal completely.

Figure 3a



Figure 3b:



Figure 3

a Diaket TM on the transversal cross sections at 60 x magnification on the transversal plane. The root canal is completely filled with the homogeneous mass .b at 320 x magnification. Diaket TM adheres to dentin and shows a complete obturation .

Figure 4a:

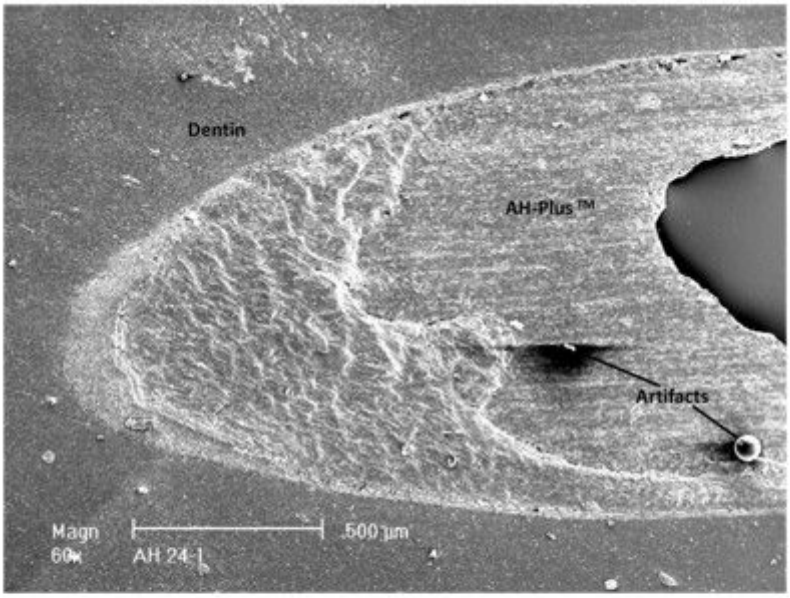

Figure 4b:



Figure 4

Retrograde filling with AH Plus™ in a. 60- and b. 320x magnifications on longitudinal plane. The artifacts are thought to be formed during preparation of the replica models. The marginal gap sizes varied between 1.210 microns and 7.240 microns .

Figure 5a:

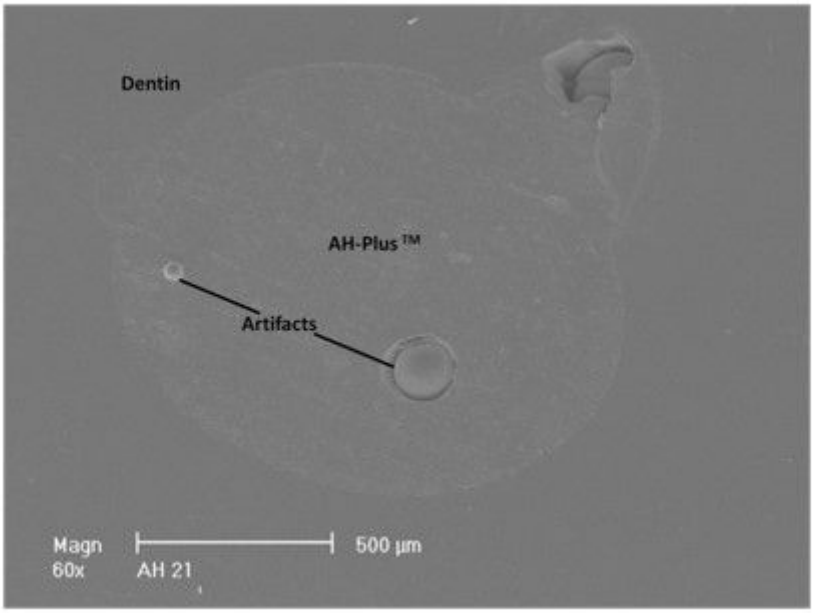

Figure 5b:



Figure 5

a AH - Plus ™ , which was viewed at 60x magnification on transversal plane. The root canal is almost completely obturated . The artifacts are created during processing and not due to the material . b AH - Plus ™ , which was viewed at 320 x magnification .The barely discernible edge gap proves despite inhomogeneity of the filler an excellent adhesion to dentin .

Figure 6a:



Figure 6b:

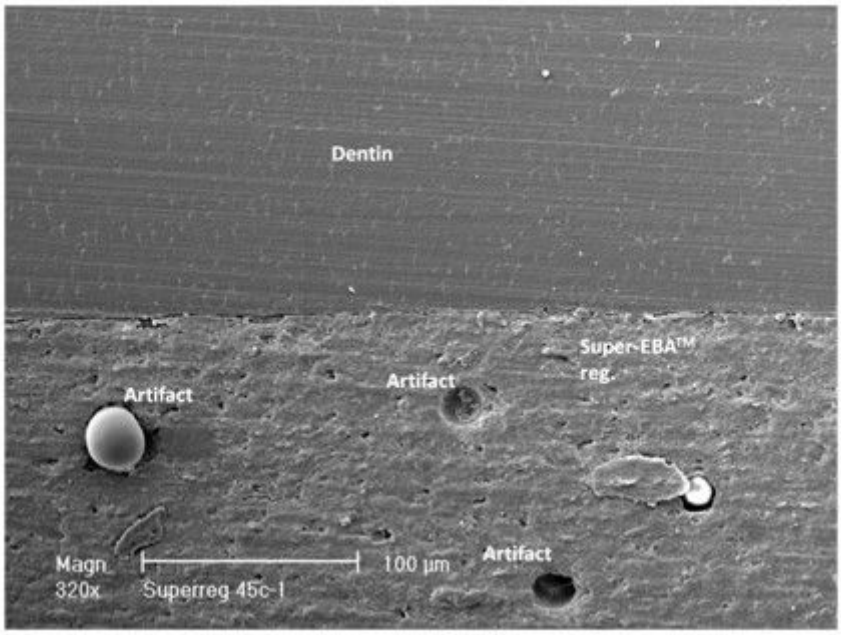

Figure 6

a Super - EBA ™ Regular at 60x magnification on longitudinal plane. The retrograde cavity was not completely filled by the material . The air entrapment can be clearly seen b. Super - EBA ™ Regular at 320x magnification.A continuous minimal marginal gap was observed.

Figure 7a:



Figure 7b:



Figure 7

a Super - EBA ™ Regular , at 60x magnification on transversal plane . The entire root canalwas filled with material. b. Super - EBA ™ Regular , at 320 x magnification on transversal sections . No marginal gap could be observed. The difference between filling material and dentin can be made out only because of the coarse surface structure .

Figure 8a:

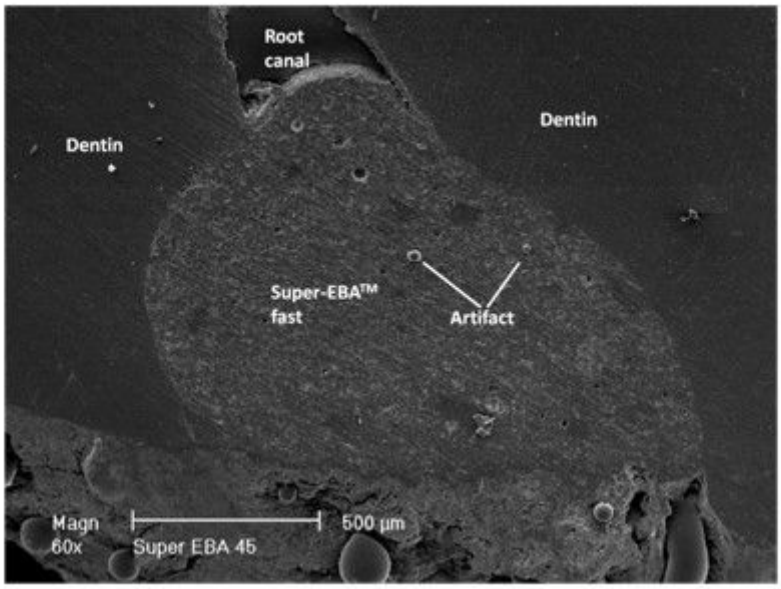

Figure 8b:



Figure 8

a Super - EBA ™ fast at 60x magnification on longitudinal plane. The retrograde cavity was completely filled by the material . Even at this magnification , a marginal gap couldbe recognized on the left side. b Super - EBA ™ fast at 320x magnification. The marginal gap which was observed in Figure 7a resulting from the lack of adherence to the dentinal wall and the inhomogeneity of the material is good to see .

Figure 9a:



Figure 9b:



Figure 9

a Super - EBA ™ fast at 60x magnification on transversal plane. . The root canal was sealed with the material completely.b. Super - EBA ™ fast 600x magnification. Again, a very good connection between filler and dentin was observed . The facets become only at this high magnification clear.

Figure 10a:



Figure 10b:

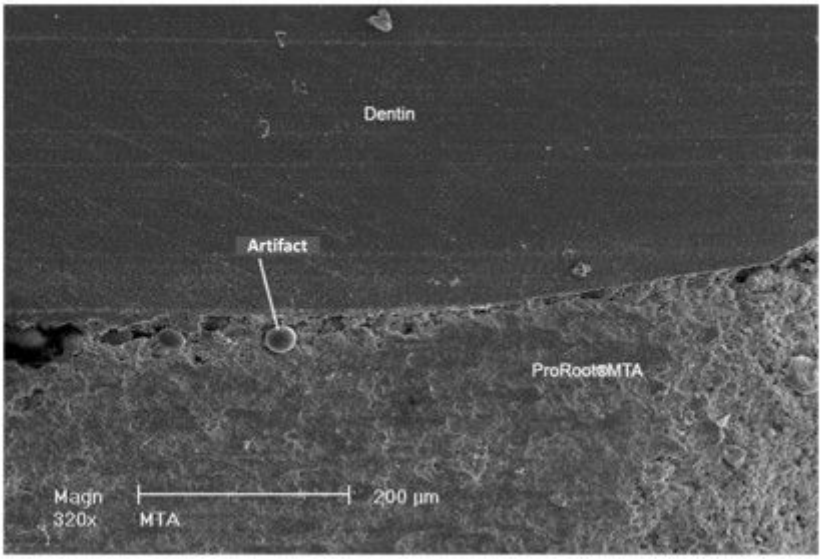

Figure 10

a ProRoot® MTA at 60x magnification on longitudinal plane. Marginal gaps and artifacts (secondary to the preparation) have been formed. b ProRoot® MTA at 320x magnification. The already recognizable marginal gap in Figure 8a could be clearly seen.

Figure 11a:

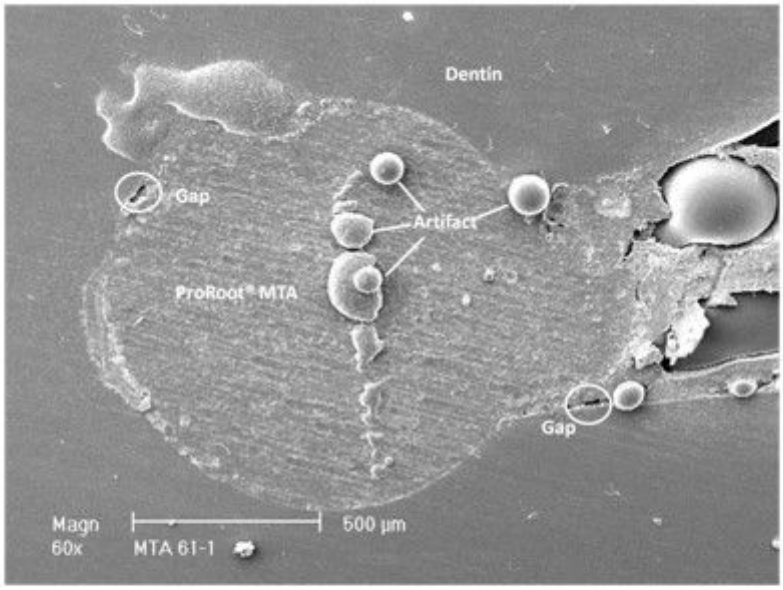

Figure 11b:



Figure 11

a ProRoot® MTA at 60x magnification on transversal plane.. Already at this low magnification, marginal gaps along with numerous artifacts are clearly visible.b ProRoot® MTA at 320x magnification . A good connection of the coarse-structured material was observed .

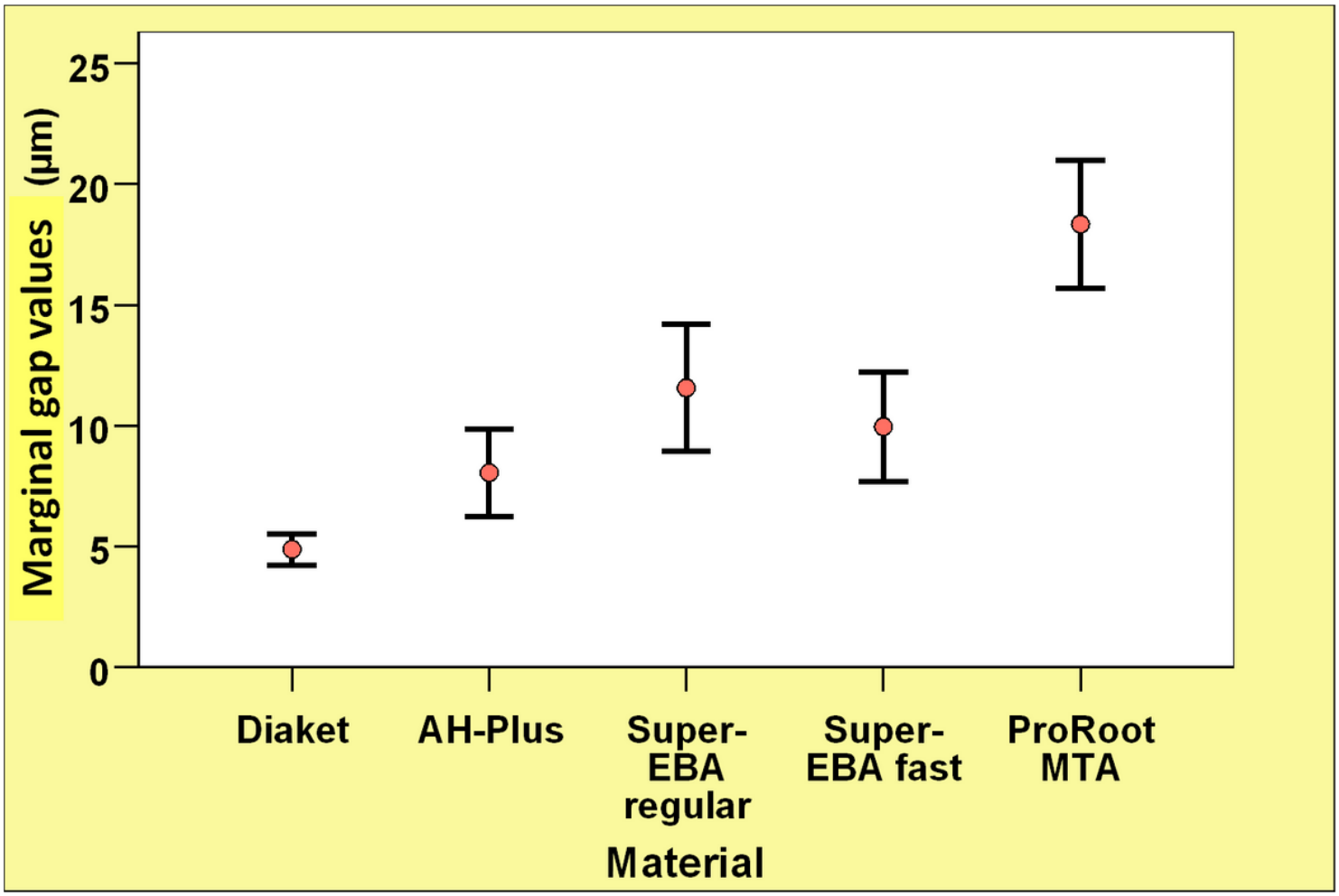

Figure 12

Comparison of the marginal gap values of five different root-end filling materials

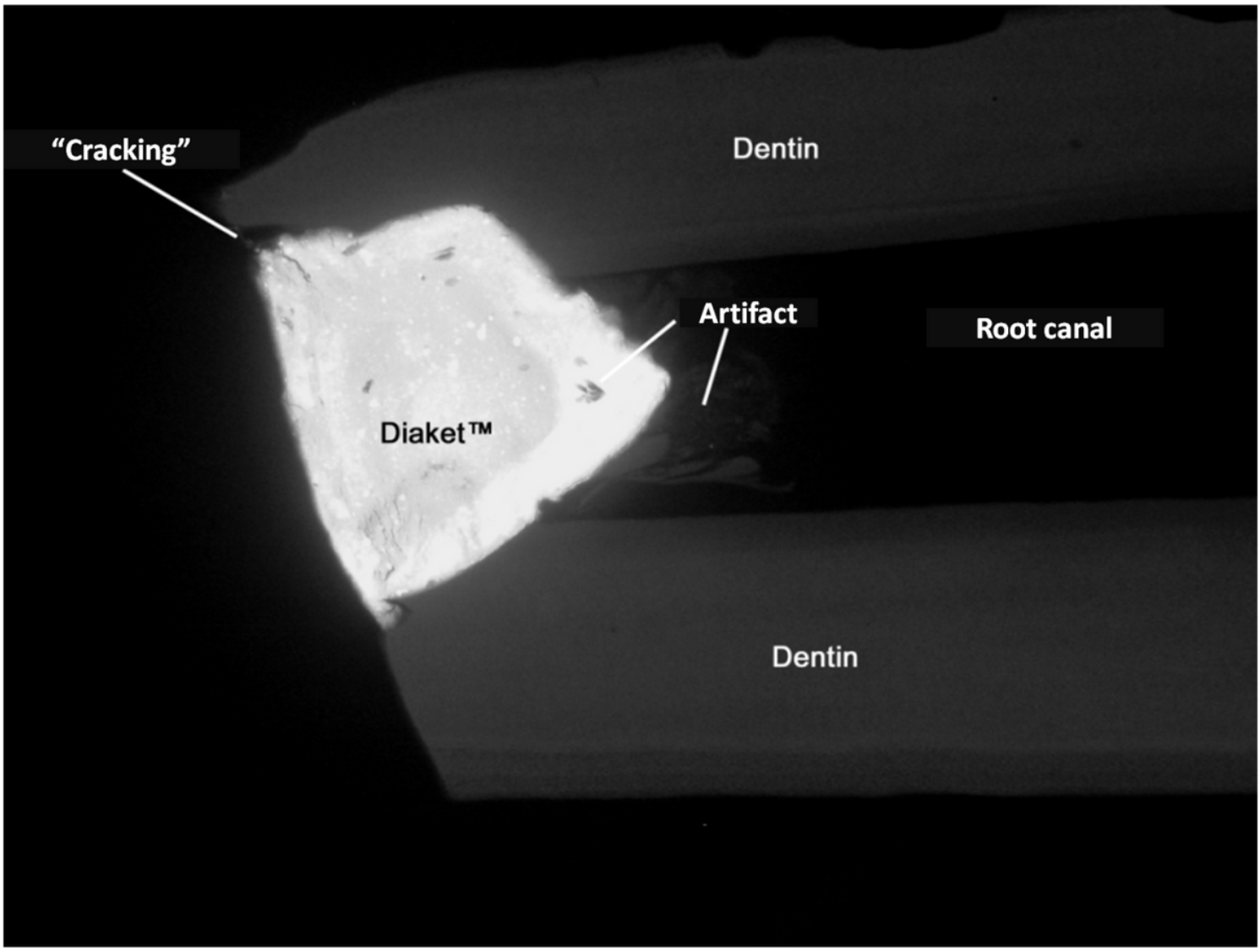

Figure 13

Microradiographic evaluation of the root canal filling with Diaket ™ at 18x magnification. A "cracking" has formed in the filler during the preparation of the for the microradiography analysis. It has no effect on the marginal integration.

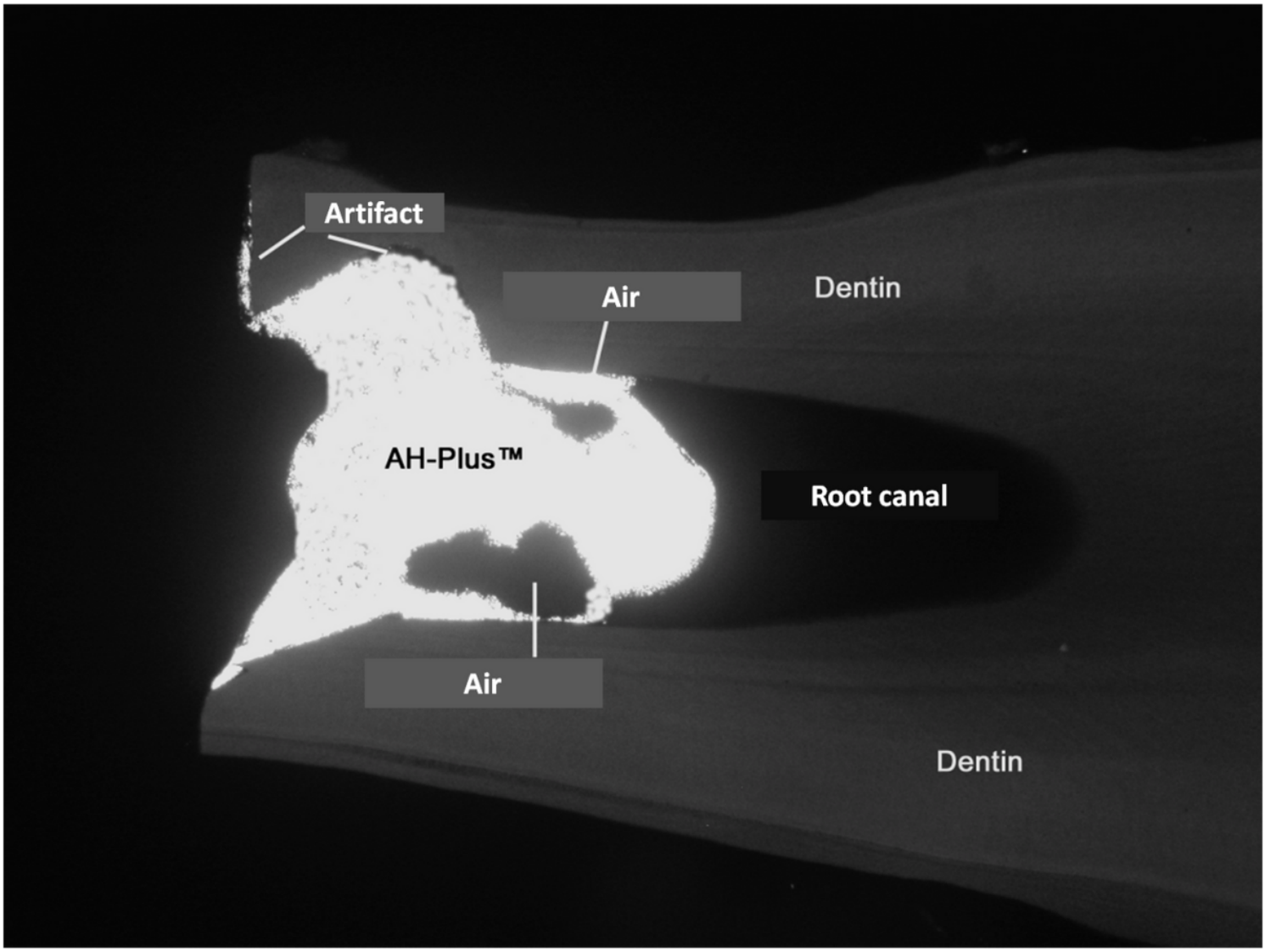

Figure 14

Microradiographic evaluation of the root canal filling with AH - Plus ™ at 18x magnification. The root canal could not be completely filled ; during processing emerged two large air pockets .

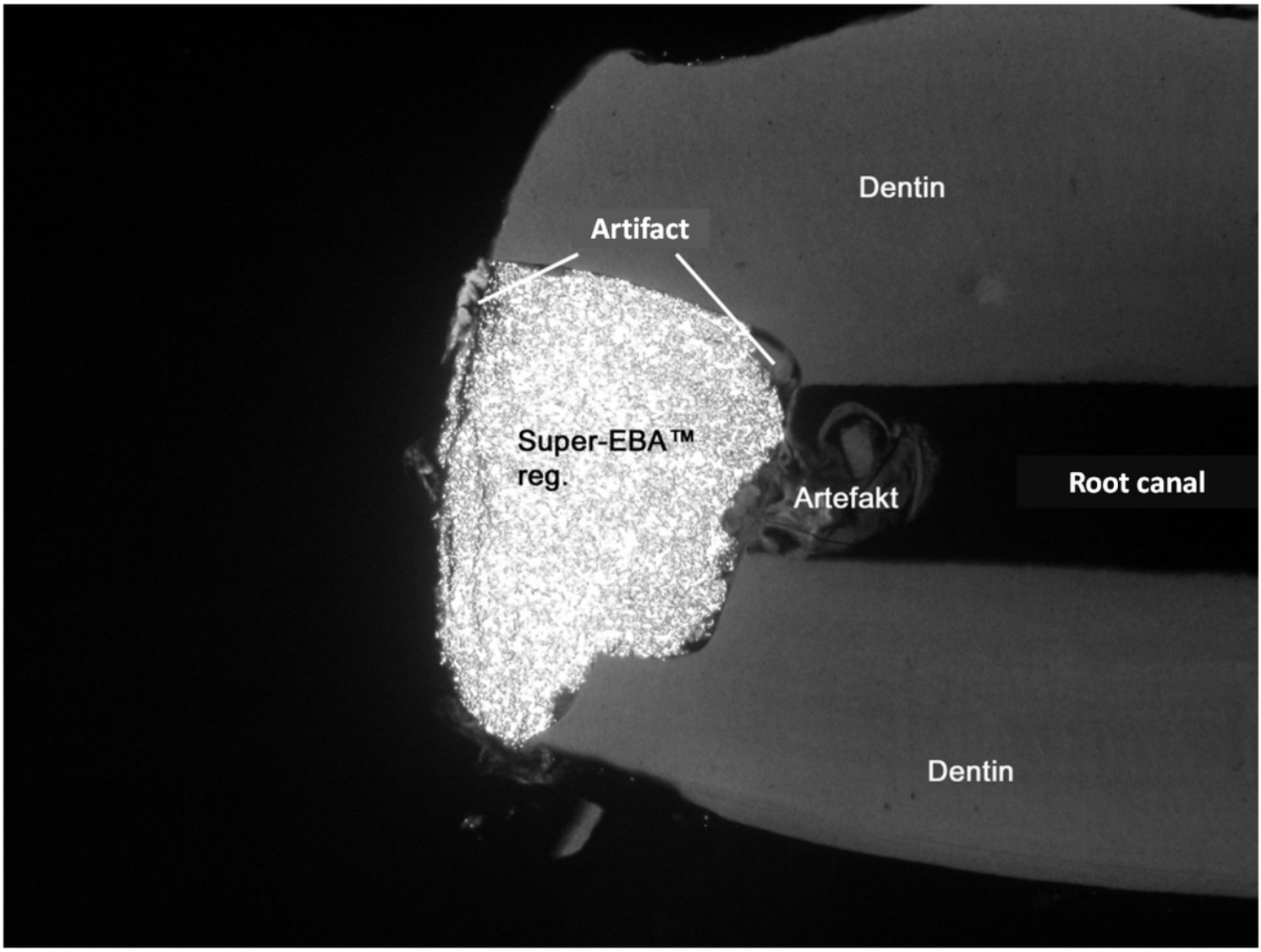

Figure 15

Microradiographic evaluation of the root canal filling with Super - EBA ™ Regular at 18x magnification. In addition to the artefacts in the root canal , the marginal gaps are clearly visible.



Figure 16

Microradiographic evaluation of the root canal filling with Super - EBA ™ fast at 18x magnification. The coarsely porous material adheres well to the dentin . The filling material is very rich in contrast.



Figure 17

Microradiographic evaluation of the root canal filling with ProRoot® MTA at 18x magnification. The retrograde preparation was sealed by the material . The inhomogeneous structure of the ProRoot® MTA is remarkable.