Small Incision Lenticule Extraction (SMILE) for Moderate and High Myopia: Seven-Year Outcomes of Refraction, Corneal tomography and Wavefront Aberrations

Fei Xia
Fudan University Eye Ear Nose and Throat Hospital Department of Ophthalmology
Yang Shen
Fudan University Eye Ear Nose and Throat Hospital Department of Ophthalmology
Tian Han
Fudan University Eye Ear Nose and Throat Hospital Department of Ophthalmology
Jing Zhao
Fudan University Eye Ear Nose and Throat Hospital Department of Ophthalmology
Hai-Peng Xu
Fudan University Eye Ear Nose and Throat Hospital Department of Ophthalmology
Xingtao Zhou (doctzhouxingtao@163.com)
Fudan University Eye Ear Nose and Throat Hospital https://orcid.org/0000-0002-3465-1579

Research article

Keywords: Myopia, Small incision lenticule extraction, Corneal stability, Corneal wavefront aberrations

Posted Date: October 2nd, 2019

DOI: https://doi.org/10.21203/rs.2.15558/v1

Version of Record: A version of this preprint was published at Journal of Ophthalmology on April 23rd, 2020. See the published version at https://doi.org/10.1155/2020/3825864.

Abstract

Background To investigate the long-term corneal stability and wavefront aberrations after small incision lenticule extraction (SMILE) for moderate and high myopia.

Methods Prospective, non-consecutive case series. A total of 26 patients (42 eyes) who underwent SMILE from May 2010 to March 2013 at the Fudan University Eye and ENT Hospital (Shanghai, China) were enrolled. The periods of follow-up were 1 month, 1 year, 5 years and 7 years after surgery. The routine eye examinations included uncorrected distance visual acuity (UDVA) and corrected distance visual acuity (CDVA), manifest refraction and corneal topography.

Results All surgeries were executed without any complications. At the final visit, a UDVA of 20/20 or better was achieved in 42 eyes (100%), 21 eyes (50%) exhibited no change in CDVA. 15 eyes (36%) gained one line, 6 eyes (14%) gained two lines, and no eyes lost CDVA lines. 93% and 100% of eyes were within ±0.5 D and ±1.00 D of the target refraction, respectively. A mean refractive regression of -0.17 D was observed between 1 month and 7 years postoperatively. Mean corneal front curvature (KMF) were significantly increased between pre- and post-SMILE surgery ($P<0.0001$). Higher-order aberrations (HOAs) and vertical coma were significantly increased after SMILE compared to those measured before surgery (all $P<0.001$). There were no significant differences in horizontal coma, trefoil and spherical aberration between pre- and post-SMILE surgery (all $P>0.05$).

Conclusions SMILE is an effective, safe and stable procedure for myopia correction, with relatively constant corneal stability and wavefront aberrations.

Background

As opposed to flap-based surgical procedures, small incision lenticule extraction (SMILE) is a minimally invasive refractive surgical technique that involves the manual removal of femtosecond laser-created intrastromal lenticule through small side cut. Shah et al.(1) and Sekundo et al.(2)first introduced this new procedure in 2011. The first clinical study of femtosecond lenticule extraction in China was reported by our group(3) in 2011. Numerous clinical studies(4–10) suggested that SMILE was a safe and effective treatment option for myopia correction, and their follow-up periods mostly spanned from 3 months to 3 years, but rarely up until 4 years(11–15). In addition, our group(16) has previously compared the 5-year outcomes of SMILE and femtosecond laser-assisted LASIK (FS-LASIK) in patients with myopia. It is noted that the long-term observation of corneal stability and wavefront aberrations following SMILE is of great significance. The present study aims to evaluate the seven-year changes in corneal stability and wavefront aberrations after SMILE for moderate and high myopia.

Methods

Subjects

A total of 26 patients (42 eyes) who underwent SMILE between May 2010 to March 2013 at Fudan University Eye and ENT Hospital (Shanghai, China) were recruited in this prospective study.

The inclusion criteria were as follows: (i) dissatisfaction of wearing glasses or contact lens; (ii) corrected distance visual acuity (CDVA) of 20/25 or greater; (iii) ages 18 year or older; (iv) manifest refraction spherical equivalent (MRSE) of −1.0 to −10.0 D and manifest cylinder of 0 to −6.0 D; (v) a stable refraction state for at least two years; (vi) residual corneal stromal bed thickness of more than 280 μm; and (vii) no use of contact lenses over the last 2 weeks. Patients with suspicious keratoconus, severe dry eyes, cataract, retinal detachment or other ocular disorders were excluded. In addition, those with systemic diseases such as diabetes and connective tissue diseases were excluded as well. The demographic and clinical characteristics of patients with moderate and high myopia are shown in Table 1.

This study adhered to the tenets of the Declaration of Helsinki, and was approved by the medical ethics committee of Fudan University Eye and ENT Hospital Shanghai, China. Written informed consent was obtained from all participants before enrollment.

Table 1. Baseline characteristics of patients

Parameters	Mean ± SD (Range)
Gender (n/n)	9 males / 17 females
Age (years)	28.27±7.76 (18 to 43)
Average follow-up (months)	82.53±8.50 (73 to 98)
IOP (mm Hg)	16.19±1.75 (12.7 to 19.5)
Axial length	25.97±0.78 (24.12 to 27.29)
MRSE (D)	-6.28±1.20 (-8.75 to -4.00)
Manifest Sphere (D)	-5.88±1.15 (-8.50 to -4.00)
Manifest Cylinder (D)	-0.80±0.58 (-3.00 to 0)
Ablation depth (μm)	126.57±19.23 (85 to 164)

D = diopters; MRSE = manifest refraction spherical equivalent; IOP = Intraocular pressure

Surgical Procedure

The surgical technique has been detailedly described by Zhao et al.[17]. VisuMax femtosecond laser system (Carl Zeiss Meditec AG, Jena, Germany) was set to a pulse energy of 130 nJ and repetition rate of 500 kHz. Additional parameter settings were as follows: 6.5 to 6.8 mm lenticule diameter, 100 to 110 μm cap thickness, 7.5 to 7.8 cap diameter (larger than 1 mm of lenticule), a 4.5-mm side cut (90 degrees) at 12:00 clock. All procedures were performed by the same experienced surgeon (XZ).

Postoperative medications included levofloxacin 4 times a day for 1 week and sodium hyaluronate 4 times a day for 1 month. Meanwhile, 0.1% fluorometholone solution was tapered gradually once every three days from 8 to 1 time daily.

Main Outcome Measures

The following parameters were assessed preoperatively, and 1 month, 1 year, 5 years and 7 years postoperatively: (i) uncorrected distance visual acuity (UDVA) and corrected distance visual acuity (CDVA); (ii) objective and manifest refraction; (iii) intraocular pressure (Tonoref II, Nidek, Japan); (iv) slit-lamp examination; and (v) thinnest corneal thickness (TCT), mean corneal front curvature (KMF), mean corneal back curvature (KMB), posterior thinnest elevation (PTE), preoperative PTE subtracted from postoperative PTE (△PTE) and wavefront aberrations.

TCT, KMF, KMB, PTE, △PTE and wavefront aberrations were measured using a corneal topography (Pentacam, Oculus GmbH, Wetzlar, Germany). KMF, KMB and PTE were delineated in the central 4-mm area above the 8-mm reference best-fit sphere. △PTE was defined as the difference between preoperative PTE and postoperative PTE at two time points.

Corneal wavefront aberrations were evaluated at a 5-mm analysis diameter. The root mean square (RMS) of spherical aberration (z40), coma (z3,1), trefoil (z33,z3−3) and total higher-order aberrations (HOAs) up to fourth order were calculated using Zernike polynomials.

Statistical Analysis

All data were analyzed using SPSS version 23.0 statistical software (SPSS Inc., Chicago, IL, USA). Continuous variables were presented as mean ± standard deviation (SD), while categorical variables were shown as frequency or percentage. Pearson correlation coefficient was used to determine the correlation between the attempted and achieved spherical equivalent. Repeated measures analysis of variance was performed to assess the standardized differences of preoperative and postoperative visits at various time points. Post-hoc test with Bonferroni correction was used to compare the data between two different time points. P values of less than 0.05 were considered statistically significant.

Results

All operations were completed smoothly without intraoperative and postoperative complications. No case of corneal ectasia was found in the present study.

Efficacy and Safety

The efficacy index was 1.07 (Figure. 1A). Among the 42 eyes, 42 eyes (100%) achieved a UDVA of 20/20 or better, 29 eyes (69%) achieved a UDVA of 20/16 or better, and 11 eyes (26%) achieved a UDVA of 20/12.5 or better.

The safety index was 1.12 (Figure 1B). Twenty one out of 42 eyes (50%) demonstrated no change in CDVA. 15 eyes (36%) gained one line of CDVA, 6 eyes (14%) gained two lines of CDVA, and no eyes lost

CDVA lines.

Predictability and Stability

As shown in Figure 1D, 93% and 100% of eyes were within±0.5 D and ±1.00 D of the targeted refraction, respectively. Meanwhile, 98% and 100% of eyes were within ±0.5 D and ±1.00 D of refractive astigmatism, respectively (Figure 1E). A scatter plot of the attempted versus the achieved correction (spherical equivalent) is illustrated in Figure 1C.

The mean values of MRSE went from 0.00±0.23 D at 1 month postoperatively to −0.17±0.23 D at 7 years postoperatively (P = 0.001). A mean refractive regression of −0.17 D was observed between 1 month and 7 years postoperatively, which corresponded to a regression rate of −0.02 D per year. In addition, the change in spherical equivalent refractive error was more than 0.5 D in 1 (2.9%) out of 34 eyes (Figure 1F).

Corneal Stability Analysis

The outcomes of corneal stability analysis are presented in Table 2. The mean values of TCT and KMF at 7 years after SMILE were significantly increased compared to those measured preoperatively (all P<0.001). However, no significant differences were found in the values of KMB, PTE and △PTE between pre- and post-SMILE surgery (P = 0.077, P = 0.185 and P = 0.196, respectively). Figure 2 shows the differences between the posterior corneal surface maps obtained by corneal topography preoperatively (A) and 1 month (B), 1 year (C), 5 years (D), and 7 years (E) after SMILE.

Table 2. Corneal stability analysis

Parameters	Pre	1 Month	1 Year	5 Years	7 Years	P
TCT	548.79±29.80	432.18±36.84[a]	440.25±40.70[a,b]	440.03±34.99[a,b,c]	442.12±36.45[a,b]	<0.001
KMF	43.38±1.20	38.11±1.30[a]	38.61±1.35[a,b]	38.62±1.38[a,b,c]	38.77±1.40[a,b]	<0.001
KMB	-6.34±0.23	-6.34±0.22	-6.32±0.23	-6.33±0.24	-6.32±0.23	0.077
PTE	4.60±3.60	1.63±3.05[a]	1.25±2.70[a]	1.71±3.65[a]	1.66±3.13[a]	0.185
△PTE	/	-1.18±3.10	-1.49±3.90	-1.39±3.47	-2.43±3.19	0.196

TCT = thinnest corneal thickness; KMF = mean corneal front curvature (from central 4 mm diameter cornea); KMB = mean corneal back curvature (from central 4 mm diameter cornea); PTE = posterior thinnest elevation; △PTE = preoperative PTE subtracted from postoperative PTE.

[a] vs. pre and of statistical significance (P <0.05).

[b] vs. 1 month and of statistical significance (P <0.05).

[c] vs. 1 year and of statistical significance (P <0.05).

[d] vs. 5 years and of statistical significance (P <0.05).

Data are presented as mean ± SD.

Corneal Wavefront Aberrations

Table 3 displays the changes in corneal wavefront aberrations following SMILE. The root mean square values of HOAs and coma were significantly increased in both corneal anterior surface and total cornea after SMILE surgery compared to those measured before the surgery (all P<0.001). Besides, the values of spherical aberration in total corneal were significantly reduced at 1 year and 7 years postoperatively in comparison with 1 month postoperatively (P = 0.006), but not significantly different between other time points (all P>0.05). Furthermore, there were no significant changes in the values of trefoil among the indicated time points (all P>0.05).

Table 3. Root mean square values of corneal wavefront aberrations for a 5-mm pupil

Parameters	Pre	1 month	1 year	5 years	7 years	P value
Corneal (front)						
spherical	0.14±0.03	0.16±0.08	0.12 ±0.07[b]	0.14±0.07	0.13±0.05	0.017
coma	0.12±0.06	0.28±0.13[a]	0.33±0.13[a]	0.32±0.13[a]	0.33±0.14[a]	<0.0001
trefoil	0.06±0.03	0.08±0.04[a]	0.09±0.05[a]	0.07±0.03	0.06±0.03	0.008
HOAs	0.22±0.06	0.37±0.08[a]	0.40±0.10[a]	0.39±0.08[a]	0.38±0.10[a]	<0.0001
Corneal (back)						
spherical	0.08±0.02	0.08±0.01	0.09±0.01	0.09±0.02	0.09±0.01	0.32
coma	0.03±0.02	0.03±0.02	0.03±0.01	0.04±0.01	0.03±0.01	0.487
trefoil	0.04±0.02	0.04±0.03	0.05±0.03	0.04±0.02	0.04±0.02	0.018
HOAs	0.11±0.02	0.11±0.02	0.12±0.02	0.12±0.02	0.12±0.02	0.115
Corneal (total)						
spherical	0.11±0.04	0.14±0.08	0.10±0.06[b]	0.12±0.07	0.10±0.05[b]	0.006
coma	0.13±0.06	0.30±0.13[a]	0.35±0.13[ab]	0.35±0.14[a]	0.35±0.15[a]	<0.0001
trefoil	0.08±0.05	0.11±0.05[a]	0.12±0.06[a]	0.10±0.05	0.09±0.06	0.025
HOAs	0.22±0.06	0.41±0.11[a]	0.43±0.10[a]	0.42±0.13[a]	0.41±0.12[a]	<0.0001

HOAs = higher-order aberrations; SA= spherical aberration

[a] vs. pre and of statistical significance (P <0.05).

[b] vs. 1 month and of statistical significance (P <0.05).

[c] vs. 1 month and of statistical significance (P <0.05).

Data are presented as mean ± SD.

Discussion

A significant proportion of myopia patients opts for SMILE among the available refractive eye surgical techniques. To date, more than 200 million SMILE procedures have been performed worldwide. Its long-term safety and efficacy have received enormous attention.

Our study indicated that 100% eyes reached 20/20 or better in UDVA at 7-year follow-up. The efficacy and safety indices for SMILE were 1.07 and 1.12, respectively. SMILE showed excellent safety and efficacy for moderate to high myopia correction. Han et al.(12) demonstrated that the UDVA was 20/20 or better in 92% of eyes at 4 years after SMILE, and the efficacy and safety indices were in line with our findings. Blum et al.(11) reported the data from 56 eyes after SMILE, in which the UDVA remained stable during 5-year follow-up, indicating the safety of SMILE. Agca et al.(15) suggested that the efficacy index at 5 years after surgery is slightly lower than our ones. However, whether these indices were associated with the early surgical experiences of myopia patients remain to be investigated. Indeed, the long-term results (7 years) confirmed the safety and efficacy of SMILE approach.

In this study, 93% and 100% of eyes were within ± 0.5 D and ±1.00 D of the targeted correction, respectively. During a 4-year follow-up period, Burazovitch et al.(13) found that 89% of eyes were within ±0.50 D of the intended correction in patients with high myopia. Moreover, in the study by Han et al.(12), 89% of eyes were within ±0.50 D of the intended correction, and 100% were within ±1.00 D. Similarly, LI et al.(16) reported that 90% and 100% of eyes were within ±0.5D and ±1.00 D of the intended correction, respectively, at 5 years after SMILE. These indicated that our findings were slightly better than the above-mentioned studies. Besides, Agca et al.(14) demonstrated 5-year results of 37 cases with high myopia, in which 59% of them are within ±0.50 D of the intended correction, and 92% of them are within ±1.00 D. They clarified that it was most likely attributed to a greater tendency toward undercorrection. Likewise, Agca et al.(15) showed that 93% of eyes were within ±0.50 D of the intended correction and 100% were within ±1.00 D among patients with mild-to-moderate myopia. Overall, the predictability after 7 years of SMILE in the current study was definitely better, which may be related to the surgical experience of our team in parameter design.

A mean refractive regression of −0.17 D was observed between 1 month and 7 years postoperatively, which corresponded to a regression rate of −0.02 D per year. Agca et al.(14) reported 5-year outcomes of patients with high myopia after SMILE, and found a statistically significant relationship between 1- and 5-year postoperative regression. LI et al.(16) compared the 5-year results between SMILE and FS-LASIK, and the average regression of SMILE group from 6 months to 5 years postoperatively is found to be −0.02 D. The long-term corneal stability influenced by a variety of factors has great importance in laser refractive surgeries. Pedersen et al.(5) reported no significant changes in spherical equivalent from 3 months to 3 years after SMILE. In other long-term studies(17, 18) of LASIK for moderate and high myopia, a mean regression of 0.63 to 0.97 D was observed after 6 or 7 years. It was worth noting that our findings were comparable and even superior to those achieved in previous studies. The long-term effects of SMILE for myopia correction were of secular stability, indicating that the selected myopes were relatively stable in the present study.

We also found a significant increase in KMF 7 years after surgery, and no significant differences in KMB, PTE and △PTE before and 7 years after the surgery. Our team(19, 20) previously discovered that the posterior corneal surface remained stable 1 year and 3 years after SMILE. Similar results have been

reported by Gyldenkerne et al.(21), suggesting that the structure of corneas remains stable after SIMLE. However, further investigations with larger sample sizes and longer follow-up periods are needed.

In addition, the results of this study indicated that the values of coma increased remarkably 7 years after SMILE, followed by HOA values. There were no significant changes in the values of spherical aberrations and trefoil. All the four wavefront aberrations remained relatively stable at the indicated postoperative time points. These results were consistent with the findings of Shah et al.(1)and Agca et al.(22). Pedersen et al.(5) show the decrease in HOA and spherical aberration from 3 months to 3 years after SMILE, probably due to the long-term corneal remodeling after the surgery. A recent study by Gyldenkerne et al.(23) demonstrateed that the spherical aberration does not change significantly at 3 months after SMILE surgery. Besides, Lee et al.(24) have compared the corneal aberrations between SMILE and transepithelial photorefractive keratectomy (PRK) after 6 months, and found smaller spherical aberration and larger coma values in SMILE group. Our results indicated that spherical aberration did not differ significantly between pre- and post-SMILE surgery, but significantly decreased at 7 years postoperatively compared to 1 month postoperatively. These findings suggest that spherical aberration may be caused by a slight postoperative reaction and other factors during the early stage, and remains stable later on.

The present study has several limitations. First, the sample size was relatively small. Second, patients with moderate and high myopia were categorized into a single group. Finally, this study focused on corneal aberrations instead of all eye aberrations.

Conclusions

This long-term follow-up study reveal that SMILE is an effective, safe and stable surgical approach for myopia correction, with good predictability and relatively constant corneal stability and wavefront aberrations.

List Of Abbreviations

SMILE: small incision lenticule extraction; UDVA: uncorrected distance visual acuity; CDVA: corrected distance visual acuity; TCT: thinnest corneal thickness; KMF: mean corneal front curvature (from central 4 mm diameter cornea); KMB: mean corneal back curvature (from central 4 mm diameter cornea); PTE: posterior thinnest elevation; △PTE: preoperative PTE subtracted from postoperative PTE; D: diopters; MRSE: manifest refraction spherical equivalent; IOP: intraocular pressure;

RMS: root mean square; HOAs: higher-order aberrations; SA: spherical aberration

Declarations

Ethics approval and consent to participate

This study adhered to the tenets of the Declaration of Helsinki, and was approved by the medical ethics committee of Fudan University Eye and ENT Hospital Shanghai, China. Written informed consent was obtained from all participants before enrollment.

Consent for publication

Not applicable.

Availability of data and materials

The datasets that were used and/or analyzed during the current study are available from the corresponding author upon reasonable request.

Competing interests

The authors declare that they have no competing interests.

Funding

This work was supported by National Natural Science Foundation of China (Grant No. 81770955); Project of Shanghai Science and Technology (Grant No.17140902900); the National Natural Science Foundation of China for Young Scholars (Grant No. 81600762).

Authors' contributions

FX carried out the data collection, performed the data analysis and drafted the manuscript. YS and TH collected the data and critically revised the manuscript. JZ and HX participated in the design of the study. XZ participated in the design and coordination of the study and helped draft the manuscript. All of the authors read and approved the final version of the manuscript.

Acknowledgements

None.

Authors' information

[1]Department of Ophthalmology and Optometry, Eye and ENT Hospital, Fudan University, Shanghai, China; [2]Key NHC Key Laboratory of Myopia (Fudan University); Laboratory of Myopia, Chinese Academy of Medical Sciences; [3]Shanghai Research Center of Ophthalmology and Optometry

References

1.Shah R, Shah S, Sengupta S. Results of small incision lenticule extraction: All-in-one femtosecond laser refractive surgery. J Cataract Refract Surg. 2011;37(1):127–37.

2.Sekundo W, Kunert KS, Blum M. Small incision corneal refractive surgery using the small incision lenticule extraction (SMILE) procedure for the correction of myopia and myopic astigmatism: results of a 6 month prospective study. Br J Ophthalmol. 2011;95(3):335–9.

3.Zhou XT, Dong ZX, Yao PJ, Huang J, Xu Y, Xu HP. [The clinical study of femtosecond lenticule extraction for myopia]. Zhonghua Yan Ke Za Zhi. 2011;47(7):584–8.

4.Kamiya K, Shimizu K, Igarashi A, Kobashi H. Visual and refractive outcomes of femtosecond lenticule extraction and small-incision lenticule extraction for myopia. Am J Ophthalmol. 2014;157(1):128–134.e2

5.Pedersen IB, Ivarsen A, Hjortdal J. Three-Year Results of Small Incision Lenticule Extraction for High Myopia: Refractive Outcomes and Aberrations. J Refract Surg. 2015;31(11):719–24.

6.Hansen RS, Lyhne N, Grauslund J, Vestergaard AH. Small-incision lenticule extraction (SMILE): outcomes of 722 eyes treated for myopia and myopic astigmatism. Graefes Arch Clin Exp Ophthalmol. 2016;254(2):399–405.

7.Torky MA, Alzafiri YA. Visual and refractive outcomes of small-incision lenticule extraction in mild, moderate, and high myopia: Six-month results. J Cataract Refract Surg. 2017;43(4):459–65.

8.Kobashi H, Kamiya K, Igarashi A, Takahashi M, Shimizu K. Two-years results of small-incision lenticule extraction and wavefront-guided laser in situ keratomileusis for Myopia. Acta Ophthalmol. 2018;96(2):e119–26.

9.Han T, Xu Y, Han X, Zeng L, Shang J, Chen X, et al. Three-year outcomes of small incision lenticule extraction (SMILE) and femtosecond laser-assisted laser in situ keratomileusis (FS-LASIK) for myopia and myopic astigmatism. Br J Ophthalmol. 2019;103(4):565–68.

10.El-Mayah E, Anis M, Salem M, Pinero D, Hosny M. Comparison Between Q-Adjusted LASIK and Small-Incision Lenticule Extraction for Correction of Myopia and Myopic Astigmatism. Eye Contact Lens. 2018;44 Suppl 2:S426–32.

11.Blum M, Taubig K, Gruhn C, Sekundo W, Kunert KS. Five-year results of Small Incision Lenticule Extraction (ReLEx SMILE). Br J Ophthalmol. 2016;100(9):1192–5.

12.Han T, Zheng K, Chen Y, Gao Y, He L, Zhou X. Four-year observation of predictability and stability of small incision lenticule extraction. BMC Ophthalmol. 2016;16(1):149.

13.Burazovitch J, Naguzeswski D, Beuste T, Guillard M. Predictability of SMILE over four years in high myopes. J Fr Ophthalmol. 2017;40(6):e201–9.

14.Agca A, Cakir I, Tulu AB, Yasa D, Yildirim Y, Yildiz BK, et al. Visual and Refractive Outcomes of Small-Incision Lenticule Extraction in High Myopia: 5-Year Results. J Ophthalmol. 2018;2018:5893126.

15.Agca A, Tulu B, Yasa D, Yildirim Y, Yildiz BK, Demirok A. Long-term (5 years) follow-up of small-incision lenticule extraction in mild-to-moderate myopia. J Cataract Refract Surg. 2019;45(4):421–26

16.Li M, Li M, Chen Y, Miao H, Yang D, Ni K, et al. Five-year results of small incision lenticule extraction (SMILE) and femtosecond laser LASIK (FS-LASIK) for myopia. Acta Ophthalmol. 2019; 97(3):e373–80

17.Sekundo W, Bonicke K, Mattausch P, Wiegand W. Six-year follow-up of laser in situ keratomileusis for moderate and extreme myopia using a first-generation excimer laser and microkeratome. J Cataract Refract Surg. 2003;29(6):1152–8.

18.Zalentein WN, Tervo TM, Holopainen JM. Seven-year follow-up of LASIK for myopia. J Refract Surg. 2009;25(3):312–8.

19.Zhao Y, Li M, Zhao J, Knorz MC, Sun L, Tian M, et al. Posterior Corneal Elevation after Small Incision Lenticule Extraction for Moderate and High Myopia. PLoS One. 2016;11(2): e0148370

20.Zhao Y, Jian W, Chen Y, Knorz MC, Zhou X. Three-Year Stability of Posterior Corneal Elevation After Small Incision Lenticule Extraction (SMILE) for Moderate and High Myopia. J Refract Surg. 2017;33(2):84–8.

21.Gyldenkerne A, Ivarsen A, Hjortdal JO. Comparison of Corneal Shape Changes and Aberrations Induced By FS-LASIK and SMILE for Myopia. J Refract Surg. 2015;31(4):223–9.

22.Agca A, Demirok A, Cankaya KI, Yasa D, Demircan A, Yildirim Y, et al. Comparison of visual acuity and higher-order aberrations after femtosecond lenticule extraction and small-incision lenticule extraction. Cont Lens Anterior Eye. 2014;37(4):292–6.

23.Gyldenkerne A, Ivarsen A, Hjortdal J. Optical and visual quality after small-incision lenticule extraction. J Cataract Refract Surg. 2019;45(1):54–61.

24.Lee H, Kang DSY, Reinstein DZ, Arba-Mosquera S, Kim EK, Seo KY, et al. Comparing corneal higher-order aberrations in corneal wavefront-guided transepithelial photorefractive keratectomy versus small-incision lenticule extraction. J Cataract Refract Surg. 2018;44(6):725–33.

Figures

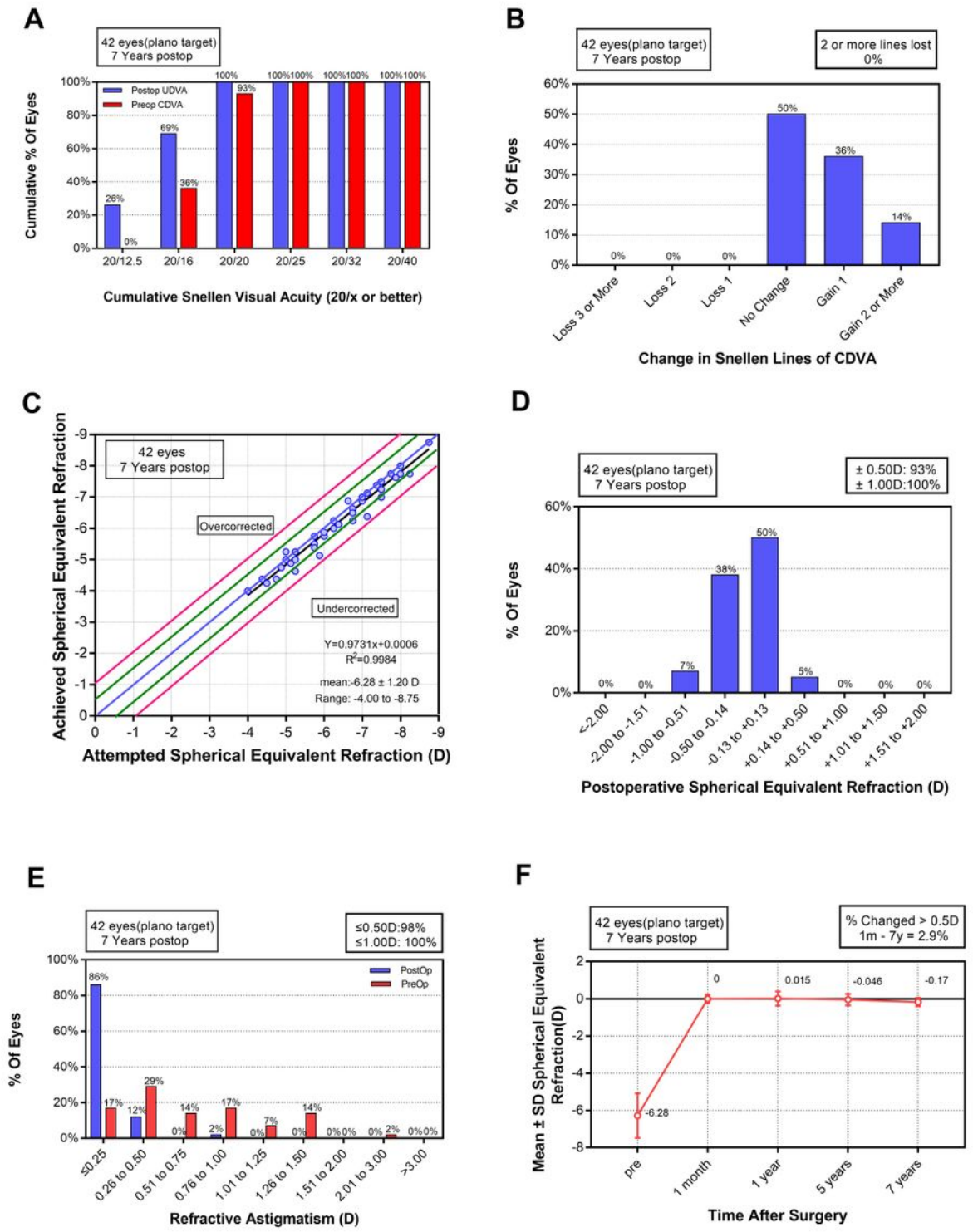

Figure 1

Refractive outcomes at 7 years postoperatively for 42 eyes with myopia (UDVA= uncorrected distance visual acuity, CDVA= corrected distance visual acuity, D=diopters, Preop=preoperative, Postop=postoperative): Uncorrected distance visual acuity(A); Change in corrected distance visual acuity(B); Spherical equivalent attempted vs achieved(C); Spherical equivalent refractive accuracy(D); Refractive astigmatism(E); Stability of spherical equivalent refraction(F).

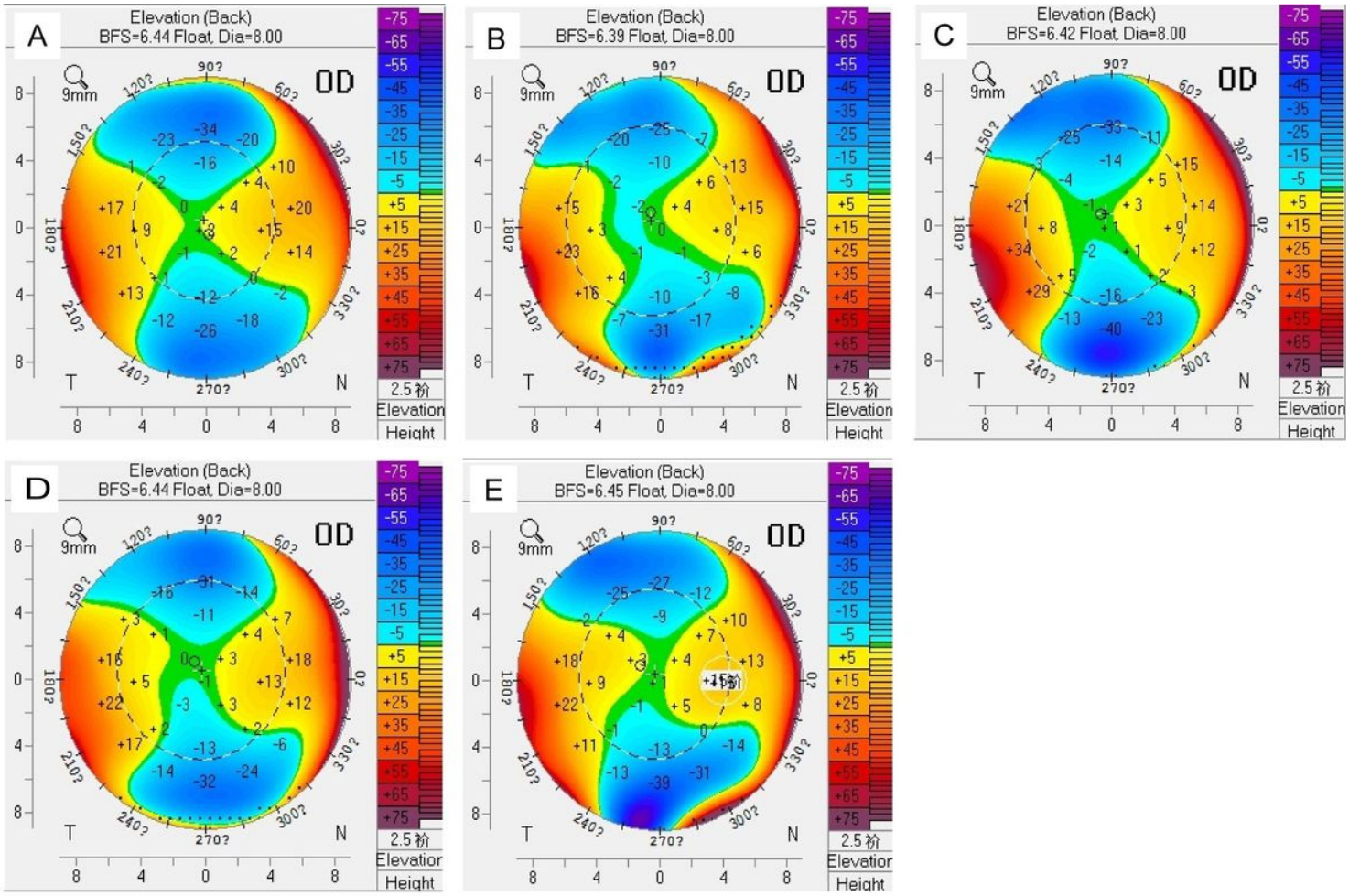

Figure 2

Comparison of posterior corneal surface maps obtained by corneal topography preoperatively (A) and 1 month (B), 1 year (C), 5 years (D), and 7 years (E) after small incision lenticule extraction (SMILE).