Endoscopic Repair of Delayed Stomach Perforation Arising From Penetrating Trauma: A Case Report

Jae hyun Yoon
Chonnam National University Hospital https://orcid.org/0000-0002-4993-2496

Chung Hwan Jun (estevanj@naver.com)
Mokpo Hankook Hospital https://orcid.org/0000-0002-7136-8350

Jae Pil Han
Mokpo hankook hospital

Ji Woong Yeom
Mokpo hankook hospital

Seung Ku Kang
Mokpo hankook hospital

Hyun Yi Kook
Chonnam National University Hospital

Sung Kyu Choi
Chonnam National University Hospital

Case report

Keywords: endoscopy, endoloop, trauma, perforation, clip, stomach, surgery, penetration

Posted Date: August 21st, 2020

DOI: https://doi.org/10.21203/rs.3.rs-62364/v1

Abstract

Background

Primary endoscopic closure of perforated gastric wall during endoscopic procedures is mostly effective and well-tolerated; however, there are only few studies on the efficacy of endoscopic management in traumatic delayed gastric perforation.

Case presentation:

Here, we report the case of a 39-year-old woman who presented with multiple penetrating trauma in the back and left abdominal cavity. Initial imaging studies revealed left diaphragmatic disruption and peri-splenic hemorrhage without gastric perforation. An emergency primary repair of the disrupted diaphragm with omental reduction and suture of the lacerated lung was performed; however, delayed free-perforation of the gastric wall was noted on computed tomography after 3 d. Following an emergency abdominal surgery for primary repair of the gastric wall, re-perforation was noted 15 d post-operatively. The high re-operation risk prompted an endoscopic intervention using two endoloops and 11 endoscopic clips using a novel modified purse-string suture technique. The free perforated gastric wall was successfully repaired without additional surgery or intervention. The patient was discharged after 46 d without any complications.

Conclusions

Endoscopic closure with this novel technique involving endoloops and endoscopic clips can be a useful therapeutic alternative to re-operation for delayed gastric perforation caused by penetrating trauma.

Background

Stomach perforation due to trauma is an emergent critical condition, and immediate management of the perforated gastric wall is highly essential. Gastric trauma has a very high mortality rate (19–43%), and a majority of the cases require primary surgical repair [1].

Although surgical management of gastric perforation is generally effective in traumatic stomach perforation, in situations wherein surgery is unfeasible or in a stable patients without sepsis, endoscopic treatment modalities can be considered as alternatives. Endoscopic treatment method with an endoloop and clips (purse-string suture technique) has showed good results in few reports for large iatrogenic gastrointestinal (GI) perforation closures caused after endoscopic therapeutic procedures [2–4]. Also a case report exhibited successful closure of small gastric penetrating stab wound with clips.[5] Endoscopic treatment might be an effective option to treat GI perforation owing to it being minimally invasive, and associated with fast recovery and relatively low costs compared to surgery.[6] However, there is limited

data on the efficacy of endoscopic closures for trauma-induced delayed GI tract perforation and anastomotic leakage.

This is the first case report on the successful execution of a novel modified endoscopic purse-string suture technique for delayed stomach perforation after primary surgical repair.

Case Presentation

A 39-year-old woman was rushed to the emergency department due to multiple penetrating stab wounds from a knife. Initial vital signs were stable (blood pressure: 120/60 mmHg, heart rate: 84/min, respiratory rate: 16/min, and body temperature: 36.4 °C). Physical examination revealed three stab wounds in the upper back and one in the left flank with herniated omental fat. There were no definite physical signs of pan-peritonitis. Initial computed tomography (CT) revealed a left hemopneumothorax and focal diaphragmatic disruption (Figure 1a) with left lower lobe and splenic lacerations and hematomas in the perisplenic space and the lesser sac (Figure 1b). No definite stomach perforation was observed (Figure 1c). An emergency primary repair of the disrupted diaphragm was performed with omental fat reduction and suturing for the lacerated lung. Follow-up CT performed on postoperative day (POD) 1 revealed an increased amount of hemoperitoneum without evidence of active bleeding or gastric perforation. The hemoperitoneum secondary to minor splenic laceration was closely monitored without further surgery.

On POD 3, tachycardia, low-grade fever, and decreased serum hemoglobin were observed. Follow-up CT revealed free perforation of the upper gastric posterior wall (PW), with newly developed hemoperitoneum and pneumoperitoneum (Figure 2a and 2b). A second emergency operation revealed a 3-cm long free perforation in the PW of the upper stomach, with severe surrounding inflammation. Primary repair of the perforated gastric wall was performed. Four drainage tubes were inserted in the intra-abdominal cavity, which were later forcibly removed by the patient due to post-operative delirium. On POD 9, follow-up CT revealed peritonitis with a multi-loculated abscess in the upper abdominal cavity, which was drained using a percutaneous drainage (PCD) catheter. To screen for possible undetected small perforations, upper gastrointestinal (UGI) series performed on POD 12 with gastrografin showed no signs of leakage at the perforation site. The daily amount of PCD decreased; however, CT on POD 18 detected a disrupted gastric wall with remaining fluid collection. UGI series also revealed prominent leakage (Figure 3a and 3b). Due to the short 14-d interval from the most recent surgery, severe adhesion and inflammation in the operative field were presumed. Therefore, there was a high-risk associated with a reoperation. Hence, we decided to conducta primary closure using a double-channel endoscope (Olympus GF UCT 260, Tokyo, Japan) under sedation with intravenous propofol.

Esophagogastroduodenoscopy (EGD) revealed a 2-cm free perforation in the gastric wall of the upper-body/greater-curvature with a large amount of pus draining into the stomach cavity via the perforated lumen (Figure 4a). Steps for the purse-string technique are as follows: First, an endoloop is placed at the perforation site. The first clip is then placed at the proximal defect site and the endoloop is anchored on the perforated lesion mucosa. The subsequent clips fix the endoloop beside the previous clips. After the

endoloop and clips encircle the defect, the rim of the opening is approximated by fastening the endoloop using the purse-string technique.[7] However due to severe edema and friability of the gastric mucosa, we attached four fixing clips (Optimos™ disposable clip, Taewoong Medical, Gimpo, South Korea) as pillars at the margin of the perforated lumen in advance. Then, we placed an endoloop (Olympus HX-20U-1, Tokyo, Japan) encircling the margin of the attached clips, and fixed it to the gastric mucosa using seven additional endoscopic clips (Figure 4b). Finally, we fastened the endoloop, which tightened and secured the perforated lumen (Figure 4b). Follow-up CT and EGD at POD 25 revealed a successfully healed gastric lumen and a decreased loculated fluid collection (Figure4c). Feeding was initiated on POD 39 and she was discharged on POD 46 without other complications.

Discussion And Conclusions

Gastric perforation may be caused by trauma, malignant tumors, benign ulcers, and iatrogenic factors such as endoscopic procedures. Severe gastric injuries secondary to penetrating abdominal trauma occur in 7–20% of the cases, and are associated with several complications [8]. Injuries to other visceral organs can occur in 65–74% of the cases [9], and liver lacerations can co-exist with these injuries, especially diaphragmatic injury [10]. Physicians should be aware of delayed gastric perforation, because a superficial injury of the gastric wall can progress to free perforation [11]. In our case, the initial CT scan showed only splenic hemorrhage with diaphragmatic injury, but the patient developed free gastric perforation after 3 d; we believe that a thorough surgical exploration of the abdominal cavity during the first operation could have prevented delayed gastric perforation [9, 12]. Furthermore, we believe that the second delayed perforation of the stomach wall occurred due to perigastric fluid accumulation that may have interrupted stomach wall healing.

The treatment modality differs depending on the etiology and severity of the gastric perforation. Therapeutic endoscopy can promptly identify free perforation of the gastric wall, thereby allowing adequate and successful management. Accordingly, recent studies have demonstrated good results from on-site endoscopic closure of GI tract perforations [3, 13]. However, the immediate detection and management of free perforation may be difficult in gastric perforation from an external force, such as blunt or penetrating trauma. With delayed perforation, endoscopic closure of the perforation site may be challenging due to bowel edema, inflammation, and fibrosis of the surrounding tissues.

Our case suggests that when surgery is unfeasible due to unexpected patient conditions, such as delayed gastric re-perforation or leakage from the repair site, salvage treatment using endoscopy may be preferable to re-operation, which is associated with high morbidity and mortality [14]. Endoloops and endoscopic clips for the closure of GI tract perforation are effective treatment modalities [2, 3]. However, existing studies have only reported on the efficacy of on-site endoscopic closure for early GI perforation and have limited data for delayed GI tract perforation and anastomotic leakage after trauma. Our case offers a novel technique for these situations. Thus, for swollen and friable gastric mucosa (often observed in traumatic gastric perforation), using the modified purse-string technique (i.e., placing the

“pillar clips” before the endoloop to retain a sufficient margin of the perforated lumen) over the conventional purse-string technique may be more appropriate. Regrettably, an extensive abdominal examination during the first surgery may have identified the gastric injury and prevented perforation and complications. Therefore, thorough surgical exploration of the abdominal cavity should be considered in cases of abdominal trauma, especially those with penetrating diaphragmatic injury.

In conclusion, endoscopic treatment using this novel modified purse-string technique can successfully manage delayed re-perforation of the stomach due to trauma, without complications or subsequent surgery. The successful implementation of the modified purse-string technique in this case merits further study for both safety and efficacy in large scale trials.

Abbreviations

GI
Gastrointestinal
CT
Computed tomography
POD
Postoperative day
PW
Posterior wall
PCD
Percutaneous drainage
UGI
Upper gastrointestinal
EGD
Esophagogastroduodenoscopy

Declarations

Ethics approval and consent to participate:

The patient provided written informed consent for the publication of this case report (in accordance with the Declaration of Helsinki).

Consent for publication:

Obtained

Availability of data and materials:

Available on request

Competing interests:

The authors declare that they have no competing interests.

Funding:

Not applicable.

Authors’ contributions:

JPH and CHJ analyzed and interpreted the patient data and clinical course following the endoscopic closure of the stomach. JWY and SKK performed the surgery and participated in the revision of the manuscript. JHY was a major contributor in writing the manuscript. All authors read and approved the final manuscript.

Acknowledgements:

None

References

1. Edelman DA, White MT, Tyburski JG, Wilson RF. Factors affecting prognosis in patients with gastric trauma. Am Surg. 2007;73(1):48–53.
2. Ryu JY, Park BK, Kim WS, Kim K, Lee JY, Kim Y, et al. Endoscopic closure of iatrogenic colon perforation using dual-channel endoscope with an endoloop and clips: methods and feasibility data (with videos). Surgical endoscopy. 2019;33(4):1342–8.
3. Shi D, Li R, Chen W, Zhang D, Zhang L, Guo R, et al. Application of novel endoloops to close the defects resulted from endoscopic full-thickness resection with single-channel gastroscope: a multicenter study. Surgical endoscopy. 2017;31(2):837–42.
4. Dabizzi E, De Ceglie A, Kyanam Kabir Baig KR, Baron TH, Conio M, Wallace MB. Endoscopic "rescue" treatment for gastrointestinal perforations, anastomotic dehiscence and fistula. Clinics research in hepatology gastroenterology. 2016;40(1):28–40.
5. Addley J, Ali S, Lee J, Taylor M, Lowry P, Mitchell RM. Endoscopic clip closure of penetrating stab wound to stomach. Endoscopy. 2008;40(Suppl 2):E219-20.
6. Sun K, Chen S, Ye J, Wu H, Peng J, He Y, et al. Endoscopic resection versus surgery for early gastric cancer: a systematic review and meta-analysis. Digestive endoscopy: official journal of the Japan Gastroenterological Endoscopy Society. 2016;28(5):513–25.

7. Shi Q, Chen T, Zhong YS, Zhou PH, Ren Z, Xu MD, et al. Complete closure of large gastric defects after endoscopic full-thickness resection, using endoloop and metallic clip interrupted suture. Endoscopy. 2013;45(5):329–34.
8. Durham RM, Olson S, Weigelt JA. Penetrating injuries to the stomach. Surg Gynecol Obstet. 1991;172(4):298–302.
9. Leppaniemi A, Haapiainen R. Diagnostic laparoscopy in abdominal stab wounds: a prospective, randomized study. The Journal of trauma. 2003;55(4):636–45.
10. Lee SH, Chou SH, Kao EL. Diaphragmatic injury. Gaoxiong yi xue ke xue za zhi = The. Kaohsiung journal of medical sciences. 1991;7(12):622–7.
11. Sung CK, Kim KH. Missed injuries in abdominal trauma. The Journal of trauma. 1996;41(2):276–82.
12. Agresta F, Ansaloni L, Baiocchi GL, Bergamini C, Campanile FC, Carlucci M, et al. Laparoscopic approach to acute abdomen from the Consensus Development Conference of the Societa Italiana di Chirurgia Endoscopica e nuove tecnologie (SICE), Associazione Chirurghi Ospedalieri Italiani (ACOI), Societa Italiana di Chirurgia (SIC), Societa Italiana di Chirurgia d'Urgenza e del Trauma (SICUT), Societa Italiana di Chirurgia nell'Ospedalita Privata (SICOP), and the European Association for Endoscopic Surgery (EAES). Surgical endoscopy. 2012;26(8):2134-64.
13. Abe S, Minagawa T, Tanaka H, Oda I, Saito Y. Successful endoscopic closure using over-the-scope clip for delayed stomach perforation caused by nasogastric tube after endoscopic submucosal dissection. Endoscopy. 2017;49(S 01):E56-E7.
14. Hyman NH. Managing anastomotic leaks from intestinal anastomoses. The surgeon: journal of the Royal Colleges of Surgeons of Edinburgh Ireland. 2009;7(1):31–5.

Figures

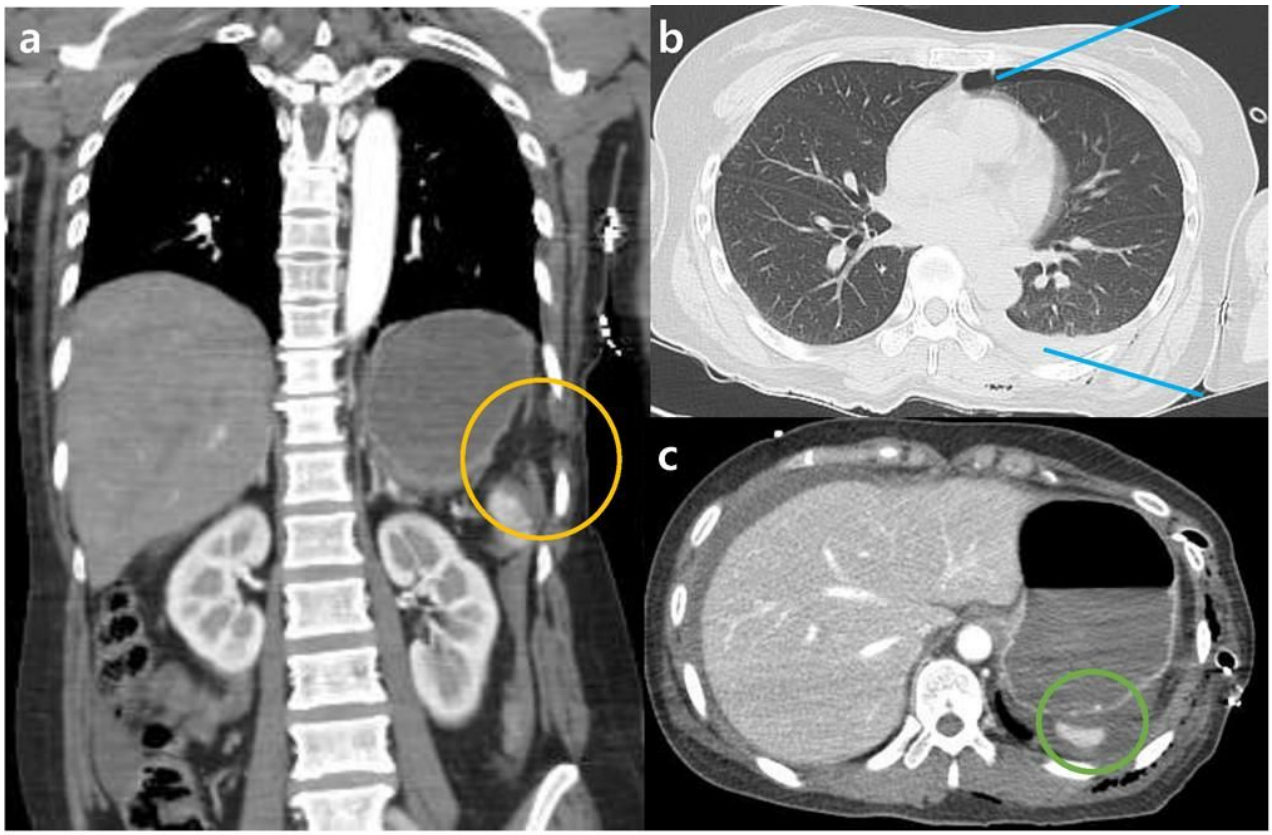

Figure 1

Initial computed tomography scan of the abdominal cavity. This scan shows left hemidiaphragmatic injury with herniation (1a, yellow circle), left hemopneumothorax (1b, blue line), and perisplenic hemorrhage without signs of gastric perforation (1c, green circle).

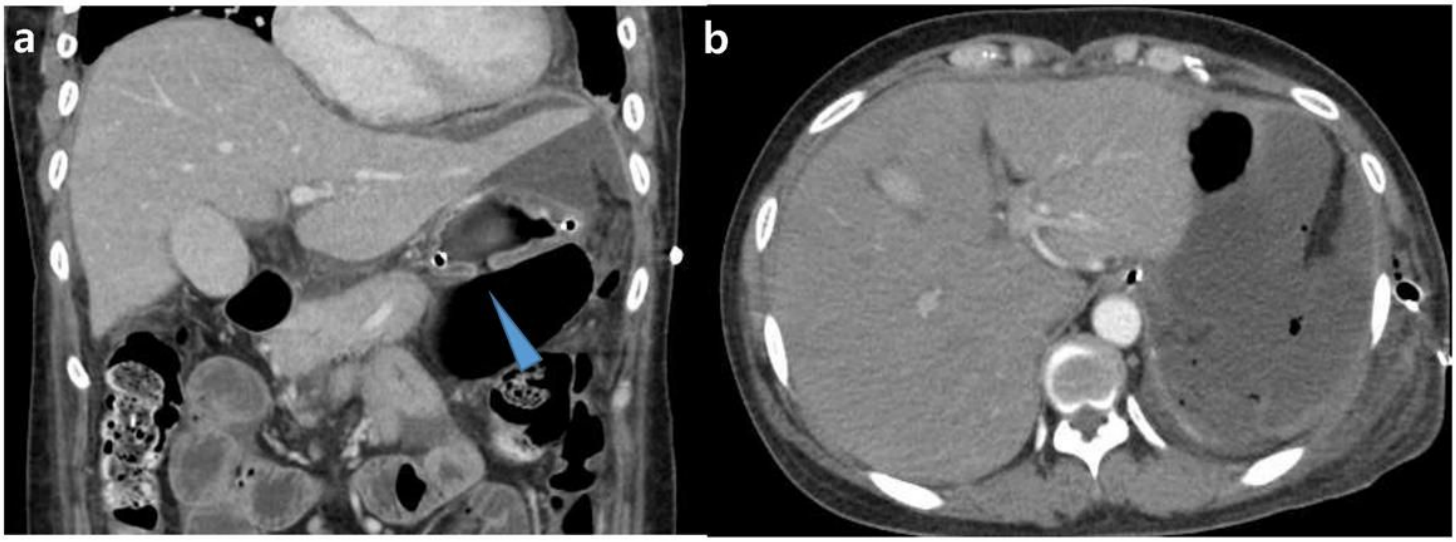

Figure 2

Follow-up computed tomography scan at post-operative day 3. Free perforation of the upper stomach (2a, blue arrowhead) with hemoperitoneum and pneumoperitoneum (2b) was noted.

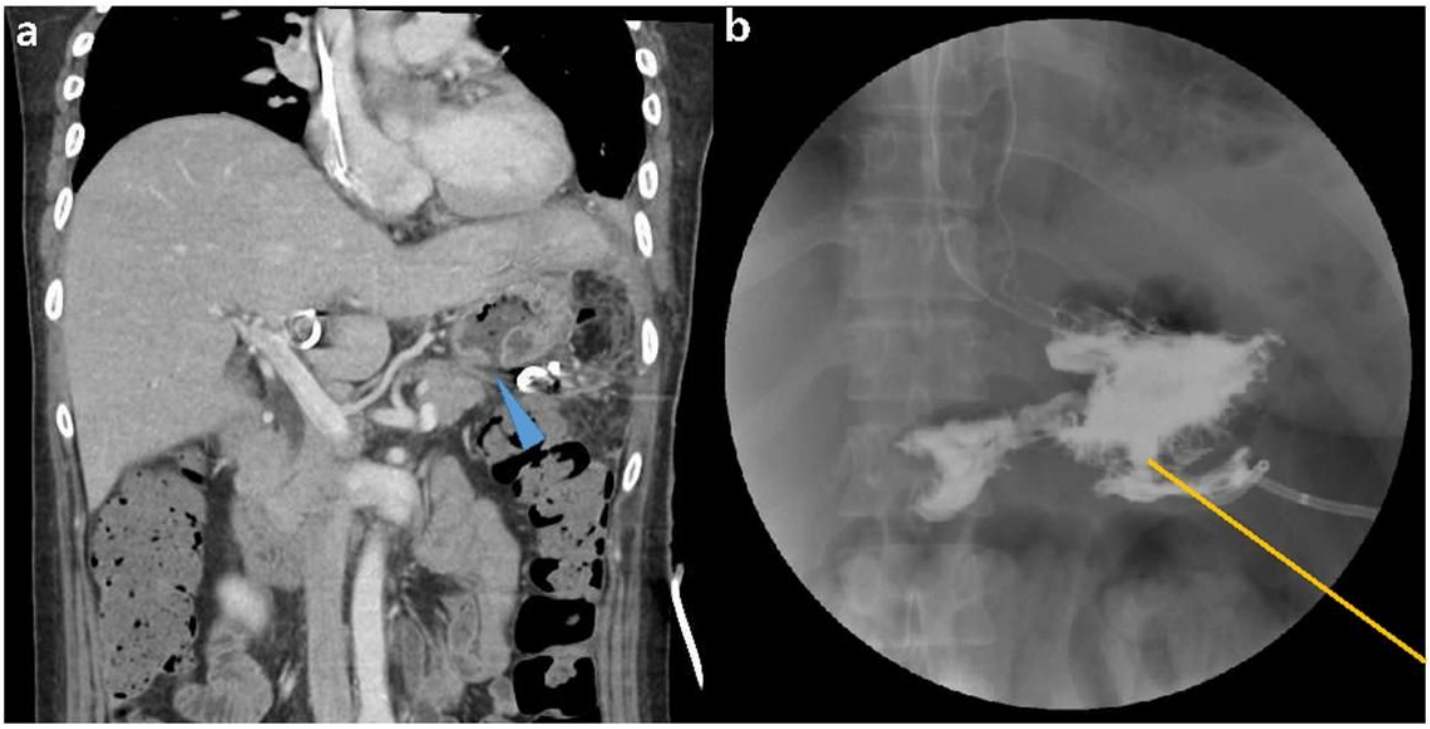

Figure 3

Radiologic findings of re-perforated gastric wall. Computed tomography findings showing gastric wall re-perforation (3a, blue arrowhead) and upper gastrointestinal series showing leakage of gastric contents (3b, yellow line)

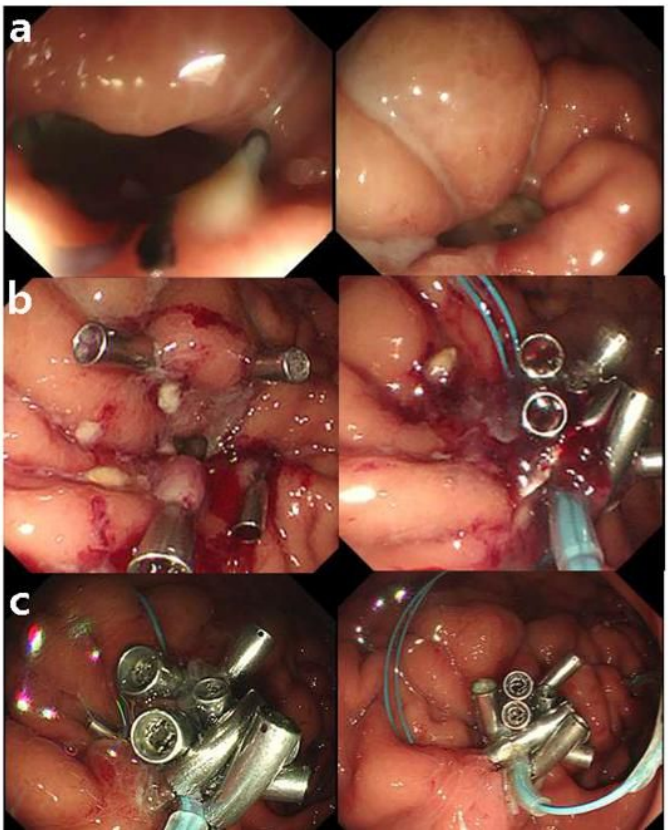

Figure 4

Primary closure of perforated gastric wall with endoscopic procedure. Endoscopic findings of the re-perforated gastric lumen (a) and primary closure of the gastric lumen with endoloops and clips using the modified purse-string technique (b). Final endoscopic and computed tomography findings on post-operative day 25 showing a well-healed gastric wall (c).

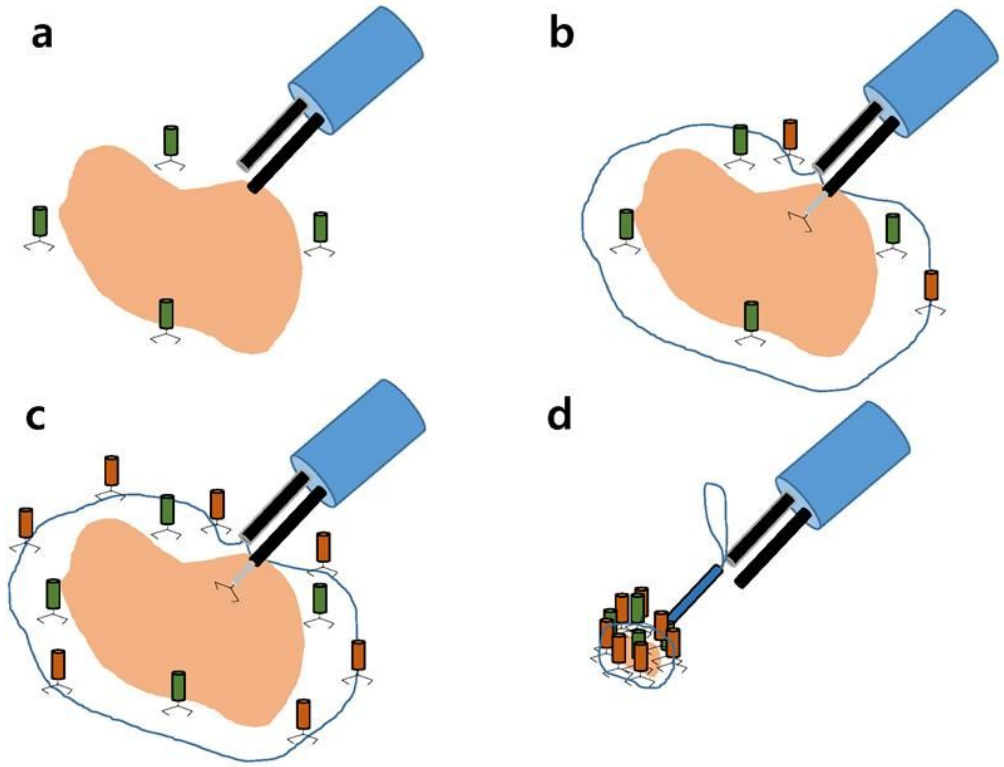

Figure 5

Schematic diagram of the purse-string technique with pillar clips. After detection of the perforated stomach lumen and swollen edematous mucosa, pillar clips are fixed near the margin of the perforated wall (a). The endoloop is then placed at the outer margin of the pillar clips, and is fixed with additional clips (b and c). Finally, the endoloop is fastened with the purse-string technique.