Axillary Ultrasound and Fine-Needle Aspiration Cytology to Predict Clinically Relevant Nodal Burden in Breast Cancer Patients .

Isabela Carlotti (isabelacarlotti@yahoo.com.br)
USP: Universidade de Sao Paulo https://orcid.org/0000-0002-3441-0556

Francisco José Candido dos Reis
USP: Universidade de Sao Paulo

Jurandyr Moreira de Andrade
USP: Universidade de Sao Paulo

Tamara Rodrigues
USP: Universidade de Sao Paulo

Jessica Borba
USP: Universidade de Sao Paulo

Amanda Homse Netto
USP: Universidade de Sao Paulo

Marina Polydoro
USP: Universidade de Sao Paulo

Daniel Guimarães Tiezzi
USP: Universidade de Sao Paulo https://orcid.org/0000-0002-2660-0093

Research Article

Keywords: breast cancer, lymph node metastasis, axillary ultrasound, fine needle aspiration cytology.

Posted Date: June 25th, 2021

DOI: https://doi.org/10.21203/rs.3.rs-623669/v1

Abstract

Background

Axillary lymph node involvement is one important prognostic factor in breast cancer, but the way to access this information has modified over the years.This study evaluated if axillary ultrasound (US) coupled with fine needle aspiration cytology (FNAC) can better predict clinically relevant node metastasis than physical exam, in patients with breast cancer.

Methods

This is a cross-sectional study with retrospective data collection of 241 women with operable breast cancer who were submitted to preoperative axillary assessment by physical exam, US and FNAC if suspicious nodes by imaging. We calculated sensitivity, specificity, and accuracy of the methods. We compared the patient's characteristics using chi-square test, parametrics and non parametrics statistics according to the variable.

Results

The most sensible method was US (0.59; 95% CI, 0.50-0.69) and the most specific was US coupled with FNAC (0.97; 95% CI, 0.92-0.99). Only 2,7% of the patients with normal axillary US had more than 2 metastatic nodes in the axillary lymph node dissection, against 50% of the patients with suspicious lymph nodes in the US and positive FNAC.

Conclusions

We found that axillary US and FNAC are more accurate than physical examination in detecting node metastasis in breast cancer patients. Moreover, axillary US coupled with FNAC can sort patients that have a few metastatic nodes at most from those with heavy axillary burden and could be one more tool to initially evaluate patients and define treatment´s strategies.

Background

Breast cancer is the most common malignancy among women all over the World, and responsible for almost 500.000 deaths each year (1). Axillary lymph node involvement is one important prognostic factor, but the way to access them has modified over the years(2). Axillary lymph node dissection (ALND) was performed routinely since William Halsted (3) with great morbidity, specially lymphedema and loss of arm function. In the 1990´s the sentinel node biopsy (SLNB) emerged, leading to the same important prognostic information and minimal morbidity, becoming the standard of care in the management of the axilla in clinically node negative breast cancer patients(4) .

More recently, the role of axillary dissection in sentinel node positive, early breast cancer patients has been questioned by several trials, including Z0011. They found that ALND did not confer an advantage compared to SLNB in survival nor recurrence, in a subset of T1-2 patients with no palpable adenopathy and 1 or 2 metastatic lymph nodes(5).

Following this trend, non invasive and costly methods to access the axilla, such as PET/CT and MRI, have been studied. Axillary ultrasonography (US) coupled with fine-needle aspiration cytology (FNAC) for the suspicious nodes is a low cost, safe procedure that could evaluate the axillary status pre-operatively, sparing time and costs of an unnecessary SLNB and helping clinicians to select patients that could benefit from NACT (6,7).

The aim of our study was to evaluate if axillary US coupled with FNAC of the suspicious nodes can better predict lymph node metastasis than physical exam in patients with breast cancer. Moreover, we evaluated if axillary US and FNAC can sort patients with clinically heavy nodal burden from those with minimal or little lymph node involvement.

Methods

Study design

This is a cross-sectional study with retrospective data collection of women with breast cancer who were submitted to preoperative axillary ultrasound. The patients were assessed and treated at the Breast Diseases Division of Hospital das Clínicas of Ribeirão Preto Medical School, University of São Paulo from August 2015 to November 2019. Patients were excluded if they did not undergo surgery, if they underwent neoadjuvant treatment, if they had distant metastasis or had tumors that were not primary from the breast. Three patients with suspicious lymph nodes in the US that weren´t submitted to FNAC were included only in the ultrasound analysis.

Protocol Of Preoperative Axillary Assessment

All patients underwent clinical assessment and axillary ultrasound before treatment. Patients with suspicious sonographic findings underwent FNAC of the most suspicious lymph node. The clinical assessment was performed by an experienced breast surgeon. Clinical axillary status was classified as N0 if no suspicious lymph node was identified, N1 if suspicious movable level I - II axillary lymph nodes were identified, or N2 if palpable suspicious level I - II axillary lymph nodes were clinically fixed or matted (8).

Ultrasound

The patients were assessed by axillary ultrasound scan using a wide-band linear transducer within at least 4 to 11 mHz range. The ultrasound systems used were Voluson 730 (GE Healthcare, Chicago, USA) until january 2018 and Voluson S10 (GE Healthcare, Chicago, USA) thereafter. We considered suspicious lymph nodes in the US, those with thickening of the cortex (larger than 3mm), eccentric medulla or absent medulla (Fig. 1). After the ultrasound, nodes considered suspicious underwent guided FNAC. FNAC was performed in the most representative abnormal node.

Statistical analysis

The postoperative histology was the gold standard for axillary status. The characteristics of patients with positive and negative nodes were compared using chi-square, non-parametric or parametric statistics according to variable types. We calculated sensitivity, specificity, and accuracy of physical exam, axillary US and US followed by FNAC when US was suspicious for metastasis.

Results

The study design is described in Fig. 2. A total of 241 patients with histologically confirmed breast cancer who underwent upfront surgery were included.

The characteristics of included patients according to the final axillary status is shown in Table 1. Forty six percent of the patients had at least one positive axillary lymph node. The distribution according to age, and tumor characteristics (size, grade, and immunohistochemistry biomarkers) were similar between the two groups. The clinical assessment of axillary lymph nodes showed cN1 and cN2 were more frequent among patients with positive axillary lymph nodes.

Table 1
Characteristics of patients according to the final axillary status.

Variable	Negative nodes	Positive nodes	p-value
Number of cases	n = 130	n = 111	
Age (range)	61.0 (31–88)	58.3 (27–88)	0.081
Tumor size (T)			0.111
1[a]	1 (0.8%)	1 (0.9%)	
1b	19 (14.6%)	5 (4.5%)	
1c	57 (43.8%)	59 (53.2%)	
2	46 (35.4%)	39 (35.1%)	
3	2 (1.5%)	0 (0%)	
4b	4 (3.1%)	3 (2.7%)	
Missing	1 (0.8%)	4 (3.6%)	
Clinical lymph nodes			< .001
N0	110 (84.6%)	65 (58.6%)	
N1	17 (13.1%)	40 (36%)	
N2	1 (0.8%)	6 (5.4%)	
Missing	2 (1.5%)	0 (0%)	
Ultrasound			< .001
Normal	103 (79.2%)	45 (40.5%)	
Suspicious	27 (20.8%)	66 (59.5%)	
Tumor grade			0.601
1	40 (30.8%)	28 (25.2%)	
2	70 (53.8%)	64 (57.7%)	
3	17 (13.1%)	17 (15.3%)	
Missing	3 (2.3%)	2 (1.8%)	
Estrogen receptor			0.184
Negative	23 (17.7%)	12 (10.8%)	
Positive	107 (82.3%)	99 (89.2%)	
Progesterone receptor			1
Negative	42 (32.3%)	35 (31.5%)	
Positive	88 (67.7%)	76 (68.5%)	
HER 2			0.637
Negative	111 (85.4%)	98 (88.3%)	
Positive	19 (14.6%)	13 (11.7%)	
Ki 67			0.54

Variable	Negative nodes	Positive nodes	p-value
Negative	41 (31.5%)	39 (35.1%)	
Positive	78 (60%)	60 (54.1%)	
Missing	11 (8.5%)	12 (10.8%)	
Surgery			0.457
Mastectomy	49 (37.7%)	48 (43.2%)	
Tumorectomy	81 (62.3%)	63 (56.8%)	

The individual accuracy of clinical assessment, axillary ultrasound and ultrasound combined with FNAC is shown in Table 2. Adding FNAC to axillary US did not modify the accuracy, because the increase in the specificity from 79–97% was associated with the decrease of sensitivity from 59–40%.

Table 2
Accuracy of diagnostic methods for axillary status considering any positive node in the surgery.

Method	Clinical	Ultrasound	Ultrasound and FNAC
Sensitivity	0.41 (0.32, 0.51)	0.59 (0.50, 0.69)	0.40 (0.30, 0.49)
Specificity	0.86 (0.79, 0.91)	0.79 (0.71, 0.86)	0.97 (0.92, 0.99)
PPV[a]	0.72 (0.59, 0.82)	0.71 (0.61, 0.80)	0.92 (0.80, 0.98)
NPV[b]	0.63 (0.55, 0.70)	0.70 (0.62, 0.77)	0.65 (0.58, 0.72)
Diagnostic accuracy	0.65 (0.59, 0.71)	0.70 (0.64, 0.76)	0.70 (0.64, 0.76)

[a]PPV: Positive predictive value, [b]NPV: Negative predictive value.

Twenty-seven out of 91 patients that were clinically node negative and did not have any suspicious lymph nodes in the US had metastatic nodes in the surgery: 18 patients with one positive node, 2 with micrometastasis, 3 with two positive nodes and 4 patients with more than two positive nodes.

We identified 99 patients that fit the ACOSOG Z0011 trial criteria: T1 or T2, cN0, submitted to conservative surgery followed by radiation therapy. All of them had preoperative axillary ultrasound. Only four patients (4%) had suspicious lymph nodes in the US and positive FNAC, but up to two metastatic nodes in the dissection. These four patients were overtreated according to the results from the ACOSOG Z0011 trial, because of the results of the US and FNAC.

On the other hand, we identified 13 patients that were clinically N1 or N2 but had non-suspicious nodes in the ultrasound and underwent sentinel node biopsy. Seven of these patients had no metastatic nodes, 2 had exclusive micrometastatic disease and 2 had up to two metastatic lymph nodes and did not get axillary dissection. These 11 patients (17% of the N + patients) had treatment deescalated because of the preoperative axillary ultrasound.

Suspicious axillary lymph nodes in the US and positive FNAC were associated with a heavier axillary burden. Among the 148 patients with normal axillary ultrasound, only 4 (2.7%) had more than 2 metastatic lymph nodes, while among the 93 with atypical lymph nodes in the US, thirty two (34%) had more than 2 metastatic nodes ($p < 0.005$). Moreover, among the 48 patients with positive FNAC, 24 (50%) had more than 2 axillary lymph nodes with metastasis ($p < 0.005$). Figure 3 shows the percentage of patients with more than three metastatic nodes in the ALND according to the clinical assessment, axillary US result and FNAC result.

Discussion

Axillary lymph node involvement is an important prognostic factor in breast cancer (9–12). It is well known that the accuracy of physical examination alone is limited (13), therefore, alternative methods are being investigated to effectively assess the axillary lymph node status with minimal morbidity and low cost. All preoperative methods used in this study (physical exam, axillary US and FNAC) missed metastatic axillary lymph nodes.

We found 29% positive nodes in women with normal sonographic and clinical N0 axillary status, therefore, the false negative rate of physical exam and axillary US was too high to substitute sentinel node biopsy. It is interesting to note that almost 96% of these patients with no suspicious nodes in the physical exam and the US had less than three positive nodes in the surgery. Therefore, physical exam and axillary ultrasound were able to predict accurately at least a low axillary lymph node involvement, but at the present moment it is not yet clear if that is enough information to tailor the adjuvant treatment(14). The ongoing SOUND trial (NCT02167490) is prospectively evaluating if preoperative imaging of the axilla in early breast cancer patients can identify patients with clinically relevant nodal burden and safely spare patients from SLN biopsy(15).

Patients with clinical N1 - N2 axillary status had a high rate of positive nodes even with normal ultrasound (55%). The absencee of neoplasic cells on FNAC in ultrasound suspicious nodes also did not exclude malignant nodes. The false negative rate of FNAC was 35%. FNAC was particularly useful though to confirm a metastatic lymph node when ultrasound was suspicious since the specificity of US was 79% while the specificity of FNAC was 97%. Therefore, before deciding about scalonating treatment (local or systemic) because of a suspicious lymph node image it is essential to perform a FNAC.

Patients with suspicious US and positive FNAC were more likely to have a higher disease burden than those with positive sentinel nodes alone, and therefore represent a distinct patient population that should be addressed carefully (16). In this context, the methods could help sort patients with high axillary burden that can benefit from neoadjuvant therapy, including deescalating axillary surgery.

To our understanding, axillary evaluation of breast cancer patients is an evolving topic, and axillary US coupled with FNAC could be one of the noninvasive strategies used to define therapy. The accuracy of the methods is high to sort patients that have a few metastatic lymph nodes at most from those with a heavy axillary burden (three or more positive nodes).

However, it is relevant to highlight the possible limitations of the methods, including a reasonably high false negative rate even when combining physical exam and US, and a small portion of cN0 patients and suspicious nodes in the US with positive FNAC that could have benefitted from sentinel node biopsy because fit the ACOSOG criteria. Better than one method alone is the combination of physical exam and axillary ultrasound findings. FNAC is especially useful when high specificity is intended.

Conclusion

Axillary US and FNAC are more accurate than physical exam in detecting lymph node metastasis in breast cancer patients and could be one more tool to initially evaluate them and define treatment´s strategies. A normal physical exam (cN0) and non-suspicious axillary nodes in the ultrasound can predict accurately at least a low axillary lymph node involvement. Likewise, a suspicious axillary US and positive FNAC are associated with relevant axillary burden and could be useful to sort patients that can benefit from neoadjuvant therapy.

List Of Abbreviations

ALND - axillary lymph node dissection

FNAC - fine needle aspiration citology

MRI - magnetic resonance imaging

NACT - neoadjuvant chemotherapy

PET/CT - positron emission tomography/computed tomography

SLN - sentinel lymph node

SLNB - sentinel lymph node biopsy

US - ultrasound

Declarations

Ethics approval and consent to participate

The study was approved by the Institutional Ethic Committee and the informed consent waived (CAAE: 49843815.8.0000.5440).

Consent for publication

Not applicable.

Availability of data and materials

The datasets used and/or analysed during the current study are available from the corresponding author on reasonable request.

Fundings

The authors did not receive any financial support for the research, authorship, and/or publication of this article.

Author´s contributions

IPCB - substantial contributions to the conception and design of the work, acquisition, analysis and interpretation of data and drafting the work.

FJCR - substantial contributions to the conception of the work, analysis and interpretation of data and revising it critically for important intellectual content.

JMA - substantial contributions to the conception of the work and revising it critically for important intellectual content.

TCGFR - substantial contributions to the acquisition, analysis and interpretation of data for the work. Revised it critically for important intellectual content.

JMCB - substantial contributions to the acquisition, analysis and interpretation of data for the work. Revised it critically for important intellectual content.

AHN - substantial contribution to the acquisition of, analysis and interpretation of data for the work. Revised it critically for important intellectual content.

MSP - substantial contribution to the acquisition of, analysis and interpretation of data for the work. Revised it critically for important intellectual content.

DGT - substantial contributions to the conception and design of the work, analysis and interpretation of data and revising the work critically for important intellectual content.

Competing interests

The authors declare that they have no competing interests.

Acknowledgments

Not applicable.

References

1. Ban K, Godellas C. Epidemiology of Breast Cancer. Surg Oncol Clin N Am. 1º de julho de 2014;23:409–22.
2. Yan M, Abdi MA, Falkson C. Axillary Management in Breast Cancer Patients: A Comprehensive Review of the Key Trials. Clin Breast Cancer. 2018;18(6):e1251–9.
3. Halsted WS. I. The Results of Operations for the Cure of Cancer of the Breast Performed at the Johns Hopkins Hospital from June, 1889, to January, 1894. Ann Surg. novembro de 1894;20(5):497–555.
4. (PDF) Axillary surgery in breast cancer: An updated historical perspective [Internet]. [citado 27 de abril de 2021]. Disponível em: https://www.researchgate.net/publication/345503861_Axillary_surgery_in_breast_cancer_An_updated_historical_perspective?_sg=iwRRlguFliJ_hWcNsYBX9_F70k7O4UkfbXdpTis31uO3ki7hxjwObSIWMPBM7ziux5WVKQTZs9T4sQM
5. Locoregional Recurrence After Sentinel Lymph Node Dissection With or Without Axillary Dissection in Patients With Sentinel Lymph Node Metastases: Long-term Follow-up From the American College of Surgeons Oncology Group (Alliance) ACOSOG Z0011 Randomized Trial - PubMed [Internet]. [citado 27 de abril de 2021]. Disponível em: https://pubmed.ncbi.nlm.nih.gov/27513155/
6. Gipponi M, Fregatti P, Garlaschi A, Murelli F, Margarino C, Depaoli F, et al. Axillary ultrasound and Fine-Needle Aspiration Cytology in the preoperative staging of axillary node metastasis in breast cancer patients. Breast Edinb Scotl. dezembro de 2016;30:146–50.
7. Sparing sentinel node biopsy through axillary lymph node fine needle aspiration in primary breast cancers | World Journal of Surgical Oncology | Full Text [Internet]. [citado 27 de abril de 2021]. Disponível em: https://wjso.biomedcentral.com/articles/10.1186/1477-7819-11-296
8. Amin MB, Greene FL, Edge SB, Compton CC, Gershenwald JE, Brookland RK, et al. The Eighth Edition AJCC Cancer Staging Manual: Continuing to build a bridge from a population-based to a more “personalized” approach to cancer staging. CA Cancer J Clin. março de 2017;67(2):93–9.
9. Maráz R, Zombori T, Ambrózay É, Cserni G. The role of preoperative axillary ultrasound and fine-needle aspiration cytology in identifying patients with extensive axillary lymph node involvement. Eur J Surg Oncol J Eur Soc Surg Oncol Br Assoc Surg Oncol. novembro de 2017;43(11):2021–8.
10. Nemoto T, Vana J, Bedwani RN, Baker HW, McGregor FH, Murphy GP. Management and survival of female breast cancer: results of a national survey by the American College of Surgeons. Cancer. 15 de junho de 1980;45(12):2917–24.
11. Carter CL, Allen C, Henson DE. Relation of tumor size, lymph node status, and survival in 24,740 breast cancer cases. Cancer. 1º de janeiro de 1989;63(1):181–7.
12. Effects of radiotherapy and of differences in the extent of surgery for early breast cancer on local recurrence and 15-year survival: an overview of the randomised trials - PubMed [Internet]. [citado 27 de abril de 2021]. Disponível em: https://pubmed.ncbi.nlm.nih.gov/16360786/
13. Sacre RA. Clinical evaluation of axillar lymph nodes compared to surgical and pathological findings. Eur J Surg Oncol J Eur Soc Surg Oncol Br Assoc Surg Oncol. junho de 1986;12(2):169–73.
14. A Positive Node on Ultrasound-Guided Fine Needle Aspiration Predicts Higher Nodal Burden Than a Positive Sentinel Lymph Node Biopsy in Breast Carcinoma | SpringerLink [Internet]. [citado 27 de abril de 2021]. Disponível em: https://link.springer.com/article/10.1007/s00268-016-3557-3
15. Gentilini O, Veronesi U. Abandoning sentinel lymph node biopsy in early breast cancer? A new trial in progress at the European Institute of Oncology of Milan (SOUND: Sentinel node vs Observation after axillary UltraSouND). Breast Edinb Scotl. outubro de 2012;21(5):678–81.
16. Boone BA, Huynh C, Spangler ML, Sumkin J, Johnson R, McGuire KP, et al. Axillary Lymph Node Burden in Invasive Breast Cancer: A Comparison of the Predictive Value of Ultrasound-Guided Needle Biopsy and Sentinel Lymph Node Biopsy. Clin Breast Cancer. outubro de 2015;15(5):e243-248.

Figures

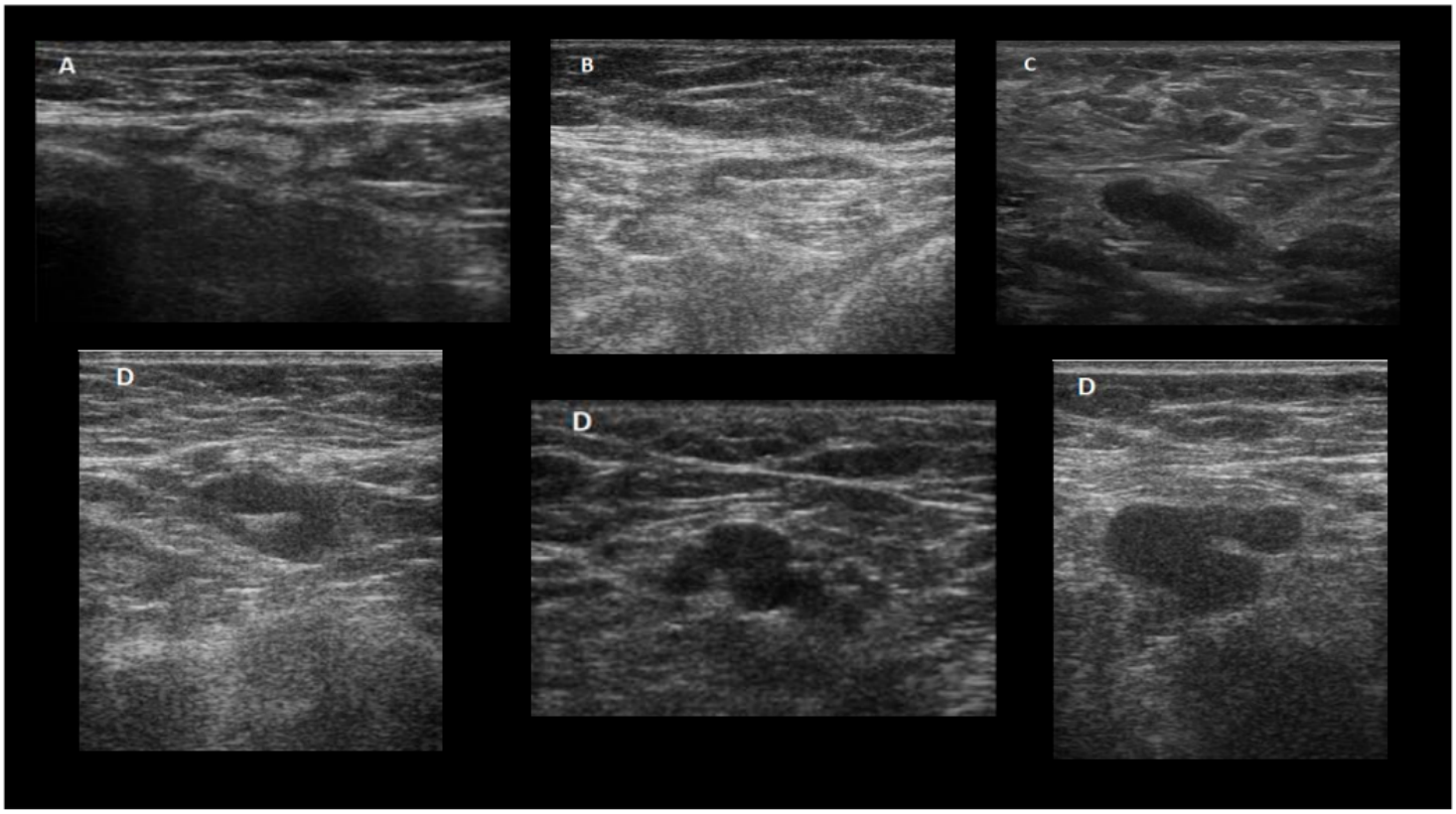

Figure 1

Axillary lymph node US images. Legend Figure 1: Axillary US images of non suspicious lymph nodes in clinically node negative patients and non metastatic nodes in the surgery (A). Axillary lymph node with eccentric thickening of the cortex in the US, positive FNAC and one metastatic lymph node in the ALND (B). Atypical lymph node in the US in a clinically N1 patient, with positive FNAC and one metastatic node in the ALND(C). Atypical lymph node in clinically node negative patients, with positive FNAC and more than three metastatic nodes in the ALND (D).

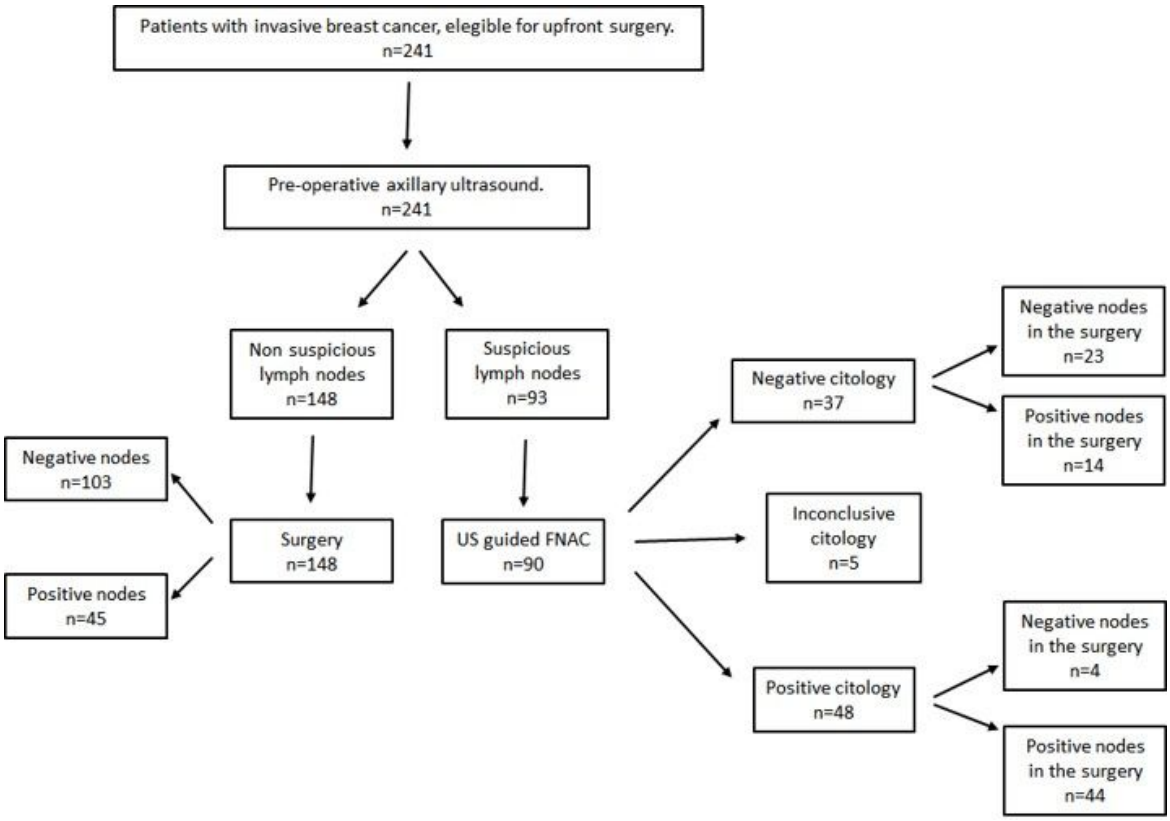

Figure 2

Study design.

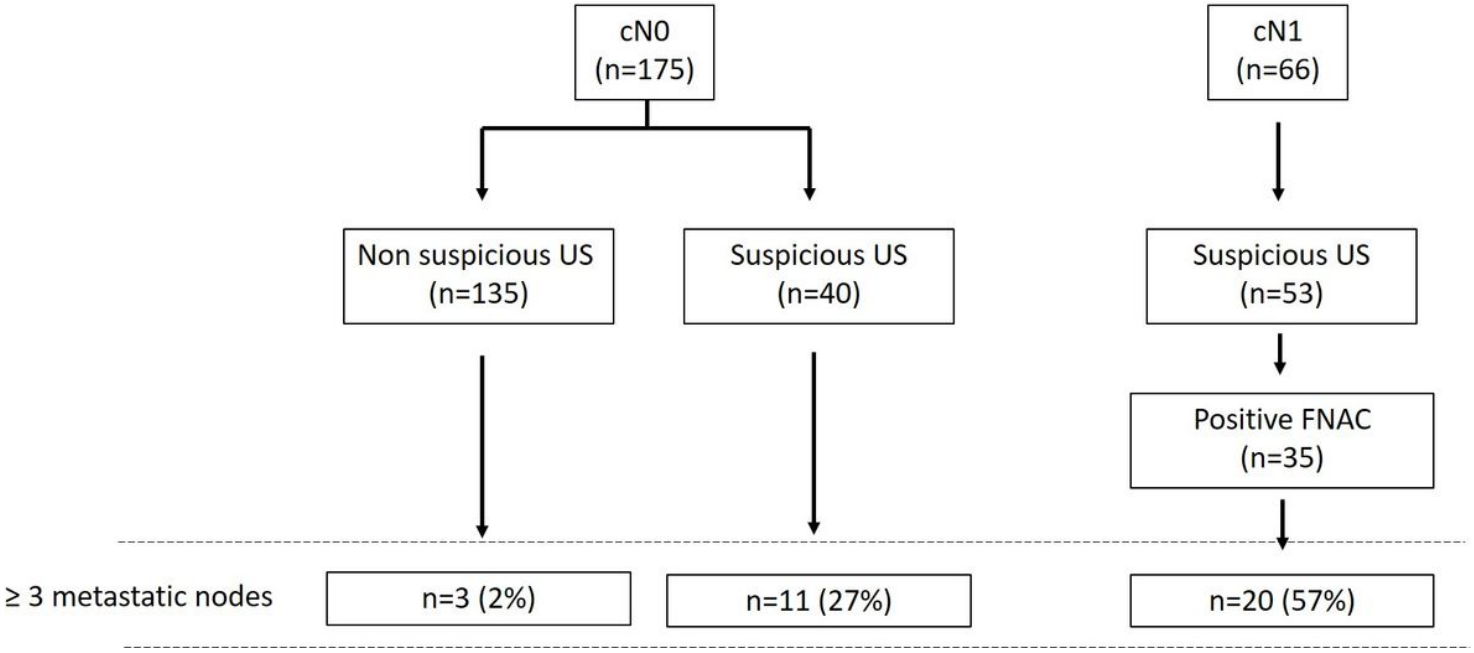

Figure 3

Massive axillary involvement according to the clinical status and US imaging. Legend Figure 3: Percentage of patients with high axillary burden (≥ 3 metastatic nodes in the ALND) according to the clinical assessment, axillary US result and FNAC result.