Mid-term Effect of Key-hole and ACDF for Treatment Cervical Spondylotic Radiculopathy

Feng Chaoqun (1021062572@qq.com)
Chengdu University of Traditional Chinese Medicine https://orcid.org/0000-0003-3210-9791

Li Tong
Chengdu University of Traditional Chinese Medicine Affiliated Hospital

Zhao Min
Chengdu University of Traditional Chinese Medicine

Jiang Leiming
Chengdu University of Traditional Chinese Medicine Affiliated Hospital

Li Ruoyan
Chengdu University of Traditional Chinese Medicine Affiliated Hospital

Tang Xiaochen
Chengdu University of Traditional Chinese Medicine Affiliated Hospital

Fan Xiaohong
Chengdu University of Traditional Chinese Medicine Affiliated Hospital

---

Research article

Keywords: Cervical Spondylotic Radiculopathy, Anterior Cervical Decompression and Fusion, Key-hole, Full-endoscopic Cervical Discestomy

Posted Date: September 1st, 2020

DOI: https://doi.org/10.21203/rs.3.rs-62846/v1

Abstract

Background: Compare the mid-term clinical efficacy of Key-hole and ACDF in the treatment of single segment cervical spondylotic radiculopathy.

Methods: From June 2016 to June 2018, a retrospective study was conducted on 30 patients with single segment cervical spondylosis radiculopathy who were divided into the observation group (Key-hole group) of 14 cases and the control group (ACDF group) of 16 cases. SF-MPQ pain score, NDI score and JOA function score were compared between the two groups on 1 day before operation, 7 days, 3 months after operation and the last follow-up. Meanwhile, the operation time, hospitalization days and orthopedic treatment cost of the two groups were compared for comprehensive evaluation.

Results: The follow-up time of 30 patients was 22–34 months, with an average of 24.7 (± 5.1) months. The results showed that SF-MPQ score, NDI score and JOA score were significantly improved at each time point after the operation ($P < 0.05$). The results showed that the VAS score, PPI score and NDI score of the Key-hole group were better 7 days after operation ($P < 0.05$), but there was no significant difference between the two groups at 3 months after operation and the last follow-up ($P > 0.05$). There were significant differences between the two groups in operation time, hospitalization days and treatment cost ($P < 0.05$).

Conclusion: Key-hole and ACDF are both effective in the mid-term treatment of single segment cervical spondylotic radiculopathy. However, Key-hole group was superior to ACDF group in terms of hospitalization days, treatment costs, surgical comfort and surgical trauma recovery.

Background

Cervical spondylotic radiculopathy (CSR) is a common cervical disease caused by the degeneration of cervical intervertebral disc and adjacent structures, resulting in nerve root compression. The clinical symptoms usually include neck and shoulder stiffness, pain, limited movement, unilateral or bilateral upper limb radiation pain, corresponding skin segment paresthesia, muscle weakness, etc[1]. Among them, conservative treatment and improvement of living habits can effectively alleviate the disease, but there are still patients whose symptoms can not be improved which seriously affects the quality of life and causes great harm to body and mind. Such patients should be treated with surgery in time on the premise of grasping the indications.

Anterior cervical decompression and fusion (ACDF) has been reported by Smith and Robinson in 1955[2]. After more than half a century of research and development, this intermuscular approach, resection of intervertebral disc, direct removal of compression material, decompression of nerve root, and bone graft fusion, has become the benchmark of CSR treatment. Its excellent clinical efficacy has been confirmed in many reports around the world[3–5]. As a new surgical method for the treatment of CSR, Key-hole technology was first reported by Ruetten et al in 2007[6], and the research on this minimally invasive spinal surgery technology has never stopped. With the rise of minimally invasive spine wave, especially in the field of lumbar spine, the future development direction of spinal surgery must be subtle and accurate. More device research and development and auxiliary equipment[7, 8] are used in clinical practice, which undoubtedly bring a better prospect for Key-hole technology. However, in the actual clinical choice, whether it is Key-hole or ACDF is still controversial in the world.

By retrospective analysis, the patients with single segment CSR who received surgery in the Department of Orthopedics, the Affiliated Hospital of Chengdu University of Traditional Chinese Medicine from June 2016 to June 2018 were divided into observation group (Key-hole group) and control group (ACDF group) according to different surgical methods. The Short-form of McGill Pain Questionnaire (SF-MPQ) score, Neck Disability Index (NDI) score, Japanese Orthopedics Association (JOA) function score, operation time, hospitalization time, treatment cost and complications were compared between the two groups.

Patients And Methods

Patients The patients were from June 2016 to June 2018 in the orthopedic department of our medical center. Finally, 14 patients in Key-hole group and 16 patients in ACDF group were included.

Materials ACDF group used anterior cervical plate internal fixation system from Medtronic Inc. and artificial bone implant fusion cage from Sichuan guona Technology Co., Ltd, while Key-hole group used bipolar spherical radiofrequency ablation electrode of Joimax GmbH.

Applicants inclusion criteria

(1)In accordance with the diagnostic criteria of CSR[9]; (2)Patients with unilateral nerve root involvement due to single segment disc herniation; (3) After regular conservative treatment for 2 months (no more than 6 months) [7], the patients had no obvious relief of symptoms, or the pain was acute and intolerable, and there were surgical indications; (4)Patients with good stability of cervical spine before operation; (5) All operations were performed by the same surgeon and his treatment team.

Applicants exclusion criteria

(1) Does not meet any of the inclusion criteria; (2)Patients with spinal tuberculosis, spinal tumor, cervical fracture and dislocation, severe osteoporosis and other diseases; (3)Ossification of posterior longitudinal ligament, ossification of ligamentum flavum and other bone compression; (4) Patients with cardiovascular and cerebrovascular accidents or mental disorders, which affect postoperative functional recovery and curative effect evaluation.

Group

According to different surgical methods, they were divided into observation group (Key-hole group) and control group (ACDF group). All patients have expressed informed consent to the treatment plan, which has been approved by the hospital ethics committee.

Methods

Preoperative Preparation (1) Before operation, detailed medical history was inquired, systematic review and specialized physical examination were completed repeatedly, and imaging examination was combined to ensure accurate positioning; (2)The patients in ACDF group were given trachea shift training and respiratory function exercise 3–5 days before operation[10]; (3) Because of the particularity of the operation site of the

neck, there is a risk of vascular and nerve injury. Blood was prepared routinely before operation, and methylprednisolone and mannitol were brought into the operating room.

ACDF Group Operation Process In supine position, the right anterior cervical incision was taken to expose the anterior space of platysma muscle and sternocleidomastoid muscle. The vascular sheath and visceral sheath were pulled to both sides. The anterior cervical fascia was cut to expose the longus cervical muscle. The vertebral body was marked with injection needle, and the responsible disc was determined by C-arm. Subsequently, the intervertebral disc tissue and vertebral hyperosteogeny were removed, the local posterior longitudinal ligament was removed, and the posterior wall of decompression was sneaked to the uncinate joint. The decompression of nerve root canal was expanded, and the dura mater and nerve root were explored to ensure that there was no pressure substance. According to the measurement results of vertebrae, the appropriate length of fusion cage, steel plate and locking nail were fixed in order. The position of the fusion cage was confirmed by fluoroscopy again. After decompression, the fusion cage was completely hemostatic. The wound was sutured layer by layer. Appropriate amount of cocktail (tranexamic acid + ropivacaine + compound betamethasone) was injected around the wound. The drainage tube was indwelled, he neck bracket was protected, and the operation was closed (Figs. 1).

Key-hole Group Operation Process In the Key-hole group, patients were placed in prone position with head high and feet low, and neck was fixed in slightly forward flexion position. Under fluoroscopy, the incision was made 1.0-1.5 cm away from the posterior midline of the neck. The 18 needle was used to puncture the bone surface of the lower edge of the upper lamina near the articular process. A 2 cm longitudinal incision was made. The 3-stage sleeve was expanded step by step (always pay attention to the puncture needle and expansion tube on the surface of the hard bone), and the working channel, lens and monitor were installed in turn. Under endoscope, the corresponding intervertebral space and upper and lower lamina were exposed. After the lower edge of the upper lamina and the upper edge of the lower lamina were thinned by the power grinding drill, part of the lamina and ligamentum flavum were removed by the bone biting forceps under the endoscope. If necessary, part of the facet joints should be removed, the nerve roots were exposed and pulled out, and the protruding nucleus pulposus tissue should be explored and removed by using endoscopic nucleus pulposus forceps. After confirming that the decompression was sufficient, bipolar radiofrequency electrocoagulation was used for hemostasis, proper amount of cocktail was injected along the channel, the working sleeve was pulled out, and the wound was sutured (Figs. 2).

Postoperative treatment (1)Two groups of patients were given routine symptomatic support, and did a good job in the prevention of laryngeal edema, epidural hematoma and other critical situations; (2)Perioperative pain management, using intravenous drip, intramuscular, oral multi-mode combined pain; (3)Perioperative fluid management, intravenous antibiotics were applied 24 hours after operation, and routine application of dexamethasone and mannitol is to reduce edema 3 days after operation. According to the preoperative Caprini thrombus risk assessment scale, if there was a high risk of thrombosis, low molecular weight heparin was used for anticoagulation 24 hours after operation; (4)In ACDF group, the drainage device was removed 1 day after operation (in case of unobstructed drainage, the drainage volume was less than 30 ml in 12 hours or less than 50 ml in 24 hours).

Outcome measures (1)The operation time, hospitalization time and treatment cost were recorded (the treatment cost was related to surgery, including examination cost, operation cost, perioperative management, complication treatment cost, etc. (2) The SF-MPQ pain score, NDI and JOA function scores were recorded 1 day before operation, 7 days after operation, 3 months after operation and the last follow-up; (3)Follow up the whole process and record the complications at any time.

Statistical analysis SPSS 25.0 statistical software package was used for data analysis. The counting data was analyzed by Fisher exact test, the rank data was analyzed by Mann-Whitney test, and the measurement data was expressed by`x ± s. The independent sample t-test was used for inter group comparison, and the paired sample t-test was used for comparison at each time point within the group. The difference was statistically significant ($P < 0.05$).

Results

Analysis of the number of participants According to the applicants inclusion and exclusion criteria, 30 patients with single segment CSR were enrolled, including 14 patients in Key-hole group and 16 patients in ACDF group. All of them were involved in the result analysis, and there were no cases of falling off.

Comparison of baseline data There was no significant difference in gender, age, operative segment, SF-MPQ pain score (including PRI score, VAS score, PPI score), NDI score and JOA score between the two groups ($P > 0.05$; Table 1–2).

Table 1
Preoperative Patients Baseline Data

Group	Case(n)	Gender (Male/Female,n)	Age	Operated levels(C3/4 /C4/5 /C5/6 /C6/7,n)
Key-hole	14	8/6	49.36 ± 8.72	1/1/6/6
ACDF	16	7/9	52.31 ± 12.89	0/4/7/5
t(Z)		-	-0.724	-0.715
P		0.715	0.475	0.475

Table 2
Preoperative Pain and Functional Scores

	Key-hole	ACDF	t	P
PRI	17.79 ± 1.62	18.00 ± 1.46	-0.380	0.707
VAS	8.08 ± 0.28	7.99 ± 0.32	0.826	0.416
PPI	4.14 ± 0.66	4.38 ± 0.50	-1.091	0.285
NDI	40.07 ± 2.84	40.94 ± 2.79	-0.841	0.408
JOA	12.00 ± 0.68	12.00 ± 0.63	0.000	1.000

Comparison of intraoperative and postoperative indexes The hospitalization days and treatment costs of Key-hole group were significantly better than ACDF group ($P < 0.05$), and the operation time of ACDF group was better than Key-hole group ($P < 0.05$; Table 3)

Table 3
Surgery-related Indicators

	Key-hole	ACDF	t	P
operation time (mins)	123.86 ± 37.08	88.50 ± 19.03	3.22	0.005
hospitalization days (days)	12.93 ± 2.92	16.81 ± 6.33	-2.106	0.044
treatment costs (CNY)	2.65 ± 0.14	6.82 ± 1.21	-13.654	0.000

The follow-up time of 30 patients was 22–34 months, with an average of 24.7(± 5.1) months. The VAS score, PPI score and NDI score of Key-hole group were significantly better than ACDF group 7 days after operation ($P < 0.05$). There was no significant difference between the two groups 3 months after operation and at the last follow-up ($P > 0.05$). Meanwhile, SF-MPQ pain score, NDI and JOA function score of the two groups were significantly improved at each time point after operation ($P < 0.05$; Table 4).

Table 4
Observation Indicators at Postoperative 7 days, 3 months and the last follow-up

group	n	PRI			VAS			PPI		
		7days	3months	the last	7days	3months	the last	7days	3months	the last
Key-hole	14	8.21 ± 2.75*	4.07 ± 3.75*	1.14 ± 1.03*	3.87 ± 1.51*	2.15 ± 1.70*	0.65 ± 0.47*	2.00 ± 0.679*	0.86 ± 0.86*	0.21 ± 0.43*
ACDF	16	9.56 ± 2.19*	3.63 ± 1.36*	1.25 ± 0.86*	5.00 ± 0.65*	1.78 ± 0.57*	0.72 ± 0.34*	2.69 ± 0.70*	0.81 ± 0.54*	0.38 ± 0.50*
t	-	-1.494	0.445	-0.312	-2.714	0.773	-0.459	-2.712	0.172	-0.940
P	-	0.146	0.660	0.758	0.011	0.451	0.650	0.011	0.865	0.355

group	n	NDI			JOA		
		7days	3months	the last	7days	3months	the last
Key-hole	14	20.50 ± 6.02*	11.29 ± 6.83*	6.29 ± 2.59*	15.00 ± 1.57*	16.07 ± 1.14*	16.50 ± 0.76*
ACDF	16	25.50 ± 5.43*	12.13 ± 3.36*	6.50 ± 3.23*	14.25 ± 1.24*	16.25 ± 0.78*	16.44 ± 0.73*
t	-	-2.392	-0.435	-0.199	1.462	-0.507	0.230
P	-	0.024	0.667	0.844	1.155	0.616	0.820

Note: * indicates that there is significant difference after operation and before operation ($P < 0.05$).

Implant/Surgery-Related Serious Adverse Events The biocompatibility of the implants was good. No infection, allergy, non-fusion and rejection were found during the follow-up. There were 3 patients with operation related complications during the whole follow-up period in the two groups. In the Key-hole group, one patient had transient nerve injury and one patient had residual nucleus pulposus. Among them, transient nerve injury was caused by the needle inadvertently entering the spinal canal during puncture positioning. The patient suffered from numbness of limbs and hypoesthesia after operation. Frankel was grade D[11]. After a series of conservative treatment such as nerve nutrition, dehydration and anti-inflammatory, the symptoms had obviously recovered at the time of discharge. At 3 months of follow-up, the patient recovered to normal level (Frankel Grade E), the symptoms of nerve root irritation were completely relieved, and the patient was in good condition at the last follow-up. Another patient had residual symptoms after operation, which was judged as residual nucleus pulposus after reexamination of cervical MRI. Because the compression was not completely relieved, the Key-hole operation was performed again 7 days after the operation. The patients recovered well after the operation, and the patients did not complain of related discomfort at the last follow-up. The incidence of postoperative complications in this group was 14.3%. In ACDF group, one patient had partial respiratory

function limitation after operation. The airway compression caused by soft tissue swelling and hematoma was eliminated by providing neck MRI and other auxiliary examinations. It was judged that the symptoms were caused by the aggravation of lung problems caused by surgical trauma stimulation. After symptomatic support and anti-infective therapy, the patient was transferred to the general ward for one week. The incidence of postoperative complications was 6.2%. There was no significant difference in postoperative complications between the two groups ($P > 0.05$; Table 5).

Table 5
Complications

Complication	Key-hole(n = 14)	ACDF(n = 16)
Transient nerve injury	1	0
Postoperative hematoma	0	0
Dyspnea	0	1
Residual nucleus pulposus	1	0
Dysphagia	0	0
Recurrent laryngeal nerve paralysis	0	0
Wound infection	0	0
Endophyte withdrawal	0	0
Incidence rate	14.3%	6.2%
P	0.586	

Discussion And Conclusion

As a model of anterior cervical decompression in the treatment of cervical spondylosis, ACDF has achieved a very high proportion in similar operations in the world, especially in the treatment of CSR[3–5, 12]. However, in addition to the excellent surgical results, the problems caused by this operation itself have also attracted more attention from spine surgeons. It includes: (1) recurrent pain caused by accelerated degeneration of adjacent segments[4], and 2/3 of the newly diagnosed patients were ineffective in conservative treatment and required a second operation[13]; (2)the high elastic modulus of implants increased the risk of complications of implants [14–16]; (3)laryngeal edema, epidural hematoma, acute nerve injury, postoperative isolated dysphagia, recurrent laryngeal nerve paralysis, wound infection and other complications seriously affect the prognosis of patients, and even directly endanger the life of patients; (4)in the single segment CSR treatment, Alan et al[13] found that the incidence of adjacent vertebral disease in single segment fusion was significantly higher than that in multi-level fusion. These problems also prompt spinal surgeons to seek new solutions in the face of CSR patients with longer life expectancy or more basic diseases.

Key-hole as a posterior cervical endoscopic surgery, it can effectively avoid the occurrence of serious adverse events related to the surgical approach, including anterior vascular and nerve injury, posterior open surgery trauma, axial symptoms and so on. At the same time, the range of motion of the cervical spine at the operative

segment is retained without iatrogenic instability of the cervical spine. Ren et al[14] also confirmed that the overall motion and stability of the cervical spine after Key-hole surgery are similar to those of the non-surgical group, and have biomechanical stability. Nguyen et al[16] found through cadaver test and analysis that the use of Key-hole surgery can reliably increase the area of nerve root canal in various functional positions, and it will not cause iatrogenic instability of cervical spine. Although Komp et al[17] found in the clinical follow-up observation that about 1/3 of the patients with Key-hole had MRI progressive degenerative sign, it did not cause related symptoms, surgical segment kyphosis or instability.

In this study, by comparing the preoperative and postoperative pain, function score, operation time, hospitalization days, treatment cost and other indicators of the two groups, the mid-term efficacy of the two methods in single segment CSR treatment was comprehensively evaluated. In terms of therapeutic effect, the two treatment methods have achieved satisfactory results. However, the VAS score, PPI score and NDI score of Key-hole group were significantly better than those of ACDF group at 7 days after operation ($P < 0.05$). According to the relevant data learning[18], the main reason for this difference is that the Key-hole operation is superior to ACDF in terms of operation comfort, including less blood loss, smaller surgical incision, smaller soft tissue trauma, no drainage tube placement, etc. So it has better feedback in the short-term follow-up after operation.

In terms of hospitalization days and treatment costs, the Key-hole treatment group was significantly better than the ACDF treatment group, which also directly reflected the absolute advantages of rapid recovery and low cost of the Key-hole minimally invasive technology. The prolongation of hospitalization days directly affects the time for patients to return to normal life, and the high cost of treatment directly increases the economic pressure of patients. The aggravation of these puzzles may affect the recovery of patients' condition and fail to achieve satisfactory surgical effect. As early as 1977, Engel put forward the modern medical model of biology, psychology and society in Science[19].As a complex social role, once a patient suffers from a physiological disease, the impact of his pain is not limited to the physiological level, and the chain effect at the psychological level will also bear irrefutable influence. In the same way, doctors need to consider the psychological, economic conditions and other aspects of patients when they choose treatment methods to solve the physiological pain of patients, and have achieved better surgical results.

At present, although the indications of Key-hole surgery are still limited, relevant literatures have reported the therapeutic effect of Key-hole technique in CSR of bony lateral spinal stenosis[20] and adopted different surgical approaches[21] to expand the scope of indications. With the application of electromagnetic navigation[7], auxiliary fixed arm[8] and other auxiliary equipment in clinic, the disadvantages such as radiation exposure, puncture risk, unstable channel and long operation time can be effectively solved.

In conclusion, Key-hole and ACDF are effective in single segment CSR. Meanwhile, compared with ACDF, Key-hole operation has the advantages of shorter hospitalization time, lower treatment cost, higher surgical comfort and faster postoperative recovery. Relying on better biomechanical results, Key-hole operation has a better application prospect. However, in terms of long-term efficacy, there are only theoretical studies at present, but there is still a lack of large sample, multi center prospective randomized double-blind controlled study.

Abbreviations

CSR: Cervical Spondylotic Radiculopathy; ACDF: Anterior Cervical Decompression and Fusion; SF-MPQ: Short-form of McGill Pain Questionnaire; PRI: Pain Rating Index; VAS: Visual Analogue Scale; PPI: Present Pain Intensity; NDI: Neck Disability Index; JOA: Japanese Orthopedics Association.

Declarations

Ethics approval and consent to participate:

Our retrospective study received Institutional Review Board approval and written informed consent was obtained from all participants.

Consent for publication:

Not applicable.

Availability of data and materials:

The datasets used and/or analysed during the current study are available from the corresponding author on reasonable request.

Competing interests:

The authors declare that they have no competing interests.

Funding:

This work was supported by project of major special projects in Sichuan Province—Research and industrialization of spinal minimally invasive 3D navigation system based on medical images (No.2018SZDZX0013).

Author's contributions:

C. Q. Feng: Designing the study, Analyzing the data, Writing the manuscript. T. Li: Designing the study, Analyzing the data, Reviewing the manuscript. M. Zhao: Compiling the data, Statistical analysis. L. M. Jiang: Performing surgery. R. Y. Li: Performing surgery. X. C. Tang: Compiling the data. X. H. Fan: Performing surgery, Reviewing the manuscript. All authors read and approved the final manuscript.

Acknowledgements:

Not applicable.

References

1. Iyer S, Kim HJ. Cervical radiculopathy. Curr Rev Musculoskelet Med. 2016;9(3):2 72–80.
2. Robinson R, Smith G. Anterolateral cervical disc removal and interbody fusion for cervical disc syndrome. Bull John Hopkins Hosp. 1955;96:223–4.
3. Liu CY, Zygourakis CC, Yoon S, et al. Trends in Utilization and Cost of Cervical Spine Surgery Using the National Inpatient Sample Database, 2001 to 2013. Spine (Phila Pa 1976). 2017;42(15):E906–13.
4. Gore DR, Sepic SB. Anterior Discectomy and Fusion for Painful Cervical Disc Disease. Vol. 23, Spine. 1998. p. 2047–51.
5. Hu Y, Lv G, Ren S, et al. Mid- to long-term outcomes of cervical disc arthroplasty versus anterior cervical discectomy and fusion for treatment of symptomatic cervical disc disease: A systematic Review and meta-analysis of eight prospective randomized controlled trials. PLoS One. 2016;11(2):1–17.
6. Ruetten S, Komp U, Merk H, et al. A new full-endoscopic technique for cervical posterior foraminotomy in the treatment of lateral disc herniations using 6.9-mm endoscopes: Prospective 2-year results of 87 patients. Minim Invasive Neurosurg. 2007;50(4):219–26.
7. Zhang C, Wu J, Xu C, et al. Minimally invasive full-endoscopic posterior cervical foraminotomy assisted by o-arm-based navigation. Pain Physician. 2018;21(3):E215–23.
8. Oertel JMK, Philipps M, Burkhardt BW. Endoscopic Posterior Cervical Foraminotomy as a Treatment for Osseous Foraminal Stenosis. World Neurosurg. 2016;91:50–7.
9. Yang Z, Li F, Chen J,et al. The experts consensus on the classification, diagnosis and non-surgical treatment of cervical spondylisis(2018). Chinese Journal of Surgery. 2018;56(6):401–2.
10. Sun T, Shen J, Liu Z, et al. Expert consensus in enhanced recovery after spinal surgery in China: perioperative management. Chinese Journal of Bone Joint Surgery. 2017;10(04):271–9.
11. Frankel HL, Hancock DO, Hyslop G, et al. The value of postural reduction in the initial management of closed injuries of the spine with paraplegia and tetraplegia. I Paraplegia. 1969;7(3):179–92.
12. Park MS, Ju YS, Moon SH, et al. Reoperation rates after anterior cervical discectomy and fusion for cervical spondylotic radiculopathy and myelopathy A national population-based study. Spine (Phila Pa 1976). 2016;41(20):1593–9.
13. Hilibrand AS, Carlson GD, Palumbo MA, et al. Radiculopathy and myelopathy at segments adjacent to the site of a previous anterior cervical arthrodesis. J Bone Jt Surg - Ser A. 1999;81(4):519–28.
14. Ren J, Li R, Zhu K, et al. Biomechanical comparison of percutaneous posterior endoscopic cervical discectomy and anterior cervical decompression and fusion on the treatment of cervical spondylotic radiculopathy. J Orthop Surg Res. 2019;14(1):1–7.
15. Kim CH, Shin KH, Chung CK, et al. Changes in cervical sagittal alignment after single-level posterior percutaneous endoscopic cervical diskectomy. Glob Spine J. 2014;5(1):31–8.
16. Nguyen J, Chu B, Kuo CC, et al. Changes in foraminal area with anterior decompression versus keyhole foraminotomy in the cervical spine: A biomechanical investigation. J Neurosurg Spine. 2017;27(6):620–6.
17. Komp M, Oezdemir S, Hahn P, et al. Full-endoscopic posterior foraminotomy surgery for cervical disc herniations. Oper Orthop Traumatol. 2018;30(1):13–24.

18. Guo J, Hu P, Liu X, et al. Effect of PTED and ACDF for treatment of cervical spondylotic radiculopathy in single level. Chin J Bone Joint Injury. 2017;32(1):1–5.
19. Engel GL. The need for a new medical model: a challenge for biomedicine. Science. 1977;196. 129 – 36.
20. Li R, Wang G, Ren J, et al. Clinical results and analysis of osteophyte removal within lateral spinal canal through posterior percutaneous endoscopic cervical discectomy. Chinese Journal of Bone Joint. 2019;8(12):925–30.
21. Quillo-Olvera J, Lin G-X, Kim J-S. Percutaneous endoscopic cervical discectomy: a technical review. Ann Transl Med. 2018;6(6):100–0.

Figures

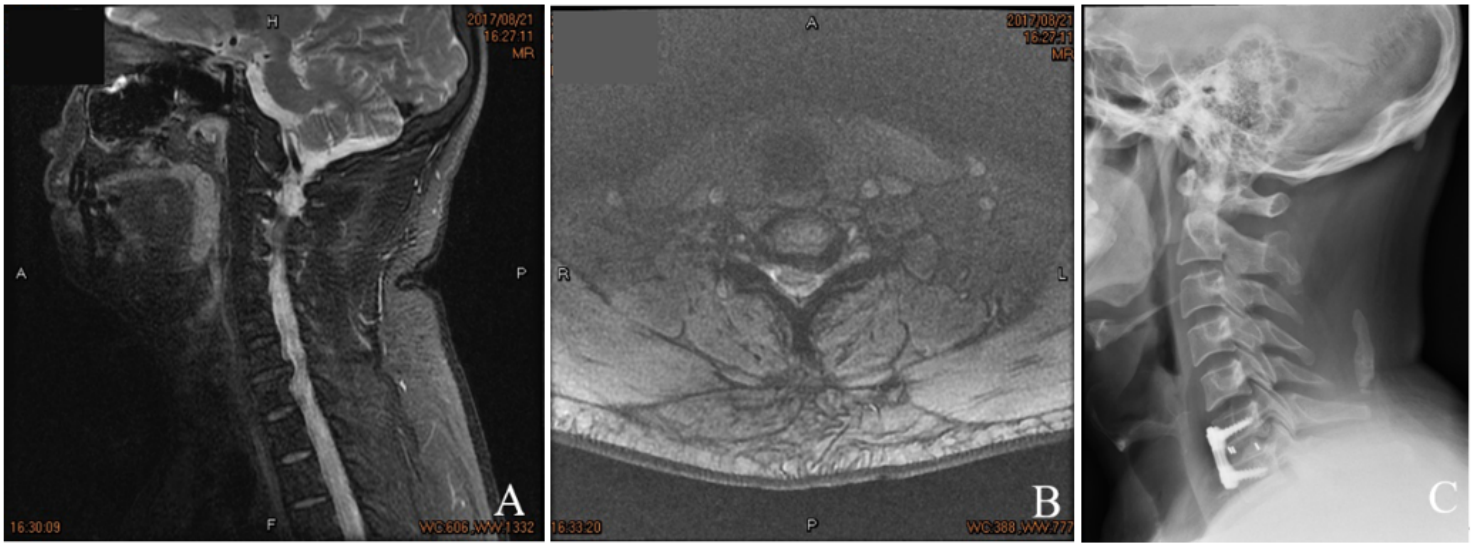

Figure 1

A and B show preoperative cervical MRI of ACDF patients; C shows postoperative X-ray.

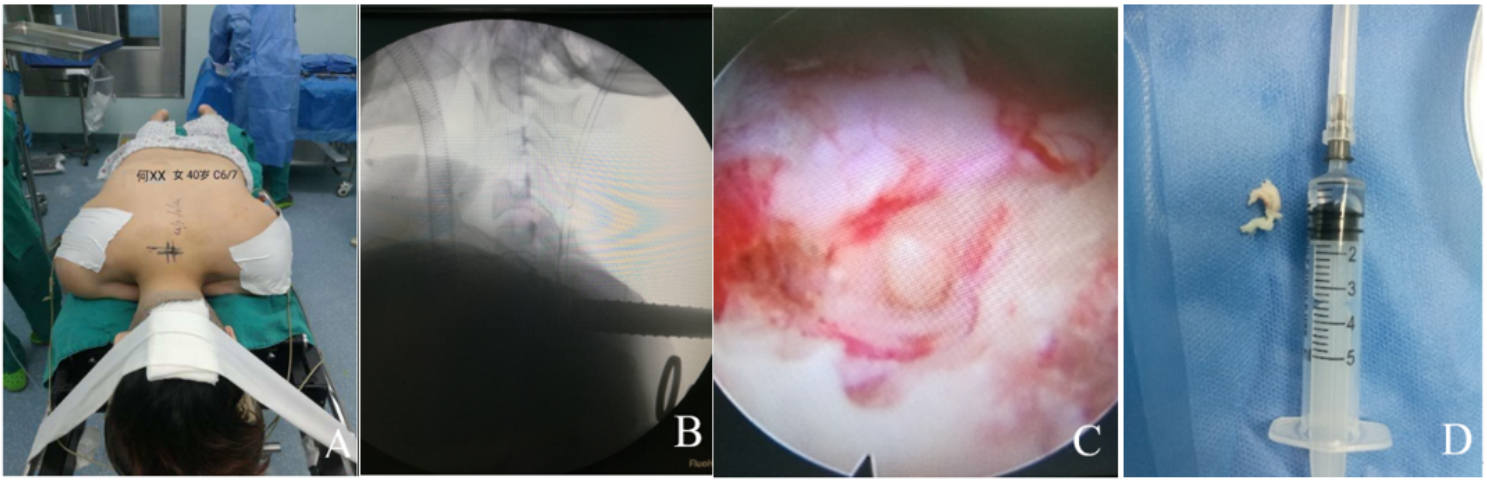

Figure 2

A forty years old woman presented by C6/7 right brachialgia since 4 months. She had Key-hole with excellent outcome. Intraoperative imaging (A shows body position; B shows operation channel; C shows protrusion of nucleus; D shows removal of nucleus pulposus).