Comparative Analysis of the Diagnostic Value of Several Methods for the Diagnosis of Patent Foramen Ovale

Fangfang liu
Shandong University Qilu Hospital
Qingyu Kong
Shandong University Qilu Hospital
Xiaojun Zhang
Rongjun General Hospital
Yan Li
Shandong University Qilu Hospital
Shimin Liang
The Fifth Hospital of Jinan
Shuang Han
The First Hospital of shandong First Medical University
guishuang Li (liguishuang2020@163.com)
Shandong University Qilu Hospital

Research

Keywords: patent foramen ovale, contrast transcranial Doppler, contrast- transthoracic echocardiography, contrast- transesophageal echocardiography

Posted Date: September 9th, 2020

DOI: https://doi.org/10.21203/rs.3.rs-63042/v1

Abstract

Background: In recent years, patent foramen ovale (PFO) has been reported to be strongly associated with embolic strokes of undetermined source (ESUS), including cryptogenic stroke, transient ischemic attack (TIA), migraine, and so on.The aim of this research was to compare the sensitivity and positive predictive value of contrast transcranial Doppler (c-TCD), contrast- transthoracic echocardiography (c-TTE) versus contrast- transesophageal echocardiography (c-TEE), to find which is the best method to diagnose patent foramen ovale (PFO), provides reference for the further improvement of clinical.

Methods: We investigated 161 patients who suffered from migraine, cryptogenic stroke, TIA, and cerebral infarction of unknown cause, all patients underwent the transcatheter examination, and put the results of the right heart catheterization (RHC) as the gold standard for PFO diagnosis. A chi-square test was used to compare the sensitivity and specificity between the three methods. A P value of <0.05 indicated statistical significance.

Results: The present study revealed that c-TTE with the Valsalva maneuver yielded a higher sensitivity in detecting PFO-RLS, but the rate of misdetection might be higher than c-TCD.

Conclusions: For the suspected patients, can examine with c-TCD first, if we get the positive results, then c-TTE and c-TEE should be taking to further confirmed. These findings may be helpful in the diagnosis of patent foramen ovale in practice.

Introduction

In recent years, the definition of embolic strokes of undetermined source (ESUS) emerged as a new clinical construct to characterize cryptogenic stroke (CS),most of the patients were young and had no medical history of hypertension, diabetes or hyperlipidemia, routine imageological examination also failed to detect significant vascular abnormalities (Hart et.al, 2017). Currently, patent foramen ovale (PFO) has been reported to be strongly associated with a number of diseases, including cryptogenic stroke (Mojadidi et.al, 2018), transient ischemic attack (TIA) (Khan et.al, 2016), migraine (Smith and Williams, 2017), peripheral arterial embolism, and decompression sickness (Rushdi et.al, 2011).

Foramen ovale is a persistent fetal communication between the right and left atrium due to incomplete closure of the atrial septum. After birth, with the interruption of umbilical blood circulation and the establishment of respiration, the foramen ovale then closed functionally, the complete closure is generally 5 to 7 months after birth. If the foramen ovale is still unclosed in children over 3 years old, PFO can be diagnosed. If the right atrial pressure is higher than left atrium (for example, cough, inspiration, Valsalva manoeuvre), blockages from venous system then can flow to the left atrium. Patent foramen ovale is the cause of 95% of paradoxical embolism (Rushdi et.al, 2011).

There are three methods for the diagnosis of PFO, contrast-transcranial doppler(c-TCD), transthoracic echocardiography (TTE), transesophageal echocardiography (TEE), TEE has a major role in the assessment of PFO. The diagnostic sensitivity of PFO-RLS by contrast transcranial Doppler (c-TCD) is similar to that of TEE. However, c-TCD has a limited ability to differentiate cardiac from pulmonary Right-to-Left Shunt (RLS). The use of contrast echocardiography was first reported by Gramiak (1968). Currently, contrast transthoracic echocardiography (c-TTE) with the Valsalva maneuver is extensively used for the detection and semiquantitative assessment of PFO-RLS (Kerut et.al, 2001). But the diagnostic criteria is not unified, thus, the aim of this research was to compare the sensitivity and specificity of each examination method, to find which is the best method to diagnose PFO, provides reference for the further improvement of clinical.

Materials And Methods

Patient Population

We investigated 161 patients (86 male, 75 female; mean age, 42.0 ± 15.6 years) admitted to the Departments of Neurology and Cardiology in Qilu Hospital, Shandong University from August 2018 to July 2019 who suffered from migraine, cryptogenic stroke, TIA, and cerebral infarction of unknown cause, including migraine 55 cases, cryptogenic stroke 56 cases, both of the symptoms 20 cases, dizzy or syncope 19 cases, TIA 9 cases, epilepsy 2 cases. Exclusion criteria: (1)Cerebral embolism that can find any cause, for example, cardiac cerebral embolism, arteriosclerosis; (2) Patients who could not afford antiplatelet or anticoagulant therapy, for example, severe bleeding within 3 months, severe retinopathy, history of intracranial hemorrhage and other intracranial disease; (3) Obstruction caused by inferior vena cava or pelvic venous thrombosis, systemic or local infection, septicemia, intracardiac thrombosis etc.; (4) Pregnancy; (5) Combine with pulmonary arterial hypertension or PFO cannot be closed; (6) Acute stroke within 2 weeks.

The study was approved by the local ethics committee, and all patients or their relatives provided written informed consent to participate in this study prior to the examination. All patients signed informed consent.

Saline contrast preparation:

Right anterior elbow vein was selected for an indwelling needle. The contrast agent was prepared by mixing with 3 ml of air, 30 ml of saline solution, and 3–5 ml of patient blood, intensively mixed back and forth 20 times between two 30-ml syringes connected by a T-branch pipe.

c-TCD Examination

TCD was performed using the Multi-DopX4 Transcranial doppler (DWL Electronic Systems, Sipplingen, Germany) with a 2 MHz probe, Middle cerebral artery flow was monitored through the temporal bone window at a depth of 50–65 mm. The study was performed by a neurologist specialized in this technique and blinded to the results of the echocardiographic study. After the middle cerebral artery blood flow

velocity value was obtained, the contrast agent was quickly injected via the established route of the anterior elbow vein. The contrast agent was prepared, right-to-left shunt was diagnosed when TCD detected microsignals in the middle cerebral artery, both in the resting state and performing the Valsalva maneuver. The severity of the shunt was quantified as negative (no microsignals), mlid (1–20 microsignals, 1–10 for one side), moderate (≥ 20 microsignals, ≥ 10 for one side), or extensive (≥ 30 microsignals or rain curtain-like signals) (Fig. 1).

c-TTE and c-TEE Examination

Contrast-TTE was conducted using the GE Vivid E9 or E95 platform equipped with a 3.7–5 MHz M5S transducer (Horten, Norway) or Philips EPIQ7 platform equipped with a 1–5 MHz S5-1 transducer (Philips USA). All patients were asked to keep still in the left lateral position. Conventional 2D echocardiography was carried out to acquire the standard apical, parasternal, and subxyphoid four-chamber views. Color flow Doppler was used to observe whether there was RLS at the foramen ovale of the interatrial septum. First, in rest state, the contrast agent was mixed and injected as the same way as c-TCD. Keep the apical four chamber view, after microbubbles filled the right atrium, keep a persistent observation if microbubbles appeared in the left atrium. Then repeat the operation as described above in Valsalva maneuver. When right atrium was filled with microbubbles, let patients do Valsalva maneuver immediately. RLS was graded according to the highest number of microbubbles observed in the left chamber in a single frame: image-negative (no microbubbles), mild (1–10 microbubbles), moderate (11–30 microbubbles), or extensive (≥ 30 microbubbles or left chamber opacification) (Fig. 2). If microbubbles appeared in the left atrium within five cardiac cycles after release, RLS was mostly considered to be derived from a PFO. If microbubbles appeared in the left atrium after more than five cardiac cycles, RLS was assumed to originate from a pulmonary arteriovenous malformation.

Contrast-TEE was performed using the same system fitted with a 2–7 MHz multi-frequency transesophageal probe. To improve the tolerance to the test, pharyngeal topical anesthesia was carried out using tetracaine hydrochloride gel 15 min before the examination. The probe was pushed in 30-40cm, rotated within 45°–140° to clearly display ascending aorta root, the septum primum and septum secundum and to obverse whether an opened PFO existed in two-dimensional, measured the PFO width and length at the same time, color Doppler was used to obverse whether there was a shunt across the PFO. Then, in rest and in Valsalva maneuver state, the prepared saline contrast agent was injected as the same way above. To ensure maximal diagnostic yield, a standard apical four-chamber view was performed with the administration of contrast agents. The severity of the microbubbles was quantified as the same way as c-TTE (Fig. 3).

Right heart catheterization and transcatheter closure

All patients who indicated RLS underwent the transcatheter examination, and put the results of the right heart catheterization (RHC) as the gold standard for PFO diagnosis. After localized anesthesia with lidocaine, the femoral vein was punctured with an intravenous cannula, and then a 6-F sheath was

inserted over the guidewire, reach the foramen ovale at the right atrial, if the catheter can get though the foramen ovale to reach the left atrium, then PFO can be diagnosed. If the sheath failed, then the guidewire was exchanged for a 0.035-in hydrophilic wire, if the hydrophilic wire can get though the foramen ovale to reach the left atrium, then PFO can also be diagnosed. At last, if the hydrophilic wire failed, we injected intravascular contrast media though the catheter, if the contrast media cannot reach the left atrium, PFO cannot be diagnosed. If the PFO cannot be diagnosed, then pulmonary arteriovenous fistula (PAVF) was excluded by pulmonary angiography (Fig. 4).

Statistical Analysis

A chi-square test was used to compare the sensitivity and specificity between the three methods. A *P* value of < 0.05 indicated statistical significance. All data were analyzed using SPSS software (version 18.0.1, SPSS Inc.).

Results

Diagnosis of PFO

As put the results of the right heart catheterization (RHC) as the gold standard for PFO diagnosis, 141 of the 161 patients studied were diagnosed with PFO, 18 patients cannot be diagnosed with PFO, 2 patients were diagnosed as pulmonary arteriovenous malformation, the morbidity of PFO was 88.17% (Table 1).

Table 1
Baseline characterization of patients

Items	Cases
Total cases	161
Male	86
Famale	75
Age(years)	42.0 ± 15.6
migraine	55
cryptogenic stroke (CS)	56
migraine + CS	20
TIA	9
dizzy or syncope	19
epilepsy	2
Diagnosed of PFO	141

Diagnostic value of c-TCD

Two patients did not accept the c-TCD examination, the right-to-left shunt was visualized at baseline by c-TCD in 97 patients (70.28%, 97/138), the degree of mild included 44 patients (31.88%, 44/138), moderate included 22 patients (15.94%, 22/138), extensive included 31 patients (22.46%, 31/138), the Valsalva maneuver was effective in all c-TCD studies, then RLS was identified 128 patients (92.75%, 128/138), the degree of mild included 36 patients (26.09%, 36/138), moderate included 28 patients (20.29%, 28/138), extensive included 64 patients (46.38%, 64/138), the difference between baseline and Valsalva maneuver was statistically significant (Table 2).

Table 2
, *Results of c-TCD, c-TTE and c-TEE in 141 cases*

		Baseline	Valsalva maneuver
c-TCD*	negative	41	10
n = 138	mild	44	36
	moderate	22	28
	extensive	31	64
c-TTE#	negative	54	9
n = 135	mild	41	24
	moderate	15	35
	extensive	25	67
TTE 2D (+), n = 141		12	
TTE color (+), n = 141		17	
c-TEE&	negative	61	17
n = 130	mild	37	32
	moderate	12	15
	extensive	20	66
TEE 2D (+), n = 132		119	
TEE color (+), n = 132		40	

*: Two patients did not accept the c-TCD examination; #: Six patients did not accept the c-TTE examination; &:Seven patients did not accept the TEE examination.

Diagnostic value of c-TTE and c-TEE

The loss of echo was identified in 12 patients (8.51%, 12/141) by TTE, included 3 atrium septal aneurysms, the color shunt was identified in 17 patients (12.06%, 17/141), six patients did not accept the c-TTE examination, TEE bubble was identified in 81 patients (60.00%, 81/135) at baseline, the degree of mild included 41 patients (30.37%, 41/135), moderate included 15 patients (11.11%, 15/135), extensive included 25 patients (18.52%, 25/135), the Valsalva maneuver was effective in all c-TTE studies, then RLS was identified 126 patients (93.33%, 126/135), the degree of mild included 24 patients (17.78%, 24/135), moderate included 35 patients (25.93%, 37/135), extensive included 67 patients (49.63%, 67/135); There were eight patients did not tolerate TEE examination, include seven PFOs and one without PFO. Two-dimensional TEE displayed a “slit-like” channel ≥ 2 mm between the septum primum and the septum secundum in 119 patients (90.15%, 119/132). The color shunt was identified in 40 patients (30.30%, 40/132), and then, two patients did not accept c-TEE examination, TEE bubble was identified in 69 patients (53.08%, 69/130) at baseline, the degree of mild included 37 patients (28.46%, 37/130), moderate included 12 patients (9.23%, 12/130), extensive included 20 patients (15.38%, 20/130), the Valsalva maneuver was effective in all c-TEE studies, then RLS was identified 113 patients (86.92%, 113/130), the degree of mild included 32 patients (24.62%, 32/130), moderate included 15 patients (11.54%, 15/130), extensive included 66 patients (50.77%, 66/130) (Table 2).

Diagnosis of patients without PFO

In the total 161 patients, 18 patients cannot be diagnosed with PFO, among of them, results of c-TCD in 4(22.22%, 4/18) patients were positive both at baseline and Valsalva maneuver, 7(38.89%, 7/18) patients were positive only after Valsalva maneuver effected. Besides, results of c-TTE in 6(33.33%, 6/18) patients were positive both at baseline and Valsalva maneuver, 7(38.89%, 7/18) patients were positive only after Valsalva maneuver. The slit-like channel between the septum primum and the septum secundum by TEE was identified 5 (29.41%, 5/17) patients, TEE bubble was identified in 4(23.53%, 4/17) patients both at baseline and Valsalva maneuver, 6 (35.29%, 6/17) patients only after Valsalva maneuver (Table 3).

Table 3
Diagnosis of patients without PFO (18 cases)

		Baseline	Valsalva maneuver
c-TCD	negative	14	7
	mild	3	8
	moderate	0	1
	extensive	1	2
c-TTE	negative	12	5
	mild	5	6
	moderate	1	5
	extensive	0	2
TTE 2D (+)		0	0
TTE color (+)		0	0
c-TEE*	negative	13	7
	mild	3	4
	moderate	0	3
	extensive	1	3
TEE 2D (+)		5	5
TEE color (+)		0	0

*: One of the 18 patients did not tolerate TEE.

Diagnostic value between the different methods

In total, the sensitivity of c-TCD at baseline was 70.28% (97/138), 22.46% (31/138) for the degree of extensive, 38.40% (53/138) for moderate and extensive; the sensitivity of c-TCD after Valsalva maneuver was 92.75% (128/138), 46.38% (64/138) for the degree of extensive, 66.67% (92/138) for moderate and extensive; the sensitivity of the loss of echo by TTE was 8.51% (12/141), the color shunt was 12.06% (17/141); the sensitivity of the total c-TTE at baseline was 60.00% (81/135), 18.52% (25/135) for the degree of extensive, 29.63% (40/135) for moderate and extensive; the sensitivity of the total c-TTE after Valsalva maneuver was 93.33% (126/135), 49.63%(67/135) for the degree of extensive, 75.56% (102/135) for moderate and extensive; the sensitivity of the slit-like channel between the septum primum and the septum secundum by TEE was 90.15% (119/132), the color shunt was 30.30% (40/132); the sensitivity of the total c-TEE at baseline was 53.08% (69/130), 15.38% (20/130) for the degree of extensive, 24.62% (32/130) for moderate and extensive; the sensitivity of the c-TEE after Valsalva

maneuver was 86.92% (113/130), 50.77% (66/130) for the degree of extensive, 62.31% (81/130)for moderate and extensive.

For the comparison among groups, there were no significant difference between the sensitivity of total c-TCD, c-TTE and c-TEE at baseline, when compared by pairs other, c-TCD was significantly higher than c-TEE ($P = 0.004$); After Valsalva maneuver, the sensitivity of total c-TTE was significantly higher than c-TEE ($P = 0.041$). For the comparison within groups, if the bubbles were extensive in the examination of c-TTE at baseline, the sensitivity was significantly higher than c-TCD ($P = 0.011$) and c-TEE ($P = 0.009$).

The positive predictive value of total c-TCD at baseline was 96.04% (97/101), 96.88% (31/32) for the degree of extensive, 98.15% (53/54) for moderate and extensive. After Valsalva maneuver, the positive predictive value of total c-TCD wes 92.09% (128/139), 96.97% (64/66) for the degree of extensive, 96.84% (92/95) for moderate and extensive. The false negative rate of total c-TCD at baseline was 29.71% (41/138), 7.25% (10/138) after Valsalva maneuver. The positive predictive value of c-TTE at baseline was 93.10% (81/87), 100.00% (25/25) for the degree of extensive, 97.56% (40/41) for moderate and extensive; after Valsalva maneuver, the positive predictive value was 90.65% (126/139), 97. 10% (67/69) for the degree of extensive, 93.58% (102/109) for moderate and extensive. The false negative rate of total c-TTE at baseline was 40.00% (54/135), 6.67% (9/135) after Valsalva maneuver. The positive predictive value of c-TEE at baseline was 94.52% (69/73), 95.24% (20/21) for the degree of extensive, 96.97% (32/33) for moderate and extensive; after Valsalva maneuver, the positive predictive value was 91.87% (113/123), 95.65% (66/69) for the degree of extensive, 93.10% (81/87) for moderate and extensive. The false negative rate of total c-TEE at baseline was 46.92% (61/130), 13.08% (17/130) after Valsalva maneuver (Table 4).

Table 4
, Diagnostic value of c-TCD, c-TTE and c-TEE

		Baseline			Valsalva maneuver		
		Sensi(%)	PPV(%)	FNR (%)	Sensi (%)	PPV (%)	FNR (%)
c-TCD	Total	70.29**	96.04	29.71	92.75	92.09	7.25
	extensive	22.46	96.88	56.94	46.38	96.97	13.51
	moderate + extensive	38.40	98.15	43.62	66.67	96.84	9.80
c-TTE	Total	60.00	93.10	40.00	93.33*	90.65	6.67
	extensive	18.52	100#	68.35	49.63	97.10	11.84
	moderate + extensive	29.63	97.56	57.44	75.56	93.58	8.10
TTE 2D		8.51	100				
TTE color		12.06	100				
c-TEE	Total	53.08	94.52	46.92	86.92	91.87	13.08
	extensive	15.38	95.24	75.30	50.77	95.65	20.48
	moderate + extensive	24.62	96.97	65.59	62.31	93.10	17.35
TEE 2D		90.15	94.17	9.85			
TEE color		30.30	100				

PPV: positive predictive value; Sensi: Sensitive; FNR: false negative rate. **: P 0.005(0.004) vs c-TEE; *: P 0.05(0.041) vs c-TEE; #: P 0.05(0.011) vs extensive of c-TCD, (0.009) vs extensive of c-TEE.

Discussion

Foramen ovale is a persistent fetal communication between the right and left atrium due to incomplete closure of the atrial septum, after birth, the foramen ovale closed. But the morbidity of PFO was about 30% (Homma et.al, 2001). PFO has no obvious symptoms in usual times, and hard to heard the heart murmur, there were no abnormal in the electrocardiogram and chest X-ray, so it was easy to be neglected. Recently, patients who suffered from migraine headaches, cryptogenic stroke, TIA, and cerebral infarction, if did not have acute cerebral infarction or anterior circulation transient ischemic attack on admission, the possibility of being caused by the right-to-left shunt then be considered.

Our study assessed a large series of patients to find out the presence of right-to-left shunt, the results demonstrated that the sensitivity of c-TTE is superior to c-TEE in the diagnosis of PFO both at baseline and Valsalva maneuver, c-TCD performed simultaneously with c-TEE but maybe gave a false positive.

TEE was lack of sensitivity contrast with c-TCD, the probability false-negative was higher than c-TCD, so the c-TCD can be used as an effective supplement to diagnose PFO; the sensitivity of TEE was highest in the three methods, still can be the gold standard. But the results of c-TCD can only point out that right-to-left shunt, cannot exclude extracardiac shunt, so combined application should be used.

PFO was a three-dimensional structure, which will change the shape with the cardiac cycle. Therefore, it is difficult to fully display the PFO simply by using TEE's two-dimensional technology, as our results, three was some false positive cases when we used 2D image of TEE (5 cases). The three-dimensional (3D) technology can solve the one-sidedness problem, but 3D image quality due to the 2D image, sometimes, 3D image was just for the reference (Shanks et.al, 2012). In terms of sensitivity,total c-TTE after Valsalva maneuver was the highest, especially for extensive, so we consider that sensitivity was increased with the quantity of bubbles in left heart. Moreover, if we observed the color shunt from the slit-like channel between the septum primum and the septum secundum by TEE, the positive predictive value was 100.00%, so in our daily clinical work, the observation of TEE color shunt is very important. But the sensitivity of c-TEE was lower than c-TTE after Valsalva maneuver, based on our observations, patients sometimes cannot make the Valsalva maneuver perfectly during TEE examination, that might be the most probable reason. c-TCD has the greatest value in diagnosing PFO, almost all the PFO patients had positive results in c-TCD examination, but c-TCD can only point out that right-to-left shunt, cannot exclude extracardiac shunt (Wessler et.al, 2015), c-TTE and c-TEE can observe the structure of oval foramen, were more convincing. The positive predictive value can reflect the possibility of prevalence rate in patients with positive results. In all the three methods (c-TCD, c-TTE, c-TEE), if three were a large number of bubbles in the left heart, especially with the color shunt from the slit-like channel, the positive predictive value was the highest. Although c-TCD has the highest positive predictive value, some unsolved problems still existed, for example, some bubbles can get though the pulmonary circulation, be detected in the cerebral arteries, so we will get a false positive result. On the other hand, c-TTE and c-TEE had more false negatives, the rate of misdetection might be higher than c-TCD. So, for the suspected patients, can examine with c-TCD first, if we get the positive results, then c-TTE and c-TEE should be taking to further confirmed.

The results sometimes were different between resting state and Valsalva maneuver, the positive rate is higher with Valsalva maneuver. At the resting state, not all the patients could be observed the RLS. In some PFO patients, the foramen ovale is closed in resting state, only under some particular situation, for example, cough, cry, constipation, Valsalva maneuver and so on, that’s also the causes of nervous system symptoms on PFO patients (Zhao et.al, 2015). Only under those situations, the right atrial pressure can higher than the left atrial transiently, the foramen ovale then opened, so we could observe the RLS. So, for the situation when the left heart didn’t exist bubbles, Valsalva maneuver was necessary, results were positive no no matter Valsalva or not when bubbles existed in left heart.

Pulmonary arteriovenous fistula (PAVF) is abnormal pulmonary vascular structures that connect a pulmonary artery to a pulmonary vein, bypassing the normal capillary bed resulting in an intrapulmonary right-to-left shunt (Abdel Aal et.al, 2018). In our study, 2 patients were diagnosed as PVAF. At first, we

didn’t give much attention to this disease, the results of c-TCD, c-TTE and c-TEE showed a strongly positive reaction, so we did the transcatheter examination, but the result was unexpected, PFO cannot be diagnosed. Then pulmonary angiography was performed, the results showed that the contrast medium can get to pulmonary vein from pulmonary artery, so we did a diagnose mistake before. We looked back the examinations, find that the slit-like channel by TEE was not very sure, and the bubbles seemed to be from la roof, the entrance of pulmonary vein, these findings could help us to diagnose PVAF. So, in conclusion, we have to consider the following points to diagnose PVAF: first, the results of c-TCD, c-TTE and c-TEE show a positive sometimes a strongly reaction; second, TEE image cannot make sure the slit-like channel existed, or the width of foramen ovale cannot match the quantity of bubbles; third, he bubbles seemed to be from la roof, the entrance of pulmonary vein, not from the foramen ovale.

Conclusion

In conclusion, the present study revealed that c-TTE with the Valsalva maneuver yielded a higher sensitivity in detecting PFO-RLS, but the rate of misdetection might be higher than c-TCD. Therefore, for the suspected patients, can examine with c-TCD first, if we get the positive results, then c-TTE and c-TEE should be taking to further confirmed. These findings may be helpful in the diagnosis of patent foramen ovale in practice.

Abbreviations

PFO patent foramen ovale

c-TCD contrast transcranial Doppler

c-TTE contrast- transthoracic echocardiography

c-TEE contrast- transesophageal echocardiography

TIA transient ischemic attacks

ESUS embolic strokes of undetermined source

CS cryptogenic stroke

RLS Right-to-Left Shunt

RHC right heart catheterization

PAVF pulmonary arteriovenous fistula

Declarations

Ethics approval and consent to participate

The study was approved by the local ethics committee, and all patients or their relatives provided written informed consent to participate in this study prior to the examination. All patients signed informed consent.

Consent for publication

Not applicable.

Availability of data and materials

../PFO□□/PFO□□□□.xlsx">..\PFO□□\PFO□□□□.xlsx

Competing interests

The authors declare that they have no competing interests.

Funding

Research reported in this research was supported by the technology capture project of Shandong province under award number 2017GGX90104.

Authors' contributions

QK and JZ analyzed the data of right cardiac catheterization, YL analyzed the data of c-TCD, FL SL and HS analyzed the data of c-TEE and c-TTE, FL performed the data statistics and was a major contributor in writing the manuscript. All authors read and approved the final manuscript.

Acknowledgements

Not applicable.

References

1. Abdel Aal AK, Eason J, Moawad S, Mahmoud K, Hamed BF, Massoud MO, Ertel N, Gunn A, Oser R, Saddekni S. Persistent Pulmonary Arteriovenous Malformations: Percutaneous Embolotherapy. Curr Probl Diagn Radiol. 2018 Nov;47(6):428–36.
2. Hart RG, Catanese L, Perera KS, Ntaios G, Connolly SJ. Embolic Stroke of Undetermined Source: A Systematic Review and Clinical Update. Stroke. 2017 Apr;48(4):867–72.
3. Homma S, Messé SR, Rundek T, Sun YP, Franke J, Davidson K, Sievert H, Sacco RL, Di Tullio MR. Patent Foramen Ovale. Nat Rev Dis Primers. 2016 Jan;21:2:15086.
4. Gramiak R, Shah PM, Kramer DH. Ultrasound cardiography: contrast studies in anatomy and function. Radiology. 1969 Apr;92(5):939–48.

5. Kerut EK, Norfleet WT, Plotnick GD, Giles TD. Patent Foramen Ovale: A Review of Associated Conditions and the Impact of Physiological Size. J Am Coll Cardiol. 2001 Sep;38(3):613–23.
6. Khan R, Chan AK, Mondal TK, Paes BA. Thrombosis and Hemostasis in Newborns (THIN) Group. Patent Foramen Ovale and Stroke in Childhood: A Systematic Review of the Literature. Eur J Paediatr Neurol. 2016 Jul;20(4):500–11.
7. Mojadidi MK, Zaman MO, Elgendy IY, Mahmoud AN, Patel NK, Agarwal N, Tobis JM, Meier B. Cryptogenic Stroke and Patent Foramen Ovale. J Am Coll Cardiol. 2018 Mar;6(9):1035–43. 71(.
8. Ali Kausar Rushdi Y, Hina H, Patel B, Cross FW. The Incidence of Peripheral Arterial Embolism in Association With a Patent Foramen Ovale (Right-To-Left Shunt). JRSM Short Rep. 2011 May;2(5):35.
9. Hildick-Smith D, Williams TM. Patent Foramen Ovale and Migraine Headache. Interv Cardiol Clin 2017 Oct;6(4):539–545.
10. Shanks M, Manawadu D, Muhll IV, Khan K, Becher H, Choy J. Detection of Patent Foramen Ovale by 3D Echocardiography. JACC Cardiovasc Imaging. 2012 Mar;5(3):329–31.
11. Wessler BS, Kent DM, Thaler DE, Ruthazer R, Lutz RS, Serena J. The RoPE Score and Right-to-Left Shunt Severity by Transcranial Doppler in the CODICIA Study. Cerebrovasc Dis. 2015;40(1–2):52–8.
12. Zhao E, Wei Y, Zhang Y, Zhai N, Zhao P, Liu B. A Comparison of Transthroracic Echocardiograpy and Transcranial Doppler With Contrast Agent for Detection of Patent Foramen Ovale With or Without the Valsalva Maneuver. Medicine (Baltimore).2015 Oct;94(43):e1937.

Figures

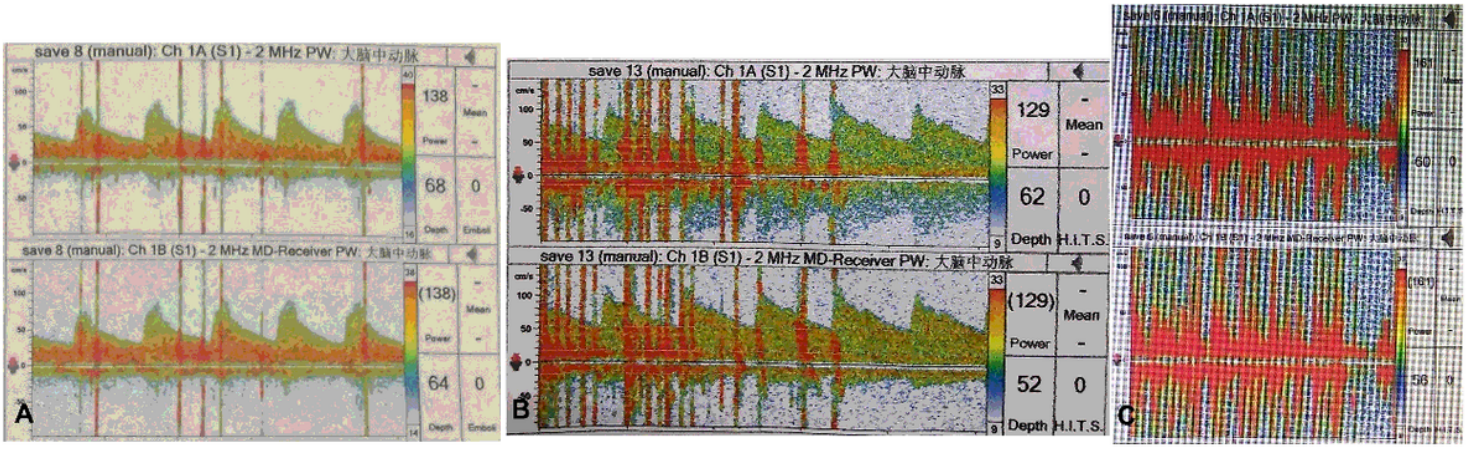

Figure 1

Quantification of the shunt by c-TCD. (A) Grade I, mild signals. (B) Grade II, moderate signals. (C) Grade III, extensive signals.

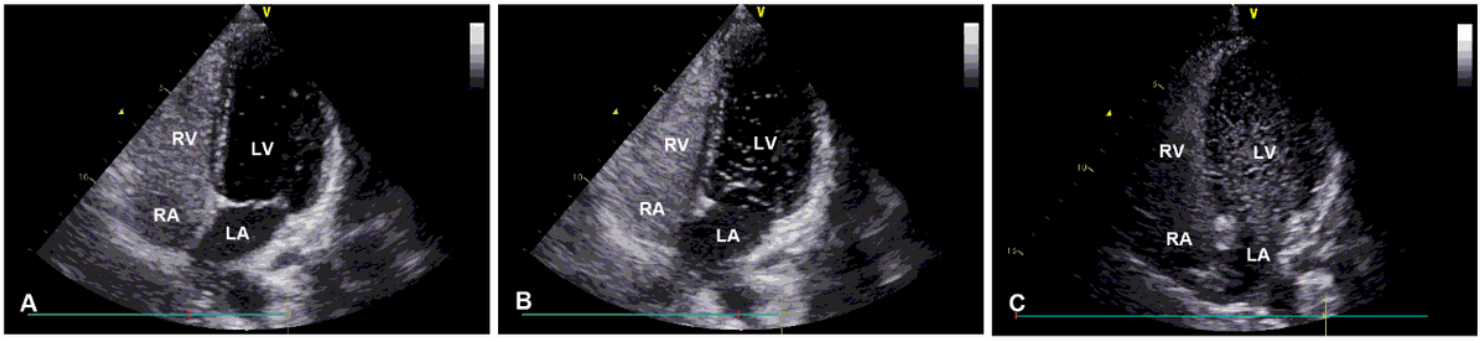

Figure 2

Quantification of the shunt by c-TTE. (A) Grade I, mild signals. (B) Grade II, moderate signals. (C) Grade III, extensive signals. LA: left atrium; LV: left ventricle; RA: right atrium; RV: right ventricle.

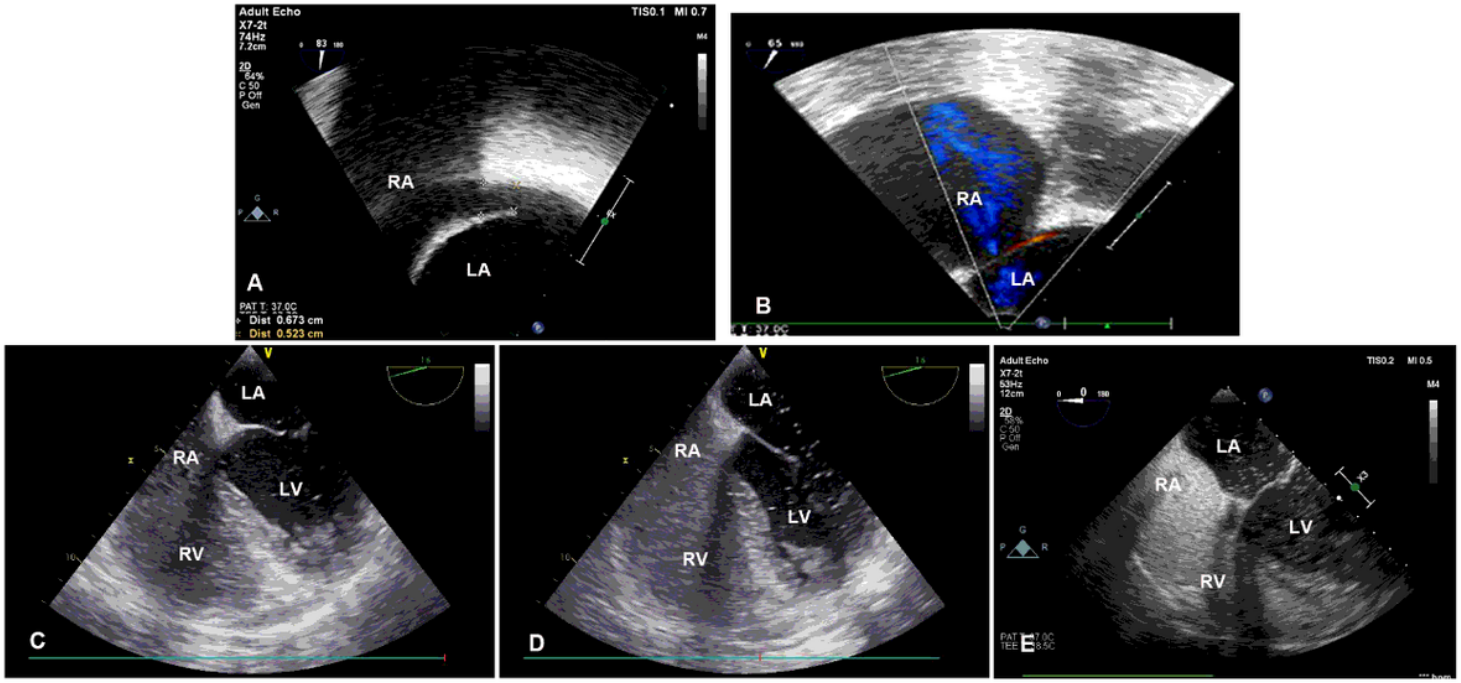

Figure 3

Two-dimensional and color Doppler TEE, Quantification of the shunt by c-TTE. (A) Two-dimensional TEE displayed the “slit-like” channel between the septum primum and the septum secundum. (B) Color Doppler displayed the right-to-left color shunt. (C) Grade I, mild signals. (D) Grade II, moderate signals. (E) Grade III, extensive signals. LA: left atrium; LV: left ventricle; RA: right atrium; RV: right ventricle.

Figure 4

Right heart catheterization with angiography. (A) After injected intravascular contrast media though the catheter, if the contrast media cannot reach the left atrium, PFO cannot be diagnosed. (B & C) If the PFO cannot be diagnosed, then pulmonary arteriovenous fistula (PAVF) was excluded by pulmonary angiography. (D) Pulmonary arteriography showed the PAVF.