Yogic agnisara increases blood flow in the superior mesenteric artery

Rinad Minvaleev (r.minvaleev@spbu.ru)
St Petersburg University

Rinat Bogdanov
Moscow Regional Scientific Research Clinical Institute. MF Vladimirsky

David Bahner
The Ohio State University Wexner Medical Center

Alexander Levitov
Eastern Virginia Medical School

Andrej Kuznetsov
First Pavlov State Medical University of St. Petersburg

Research Article

Keywords: ultrasound Doppler flowmetry, superior mesenteric artery, exercise, agnisara, uddiyana bandha

Posted Date: June 27th, 2021

DOI: https://doi.org/10.21203/rs.3.rs-636921/v1

Version of Record: A version of this preprint was published at Journal of Bodywork and Movement Therapies on April 1st, 2022. See the published version at https://doi.org/10.1016/j.jbmt.2022.04.004.

Abstract

Objectives

Medieval yoga texts claim that a special exercise of the muscles of the anterior abdominal wall, called *agnisara*, improves digestive function. Main objective of the study was to demonstrate change in the blood flow through superior mesenteric artery (if any) after performance of agnisara.

Design and subjects:

Ultrasound examination of the linear and volumetric indicators of blood flow in the superior mesenteric artery (SMA) before and after performing the *agnisara* yoga exercise 100 times was carried out in 12 healthy volunteers of both sexes (8 of them women).

Results

A significant increase in the diameter of the SMA, peak systolic and diastolic velocities, and blood flow in the superior mesenteric artery after performing the *agnisara* exercise 100 times was found, which contrasts with the established data on a decrease in splanchnic blood flow in humans in response to normal physical activity.

Conclusion

Properly performed agnisara increases blood flow to the splanchnic region, registered by the SMA, which should contribute to adequate blood supply to the gastrointestinal tract for successful performance of digestive function.

Introduction

In the course of our ultrasound studies of yogic postural influences on intracardiac [1] and intraorganic blood flow [2, 3], we decided to evaluate the blood flow to the gastrointestinal tract during the *agnisara*, or *vahnisara*, yoga exercise, since in medieval texts on yoga a direct influence on gastrointestinal function is attributed to this exercise [4]. Consequently, modern guidelines for yoga practice repeat the above instruction and yoga practitioners believe they are increasing their digestive activity.

The activation of the digestive tract function must be accompanied and is, indeed, accompanied by a natural increase in its blood supply, which is well established in case of postprandial blood flow to the celiac region by various independent methods [5, 6], including Doppler flowmetry [7]. The superior mesenteric artery (SMA), which supplies the whole of small intestine, is often studied, because the anatomy of this vessel lends itself to examination by a noninvasive Doppler ultrasound method [8]. The

adapting of noninvasive Doppler techniques has made it possible to develop reproducible measurements of celiac and superior mesenteric arteries blood flow, which are the main contributors to the gastrointestinal vasculature [9].

In a recent study of cerebral blood flow during inverted yoga pose (*shirshasana*), we found a decrease in the blood flow to the brain through the internal carotid artery, contrary to the prevailing opinion among yoga practitioners [10], which makes the problem statement relevant for testing other yoga practices. Since it remains unclear how *agnisara* increases digestive function while physical exercise in general reduces celiac blood flow by distributing cardiac output in favor of working skeletal muscles [11], we decided to evaluate celiac blood flow using ultrasound examination of the SMA before and after doing the *agnisara* exercise multiple (100) times.

Compliance with Ethical Standards

This study was approved by the Institutional Review Board of Saint Petersburg State University (IRB00003875, irb@spbu.ru). Written informed consent was translated into all relevant languages and cross translated to assure accuracy. Consent was signed by all participants after all questions had been answered by the scientific team.

Subjects And Methods

A total of 12 healthy volunteers of both sexes (including 8 women) at the age from 34 to 57 years old were examined (see Table 1 for details).

Table 1.

All subjects had varying levels of yoga experience and were trained to do the *agnisara* exercise.

A short description of this exercise is presented, for example, in the medieval instruction on yoga practice called "Gheranda-samhita" [4]: "Move the navel plexus to the spinal column one hundred times. This gets rid of intestinal diseases and increases the digestive fire. This Vahnisara (Agnisara) brings about success in Yoga for yogis…" (Chapter 1. 18-20). Outwardly, it looks like alternate, forceful retractions and protrusions of the abdominal wall, performed along a 20-30 s period of apnea after a full exhalation (Fig. 1). Interestingly, an outwardly similar exercise called "vacuum" has become widespread in Western training systems such as fitness and bodybuilding, with a direct indication that this exercise is adopted from yoga.

We performed ultrasound examination of the blood flow of the superior mesenteric artery using an expert class ultrasound machine Fujifilm Sonosite Edge (Bothell, Washington). For sagittal visualization of the abdominal aorta and the superior mesenteric artery extending from it, a C60x convex probe with a scanning frequency of 2-5 MHz was used (Fig. 2).

Protocol

Power and Pulsed Wave Doppler flowmetry of the superior mesenteric artery blood flow was consistently carried out in all subjects in the morning on an empty stomach in the supine position with knees bent to relax the abdominal muscles. Power Doppler was used to confirm vascular flow and angle of SMA takeoff. Pulsed Wave Doppler was used to generate a spectral image of flow in SMA at takeoff. Waveform generated and assessed for quality (Quality was determined by lack of spectral broadening in arterial wave form). Scale was adjusted to fit wave form onto image display. Quality image and Doppler wave form with arterial pattern in obtained within 1cm of SMA takeoff. Calipers are used to measure peak systole and peak diastole. Calculation function is used to measure the SMA diameter at the area where Doppler wave form obtained at SMA take off. Volume flow was calculated by measuring peak to peak and converted to ml/min.

Immediately after this, each subject, in a sitting position with their legs crossed, performed the *agnisara* exercise, holding their breath after a full exhalation, as many times as possible (Fig. 1). In total, three to four exercise cycles were performed each time after a new exhalation, in order to obtain a total of 100 propulsive movements of the anterior abdominal wall. Immediately after completing the *agnisara* exercise 100 times, the ultrasound of the SMA blood flow was repeated.

The results of measuring the actual diameter (in cm), peak velocities at the times of systole and diastole (in cm/s), and the total estimate of the volumetric blood flow (in ml/min) in the superior mesenteric artery were read from the obtained sonograms (Fig. 3).

Statistical processing of the numerical results obtained was carried out using the paired samples t test.

Results

At the initial stage of the examination, unidirectional changes in SMA blood flow were found in response to performing the *agnisara* exercise 100 times in most subjects, which made it possible to draw a preliminary conclusion about an increase in linear and volumetric parameters of SMA blood flow after this exercise. However, in the test subject ES (female), in response to performing the *agnisara* exercise 100 times, a decrease in diameter and an almost twofold decrease in volumetric blood flow in the SMA was discovered. After conversations with her and with other participants, it turned out that their techniques of performing *agnisara* were different. Namely, subject ES performed *agnisara* in strict accordance with the instructions given in the Gheranda Samhita, pressing the front abdominal wall against the spine, while the rest of the participants, who had received yoga training from another trainer, performed *uddiyana bandha* (Sanskrit: 'flying up'), in which the front abdominal wall is pulled not to the spine, but up to the diaphragm raised while holding the breath after exhalation (see Fig. 1). On the next day, during the repeated ultrasound examination, subject ES performed *uddiyana bandha* before each abdominal retraction, and the direction of changes in SMA blood flow after performing *agnisara* 100 times was equal to that of the main group (see Table 2).

Table 2.

Since all other subjects (n = 11) performed the *agnisara* yoga exercise with the preliminary performance of *uddiyana bandha*, their measurement results, including the results of repeated measurements in subject ES, were summarized in Table 3 and subjected to statistical processing.

Table 3.

Following the guidelines, we give 95% confidence intervals (CI) for significant changes in the studied indicators:

1. mean difference in diameter was 0.04 cm (95% CI 0.073 – 0.01 cm) or 6.6% mean increase;
2. mean difference in systolic blood flow in the SMA was 18.31 cm/s (95% CI 35.5 - 1.1 cm/s) or 12.7% mean increase;
3. mean difference in diastolic blood flow in the SMA was 6.8 cm/s (95% CI 2.8 - 10.9 cm/s) or 34% mean increase;
4. mean difference in blood flow volume in the SMA was 142.7 ml/min (95% CI 63.2 – 222.2 ml/min) or 31% mean increase.

Discussion

Table 3 shows a significant (with a probability of type 1 error less than 0.05) increase in all indicators of linear and volumetric blood flow through the SMA after the 100-fold execution of a specific *agnisara* exercise, despite the statistical invariance of the resistance index (highlighted in gray in Table 3). Moreover, the amount of blood flowing through the SMA per minute increased with a probability close to 1.

The latter contrasts with the established data on a decrease in mesenteric blood flow in humans in response to various sympatho-adrenal activations, including physical activity. In other words, a performance of the special physical exercise *agnisara* 100 times should have reduced the blood flow through the superior mesenteric artery, like any other physical activity, which has been found in many studies [12, 13, 14, 15]. This is exactly what happened in subject ES when performing *agnisara* without *uddiyana bandha*. When we added the performance of *uddiyana bandha* before each propulsive movement of the anterior abdominal wall during *agnisara*, the volumetric flow of arterial blood along the SMA increased (see Table 2), which allows us to indicate a specific retraction of the anterior abdominal wall up to the diaphragm, called in yoga the *uddiyana bandha*, as a key element for the correct performance of *agnisara*.

In 2003, we described a shift in the autonomic tone towards the predominance of parasympathetic influences when performing *uddiyana bandha* [16]. The same cholinergic reflex mediates an increase in blood flow to the SMA after a meal [17]. Thus, the correct agnisara reproduces/imitates the vegetative support of the digestive process before meals, preparing the digestive tract to perform its function.

Interestingly, even at the initial stage of digestion, blood flow in the SMA also increased from as early as the first minute after a meal, that is, even before the chyme entered the intestine, or, in other words, preventively [18]. We observed a similar more than 30% increase in blood flow in the SMA when performing the correct *agnisara*, of course, outside the meal, which allows us to prove the capacity of a correctly performed *agnisara* to activate gastrointestinal function through an increase in the SMA. Another coincidence with our data (see table 3) was that the increase in the mesenteric blood flow after a meal was mainly due to an increase in velocity and volume, the increase in the vessel diameter was less important [17].

Thus, an increase in blood flow to the SMA after repeating this yoga exercise 100 times can be seen as a sign of performing the exercise correctly. Then, our ultrasound experimental data can be seen as a confirmation of the ancient description of *agnisara* as the practice of "kindling the digestive fire" [4].

Conclusion

Correctly performed *agnisara* (with the obligatory performance of *uddiyana bandha* before each propulsive movement of the anterior abdominal wall) increases blood flow to the splanchnic area, by the SMA, which should contribute to an increased blood supply to the gastrointestinal tract for the corresponding improvement of the digestive function.

References

1. Minvaleev, R.S., Kuznetsov, A.A., Nozdrachev, A.D. & Lavinskiĭ, Iu.Kh. Left Ventricle Filling in Sirshasana and Sarvangasana Yogic Postures. *Human Physiology* 25(6), 665-671. Translated from *Fiziologiya Cheloveka* 25(6), 27-34 (1996).
2. Minvaleev, R.S., Kuznetsov, A.A., Nozdrachev, A.D. The Influence of Body Position on the Blood Flow of Parenchymatous Organs: 1. Liver. *Human Physiology* 24(4), 475-480. Translated from *Fiziologiya Cheloveka* 24(4), 101-107 (1998).
3. Minvaleev, R.S., Kuznetsov, A.A., Nozdrachev, A.D. The Influence of Body Position on the Blood Flow of Parenchymatous Organs: II. Kidneys. *Human Physiology* 25(2), 203-209. Translated from *Fiziologiya Cheloveka* 25(2), 92-98 (1999).
4. Mallinson, J. (ed.) The Gheranda Samhita: the original Sanskrit and an English translation. (YogaVidya.com, 2004).
5. Norryd, C., Denker, H., Lunderquist, A., Olin, T. & Tylén, U. Superior mesenteric blood flow during digestion in man. *Acta Chir. Scand.* **141(3),** 197-202 (1975).
6. Moneta, G.L., Taylor, D.C., Helton, W.S., Mulholland, M.W. & Strandness, D.E.Jr. Duplex ultrasound measurement of postprandial intestinal blood flow: effect of meal composition. *Gastroenterology***95(5),** 1294-1301 (1988).

7. Lilly, M.P., Harward, T.R., Flinn, W.R., Blackburn, D.R., Astleford, P.M. & Yao, J.S. Duplex ultrasound measurement of changes in mesenteric flow velocity with pharmacologic and physiologic alteration of intestinal blood flow in man. *J. Vasc. Surg.***9(1),** 18-25 (1989).
8. Jäger, K., Bollinger, A., Valli, C. & Ammann, R. Measurement of mesenteric blood flow by duplex scanning. *J. Vasc. Surg.***3(3),** 462-469 (1986).
9. Chaudhuri, K.R., Thomaides, T., Hernandez, P., Alam, M. & Mathias, C.J. Noninvasive quantification of superior mesenteric artery blood flow during sympathoneutral activation in normal subjects. *Clin. Auton. Res.* **1(1),** 37-42 (1991).
10. Minvaleev, R.S., Bogdanov, R.R., Bahner, D.P. & Levitov, A.B. Headstand (sirshasana) does not increase the blood flow to the brain. *J. Altern. Complement. Med.***25(8),** 827-832 (2019).
11. Perko, M.J., Nielsen, H.B., Skak, C., Clemmesen, J.O., Schroeder, T.V. & Secher, N.H. Mesenteric. coeliac and splanchnic blood flow in humans during exercise. *J. Physiol.***513(Pt 3),** 907-913 (1998).
12. Qamar, M.I. & Read, A.E. Effects of exercise on mesenteric blood flow in man. *Gut***28(5),** 583-587 (1987).
13. Peters, H.P., de Leeuw, D., Lapham, R.C., Bol, E., Mosterd, W.L. & de Vries, W.R. Reproducibility of ultrasound blood flow measurement of the superior mesenteric artery before and after exercise. *Int. J. Sports Med.* 22, 245–249 (2001).
14. Moses, F.M. Exercise-associated intestinal ischemia. *Curr Sports Med Rep.* 4, 91-95 (2005).
15. van Wijck, K., Lenaerts, K., van Loon, L.J., Peters, W.H., Buurman, W.A. & Dejong, C.H. Exercise-induced splanchnic hypoperfusion results in gut dysfunction in healthy men. *PLoS ONE*; **6(7),** 22366; 10.1371/journal.pone.0022366 (2011).
16. Minvaleev, R.S. & Ivanov, A.I. Uddiyana-bandha. *Adaptivnaya fizicheskaya kul'tura*. **13(1),** 10-11 (2003). [Article in Russian]
17. Sieber, C., Beglinger, C., Jaeger, K., Hildebrand, P. & Stalder, G.A. Regulation of postprandial mesenteric blood flow in humans: evidence for a cholinergic nervous reflex. *Gut.***32(4),** 361-366 (1991).
18. Someya, N., Endo, M.Y, Fukuba, Y., Hayashi, N. Blood flow responses in celiac and superior mesenteric arteries in the initial phase of digestion. *Am. J. Physiol. Regul. Integr. Comp. Physiol.*; **294(6)**, R1790-6 (2008).

Declarations

Acknowledgements

The authors express their heartfelt gratitude to Irina Arkhipova, general director of the film studio of the historical film "Pharaoh", the inspirer and organizer of international scientific expeditions within the framework of her author's project "In Search of Lost Knowledge" (c), aimed at supporting national science, as well as to all participants of the expeditions "Pyrenees-2018" and "Pyrenees-2019".

Author contributions

R.M. was the principal investigator for this study. R.M. and A.L. designed the study. D.B. performed ultrasound examinations. R.M. and A.L. wrote the first draft of the manuscript. R.B. and A.K. collected and analysed the data. All authors helped to critically revise the draft and approved the final version of the paper.

Competing interests: The authors declare no competing interests.

Tables

Table 1. Descriptive characteristics of the test group.

NN	Name	Sex	Age, yr	Height, cm	Weight, kg	BMI
1	AM	m	45	184	86	25.40
2	DK	m	48	185	100	29.22
3	RB	m	41	168	65	23.03
4	RM	m	53	182	80	24.15
5	NW	f	44	165	70	25.71
6	LI	f	57	178	75	23.67
7	ES	f	38	165	52	19.10
8	DZ	f	34	174	54	17.84
9	OB	f	49	167	58	20.80
10	UT	f	51	175	75	24.49
11	GA	f	47	162	75	28.58
12	SP	f	47	170	66	22.84
Mean (SD)			46.2 (6.4)	172.9 (7.9)	71.3 (13.7)	23.74 (3.4)

Table 2. Indicators of linear and volumetric blood flow before and after the subject ES performed *agnisara* 100 times without *uddiyana bandha* and with *uddiyana bandha*.

Indicator	Agnisara			
	Without Uddiana		With Uddiana	
	before	after	before	after
Diameter, cm	0.67	0.57	0,58	0,65
Peak systolic velocity, cm / s	100.1	73.2	127.4	196
Peak diastolic velocity, cm / s	16.7	24.2	24.8	36.6
Volumetric blood flow, ml / min	634	372	529	864
Direction of change	Decrease		Increase	

Table 3. Indicators of linear and volumetric blood flow in the superior mesenteric artery before and after the performance by all subjects (n = 12) of the yoga exercise *agnisara* with the preliminary *uddiyana bandha* 100 times.

Indicator	Mean (Standard Deviation)		Probability of the Type I error, α or p-value	Power for α=0.05	Probability of the Type II error, β
	before	after			
Diameter, cm	0.605 (0.062)	0.647 (0.049)	0.01379<0.05	0.75928	0.24072
Systolic blood flow, cm/s	144.3 (63.5)	162.6 (59.4)	0.03911<0.05	0.56925	0.43075
Diastolic blood flow, cm/s	20.05 (8.64)	26.88 (9.4)	0.00336<0.01	0.92271	0.07729
Blood flow volume, ml/min	447.75 (323)	590.42 (351.5)	0.00228<0.01	0.94803	0.05197
Resistance index	0.85016 (0.037)	0.82834 (0.036)	0.13638>0.05	0.31227	0.68773

Figures

Figure 1

Agnisara exercise.

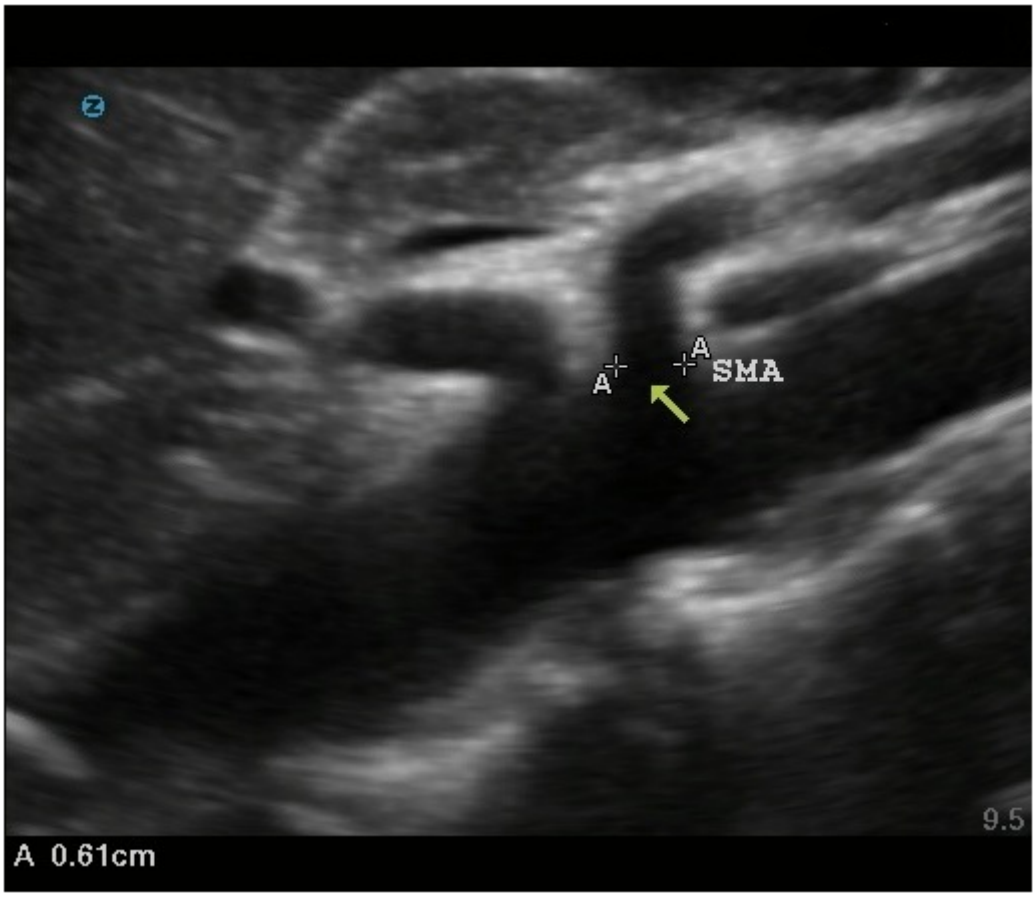

Figure 2

Ultrasound visualization of SMA.

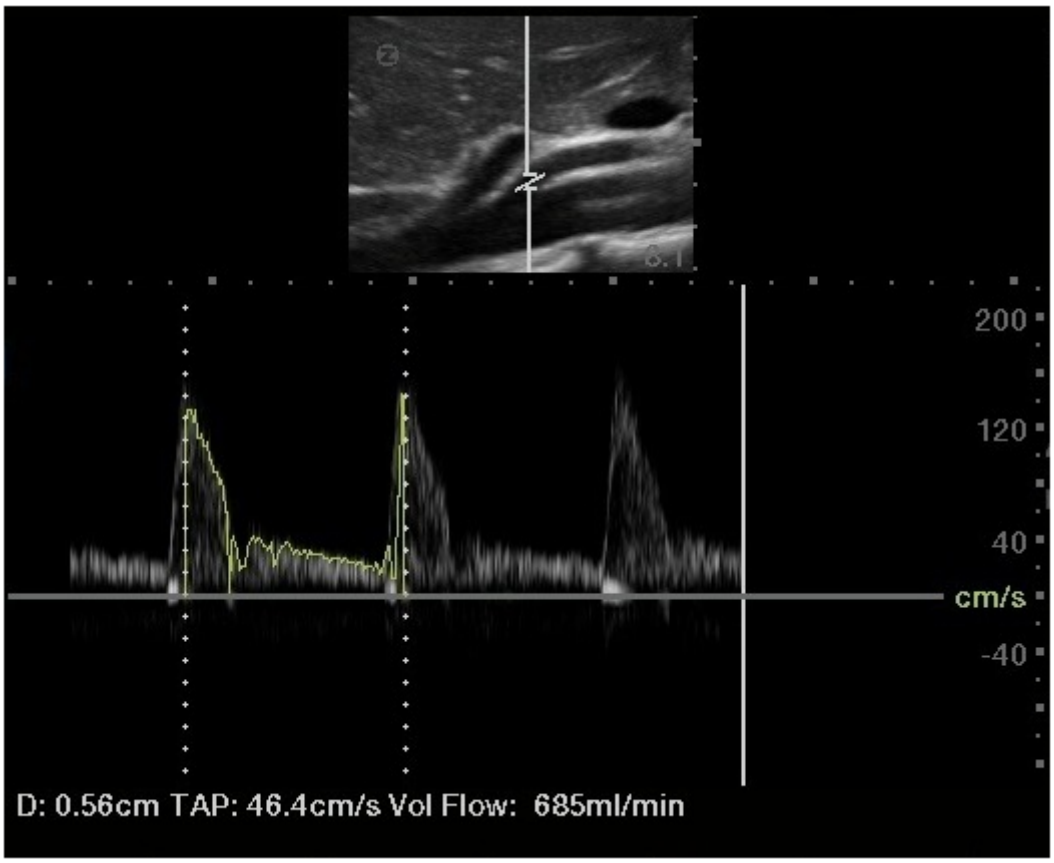

Figure 3

Typical sonogram of linear and volumetric blood flow in the superior mesenteric artery after performing the agnisara exercise.