Effect of Cervical Conization with Positive Margins on Lymph Node Metastasis in Cervical Cancer

Yukari Nagao
Nagoya University
Akira Yokoi (ayokoi@med.nagoya-u.ac.jp)
Nagoya University
Kosuke Yoshida
Nagoya University
Masanori Sumi
Nagoya University
Masato Yoshihara
Nagoya University
Satoshi Tamauchi
Nagoya University
Yoshiki Ikeda
Nagoya University
Nobuhisa Yoshikawa
Nagoya University
Kimihiro Nishino
Nagoya University
Kaoru Niimi
Nagoya University
Hiroaki Kajiyama
Nagoya University

Research Article

Keywords: cervical cancer, lymph node, positive margins

Posted Date: June 29th, 2021

DOI: https://doi.org/10.21203/rs.3.rs-640142/v1

Abstract

Radical surgery after cervical conization is a common approach for the treatment of cervical cancer. Clinically, rapid disease progression is sometimes observed in patients with positive margins at conization, but the details are unclear. This study aimed to investigate the clinical impact of positive margins at conization in cervical cancer. The medical records of patients with cervical cancer between 2010 and 2020 were reviewed retrospectively and we identified 101 eligible patients who underwent radical hysterectomy, including pelvic lymph node dissection. The association between the positive margins of the conization samples and outcomes, including subsequent lymph node metastasis, was evaluated. The rate of lymphovascular space invasion positivity at radical surgery was significantly higher in patients with positive margins ($p = 0.017$) than in those with negative margins, although there was no significant difference in the rate of pelvic lymph node metastasis ($p = 0.155$). Moreover, Kaplan–Meier curves showed that there were no significant difference in overall survival or progression-free survival between the two groups ($p = 0.332$ and $p = 0.200$, respectively). A positive margin at conization presented no significant prognostic disadvantage, and therefore, diagnostic conization is one of the reasonable options for locally advanced cervical cancer.

Introduction

Recently, the number of patients with cervical cancer has continued to increase and it remains a major health problem. In 2020, about 600,000 patients were diagnosed with cervical cancer globally, and more than 340,000 patients died due to the progression of the disease [1]. In comparison with other developed countries, the cervical cancer prevention program has been unsatisfactory in Japan, and the human papillomavirus vaccination and Pap smear rates were only 0.3% and 34%, respectively, in 2016 [2 3 4]. Hence, the incidence has remained unchanged in recent years, with about 34,000 newly diagnosed patients and 3,000 deaths annually [5 6]. Moreover, in developing countries, the prevention program has not been fully provided. Therefore, cervical cancer remains a life-threatening disease.

Cervical cancer is usually diagnosed based on a combination of pelvic examination, colposcopy, and radiological findings. Moreover, especially for early stage disease, diagnostic conization is one of the options for evaluating the spread of the disease more accurately. According to the National Comprehensive Cancer Network (NCCN) guidelines (Version 4.2019 Cervical Cancer), diagnostic conization such as “Cone biopsy (i.e., conization) is recommended if the cervical biopsy is inadequate to define invasiveness or if accurate assessment of microinvasive disease is required” (MS-4) [7]. Subsequently, based on the stage and pathological findings of conization, the treatment method is determined. Radical hysterectomy, concurrent chemoradiation (CCRT) and radiation therapy (RT) are major treatment options for cervical cancer. In the case of radical hysterectomy, it is necessary to evaluate whether pelvic lymph node dissection should be performed because adverse events like lymphedema can occur. Therefore, it is highly required that accurate preoperative risk assessment of lymph node metastasis is performed. As reported in several studies, lymphovascular space invasion

(LVSI) is a risk factor for lymph node metastasis, and therefore, diagnostic conization can be useful for risk assessment [8 9 10 11 12]. However, there is a concern regarding excessive conization for locally advanced cases that may cut into the tumor itself. In fact, clinically, rapid disease progression is sometimes observed in patients with positive margins at conization, but the details are unclear.

Therefore, this study aimed to evaluate the clinical impact of cervical conization with positive margins on subsequent tumor progression and prognosis of patients with cervical cancer.

Patients And Methods

We retrospectively reviewed the records of 443 patients with cervical cancer who underwent radical surgery at the Nagoya University Hospital (Nagoya, Japan) from January 2010 to May 2020. Several gynecologic oncologists in our hospital determined the treatment strategies for each patient, and diagnostic conization was performed when biopsy findings were insufficient. In accordance with the Japanese guidelines, if possible, radical surgery plus pelvic lymph node dissection was performed, and adjuvant CCRT or RT was considered depending on pathological findings. Otherwise, patients basically received CCRT. Of the 443 patients, we included 101 patients who underwent conization followed by radical surgery in the present study, excluding 342 patients without conization (Fig. 1). Based on the pathological findings of conization, we classified the patients into the positive margin (69 patients) and negative margin (32 patients) groups. We investigated the clinical information including age, stage, histological type, LVSI at conization, LVSI at radical surgery, pelvic lymph node metastasis, adjuvant therapy, recurrence, and outcome and compared the clinical outcomes between the two groups. This study was approved by the ethics committee of our institute (Approval No. 2019 – 0106, Nagoya University Graduate School of Medicine, Nagoya, Japan). All methods were carried out in accordance with relevant guidelines and regulations and our study strictly followed the requirements of the Declaration of Helsinki. Informed consent was obtained from all participants.

Statistical analyses were performed using SPSS version 27 (IBM Corp., Armonk, NY). Mann–Whitney U test and chi-squared tests were used for comparing the two groups. Overall survival (OS) was defined as the time from the primary therapy to all-cause mortality, and progression-free survival (PFS) was the time from primary therapy to tumor progression, recurrence, or all-cause mortality. Kaplan–Meier curves were used for the analysis of OS and PFS, whereas the log-rank test was used to compare the survival curves. A p value of < 0.05 was considered statistically significant.

Results

Patient characteristics are shown in Table 1, and age, stage, and histology were well-balanced between the two groups. In particular, the margin positivity and LVSI positivity at conization were independent of each other ($p = 0.417$).

Table 1
Characteristics of 101 patients

	Positive margin group (n = 69)	**Negative margin group (n = 32)**	***p* value**
Age (years)			0.242
Median (range)	34 (25–59)	37 (23–68)	
Stage (FIGO 2008)			0.379
IA1	3 (4.3%)	1 (3.1%)	
IA2	7 (10.1%)	5 (15.6%)	
IB1	56 (81.2%)	26 (81.3%)	
IB2	1 (1.4%)	0	
IIA1	2 (2.9%)	0	
Histological type			0.377
SCC*	51 (73.9%)	26 (81.3%)	
AC†	12 (17.4%)	5 (15.6%)	
ASC‡	6 (8.7%)	1 (3.1%)	
LVSI at conization			0.417
Positive	34 (49.3%)	13 (40.6%)	
Negative	35 (50.7%)	19 (59.4%)	
*SCC, Squamous cell carcinoma; †AC, Adenocarcinoma; ‡ASC, Adenosquamous carcinoma			
P value of < 0.05 was considered statistically significant.			

First, we investigated whether positive margins at conization contributed to cancer progression. The LVSI positive rate at radical surgery was significantly higher in the positive margin group than in the negative margin group (the positive and negative margin groups, 21.7% and 3.1%, respectively; $p = 0.017$; Table 2). Similarly, pelvic lymph node metastasis tended to increase in the positive margin group; however, there was no significant difference between the groups (the positive and negative margin groups, 11.6% and 3.1%, respectively; $p = 0.155$). In addition, we focused on patients with stage IB1 squamous cell carcinoma, the main subpopulation of our cohort. Similar to the above results, LVSI at radical surgery was also significantly higher in patients in the positive margin group than in those in the negative margin group (the positive and negative margin groups, 27.3% and 0%, respectively; $p = 0.005$; Table 3). Moreover, a high frequency of lymph node metastasis was observed in the positive margin group, with no significant difference (the positive and negative margin groups, 11.4 % and 4.8 %, respectively; $p = 0.362$).

Table 2
The association between a positive margin at conization and metastatic potential in all patients

	Positive margin group (n = 69)	**Negative margin group (n = 32)**	***p* value**
LVSI* at radical surgery			0.017
Positive	15 (21.7%)	1 (3.1%)	
Negative	54 (78.3%)	31 (96.9%)	
Lymph node metastasis			0.155
Positive	8 (11.6%)	1 (3.1%)	
Negative	61 (88.4%)	31 (96.9%)	
*LVSI, Lymphovascular space invasion			
P value of < 0.05 was considered statistically significant.			

Table 3
The association between a positive margin at conization and metastatic potential in stage IB1 squamous cell carcinoma

	Positive margin group (n = 44)	**Negative margin group (n = 21)**	***p* value**
LVSI* at radical surgery			0.005
Positive	12 (27.3%)	0 (0%)	
Negative	32 (72.7%)	21 (100%)	
Lymph node metastasis			0.362
Positive	5 (11.4%)	1 (4.8%)	
Negative	39 (88.6%)	20 (95.2%)	
*LVSI, Lymphovascular space invasion			
P value of < 0.05 was considered statistically significant.			

Subsequently, we evaluated the difference between the LVSI status at conization and at radical surgery (Fig. 2a). The LVSI statuses at conization and radical surgery were consistent in most patients. However, negative LVSI at conization became positive at radical surgery in four cases, three of whom were in the positive margin group. The detailed clinical information about one of the cases is shown in Fig. 2b-d. She underwent diagnostic conization because both Pap smear and biopsy were negative, despite suspicions of cervical cancer by transvaginal ultrasound. In conization, the tumor was resected to the extent

possible, while cutting through the tumor wall. Hematoxylin and eosin staining revealed that it was a pT1b1 adenocarcinoma (AC) with negative LVSI and a positive surgical margin (Fig. 2b). However, after radical surgery, the disease up-staged to pT2a1N1 and LVSI turned highly positive (Fig. 2c). Moreover, obvious enlargement of the left common iliac lymph node was identified using computed tomography, although there were no swelling before conization (Fig. 2d).

Finally, we analyzed the PFS and OS in the positive and negative margin groups. The median follow-up period was 56 months (range: 4–124 months). The 5-year PFS rates in the positive and negative margin groups were 92.3% and 96.8%, respectively (Fig. 3a). The 5-year OS rates in the positive and negative margin groups were 96.6 % and 100 %, respectively (Fig. 3b). Kaplan–Meier curves indicated that there were no statistically significant differences between the two groups in PFS ($p = 0.200$; log-rank test) and OS ($p = 0.332$; log-rank test).

Discussion

According to the Japanese and NCCN guidelines, diagnostic conization is an important method for determining the exact stage and the most accurate treatment strategy for patients with cervical cancer [7] [13] [14]. However, as depicted by the results of the present study, there is a potential risk of cutting into a tumor in some cases and resulting in a positive margin at conization. Until now, there is no consensus on whether diagnostic conization is appropriate even when positive margins are predicted. Therefore, we evaluated the association between diagnostic conization with positive margins and patient outcomes, including lymph node metastasis in uterine cervical cancer.

The basic principles of oncologic surgery are careful tumor manipulation, resection in tumor-free margins, and avoidance of tumor spillage [15]. For example, Turnbull et al. proposed the no-touch isolation technique in colon cancer surgery in 1967 [16]. This method involves vascularization first and then tumor removal to prevent hematogenous metastasis, and it contributed to a favorable 5-year survival rate. Hence, the method has also been applied for pancreatic and liver cancers [17] [18]. For uterine cervical cancer, patients who underwent minimally invasive radical hysterectomy could have shorter survival than those who underwent conventional abdominal radical hysterectomy. A possible explanation is the use of an intrauterine manipulator in the minimally invasive surgery, which might increase intrauterine pressure and spread cancer cells to the lymphovascular space [15] [19] [20] [21]. However, other reports showed that the use of manipulators is not associated with worse prognosis, and its clinical significance is still debated [22] [23]. Therefore, the basic principles are important, but they are not absolute factors, and other factors may have a great influence.

Diagnostic conization does not meet these principles in case of a positive margin. The risk of positive margins at conization was associated with several factors, such as menopausal status, grade and size of disease, devices used for conization, and purpose of conization (diagnostic or therapeutic) [24] [25] [26]. According to previous studies, a positive margin at conization would mean residual disease; however, it

was not associated with parametrial invasion at the time of hysterectomy [27 28 29]. In the present study, we showed that positive margins may increase the rate of LVSI positivity in hysterectomy samples, although there was no statistical significance regarding pelvic lymph node metastasis. Moreover, there was no significant difference in PFS and OS between the positive and negative margin groups. Consistent with our results, a recent report also indicated that there were no significant differences in lymph node metastasis, LVSI positivity, recurrence, and death between the patients with positive and negative margins [30]. Therefore, the prognostic impact of a positive margin at conization was considered to be limited.

However, in some cases, obvious lymph node enlargement and strong LVSI positivity can occur after diagnostic conization with a positive margin. Needless to say, lymph node metastasis is one of the worst prognostic factors in cervical cancer [31 32]. Therefore, regardless of the lack of statistical significance, clinicians should keep in mind that there are cases with rapid progression after conization. Moreover, due to the present relatively small-scale retrospective study, it was difficult to statistically evaluate such rare cases. Therefore, further studies are needed to evaluate the potential risk of a positive margin at conization.

In conclusion, the present study provided important evidence for the association between cervical conization with positive margins and subsequent cancer progression. We showed that there were no significant differences in the lymph node metastasis rate and patient prognosis between the positive and negative margin groups. Therefore, diagnostic conization is considered acceptable even if a positive margin will occur.

Declarations

Acknowledgments

We express the highest appreciation to the entire staff of the Department of Obstetrics and Gynecology, Nagoya University Graduate School of Medicine. This study was supported by the Aichi Cancer Research Foundation, Yokoyama Foundation for Clinical Pharmacology grant number TRY-2014, and Program for Promoting the Enhancement of Research Universities as young researcher units for the advancement of new and undeveloped fields at the Nagoya University. Furthermore, we thank Enago (https://www.enago.jp/) for English language editing of this manuscript.

Author contributions:

All authors contributed to the study conception and design. Material preparation, data collection and analysis were performed by M.S., Y.N., K.Y. and A.Y. The first draft of the manuscript was written by Y.N. and all authors commented on previous versions of the manuscript. All authors read and approved the final manuscript.

Competing interests

The authors declare no competing interests.

References

1. Cancer, I. A. f. R. o. *GLOBOCAN2020, Cervix uteri, Cancer incidence and mortality statistics worldwide and by region*, https://gco.iarc.fr/today/data/factsheets/cancers/23-Cervix-uteri-fact-sheet.pdf (2020).
2. Ho, C. M. *et al.* Multivariate analysis of the prognostic factors and outcomes in early cervical cancer patients undergoing radical hysterectomy. *Gynecol Oncol*, **93**, 458–464 https://doi.org/10.1016/j.ygyno.2004.01.026 (2004).
3. Tanaka, Y. *et al.* Outcomes for girls without HPV vaccination in Japan. *Lancet Oncol* **17**, 868–869, doi:10.1016/s1470-2045(16)00147-9 (2016).
4. Ministry of Health, L. a. W. *Cancer Registry and Statistics. Cancer Information Service, National Cancer Center, Japan (Survey of cancer screening status by prefecture)*, https://ganjoho.jp/reg_stat/statistics/dl_screening/index.html (2015–2018).
5. Ministry of Health, L. a. W. *Cancer Registry and Statistics. Cancer Information Service, National Cancer Center, Japan (Vital Statistics of Japan)*, https://ganjoho.jp/reg_stat/statistics/dl/index.html (1958–2013).
6. Ministry of Health, L. a. W. *Cancer Registry and Statistics. Cancer Information Service, National Cancer Center, Japan (National Cancer Registry)*, https://ganjoho.jp/reg_stat/statistics/dl/index.html (2016–2017).
7. Network, N. C. C. *NCCN Clinical Practice Guidelines in Oncology Version 4.2019 Cervical Cancer*, https://www.nccn.org/professionals/physician_gls/default.aspx (2019).
8. Delgado, G. *et al.* A prospective surgical pathological study of stage I squamous carcinoma of the cervix: a Gynecologic Oncology Group Study. *Gynecol Oncol* **35**, 314–320, doi:10.1016/0090-8258(89)90070-x (1989).
9. Roman, L. D. *et al.* Influence of quantity of lymph-vascular space invasion on the risk of nodal metastases in women with early-stage squamous cancer of the cervix. *Gynecol Oncol* **68**, 220–225, doi:10.1006/gyno.1998.4943 (1998).
10. Chandacham, A. *et al.* Extent of lymphovascular space invasion and risk of pelvic lymph node metastases in stage IB1 cervical cancer. *J Med Assoc Thai* **88 Suppl 2**, S31-36 (2005).
11. Milam, M. R. *et al.* Preoperative lymph-vascular space invasion is associated with nodal metastases in women with early-stage cervical cancer. *Gynecol Oncol* **106**, 12–15, doi:10.1016/j.ygyno.2007.04.010 (2007).
12. Yan, M., Zhang, Y. N., He, J. H., Sun, J. R. & Sun, X. M. Influence of lymph vascular space invasion on prognosis of patients with early-stage cervical squamous cell carcinoma. *Chin J Cancer* **29**, 425–430, doi:10.5732/cjc.009.10528 (2010).

13. Oncology, J. S. o. G. *Guidelines for treatment of uterine cervical cancer 2017 edition* (Kanehara & Co., 2017).
14. Japan Society of Obstetrics and Gynecology, T. J. S. o. P., Japan Radiological Society, Japanese Society for Radiation Oncology. *The General Rules for Clinical and Pathological Management of Uterine Cervical Cancer Clinical edition* (Kanehara & Co, 2020).
15. Kohler, C. *et al.* Laparoscopic radical hysterectomy with transvaginal closure of vaginal cuff - a multicenter analysis. *Int J Gynecol Cancer* **29**, 845–850, doi:10.1136/ijgc-2019-000388 (2019).
16. Turnbull, R. B., Jr., Kyle, K., Watson, F. R. & Spratt, J. Cancer of the colon: the influence of the no-touch isolation technic on survival rates. *Ann Surg* **166**, 420–427, doi:10.1097/00000658-196709000-00010 (1967).
17. Kuroki, T. & Eguchi, S. No-touch isolation techniques for pancreatic cancer. *Surg Today* **47**, 8–13, doi:10.1007/s00595-016-1317-5 (2017).
18. Lee, J. M., Lee, K. W., Kim, H. C., Yi, N. J. & Suh, K. S. No touch isolation technique for the prevention of postoperative recurrence of hepatocellular carcinoma after liver transplantation-combined with trans-arterial radioembolization. *Surg Oncol* **35**, 189–190, doi:10.1016/j.suronc.2020.08.024 (2020).
19. Ramirez, P. T. *et al.* Minimally Invasive versus Abdominal Radical Hysterectomy for Cervical Cancer. *N Engl J Med* **379**, 1895–1904, doi:10.1056/NEJMoa1806395 (2018).
20. Kavallaris, A., Chalvatzas, N., Gkoutzioulis, A. & Zygouris, D. Laparoscopic nerve-sparing radical hysterectomy without uterine manipulator for cervical cancer stage IB: description of the technique, our experience and results after the era of LACC trial. *Arch Gynecol Obstet* **303**, 1039–1047, doi:10.1007/s00404-020-05835-5 (2021).
21. Köhler, C., Schneider, A., Marnitz, S. & Plaikner, A. The basic principles of oncologic surgery during minimally invasive radical hysterectomy. *J Gynecol Oncol* **31**, e33, doi:10.3802/jgo.2020.31.e33 (2020).
22. Nica, A. *et al.* Survival after minimally invasive surgery in early cervical cancer: is the intra-uterine manipulator to blame? *Int J Gynecol Cancer* **30**, 1864–1870, doi:10.1136/ijgc-2020-001816 (2020).
23. Liu, Y., Huang, S., Ming, X., Jing, H. & Li, Z. Surgical Approach and Use of Uterine Manipulator Are Not Associated with LVSI in Surgery for Early-stage Cervical Cancer. *J Minim Invasive Gynecol*, doi:10.1016/j.jmig.2021.01.013 (2021).
24. Lu, H. X. *et al.* [Study on high risk factors associated with positive margin of cervix conization in patient with cervical intraepithelial neoplasia]. *Zhonghua Fu Chan Ke Za Zhi* **44**, 200–203 (2009).
25. Cheng, X. *et al.* The effectiveness of conization treatment for post-menopausal women with high-grade cervical intraepithelial neoplasia. *Exp Ther Med* **5**, 185–188, doi:10.3892/etm.2012.748 (2013).
26. Yamamoto, R. *et al.* Value and limitation of conization as a diagnostic procedure for cervical neoplasm. *J Obstet Gynaecol Res* **45**, 2419–2424, doi:10.1111/jog.14118 (2019).
27. Diaz, E. S. *et al.* Predictors of residual carcinoma or carcinoma-in-situ at hysterectomy following cervical conization with positive margins. *Gynecol Oncol* **132**, 76–80,

doi:10.1016/j.ygyno.2013.11.019 (2014).

28. Baiocchi, G. *et al.* Predictive Factors for Residual Disease After Conization in Cervical Cancer. *Ann Surg Oncol*, doi:10.1245/s10434-021-09656-x (2021).
29. Smith, B. *et al.* Less radical surgery for early-stage cervical cancer: Can conization specimens help identify patients at low risk for parametrial involvement? *Gynecol Oncol* **144**, 290–293, doi:10.1016/j.ygyno.2016.11.029 (2017).
30. Bizzarri, N. *et al.* Protective Role of Conization Before Radical Hysterectomy in Early-Stage Cervical Cancer: A Propensity-Score Matching Study. *Ann Surg Oncol*, doi:10.1245/s10434-021-09695-4 (2021).
31. Kamura, T. *et al.* Multivariate analysis of the histopathologic prognostic factors of cervical cancer in patients undergoing radical hysterectomy. *Cancer* **69**, 181–186, doi:10.1002/1097-0142(19920101)69:1<181::aid-cncr2820690130>3.0.co;2-b (1992).
32. Ho, C. M. *et al.* Multivariate analysis of the prognostic factors and outcomes in early cervical cancer patients undergoing radical hysterectomy. *Gynecol Oncol* **93**, 458–464, doi:10.1016/j.ygyno.2004.01.026 (2004).

Figures

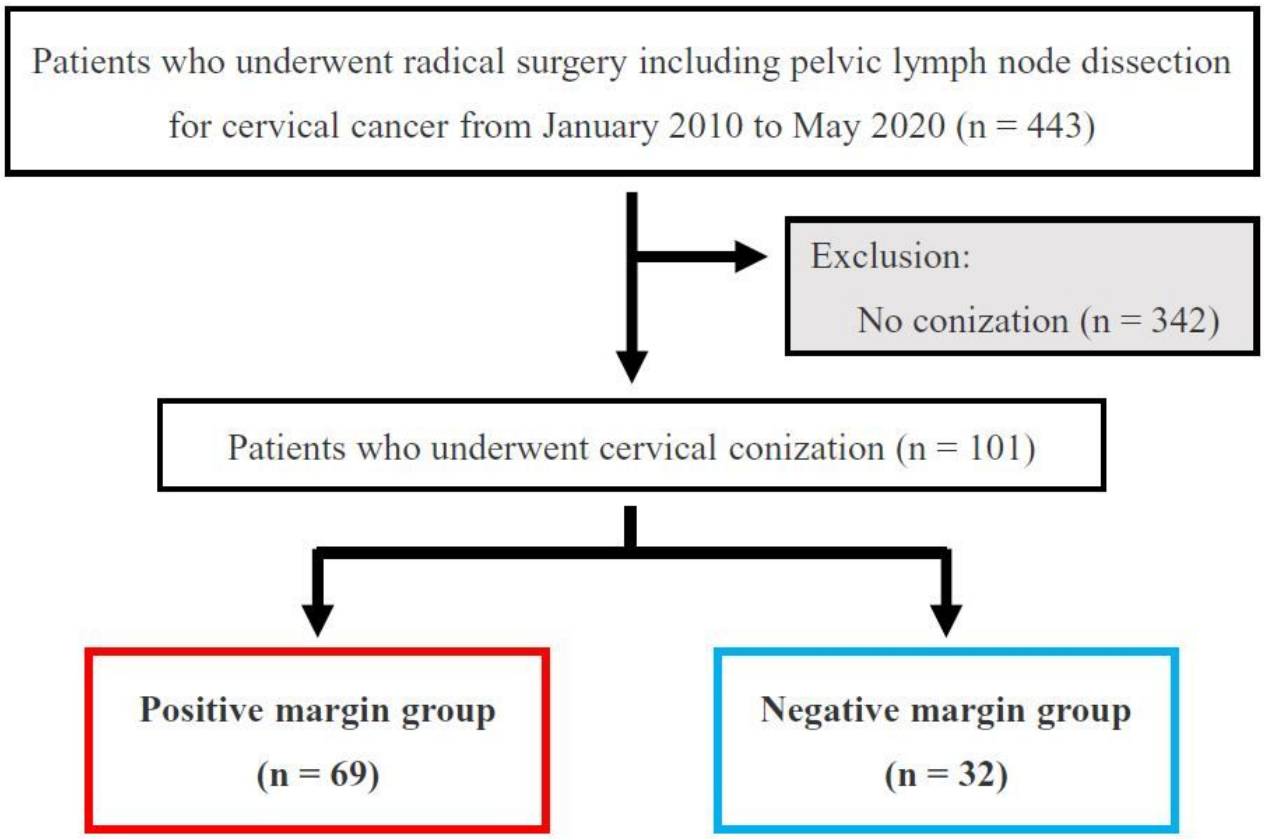

Figure 1

Flowchart of patient selection Of the 443 patients who underwent radical surgery, including pelvic lymph node dissection, for cervical cancer from January 2010 to May 2020, we excluded 342 patients without conization and included 101 patients with conization. Of the 101 patients, 69 had positive margins at conization and 32 had negative margins

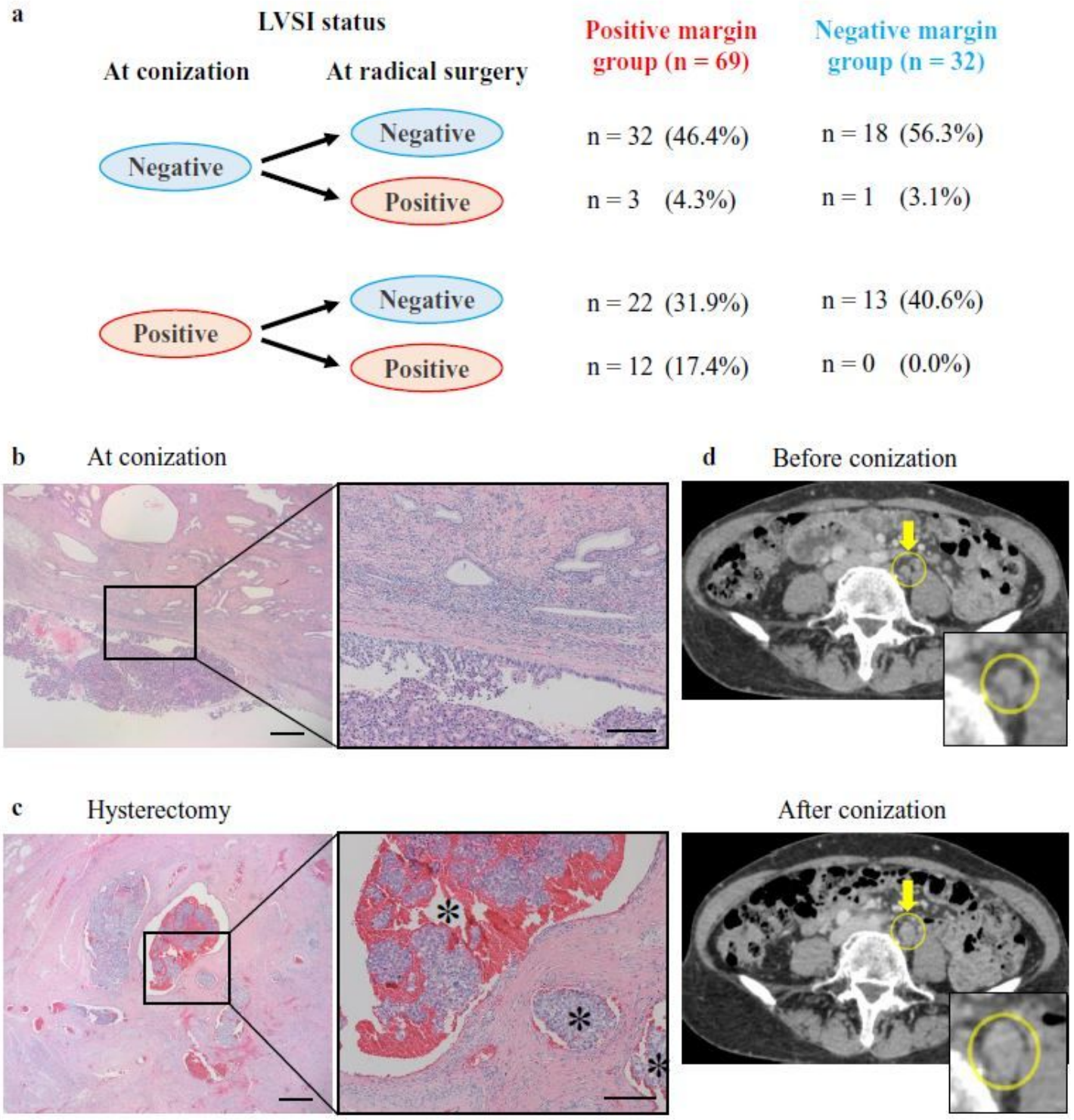

Figure 2

LVSI status at conization and at radical surgery (a) The relationship between the LVSI at conization and at radical surgery. (b and c) Representative histological images. Asterisks indicate tumors in vessels (LVSI positive). The scale bars: left; 50 μm and right; 20 μm. (d) Representative computed tomography images of the case before/after conization

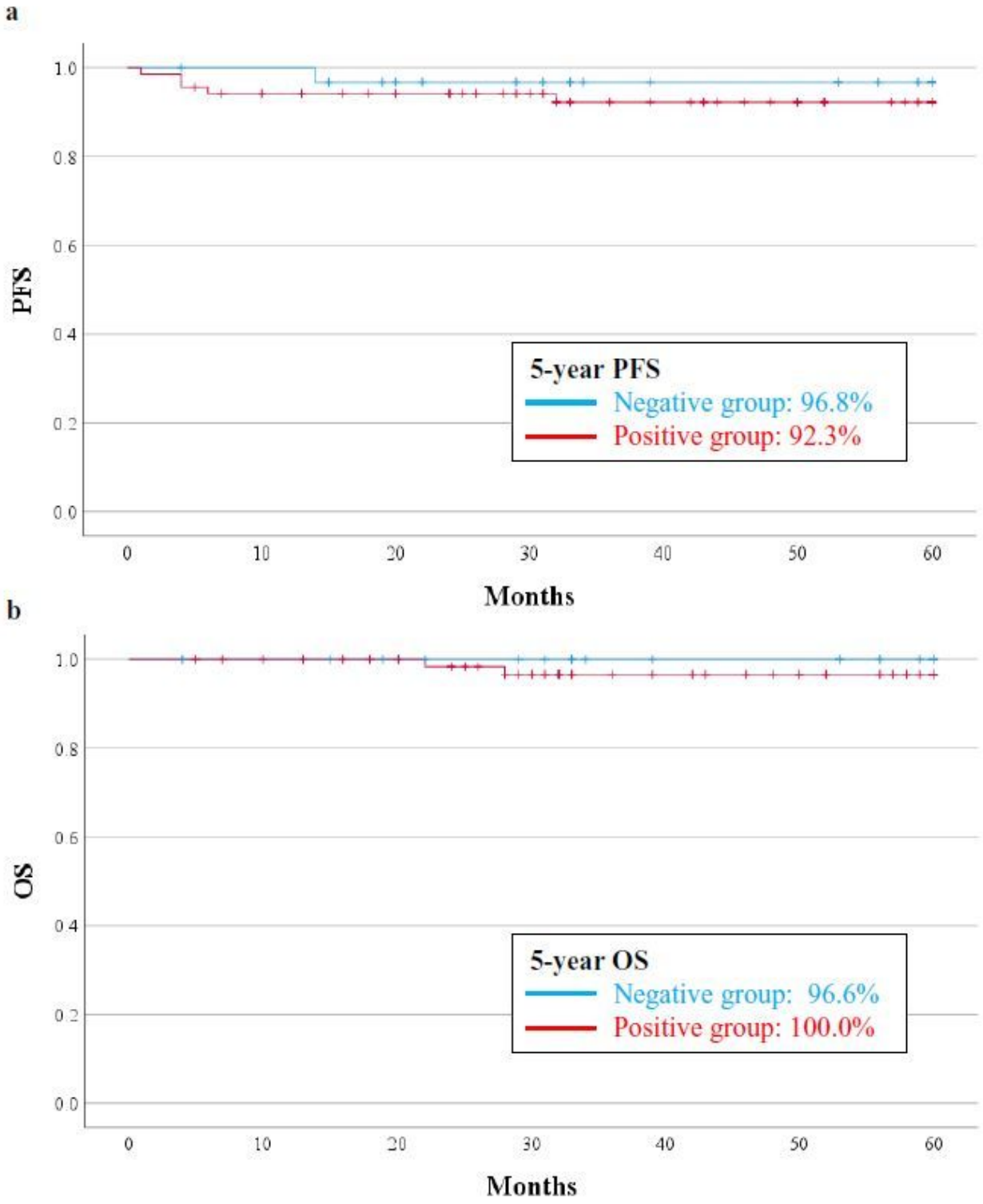

Figure 3

Prognosis of the patients Kaplan–Meier curves showing (a) PFS and (b) OS stratified by the positive and negative margin groups. Survival curves were compared using the log-rank test, but there were no significant differences in PFS and OS between the two groups