Comparison of Complication Rates, Fluoroscopy Exposure Time, and Functional Results of Two K-wire Fixation Methods in Distal Radius Fractures in Pediatric Patients: Could Mini-incision Technique Feasible for Orthopedic Surgeons?

ERSIN TASATAN (drersintasatan@yahoo.com)

Okmeydani Training and Research Hospital: Turkiye Cumhuriyeti Saglik Bakanligi Okmeydani Egitim ve Arastirma Hastanesi https://orcid.org/0000-0002-4018-0320

Ali Cagrı TEKIN

Okmeydani Training and Research Hospital: Turkiye Cumhuriyeti Saglik Bakanligi Okmeydani Egitim ve Arastirma Hastanesi

---

Research article

Keywords: Distal Radius, fracture, percutaneous pinning, mini-open technique

Posted Date: July 1st, 2021

DOI: https://doi.org/10.21203/rs.3.rs-657883/v1

Abstract

Background: In this study, we aimed to compare the complications rates especially such as neuropraxia, and tendon irritation after percutaneous K-wire fixation and K-wire fixation with mini-open techniques in pediatric distal radius fractures. Secondly, we wanted to observe the differences between the functional results of the patients.

Methods: In this retrospective design study, we enrolled 117 patients who were treated between March 2016- January 2019 for completely displaced fracture of the distal radius. One-hundred patients were evaluated in terms of demographic data, radiological and functional evaluations, and complications. In the first group, 50 patients were treated by closed reduction and percutaneous K wire application. In the second group; 50 patients were treated close reduction and K-wire fixation using mini-incision. In the 6th week, following the removal of the splint and pins, the range of motion (ROM) was evaluated. Additional radiographic evaluation was used to confirm remodeling, according to the amount of angulation in the fracture line. Patients were called in for functional and radiological evaluation at the 18th month.

Results: There were 36 (72%) boys, 14 (28%) girls in Group 1, and 38 (76%) boys, 12 (24%) girls in Group 2. The mean ages were 11,95±1,34 years and 11,75±1,25 years in Group 1 and 2 respectively. The mean fluoroscopy time was 28,6 ±7,1 seconds in Group 1 while, 15,4±5,3 seconds in Group 2. The fluoroscopy time was significantly low in Group 2 (p=0.002). Re-displacement rates were 10% in K-wire fixation percutaneously and 4% in K-wire with mini-open group respectively and it was significantly lower in mini-open group (p=0.026).

Conclusions: The mini-open incision technique had lower complication rates and fluoroscopy durations. Based on the results of this study, K-wire fixation with mini-open technique can be recommended as an alternative method for pediatric distal radius fractures.

Background

The distal radius is the most common site of the pediatric fracture, accounting for 20–30% of all fractures [1]. The choice of treatment for distal radius fractures is based on the instability of the fracture and consequently on the risk of re-displacement. Eighty-five percent of displaced distal radius fractures can be successfully managed with conservative treatment [2]. When the treatment decision is evaluated in terms of indications, the distal radius with an angulation inferior to 20° is acceptable in children younger than 10 years, whereas an angulation inferior to 10° is acceptable for older children [3]. Most of these fractures in children have been treated by a good closed anatomical reduction and immobilization in a cast [4, 5], but re-displacement following conservative treatment of displaced distal radius fractures has been reported at high rates [4, 6]. The main risk factors for re-displacement are; completely displaced fracture, > 11° angulation in the coronal plane, and an intact ulna, patient age [7, 8]. The completely displaced distal radius fractures are very unstable because of the distruption of both cortices. Because of the significant risk for re-displacement, it is advocated immediate K-wire placement is an effective

method in completely displaced distal radius fractures of children [4, 5, 7, 10, 11]. Although good results have been reported with K-wire fixation, superficial infection, neuropraxia, tendon irritation, pull out of wire, subcutaneous K-wires, and prominent scars have been reported as complications after pinning [11–13]. In the conventional pinning technique, K-wire is inserted just proximal or through the distal radial physis and transfixed across the fracture site [14, 15]. However, correction of angulation via conventional pinning is somehow difficult because the entry point of crossed K-wires is very close to the fracture line where the marrow cavity is getting narrower in this area. Currently, there are several studies in the literature indicating the mini-open technique's application in surgical treatment, such as femoral acetabular impingement, achilles tendon and rotator kuff repair [16–18]. Insight of these knowledge, we looked for an option that eliminates these problems. In this study, we aimed to compare the complications rates especially such as neuropraxia, and tendon irritation after percutaneous K-wire fixation and K-wire fixation with mini-open techniques.

Methods

The local ethics committee approved the study protocol (protocol number 48670771-514.10) and the study was carried out according to the principles of the Declaration of Helsinki (2013). In this retrospective consecutive case series, we enrolled 117 patients who were treated between March 2016-January 2019 for completely displaced fracture of the distal radius.

The patients' demographic characteristics, relevant clinical data, radiologic findings were obtained from the hospital's electronic database. Seventeen patients who had an open fracture, a pathological fracture, definite physis damage, wrist injury at the initial trauma site and lost for follow-up were excluded from the study. Thus 100 patients were evaluated in terms of demographic data, radiological and functional evaluations, and complications.

In the first group, 50 patients were treated by closed reduction and percutaneous K wire application. In the second group; 50 patients were treated close reduction and K-wire fixation using mini-incision. Cast immobilization in a below-elbow cast for 6 weeks was applied in both groups.

Patient's operations were performed using general anesthesia and the patient in a supine position with the arm placed on a hand-and-arm table. Under fluoroscopic guidance with AP and lateral images, the reduction was performed with traction and closed manipulation. In Group 1 one of the K-wire was advanced retrograde from 2 cm proximal of styloid to cross the fracture and the second K-wire was used retrograde from 2 cm proximal of styloid to cross the fracture and advanced parallel direction of the first K-wire. The 1,6 mm size of the K-wires was used for all patients. The ends of the K-wires were bent, then cut and left over the skin. In Group 2 following manipulation, a 10 mm transverse skin incision was made over 2 cm proximally from radial styloid, and blunt dissection was made and two K-wires were applied as described for the patients in Group 1 (Fig. 1 and Fig. 2).

The same fluoroscopy imaging unit was used by the same radiology technician in all cases. All the operations were performed by ≥ 10 years of experience in orthopedic surgeons.

Postoperatively, a below-elbow cast was applied to the arm. The children underwent clinical evaluation at 2nd, 4th and 6th weeks after initial trauma. During these visits, the casts were revised and renewed where necessary.

Finally, both the cast and the K wires were removed in the outpatient clinic after 6 weeks. Active exercises were initiated after K-wire removal. The children were then permitted to resume their routine daily activities. No formal physical therapy was prescribed. Additional radiographic evaluation was used to confirm fracture healing according to the amount of angulation in the fracture line. Patients were called in for functional and radiological evaluation at the 18th month.

At the 18th month follow-up, the wrist ROM was assessed with a goniometer and compared with that of the contralateral wrist. Appearance and patient satisfaction with the forearm was assessed using a 10-cm visual analog scale score (VAS) cosmetics, with maximum score for similar appearance of the fractured and the non-fractured arm, to evaluate forearm alignment and scars [20, 21]. Radiographic angulation was considered malalignment if it exceeded 15 degrees [5].

Antero-posterior and lateral radiographs were taken at scheduled times. The first radiographs were made in the emergency room followed by radiographs after reduction and during follow-up at 2nd, 4th and 6th weeks. The final radiographs were made 18 months after the trauma.

Statistical Analysis

The normality of variables was tested by the Shapiro–Wilk test. Numerical variables reflecting normal distribution were stated as mean ± standard deviation (SD) and those not reflecting normal distribution as median (minimum-maximum) values. Categorical variables were stated as number (n) and percentage (%). As there were two groups, differences between the groups in numerical variables not showing normal distribution were evaluated with the Mann–Whitney U test, and relationships between categorical variables were determined with the Pearson chi-square test and the Fisher Exact test. $P < 0.05$ was considered statistically significant.

Results

There were 36 (72%) boys, 14 (28%) girls in Group 1, and 38 (76%) boys, 12 (24%) girls in Group 2. The mean ages were 11.95 ± 1.34 years and 11.75 ± 1.25 years in Group 1 and 2 respectively. There were no statistically significant differences between the two groups in terms of age, fracture degree, reduction degree, and follow-up duration ($p > 0.005$) (Table 1). The mean fluoroscopy time was 28.6 ± 7.1 seconds in Group 1 while, 15.4 ± 5.3 seconds in Group 2. The fluoroscopy time was significantly low in Group 2 ($p = 0.002$). Re-displacement rates were 20% in K-wire fixation percutaneously and 4% in K-wire with mini-open group respectively and it was significantly lower in mini-open group ($p = 0.026$).

Table 1
Patient demographics and follow-up data (Group 1: Percutan K-wire fixation; Group 2: K-wire fixation with a mini-incision)

	Group 1	Group 2	P value
Age	11,95 ± 1,34	11,75 ± 1,25	0,458
Fracture Degree	20,62 ± 4,65	19,55 ± 4,98	0,267
Reduction Degree	2,60 ± 1,42	2,51 ± 1,53	0,762
Follow-up Duration (Month)	18,12 ± 4,73	18,02 ± 4,80	0,592
Fluoroscopy time (seconds)	28,6 ± 7,1	15,4 ± 5,3	0.002*
VAS (VAS 2–3)	3 (6%)	2 (4%)	0.86
ROM Limitations (Pronation/Supination)	4 (< 10°)	3 (< 10°)	0.99
ROM: range of motion; VAS: visual analog scale score			
Pearson Chi-Square Test (Monte Carlo), p < 0.05 considered as significant*			

Ten (20%) patients in Group 1 and 3 (6%) patients in Group 2 developed superficial pin-site infections ($p = 0.037$); all patients recovered with oral antibiotics and daily dressings. The K-wire had advanced subcutaneously because of pin migration in 7 patients (14%) in Group 1, and 1 patient (2%) in Group 2 ($p = 0.027$). In Group 1 transient neuropraxia and tendon irritation were developed in 4 (8%) and 5 (%10) patients respectively. None of the patients in Group 2 had tendon irritation or transient neuropraxia. We found significantly lower complication rates in the mini-open technique group than the percutanous K-wire fixation group ($p < 0.005$). The complications were summarized in Table 2. At the final follow-up examination, none of the patients had non-union, radioulnar synostosis, vascular damage, premature physeal closure. In 4 patients in Group 1 and 3 patients in Group 2 had observed < 10° pronation-supination ROM restriction, total ROM was > 120° and none of these patients was aware of the restriction. There was no ROM restriction in other directions. No statistically significant difference was determined between the groups in terms of VAS cosmetic scores ($p > 0.005$) (Table 1) (Fig. 3 and Fig. 4).

Table 2
Complications of the patients

	Group 1 (n/%)	Group 2 (n/%)	P value
Re-Displacement	10 (20%)	2 (4%)	0,026*
Pin track Infection	10 (20%)	3 (6%)	0,037*
Subcutaneous K wire	7 (14%)	1 (2%)	0,027*
Failed Insertion	4 (8%)	0 (0%)	0,041*
Pull out of K wire	2 (4%)	0 (0%)	0,153
Angulation	6 (12%)	0 (0%)	0,012*
Transient Neuropaxia	4 (8%)	0 (0%)	0,041*
Tendon Irritation	5 (10%)	0 (0%)	0,022*
*Pearson Chi-Square Test (Monte Carlo), f Fisher Exact test (Monte Carlo), OR Odds Ratio (95% Confidence interval) * p < 0.05 considered as significant*			

Discussion

In this study, we found the mini-open technique effective in pediatric distal radius fracture with a lower complication rate than percutanous application. Besides this, we also confirm that stabilization with K-wires are effective to prevent re-displacement in the displaced distal radius fracture of children.

In a systematic review, the mean re-displacement rate was reported 40% in the casting group and 3.6% in the pinning group [11]. K-wire fixation of displaced distal radius fractures in children reduced their predicted failure rate from 14–60% was reported by Choi et al. [10]. Leemput et al was reported a high rate of displacement (45.8%) after reduction and cast immobilisation and no redisplacement after reduction and pinning [5]. In a prospective study, Miller et al. reported 39% of patients treated with casting had re-displacement, contrarily none of the patients treated with pin fixation in pediatric patients with distal metaphyseal fractures [14]. As it can be understood from the results, K-wire fixation is recommended by some surgeons for preventing re-displacement [9, 10]. In this study, our re-displacement rates were 10% in K-wire fixation percutaneously and 4% in K-wire with mini-open group respectively and it was significantly lower in mini-open group.

Although the advantages of K-wires are known, there are some complications related to K-wires which were reported in literatures [11, 12]. In some studies, pining complication rates were varying from 0–38% (median 8.3%) [5]. The complications were loss of reduction, prominent scar, infection, pin migration, tendon irritation, transient neuropraxia, failed insertion, subcutaneous K-wires [12, 22, 23]. The reported complications were all classed as minör nevertheless there are technical challenges in the pining of these

fractures such as the presence of the physis, the small size of the bone, and the required obliquity of the wire [13].

McLauchlan et al. stated 2.8% pain, 5.7% prominent scar, and 2,8% pin migration after percutaneous K-wire stabilization in their study population [24]. In another study, Miller et al. reported K-wire complications included pin migration 12.5%, pin-site infection 12.5%, transient neuropraxia of radial nerve 6.2%, and tendon irritation 6.2% after treatment with percutaneous pin fixation [25]. Finally, in the report of Colaris et al, complications were subcutaneous K-wires 11,4%, re-fractures 4,9%, superficial infections 3.2%, transient neuropraxia 1.6%, failed insertion K- wires 1.6% in the treatment of 61 patients by K-wire stabilization [22].

In this study, we emphasize using mini-incision in the course of applying K-wire to limit the technical problems and to avoid the complications which could be irritative for the pediatric population. We found significantly lower pin-track infection, subcutaneous wire rates in K-wire fixation using by mini incision group. And also, we didn't observe potentially serious complications such as neuropraxia, tendon irritation and failed insertion of K-wires, angulation, and pull out of wire.

The function is important because it can affect the quality of children. While it was reported no significant difference between percutaneous pinning and casting concerning for to the range of motion in some literature [2]. Loss of pronation was reported higher in the casting group by Ozcan et al. [26]. Also, in the other study, Colaris et al. reported less limitation in pronation and supination in the percutaneous pinning group [22]. In our study, we observed good functional results in both groups after 18 months follow-up period.

The use of fluoroscopy in closed fixation methods increases the exposure to radiation with its associated risks; therefore, modifying the treatment method when possible has been recommended to minimize exposure [27–29].

Some limitations of the present study need to be addressed. First of all, our study's the retrospective design and the relatively low number of patients. Secondly, we could not arrange homogenous gender distribution because of our study design, last but not at least, our data collection is not enough to give angulation data at the patients' at 18th month follow-up visit. Besides limitations, strengths of this study include that patient examination was performed by observers different from the orthopaedic surgeon, surgical procedure was made by the same senior surgeon.

Conclusions

A comparison of percutaneous K-wire fixation and K-wire fixation with mini-open technique in similar pediatric patient groups showed similar functional results. The mini-open incision technique had lower complication rates and fluoroscopy durations. Based on the results of this study, K-wire fixation with mini-open technique can be recommended as an alternative method for pediatric distal radius fractures.

Declarations

Ethics approval and consent to participate: This study was performed in line with the principles of the Declaration of Helsinki. Approval was granted by Ethics Commite of Prof. Dr. Cemil TASCIOGLU City Hospital, Istanbul, Turkey,(protocol number 48670771-514.10).

Consent for publication: Written informed consent was obtained from the parents.

Availability of data and materials: Not applicable.

Competing interests: The authors declare that they have no competing interests.

Funding: No benefits in any form have been received or will be received from a commercial party related directly or indirectly to the subject of this article.

Authors' contributions: All authors contributed to the study conception and design. All authors read and approved the final manuscript.

Acknowledgements: None

References

1. Cheng JC, Shen WY. Limb fracture pattern in different pediatric age groups: a study of 3350 children. J Orthop Trauma. 1993;7(1):15–22.
2. Wendling-Keim DS, Wieser B, Dietz H-G. Closed reduction and immobilization of displaced distal radial fractures. Method of choice for the treatment of children? Eur J Trauma Emerg Surg Of Publ Eur Trauma Soc. 1993;41(4):421–428
3. Waters PM, Mih AD Fractures of the distal radius and ulna. In: Beaty JH, Kasser JR (eds) Rockwood and Wilkins' fractures in children, 6th eds. Lippincott Williams & Wilkins, Philadelphia; 2006. p. 337–398
4. Mazini JP, Martin JR. Paediatric forearm and distal radius fractures: risk factors and redisplacement-role of casting indices. Int. Orthop. 2010; 34(3): 407-412.
5. Leemput WV, Ridder KD. Distal metaphyseal radius fractures in children: reduction with or without pinning. Acta Orthop. Belg. 2009;75: 306-309
6. Schneider J, Staubli G, Kubat S, et al. Treating Displaced Distal Forearm Fractures in Children. European Journal of Trauma and Emergency Surgery. 2007;33: 619-625.
7. Alemdaroğlu KB, Iltar S, Cimen O, Uysal M, Alagöz E, Atlihan D. Risk factors in redisplacement of distal radial fractures in children. J Bone Joint Surg Am. 2008; 90(6):1224–1230
8. Sankar WN, Beck NA, Brewer JM, Baldwin KD, Pretell JA. Isolated distal radial metaphyseal fractures with an intact ulna: risk factors for loss of reduction. J Child Orthop. 2011; 5(6):459–464

9. Zamzam MM, Khoshhal KI. Displaced fracture of the distal radius in children: factors responsible for re-displacement after closed reduction. J Bone Joint Surg. 2005; 87(6):841-843.
10. Choi KY, Chan WS, Lam TP, Cheng JC. Percutaneous Kirschner-wire pinning for severely displaced distal radial fractures in children. A report of 157 cases. J Bone Jt Surg Br. 1995; 77(5):797–801.
11. Zeng Z, Liang W, Sun Y, et al. Is percutaneous pinning needed for treatment of displaced distal radius metaphyseal fractures in children? A systematic review. Medicine (Baltimore). 2018; 97 (36): e12142
12. Khandekar S, Tolessa E, Jones S. Displaced distal end radius fractures in children treated with Kirschner wires- A systematic review. Acta Orthop. Belg. 2016; 82:681-689
13. Luscombe KL, Chaudhry S, Dwyer SMJ, et al. Selective Kirschner wiring for displaced distal radial fractures in children. Acta Orthop Traumatol Turc. 2010; 44(2):117-123.
14. Parikh SN, Jain VV, Youngquist J. Intrafocal pinning for distal radius metaphyseal fractures in children. Orthopedics. 2013;36(6):783-8.
15. Miller BS, Taylor B, Widmann RF, Bae DS, Snyder BD, Waters PM. Cast immobilization versus percutaneous pin fixation of displaced distal radius fractures in children: a prospective, randomized study. J Pediatr Orthop. 2005;25: 490-4.
16. Haug EC, Novicoff WM, Cui Q. Corrections in alpha angle following two different operative approaches for CAM-type femoral acetabular impingement - Ganz surgical hip dislocation *vs* anterior mini-open. World J Orthop. 2020;11(1):27-35.
17. Munegato D, Gridavilla G, Guerrasio S, et al. Mini open versus open repair techniques in Achilles tendon rupture: clinical and isokinetic evaluation. Muscles Ligaments TendonsJ.2018;7(3):554-561. doi:10.11138/mltj/2017.7.3.554.
18. Huang R, Wang S, Wang Y, Qin X, Sun Y. Systematic Review of All-Arthroscopic Versus Mini-Open Repair of Rotator Cuff Tears: A Meta-Analysis. Sci Rep. 2016; 6:22857. doi:10.1038/srep22857.
19. Alemdaroglu KB, Iltar S, Cimen O et al. Risk factors in redisplacement of distal radial fractures in children. J Bone Joint Surg Am. 2008;90:1224-1230.
20. Tageldin ME, Alrashid M, Khoriati A, Gadikoppula S, Atkinson HD. Periosteal nerve blocks for distal radius and ulna fracture manipulation-the technique and early results. J Orthop Surg Res 2015;10: 134.
21. Huang W, Zhang X, Zhu H, Wang X, Sun J, Shao X. A percutaneous reduction technique for irreducible and difficult variant of paediatric distal radius and ulna fractures. Injury. 2016; 47: 1229-35.
22. Colaris JW, Allema JH, Biter LU, et al. Re-displacement of stable distal stable both-bone forearm fractures in children: a randomised controlled multicentre trial. Injury. 2013; 44:498-503.
23. Van Egmond PW, Schipper IB, Van Luijt PA. Displaced distal forearm fractures in children with an indication for reduction under general anesthesia should be percutaneously fixated. Eur J Orthop Surg Traumatol. 2012;22 : 201-7.

24. McLauchlan GJ, Cowan B, Annan IH, et al. Management of completely displaced metaphyseal fractures of the distal radius in children. A prospective, randomised controlled trial. J Bone Joint Surg Br. 2002; 84:413-7.
25. Miller BS, Taylor B, Widmann RF, et al. Cast immobilization versus percutaneous pin fixation of displaced distal radius fractures in children: a prospective, randomized study. J Pediatr Orthop. 2005;25: 490-4.
26. Ozcan M, Memisoglu S, Copuroglu C, et al. Percutaneous Kirschner wire fixation in distal radius metaphyseal fractures in children: does it change the overall outcome? Hippokratia. 2010;14: 265-70.
27. Madan S, Blakeway C. Radiation exposure to surgeon and patient in intramedullary nailing of the lower limb. Injury. 2002;33: 723-7.
28. Kraus R, Joeris A, Castellani C, Weinberg A, Slongo T, Schnettler R. Intraoperative radiation exposure in displaced supracondylar humeral fractures: A comparison of surgical methods. J Pediatr Orthop B 2007;16: 44-7.
29. Mastrangelo G, Fedeli U, Fadda E, Giovanazzi A, Scoizzato L, Saia B. Increased cancer risk among surgeons in an orthopaedic hospital. Occup Med (Lond). 2005; 55: 498-500.

Figures

Figure 1

Preoperative anterior–posterior (AP) and lateral (L) wrist radiographs of 10-year-old male patient treated with the K-wire pinning using the mini-open technique.

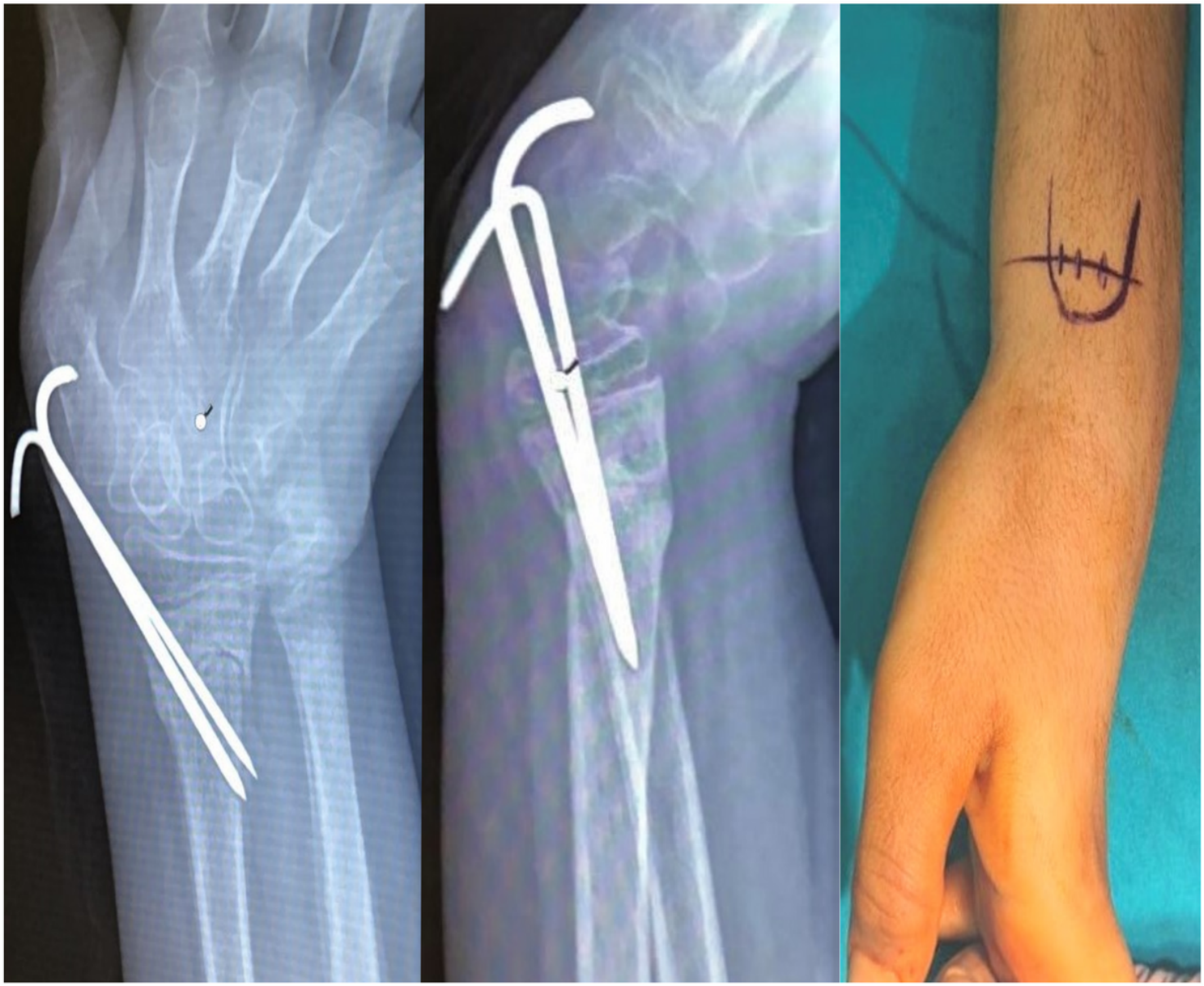

Figure 2

Image of intraoperative marking of the transverse mini incision. Early postoperative AP and L radiographs

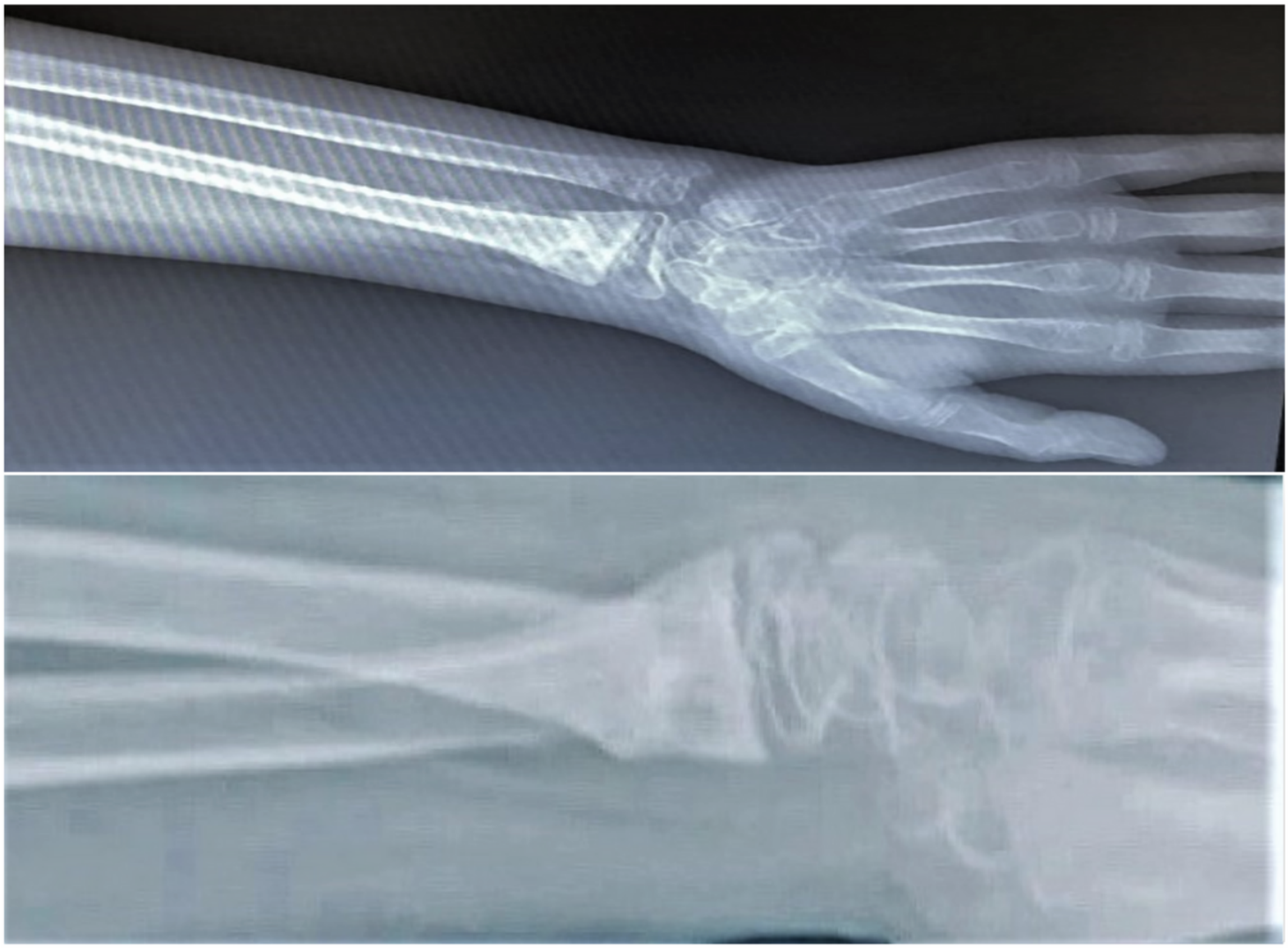

Figure 3

AP and L radiographs at 18th month.

Figure 4

Functional outcome at 6th week follow-up