Brain Stem Infarction With Pulmonary Embolism: A Case Report

HuiHua Hu (821561876@qq.com)
Hubei University of Medicine https://orcid.org/0000-0003-2521-8113

XiaoCong Wang
Hubei University of Medicine

Research Article

Keywords: Brain stem infarction, pulmonary embolism, Interventional thrombectomy, anticoagulation

Posted Date: July 9th, 2021

DOI: https://doi.org/10.21203/rs.3.rs-663504/v1

Abstract

Background: Brain stem infarction and pulmonary embolism are both serious life-threatening diseases with extremely high mortality. Central respiratory failure caused bycerebral stem infarction was considered in the initial stage of the disease. Pulmonary embolism (trunk) may have been the second cause of respiratory failure during diagnosis and treatment. The patient improved obviously after active treatment. Although the patient's condition improved significantly after active treatment, it is worth reflecting that if we had detected the right main pulmonary embolism in a timely manner during the first CTA examination, we could have determined whether the patient could benefit more from thrombolysis of the right main pulmonary artery under interventional therapy. Therefore, in clinical work, we should consider the possible complications ofthe patient while focusing on the most life-threatening primary disease.

Case presentation: The patient, a 53-year-old female, she was immediately transferred from the emergency department to the ICU. Physical examination: T 37°C, HR 109/min, R 10/min, BP 105/73 mmHg, SpO 2 79%, GCS score 5, E1V2M2, coma. T CTA examination of the cervical blood vessels and cerebral blood vessels was recommended. 2) CTA examination of the cervical blood vessels and craniocerebral blood vessels performed at 10 o'clock on March 23 suggested moderate and severe stenosis at the beginning of the right vertebral artery, severe stenosis at the middle and upper segments of the basilar artery, and severe stenosis at the beginning of the bilateral posterior cerebral artery. Consideration: high possibility of brainstem infarction. After discussion with the family members, they agreed to submit the patient to percutaneous craniography and thrombectomy. 3) Cerebral artery extraction was performed from 23:50 on March 23 to 01:20 on March 24. Intraoperative diagnosis: 1. Cerebral stem infarction. 2. Upper basilar artery occlusion. Postoperative angiography showed that the basilar artery was unobstructed, and the bilateral superior cerebellar artery and posterior cerebral artery had returned to normal. Tirofiban was given 4 ml/h postoperatively. 4) The CT diagnosis room on March 24 reported the results of the vascular CTA scan from 10 'clock on March 23: A filling defect of the right main pulmonary artery and the left lower pulmonary artery lumen was observed. Pulmonary embolism was considered. Color Doppler ultrasound examination of the heart and lower limb vessels was immediately performed, and the interventional department was consulted. Cardiac ultrasonography suggested that there was no obvious thrombus in the right atrium or right ventricle of the patient. she receive anticoagulant and antiplatelet therapy.

Conclusions: Central respiratory failure caused bycerebral stem infarction was considered in the initial stage of the disease. Pulmonary embolism (trunk) may have been the second cause of respiratory failure during diagnosis and treatment. The patient improved obviously after active treatment. Although the patient's condition improved significantly after active treatment, it is worth reflecting that if we had detected the right main pulmonary embolism in a timely manner during the first CTA examination, we could have determined whether the patient could benefit more from thrombolysis of the right main pulmonary artery under interventional therapy. Therefore, in clinical work, we should consider the possible complications ofthe patient while focusing on the most life-threatening primary disease.

Background

Brain stem infarction refers to the vertebrobasilar artery and its branches. It is caused by arteriosclerosis, embolism, spasm, inflammation leading to arterial stenosis or occlusion, and it results in ischemia of the middle brain, pons, and medulla and the corresponding neurological symptoms and signs. In severe cases, the disease is often life-threatening. Pulmonary embolism (PE)is a clinicopathological syndrome caused by the pulmonary artery, and its branches are blocked by various emboli. The most common pulmonary emboli are thromboemboli [1]. Recently, the intensive care department of our hospital successfully diagnosed and treated a case of cerebral stem infarction complicated with pulmonary embolism. The report is as follows:

The patient, a 53-year-old female, was admitted to the hospital for "vertigo with nausea for 2 hours" at 6:20 on March 23, 2019. The patient had sudden right tinnitus when using the toilet at home, with dizziness and nausea [1] and no headache, convulsions, vomiting, chest tightness, or palpitations. The patient's family members immediately sent the patient to the hospital. During the hospitalization, the patient had a large amount of gastric content in the oral horn, and blood oxygen saturation could not be maintained. Therefore, she was immediately transferred from the emergency department to the ICU. Physical examination: T 37°C, HR 109/min, R 10/min, BP 105/73 mmHg, SpO 2 79%, GCS score 5, E1V2M2, coma. The pupils on both sides were equally large and round with a diameter of approximately 2 mm, slow to reflect light. Bilateral breath sounds were slightly coarse, no obvious dry or wet rales were detected. Rhythm of the heart: no obvious pathological murmur was detected. The limbs were inactive, and no pathological signs were elicited. Auxiliary examination: Blood routine and liver and kidney function were within normal ranges. Troponin 0.017 ng/mL and D-dimer 2967 ng/mL. No obvious abnormality was found on brain CT. Past medical history: She underwent femoral hernia surgery at a local institute 3 days prior and denied a medical history of hypertension or diabetes. Treatment: 1) tracheal intubation connected with a ventilator for assisted breathing. We consulted a neurologist, who considered the possibility of cerebral infarction. CTA examination of the cervical blood vessels and cerebral blood vessels was recommended. 2) CTA examination of the cervical blood vessels and craniocerebral blood vessels performed at 10 o'clock on March 23 suggested moderate and severe stenosis at the beginning of the right vertebral artery, severe stenosis at the middle and upper segments of the basilar artery, and severe stenosis at the beginning of the bilateral posterior cerebral artery. Consideration: high possibility of brainstem infarction. After discussion with the family members, they agreed to submit the patient to percutaneous craniography and thrombectomy. 3) Cerebral artery extraction was performed from 23:50 on March 23 to 01:20 on March 24. Intraoperative diagnosis: 1. Cerebral stem infarction. 2. Upper basilar artery occlusion. Postoperative angiography showed that the basilar artery was unobstructed, and the bilateral superior cerebellar artery and posterior cerebral artery had returned to normal. Tirofiban was given 4 ml/h postoperatively. 4) The CT diagnosis room on March 24 reported the results of the vascular CTA scan from 10 'clock on March 23: A filling defect of the right main pulmonary artery and the left lower pulmonary artery lumen was observed. Pulmonary embolism was considered. Color Doppler ultrasound examination of the heart and lower limb vessels was immediately performed, and the interventional department was consulted. Cardiac ultrasonography

suggested that there was no obvious thrombus in the right atrium or right ventricle of the patient. A small regurgitation peak was observed in the tricuspid valve, with a pressure difference of 2.8 m/s and a pressure difference of 32 mmHg. Mild pulmonary hypertension was considered. The general femoral, deep femoral, shallow femoral, popliteal, posterior tibial, peroneal and intermuscular veins of both lower limbs were working normally. An irregular solid hypoechoic mass was observed in the lumen of the posterior tibial vein and intermuscular vein of both lower limbs, and the lumen extrusion did not disappear. Venous thrombosis of both lower limbs was considered. The opinion of interventional department: if the patient's family was willing to further clarify the scope and size of the thrombus by pulmonary arteriography, local thrombolysis and balloon dilatation should be performed if necessary. 5) We repeatedly discussed the patient's condition with the family members. The patient's heart rate was 70-90/min, blood pressure was 100-120/70 mmHg, and ventilator-assisted breathing was performed. There was no obvious circulatory instability. The filling defect of the right main pulmonary artery and the left lower pulmonary artery lumen was observed. The family members decided to receive anticoagulant and antiplatelet therapy, including tirofiban 0.1 μg/kg·min and aspirin 0.1 g+ clopidogrel 75 mg within 24 hours. After 24 hours, 4100 U of LMWH was given subcutaneously Q12+ clopidogrel 75 mg treatment. CT and CTA examination of the brain, lung and pulmonary artery on March 25 showed left cerebellum lesions and low-density lesions of the brainstem. Infarction was considered. Filling defects were found in the upper right and lower left pulmonary artery, and no change in stratified contrast agent shunt was found. The interventional department, respiratory medicine department and cardiothoracic surgery department were consulted once again. The re-examination of pulmonary artery CTA showed the opening of the main right pulmonary artery, indicating effective anticoagulation. Continuation of anticoagulation therapy was recommended. On March 30, the patient underwent tracheotomy, after which the ventilator was removed and oxygen was inhaled at the tracheotomy site. On April 1, the patient was conscious, the GCS score was 10, bilateral pupil size and roundness were equal, light reflex was present, eye movement was free, the left limb grade was 0, and the left para-type syndrome was positive. The patient was then referred to neurology.

Discussion

Interventional thrombectomy is the key to achieving reperfusion of a cerebral infarction and improving the prognosis of patients. Multiple large reports have suggested that interventional thrombectomy of posterior circulation infarction within 24 hours is beneficial [2, 3]. It took approximately 20 hours from the onset of the current case to interventional thrombectomy.

Reexamination of angiography and CT showed that thrombectomy was effective. The patient’s GCS score was good. Thrombosis causing pulmonary embolism is most often deep vein thrombosis [4]. Color Doppler ultrasound of the lower limbs of the patient indicated thrombosis, so the pulmonary embolism of the patient originated from both lower limbs. The patient had a right main pulmonary embolism and was briefly removed from the ventilator, and her blood oxygen saturation decreased significantly. According to the guidelines, active thrombolytic treatment should have been considered[5]. However, cerebral artery thrombolysis of the patient with cerebral infarction had just been performed, and the department of

neurology did not recommend that the patient have another systemic thrombolysis within 24 hours. The local thrombolysis effect of right pulmonary artery embolization in the interventional department was not good, and balloon dilation was not available. The patient finally chose anticoagulant treatment, and based on the treatment effect, this benefitted the patient. Cerebral stem infarction combined with pulmonary embolism is very rare. According to most reports in the literature, cerebral infarction and pulmonary embolism after long-term bed rest are relatively common [6]. After the patient was admitted to the hospital, she showed circulatory cerebral infarction, and respiratory failure was the most serious manifestation. Central respiratory failure caused bycerebral stem infarction was considered in the initial stage of the disease. Pulmonary embolism (trunk) may have been the second cause of respiratory failure during diagnosis and treatment. The patient improved obviously after active treatment. Although the patient's condition improved significantly after active treatment, it is worth reflecting that if we had detected the right main pulmonary embolism in a timely manner during the first CTA examination, we could have determined whether the patient could benefit more from thrombolysis of the right main pulmonary artery under interventional therapy. Therefore, in clinical work, we should consider the possible complications ofthe patient while focusing on the most life-threatening primary disease.

Declarations

Conclusions: Not applicable.

Ethics approval and consent to participate: We confirm that the manuscript has been read and approved by all named authors and that there are no other persons who satisfied the criteria for authorship but are not listed. We fuither confirm that the order of authors listed in the manuscript has been approved by all of us. Not applicable

Consent for publication: We confirm that we have given due consideration to the protection of intellectual property associated with this work and that there are no impediments to publication, including the timing of publication, with respect to intellectual property. In so doing we confirm that we have followed the regulations of our institutions concerning intellectual property. Not applicable.

Availability of data and materials: The datasets used or analysed during the current study are available from the corresponding author on reasonable request.

Competing interests: The authors declare no competing non-financial/financial interests.

Funding: Not applicable.

Authors' contributions: Xiaocong Wang contributed significantly to analysis and manuscript preparation;Huihua Hu contributed to the conception of the study.

Acknowledgements: I would like to express my gratitude to all those who helped me during the writing of this thesis. I would like to express my heartfelt gratitude to professor Xiaocong Wang, who led me into the world of translation.And she contributed significantly to analysis and manuscript preparation;last my

thanks would go to my beloved family for their loving considerations and great confidence in me all through these years. i also owe my sincere gratitude to my friends and my fellow classmates who gave me their help and time in listening to me and helping me work out my problems during the difficult course of the thesis.

References

[1] Stein, P. D. and Matta, F. (2010). Acute pulmonary embolism. Current Problems in Cardiology 35, 314–376.

[2] Nogueira, R. G., Jadhav, A. P., Haussen, D. C., Bonafe, A., Budzik, R. F., Bhuva, P., Yavagal, D. R., Ribo, M.,Cognard, C., Hanel, R. A., Sila, C. A., Hassan, A. E., Millan, M., Levy, E. I., Mitchell, P., Chen, M., English,J. D., Shah, Q. A., Silver, F. L., Pereira, V. M., Mehta, B. P., Baxter, B. W., Abraham, M. G., Cardona, P.,Veznedaroglu, E., Hellinger, F. R., Feng, L., Kirmani, J. F., Lopes, D. K., Jankowitz, B. T., Frankel, M. R.,Costalat, V., Vora, N. A., Yoo, A. J., Malik, A. M., Furlan, A. J., Rubiera, M., Aghaebrahim, A., Olivot, J. M.,Tekle, W. G., Shields, R., Graves, T., Lewis, R. J., Smith, W. S., Liebeskind, D. S., Saver, J. L. and Jovin, T.G. (2018). Thrombectomy 6 to 24 hours after stroke with a mismatch between deficit and infarct. The New England Journal of Medicine 378, 11–21.

[3] Berkhemer, O. A., Fransen, P. S., Beumer, D., van den Berg, L. A., Lingsma, H. F., Yoo, A. J., Schonewille,W. J., Vos, J. A., Nederkoorn, P. J., Wermer, M. J., van Walderveen, M. A., Staals, J., Hofmeijer, J., van Oostayen, J. A., Lycklama à Nijeholt, G. J., Boiten, J., Brouwer, P. A., Emmer, B. J., de Bruijn, S. F., van Dijk, L. C., Kappelle, L. J., Lo, R. H., van Dijk, E. J., de Vries, J., de Kort, P. L., van Rooij, W. J., van den Berg, J. S., van Hasselt, B. A., Aerden, L. A., Dallinga, R. J., Visser, M. C., Bot, J. C., Vroomen, P. C.,Eshghi, O., Schreuder, T. H., Heijboer, R. J., Keizer, K., Tielbeek, A. V., den Hertog, H. M., Gerrits, D. G.,van den Berg-Vos, R. M., Karas, G. B., Steyerberg, E. W., Flach, H. Z., Marquering, H. A., Sprengers, M. E.,Jenniskens, S. F., Beenen, L. F., van den Berg, R., Koudstaal, P. J., van Zwam, W. H., Roos, Y. B., van der Lugt, A., van Oostenbrugge, R. J., Majoie, C. B. and Dippel, D. W. (2015). A randomized trial of intraarterial

treatment for acute ischemic stroke. The New England Journal of Medicine 372, 11–20.

[4] Tapson, V. F. (2013). Thrombolytic therapy for acute pulmonary embolism. Seminars in Thrombosis and Hemostasis 39, 452–458.

[5] Kearon, C., Akl, E. A., Ornelas, J., Blaivas, A., Jimenez, D., Bounameaux, H., Huisman, M., King, C. S.,Morris, T. A., Sood, N., Stevens, S. M., Vintch, J. R. E., Wells, P., Woller, S. C. and Moores, L. (2016).Antithrombotic therapy for VTE disease: CHEST guideline and expert panel report. Chest 149, 315–352.

[6] Powers, W. J., Derdeyn, C. P., Biller, J., Coffey, C. S., Hoh, B. L., Jauch, E. C., Johnston, K. C., Johnston, S.C., Khalessi, A. A., Kidwell, C. S., Meschia, J. F., Ovbiagele, B. and Yavagal, D. R. (2015). 2015 American Heart Association/American Stroke Association focused update of the 2013 guidelines for the early

management of patients with acute ischemic stroke regarding endovascular treatment. Stroke 46, 3024–3039.

Figures

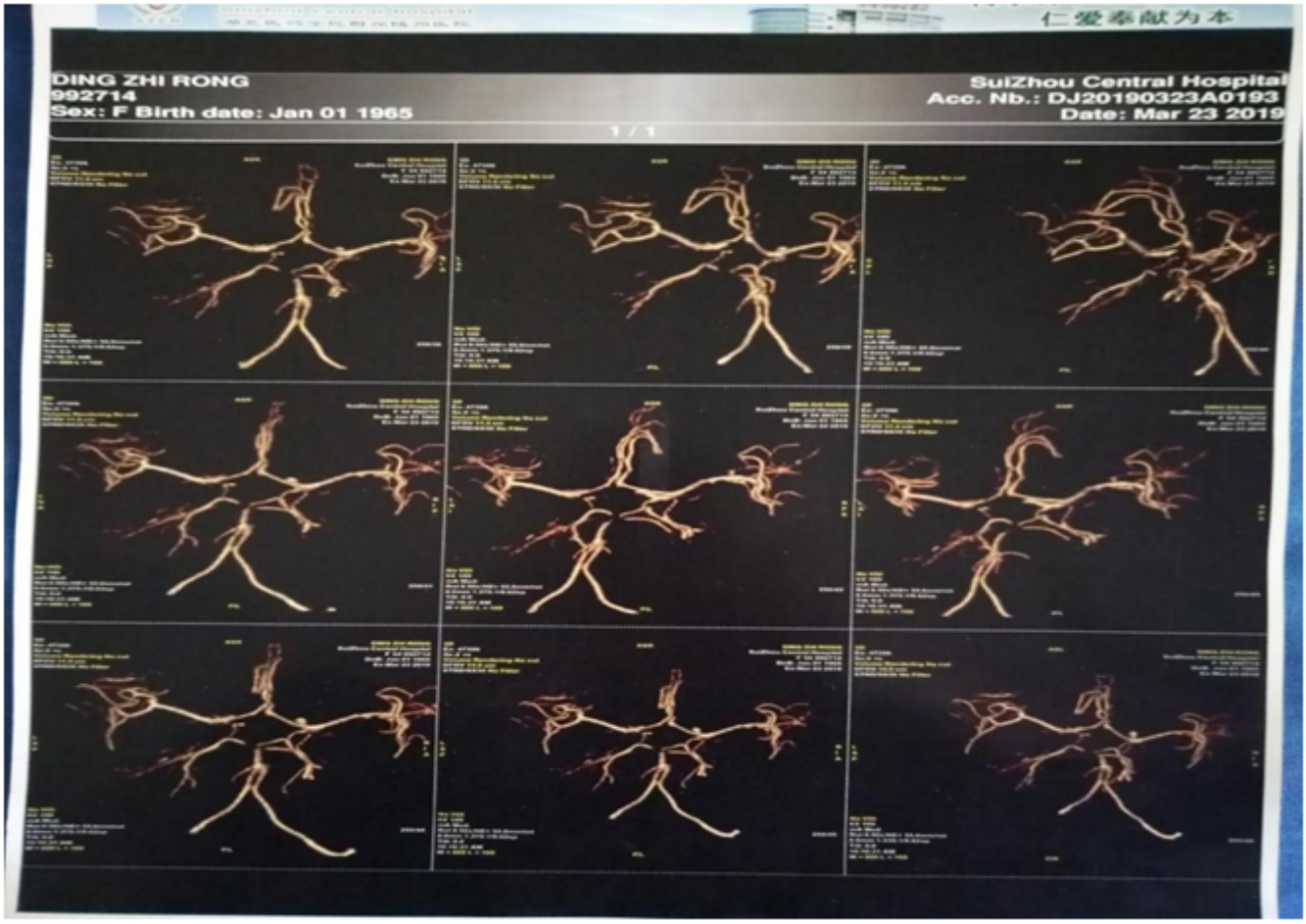

Figure 1

Cervical blood vessels and cerebral blood CTA on March 23.

Figure 2

Vertebral arteriography before thrombectomy.

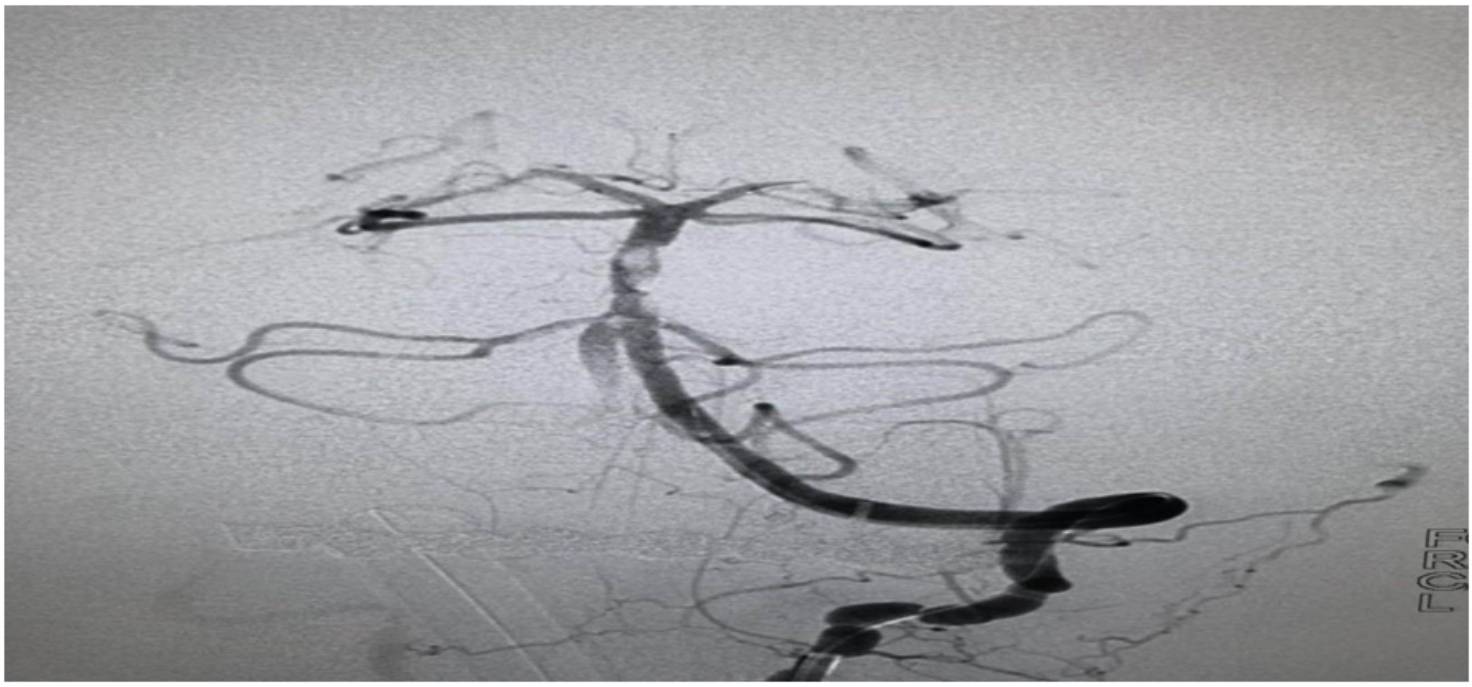

Figure 3

Vertebral artery angiography for thrombectomy.

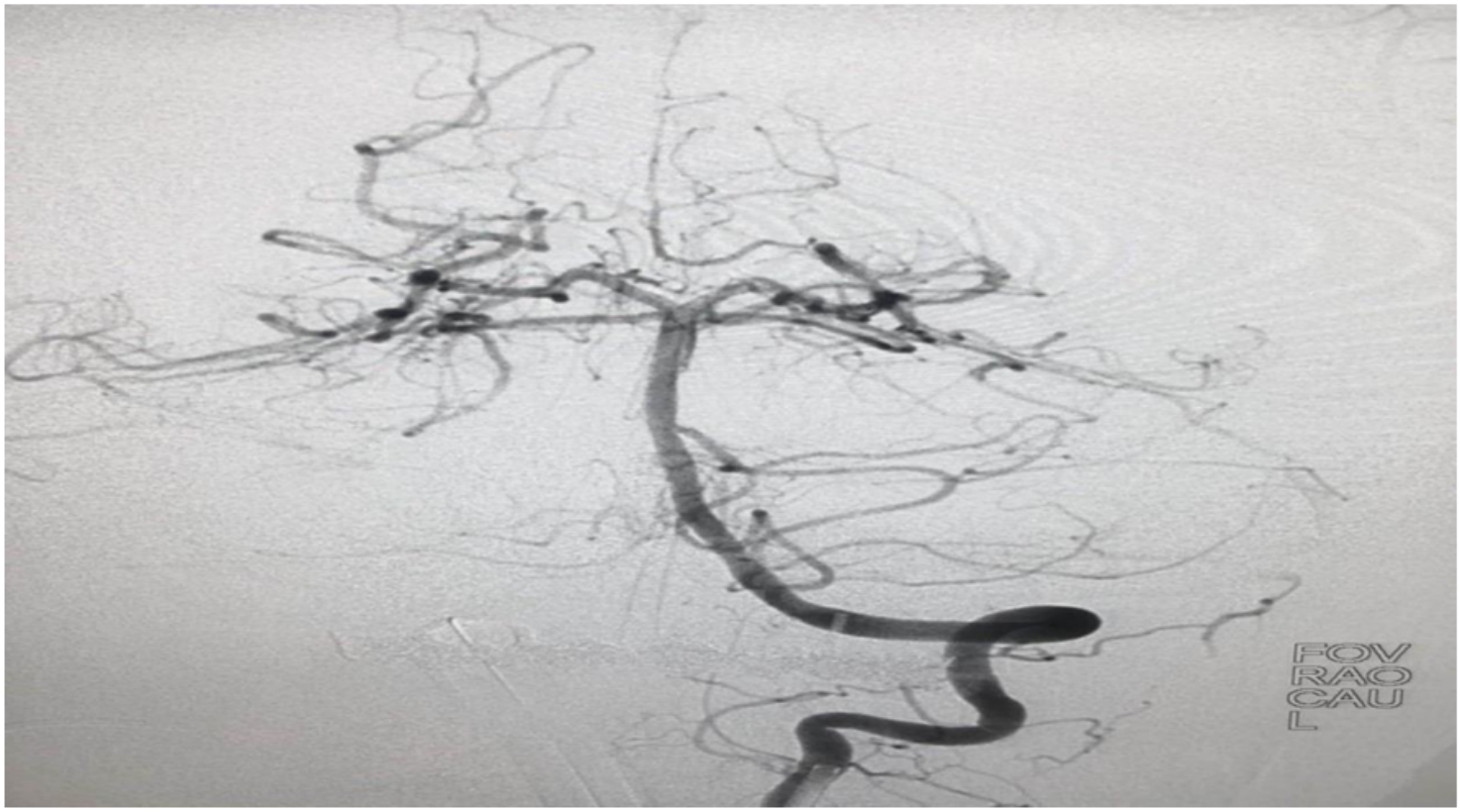

Figure 4

Vertebral arteriography after thrombectomy.

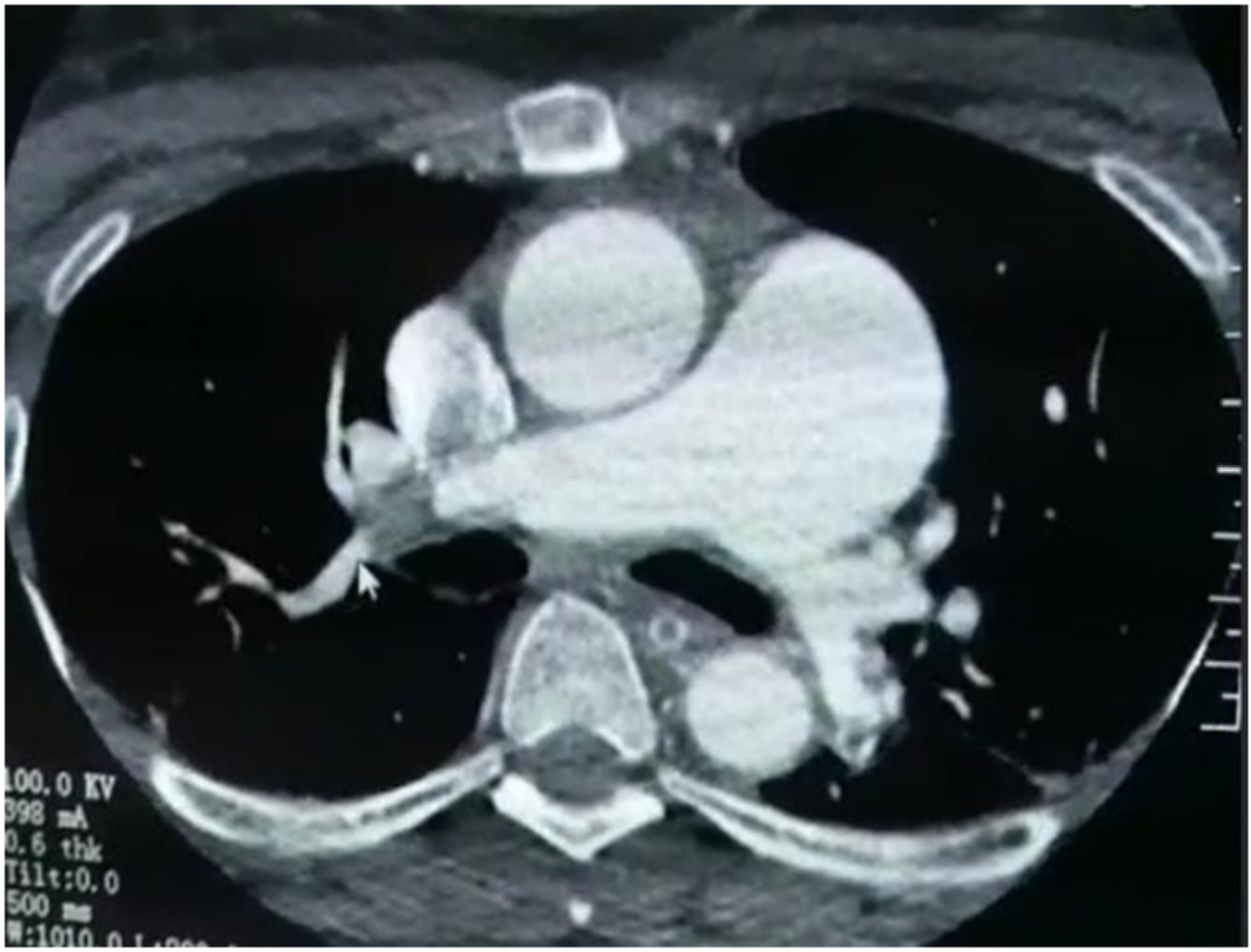

Figure 5

Right main pulmonary embolism of CTA on March 23.

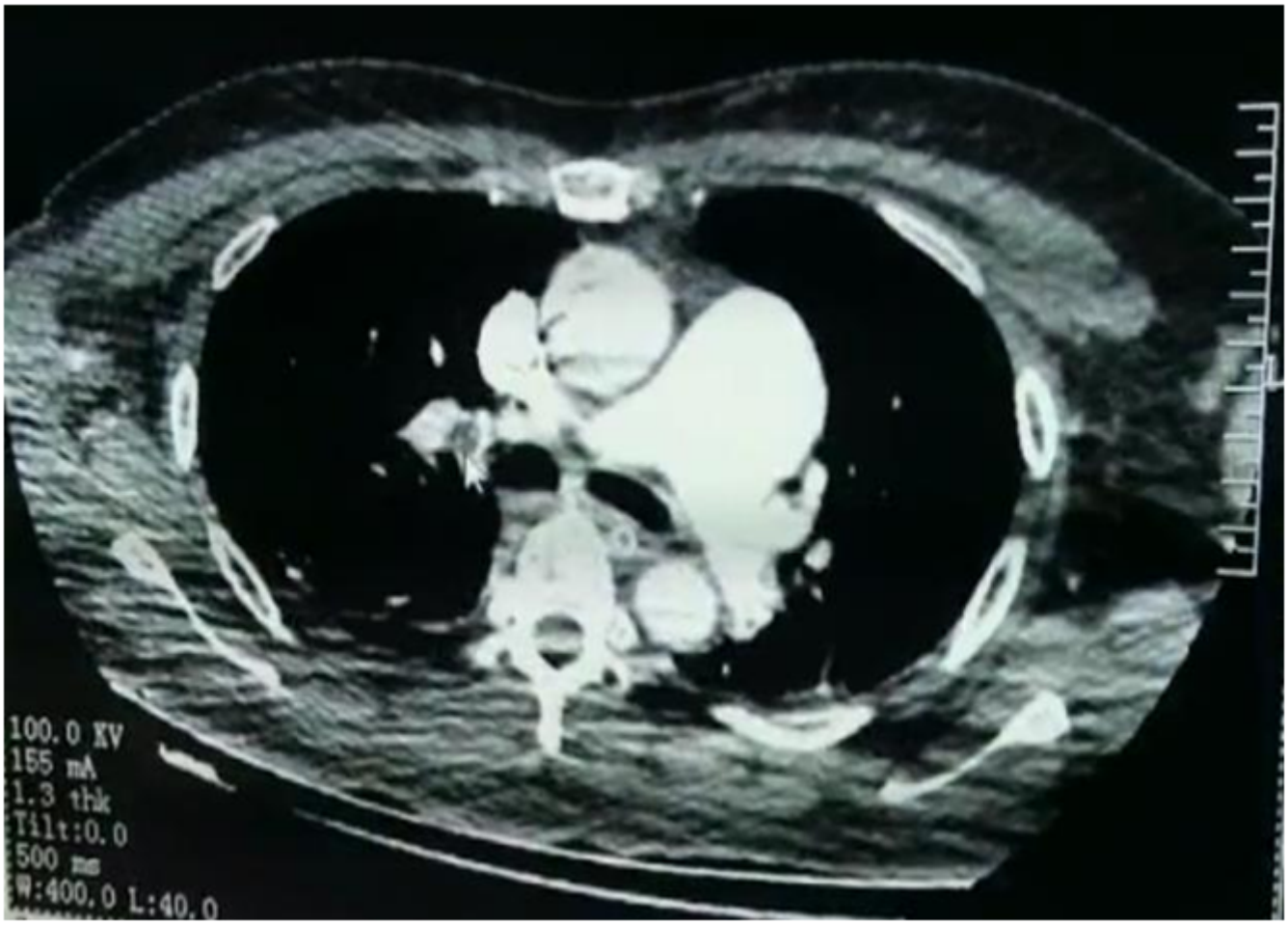

Figure 6

The main pulmonary artery was opened in the CTA review on