A new arthroscopic repair technique for triangular fibrocartilage complex using an intracapsular suture: an outside-in transfer, all-inside repair

Jiasong Zhao
Chengdu University of Traditional Chinese Medicine Affiliated Hospital
Min Gong
Chengdu University of Traditional Chinese Medicine Affiliated Hospital
Dingsu Bao
The Affiliated Hospital of Southwest Medical University
Yanming Lin
Chengdu University of Traditional Chinese Medicine Affiliated Hospital
Heng Qiu
Chengdu University of Traditional Chinese Medicine Affiliated Hospital
Lang Li
Hospital of Chengdu Office of People's Government of Tibetan Autonomous Region
Yong Huang (huangyongcdutcm@126.com)
Chengdu University of Traditional Chinese Medicine Affiliated Hospital

---

Research Article

Keywords: peripheral triangular fibrocartilage complex, all-inside, outside-in, arthroscopic repair

Posted Date: July 12th, 2021

DOI: https://doi.org/10.21203/rs.3.rs-678918/v1

Abstract

Background

Arthroscopic repair is a promising, minimally invasive surgical technique for patients with Palmer type 1B peripheral triangular fibrocartilage complex (TFCC) tears. Although several arthroscopic techniques are effective for repairing Palmer type 1B TFCC tears, some shortcomings remain; thus, better methods are necessary.

Methods

We performed an arthroscopic intracapsular suture using an outside-in transfer, all-inside repair technique, which is a modified method of the outside-in and all-inside technique using the needle of a 10-mL sterile syringe, for Palmer type 1B TFCC tears. A No. 2 polydioxanone suture was threaded through the needle and entered the wrist joint. Next, the needle was withdrawn carefully along the suture to the proximal tear ulnar surface of the TFCC and penetrated the TFCC, exiting the articular cavity surface of the ulnar side of the torn TFCC. Finally, arthroscopic knotting was performed.

Results

This new technique was used to treat 17 patients with Palmer type 1B Atzei class 1 TFCC tears. The treatment was as effective as the previously described arthroscopic techniques and had advantages of no additional incision and decreased risk of operation-related complications.

Conclusions

The outside-in transfer, all-inside repair is a simple, safe, minimally invasive, and economical procedure that confers a lower risk of complications for Palmer type 1B TFCC tears. We recommend this technique as a useful alternative to the conventional methods of repairing Palmer type 1B TFCC tears.

Introduction

The triangular fibrocartilage complex (TFCC) is the most important stabilizer of the distal radioulnar joint and act as a shock absorber across the ulno-carpal joint [1, 2]. The TFCC is composed of the fibrocartilaginous disk, the dorsal, and palmar ligaments spanning across the radius and ulna, the ulnocarpal ligaments, a meniscal homolog, and the subsheath of the ulnar extensor of the wrist, whose critical stable component inserts directly in the ulna, either deep into the fovea (ligamentum subcruentum) or at the base of the styloid [1]. Traumatic injury, including axial loading of an ulnar deviated wrist and the disruption of normal ulnar variance, to the TFCC is a frequent cause of ulnar-sided pain and wrist disability [3].

When movements of wrist rotation occur, TFCC injury usually leads to a patient complaint of activity-related ulnar-sided wrist pain, which may also be accompanied by grip weakness, instability, clicking at presentation, and weakness in pronation and supination [4]. Imaging examination, including radiography, Magnetic resonance imaging (MRI), and MRI with arthrography, is necessary to evaluate TFCC injury [5, 6]. The recent developments of MRI, including the high-resolution two-dimensional/three-dimensional sequences and 3-T field strength, may improve the detection of TFCC injuries that are difficult to evaluate on routine sequences [7]. Arthroscopy is the most accurate means by which to diagnose TFCC injury irrespective of location.

The Palmer classification system, the most widely used scheme, classifies TFCC injuries into type I (traumatic tear) and type II (degenerative tear) according to the location and chronicity of the tear [8]. Palmer type I B tears represent traumatic peripheral tears of the TFCC from its ulnar insertion and tend to be the most amenable to surgical repair when conservative treatment is ineffective [8]. A treatment-oriented classification system especially focusing on Palmer type 1B was proposed by Atzei, which subdivides Palmer type 1B peripheral tears into five types as follows: class 1l repairable distal tears; class 2, repairable complete tears; class 3, repairable proximal tears; class 4, non-repairable tears; and class 5, tears associated with distal radioulnar joint (DRUJ) arthritis [9]. Atzei advocated that class 1 tears should be sutured and that class 2 and 3 tears are associated with DRUJ instability and require TFCC reattachment to the fovea [9]. Class 1 tears were currently repaired using arthroscopy [10–14]. Arthroscopic TFCC foveal repair techniques for class 2 and 3 tears have already been introduced [9, 15–17]. However, some complications such as subcutaneous suture knotting and injury of the extensor carpi ulnaris tendon or sensory branch of the ulnar nerve still occur with the arthroscopic technique for the repair of Palmer type 1B TFCC tears. The goal of surgeons has always been to reduce the risk of surgery and complications by developing new methods that can increase TFCC tear healing and reduce complications.

Here, we report an arthroscopic repair technique for the treatment of Palmer type 1B Atzei class 1 TFCC tears. This technique could be used to suture the TFCC tissue without the capsule and subcutaneous tissue and could preserve the normal biomechanics of the meniscus during motion and reduce complications.

Methods

The patient was positioned for standard wrist arthroscopy using a standard traction apparatus. To probe and evaluate TFCC tears, the 3–4, 4R, and 6R portals were routinely performed. This new repair technique for subtype Palmer type 1B Atzei class 1 TFCC tears requires the needle of a 10-mL sterile syringe, an arthroscopic retriever, a knot pusher, and suture material. A 2.7-mm 30° arthroscope was used to the visualize TFCC tear via 3 or 4 portals, and the probe was inserted through the 6R portal to check and assess the tear parameter of the TFCC, including the site, size, pattern, stability, tissue quality, and associated pathology in the wrist joint. Before sewing, the tear site of the TFCC was debrided with a 2.9-mm full-radius motorized shaver until bleeding to remove the proliferative synovial tissue and encourage

healing through the 6R portal. Then, the outside-in transfer, all-inside repair technique was applied to repair the TFCC tear. First, on the skin near the tear ulnar site of the TFCC, the needle of a 10-mL sterile syringe penetrated the skin, subcutaneous tissue, articular capsule, and finally, the proximal tear radial surface of the TFCC, and then exited the articular cavity surface of the radial side of the torn TFCC (Fig. 1). Second, a No. 2 polydioxanone (PDS) suture was threaded through the needle of a 10-mL sterile syringe and inserted in the wrist joint. Then, the suture tip was retrieved through the 6R portal with a grasper (Fig. 2). Third, the needle was withdrawn carefully along the suture to the proximal tear on the ulnar surface of the TFCC, avoiding the suture while retreating the needle at the same time. After adjusting the needle puncture direction, the needle was reinserted upward and penetrated through the proximal tear of the ulnar surface of the TFCC, exiting the articular cavity surface of ulnar side of the torn TFCC. The procedure was carefully performed to avoid cutting the suture with the tip of needle. The suture end was folded in the tip of needle and pulled out with a grasper through the 6R portal. Here the outside-in repair technology was successfully converted to an all-inside knotting technology. Next, after confirming the tear site of the TFCC penetrated by both limbs of the suture, the suture was slowly tensioned to obtain fine reduction of the torn TFCC under arthroscopic visualization. Furthermore, the Samsung Medical Center sliding knot technique was used to form the knot, which was positioned on the synovial side to avoid articular cartilage erosion of the scaphoid and lunate bone during wrist motion. After the knot was performed, the tension was carefully checked with a probe via arthroscopic visualization. A second knot or more was also made in a similar way if it was necessary to acquire a stable TFCC repair. Finally, to assess the stability of the suture, the full range of repeated wrist motion must be finished.

Results

We have repaired 17 cases of Palmer type 1B Atzei class 1 TFCC tears with the outside-in transfer, all-inside technique since August in 2016. The mean age of the patients was 30.8 ± 7.8 year. Among of the patients, 15 were female. All the surgeries were performed in full range of motion and without loosening of the knots. At a mean follow-up period of 10 months, none of the patients had an infection, postoperative TFCC symptoms, joint-line tenderness, and a reoperation. All the patients were satisfied with the treatment outcome. One 31-year -old patient with Palmer type 1B TFCC tear was operated by this new intracapsular suture in Fig. 3.

Discussion

Palmer type 1B Atzei class 1 TFCC tears are stable because no radicular ligament injury is involved. This type of TFCC tears was managed firstly with conservative treatment using immobilization, including splints or casts [18]. However, some patients who do not respond to conservative treatment must convert to operation and can be treated with debridement and capsular sutures depending on arthroscopy. Palmer type 1B Atzei class 1 TFCC tears are most amenable to successful repair and healing because of abundant blood supply [3]. In this consecutive treatment series, a new technique of outside-in transfer, all-

inside repair was used to repair the torn TFCC. This repair technique showed constant and reliable clinical results in terms of pain relief and TFCC tear healing.

A new arthroscopic intracapsular suture repair technique called outside-in transfer, all-inside repair was used for Palmer type 1B Atzei class 1 TFCC tears in this study. This new method is a modification from the technique for meniscal tears by Wang in 2019 [19]. This repair technique using arthroscopy provides several advantages to other reported repair techniques. First, it is easy to accomplish because it first uses the outside-in technique and then transfer to using the needle of 10-mL sterile syringe, which is cheaper than other instruments. Second, its allows the use of a vertical mattress suture, which is useful for the alignment of the edge of TFCC tear and is easier to heal. Third, the suture knots of this outside-in transfer, all-inside technique can be performed without an additional skin incision and placed inside the joint instead of subcutaneously to avoid irritating the skin and injuring the dorsal branch of the ulnar nerve and extensor carpi ulnaris tendon.

Several suture techniques are available for Palmer type 1B Atzei class 1 TFCC tears. The currently used techniques of arthroscopic repair for class 1 tears include the inside-out, outside-in, or all-arthroscopic technique [10–14]. An outside-in technique using 2 needles guiding 2 sutures to repair the TFCC was first described by Zachee et al in 1993 [20]. Both Trumble et al. and Skie et al. advocated an inside-out technique for Palmer type 1B TFCC repair using 2 – 0 meniscal repair sutures [21, 22]. Although these techniques have been modified, they require an extra incision to tie the sutures subcutaneously, which confers a risk of injury to the extensor carpi ulnaris tendon or the sensory branch of the ulnar nerve. Furthermore, the suture knot lies subcutaneously, causing skin problems and even septic arthritis [23–26]. A study of an all-arthroscopic repair technique for TFCC with the outside-in technique in fresh-frozen cadaveric wrists showed that the PDS knot was 4.6 mm from the dorsal branch of the ulnar nerve, which may be injured by the knot, and injured an extensor carpi ulnaris tendon [23]. Another cadaver study showed that the mean minimum distance between the suture and the dorsal branch of the ulnar nerve was 1.9 mm in the inside-out technique [27]. In a previous study, Bayoumy reported that 37 patients with TFCC tears were treated with the arthroscopic outside-in repair technique, in which two patients showed complications, including dorsal ulnar nerve neurapraxia in one patient and weakness in extension of the little finger in the other patient [28]. The goal of surgeons has always been to reduce the risk of surgery and complications as much as possible by developing a new method that can increase TFCC tear healing and reduce complications. In our consecutive treatment series, none of the patients had complications such as skin problems, injury of the dorsal branch of the ulnar nerve, and injury of the extensor carpi ulnaris tendon.

As in knee arthroscopy, an all-inside technique should be fast and safe to use and avoid the disadvantages of the other techniques. A study by Conca et al in 2003 described an all-inside repair technique for Palmer type 1B TFCC tears using a small suture hook and three portals [29]. Böhringer et al. used a meniscus fastener fixation system to repair Palmer 1B TFCC tears [26]. A novel all-inside approach for Palmer type 1B TFCC tears with a spinal needle and no additional incision was introduced and described by Lee [13]. Kuremsky assessed the safety of an all-inside arthroscopic TFCC repair technique

in 13 above-the-elbow human cadaver specimens. The results of this study showed that the all-inside technique was safe in terms of proximity to important structures [30]. However, the technique had a significant drawback in that the intra-articular working space in the wrist was so narrow that the range of manipulation with the suture devices through the portal was restricted. Our technique is simpler than the other all-inside techniques, although one portal without special equipment is required.

A new arthroscopic intracapsular suture repair technique called outside-in transfer, all-inside repair was used for Palmer type 1B Atzei class 1 TFCC tears in this study. This new method is a modification of the technique for meniscal tears introduced by Wang in 2019 [19]. This repair technique using arthroscopy provides several advantages to other reported repair techniques. First, this technique is easy to accomplish because, first, it uses the outside-in technique and then transfer to using the needle of 10-mL sterile syringe, which is cheaper than other instruments. Second, it allows the use of a vertical mattress suture, which is useful for the alignment of the edge of the TFCC tear and faster tear healing. Third, the suture knots of this outside-in transfer, all-inside technique can be performed without an additional skin incision and placed inside the joint instead of subcutaneously to avoid irritating the skin and injuring the dorsal branch of the ulnar nerve and extensor carpi ulnaris tendon. Finally, this technique is easier to perform than other techniques.

In conclusion, our outside-in transfer, all-inside repair technique is suitable for Palmer type 1B Atzei class 1 TFCC tears, which is as simple as the previously described arthroscopic techniques. We believe that this technique could provide a good alternative for surgeons and recommend this technique as a useful alternative to other methods of repairing Palmer type 1B TFCC tears.

Abbreviations

TFCC: peripheral triangular fibrocartilage complex; MRI: Magnetic resonance imaging ; PDS polydioxanone ;

Declarations

Ethics approval and consent to participate

This study was approved by Hospital of Chengdu Office of People's Government of Tibetan. All participants gave their consent to participate.

Consent for publication

Obtained.

Availability of data and materials

The datasets used and analyzed during the current study are available from the corresponding author on reasonable request.

Competing interests

The authors declare that they have no competing interests.

Funding

there was no funding in this paper.

Authors' contributions

Jiasong Zhao: designed the research, analyzed the data, wrote, and checked the paper. Min Gong: collected the data, analyzed the data. Dingsu Bao: designed the research, analysed the data. Yanming Lin: designed the research. Heng Qiu: performed research, collected the data, analyzed the data. Lang Li: designed the research. Yong Huang: designed the research. The authors read and approved the final manuscript.

Acknowledgements

No

References

References:

1. Palmer AK, Werner FW. The triangular fibrocartilage complex of the wrist–anatomy and function. J Hand Surg Am. 1981;6(2):153–62. doi:10.1016/s0363-5023(81)80170-0. PubMed PMID: 7229292. Epub 1981/03/01.
2. Kirchberger MC, Unglaub F, Mühldorfer-Fodor M, Pillukat T, Hahn P, Müller LP, et al. Update TFCC: histology and pathology, classification, examination and diagnostics. Arch Orthop Trauma Surg. 2015;135(3):427–37. doi:10.1007/s00402-015-2153-6. PubMed PMID: 25575720. Epub 2015/01/13.
3. Jawed A, Ansari MT, Gupta V. TFCC injuries: How we treat? J Clin Orthop Trauma. 2020;11(4):570–9. doi:10.1016/j.jcot.2020.06.001. PubMed PMID: 32742122; PubMed Central PMCID: PMCPMC7384326. Epub 2020/08/04.
4. Andersson JK, Axelsson P, Strömberg J, Karlsson J, Fridén J. Patients with triangular fibrocartilage complex injuries and distal radioulnar joint instability have reduced rotational torque in the forearm. J Hand Surg Eur Vol. 2016;41(7):732–8. doi:10.1177/1753193415622342. PubMed PMID: 26701974. Epub 2015/12/25.
5. Oneson SR, Scales LM, Timins ME, Erickson SJ, Chamoy L. MR imaging interpretation of the Palmer classification of triangular fibrocartilage complex lesions. Radiographics. 1996;16(1):97–106. doi:10.1148/radiographics.16.1.97. PubMed PMID: 10946693. Epub 1996/01/01.
6. Haims AH, Schweitzer ME, Morrison WB, Deely D, Lange R, Osterman AL, et al. Limitations of MR imaging in the diagnosis of peripheral tears of the triangular fibrocartilage of the wrist. AJR Am J

Roentgenol. 2002;178(2):419–22. doi:10.2214/ajr.178.2.1780419. PubMed PMID: 11804907. Epub 2002/01/24.

7. Cody ME, Nakamura DT, Small KM, Yoshioka H. MR Imaging of the Triangular Fibrocartilage Complex. Magn Reson Imaging Clin N Am. 2015;23(3):393–403. Epub 2015/07/29.. ;). 4.001. PubMed PMID: 26216770. doi: 10.1016/j.mric.2015.0.
8. Palmer AK. Triangular fibrocartilage complex lesions: a classification. J Hand Surg Am. 1989;14(4):594–606. doi:10.1016/0363-5023(89)90174-3. PubMed PMID: 2666492. Epub 1989/07/01.
9. Atzei A. New trends in arthroscopic management of type 1-B TFCC injuries with DRUJ instability. J Hand Surg Eur Vol. 2009;34(5):582–91. Epub 2009/07/22. doi: 10.1177/1753193409100120. PubMed PMID: 19620186.
10. Corso SJ, Savoie FH, Geissler WB, Whipple TL, Jiminez W, Jenkins N. Arthroscopic repair of peripheral avulsions of the triangular fibrocartilage complex of the wrist: a multicenter study. Arthroscopy. 1997;13(1):78–84. doi:10.1016/s0749-8063(97)90213-9. PubMed PMID: 9043608. Epub 1997/02/01.
11. Bednar JM, Osterman AL. The role of arthroscopy in the treatment of traumatic triangular fibrocartilage injuries. Hand Clin. 1994;10(4):605–14. Epub 1994/11/01. PubMed PMID: 7868628.
12. Yao J, Dantuluri P, Osterman AL. A novel technique of all-inside arthroscopic triangular fibrocartilage complex repair. Arthroscopy. 2007;23(12):1357.e1-4. Epub 2007/12/08. doi: 10.1016/j.arthro.2007.02.010. PubMed PMID: 18063183.
13. Lee CK, Cho HL, Jung KA, Jo JY, Ku JH. Arthroscopic all-inside repair of Palmer type 1B triangular fibrocartilage complex tears: a technical note. Knee surgery, sports traumatology, arthroscopy:. official journal of the ESSKA. 2008;16(1):94–7. doi:10.1007/s00167-007-0386-9. PubMed PMID: 17668185. Epub 2007/08/02.
14. Chou KH, Sarris IK, Sotereanos DG. Suture anchor repair of ulnar-sided triangular fibrocartilage complex tears. J Hand Surg Br. 2003;28(6):546–50. doi:10.1016/s0266-7681(03)00173-6. PubMed PMID: 14599826. Epub 2003/11/06.
15. Nakamura T, Sato K, Okazaki M, Toyama Y, Ikegami H. Repair of foveal detachment of the triangular fibrocartilage complex: open and arthroscopic transosseous techniques. Hand Clin. 2011;27(3):281–90. doi:10.1016/j.hcl.2011.05.002. PubMed PMID: 21871351. Epub 2011/08/30.
16. Desai MJ, Hutton WC, Jarrett CD. Arthroscopic repair of triangular fibrocartilage tears: a biomechanical comparison of a knotless suture anchor and the traditional outside-in repairs. J Hand Surg Am. 2013;38(11):2193–7. doi: 10.1016/j.jhsa.2013.08.097. PubMed PMID: 24206982.
17. Park JH, Kim D, Park JW. Arthroscopic one-tunnel transosseous foveal repair for triangular fibrocartilage complex (TFCC) peripheral tear. Arch Orthop Trauma Surg. 2018;138(1):131–8. doi:10.1007/s00402-017-2835-3. PubMed PMID: 29124362. Epub 2017/11/11.
18. Sachar K. Ulnar-sided wrist pain: evaluation and treatment of triangular fibrocartilage complex tears, ulnocarpal impaction syndrome, and lunotriquetral ligament tears. J Hand Surg Am.

2008;33(9):1669–79. doi:10.1016/j.jhsa.2008.08.026. PubMed PMID: 18984356. Epub 2008/11/06.

19. Wang Z, Xiong Y, Tang X, Li Q, Zhang Z, Li J, et al. An arthroscopic repair technique for meniscal tear using a needle and suture: outside-in transfer all-inside repair. BMC Musculoskelet Disord. 2019;20(1):614. doi:10.1186/s12891-019-2984-3. PubMed PMID: 31870350; PubMed Central PMCID: PMCPMC6929296. Epub 2019/12/25.
20. Zachee B, De Smet L, Fabry G. Arthroscopic suturing of TFCC lesions. Arthroscopy. 1993;9(2):242-3. Epub 1993/01/01. doi: 10.1016/s0749-8063(05)80386-x. PubMed PMID: 8461093.
21. Skie MC, Mekhail AO, Deitrich DR, Ebraheim NE. Operative technique for inside-out repair of the triangular fibrocartilage complex. J Hand Surg Am. 1997;22(5):814–7. doi:10.1016/s0363-5023(97)80074-3. PubMed PMID: 9330138. Epub 1997/10/23.
22. Trumble TE, Gilbert M, Vedder N. Arthroscopic repair of the triangular fibrocartilage complex. Arthroscopy. 1996;12(5):588–97. doi:10.1016/s0749-8063(96)90199-1. PubMed PMID: 8902134. Epub 1996/10/01.
23. Yao J. All-arthroscopic triangular fibrocartilage complex repair: safety and biomechanical comparison with a traditional outside-in technique in cadavers. J Hand Surg Am. 2009;34(4):671–6. doi:10.1016/j.jhsa.2009.01.014. PubMed PMID: 19345869. Epub 2009/04/07.
24. Waterman SM, Slade D, Masini BD, Owens BD. Safety analysis of all-inside arthroscopic repair of peripheral triangular fibrocartilage complex. Arthroscopy. 2010;26(11):1474–7. doi: 10.1016/j.arthro.2010.02.027. PubMed PMID: 20851562.
25. Yao J, Lee AT. All-arthroscopic repair of Palmer 1B triangular fibrocartilage complex tears using the FasT-Fix device. J Hand Surg Am. 2011;36(5):836–42. doi:10.1016/j.jhsa.2011.01.005. PubMed PMID: 21458928. Epub 2011/04/05.
26. Conca M, Conca R, Dalla Pria A. Preliminary experience of fully arthroscopic repair of triangular fibrocartilage complex lesions. Arthroscopy. 2004;20(7):e79–82. doi:10.1016/j.arthro.2004.06.025. PubMed PMID: 15346129. Epub 2004/09/04.
27. McAdams TR, Hentz VR. Injury to the dorsal sensory branch of the ulnar nerve in the arthroscopic repair of ulnar-sided triangular fibrocartilage tears using an inside-out technique: a cadaver study. J Hand Surg Am. 2002;27(5):840–4. doi:10.1053/jhsu.2002.34370. PubMed PMID: 12239674. Epub 2002/09/20.
28. Bayoumy MA, Elkady HA, Said HG, El-Sayed A, Saleh WR. Short-term evaluation of arthroscopic outside-in repair of ulnar side TFCC tear with vertical mattress suture. J Orthop. 2016;13(4):455–60. doi:10.1016/j.jor.2015.10.013. PubMed PMID: 27857481; PubMed Central PMCID: PMCPMC5103042. Epub 2016/11/20.
29. Böhringer G, Schädel-Höpfner M, Petermann J, Gotzen L. A method for all-inside arthroscopic repair of Palmer 1B triangular fibrocartilage complex tears. Arthroscopy. 2002;18(2):211–3. doi:10.1053/jars.2002.30445. PubMed PMID: 11830818. Epub 2002/02/07.
30. Kuremsky MA, Habet N, Peindl RD, Gaston RG. Proximity of the Triangular Fibrocartilage Complex to Key Surrounding Structures and Safety Assessment of an Arthroscopic Repair Technique: A

Cadaveric Study. Arthroscopy. 2016;32(12):2490–4. doi:10.1016/j.arthro.2016.06.045. PubMed PMID: 27614390. Epub 2016/09/12.

Figures

Figure 1

a needle of 10 ml sterile syringe.

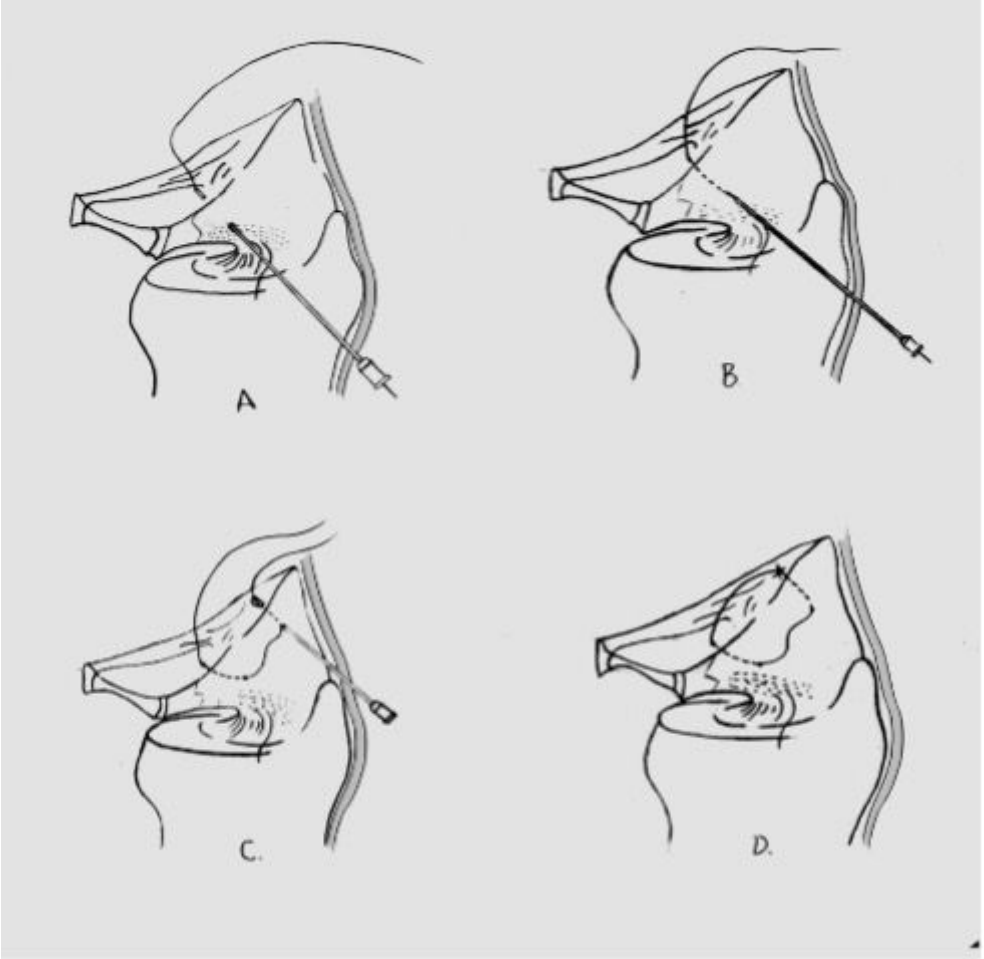

Figure 2

the suture method using a needle and suture. (A)The needle with 2 PDS suture penetrates the lower surface of the TFCC, and one limb of the PDS suture is pulled out with a grasper from the 6R portal. (B)The needle is withdrawn to the subcutaneous. (C) Adjust the angle, the needle penetrates the upper surface of the TFCC, another limb of the PDS suture is pulled out with a grasper from the 6R portal (the two limbs of the suture were retrieved through the same arthroscopy portal using a grasper and formed a sliding knot inside the joint. (D) Tennessee Knots and then additional knots were made to secure the knot. The suture strands were cut by knot cutter and then the knot was pushed to the upper surface of the TFCC.

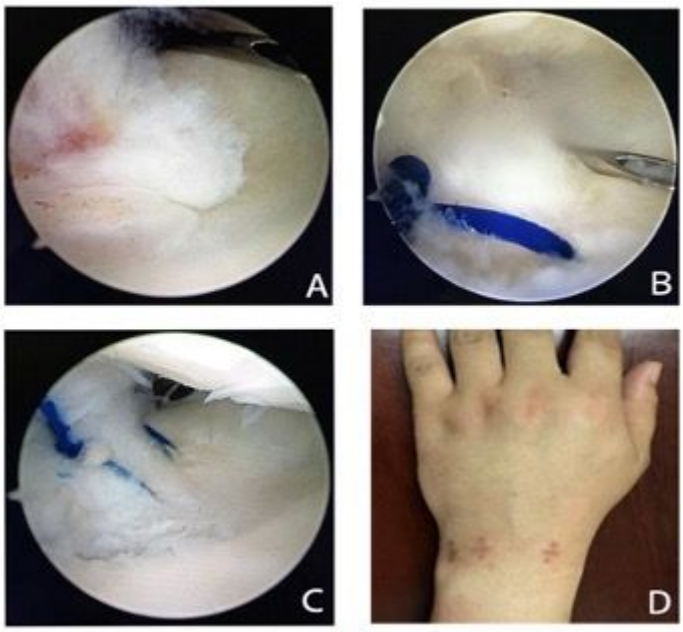

Figure 3

one patient with Palmer type 1B TFCC tear was operated using the outside-in transfer, all-inside technique. A. Arthroscopic examination revealed the TFCC injury, Palmer type I B, superficial injury. B. The needle with PDS suture penetrates the lower surface of the TFCC.C Repair of injured TFCC using a needle and suture.D. The knots cause an inflammatory reaction after the operation.