Application of Ultrasonography in Conservative Treatment of Humeral Shaft Fracture in Children

Jun Li
Chongqing Medical University Affiliated Children's Hospital
Xin Tan
Chongqing Medical University Affiliated Children's Hospital
Xiang Li
Chongqing Medical University Affiliated Children's Hospital
Pan Gou
Chongqing Medical University Affiliated Children's Hospital
Xiaowei Yuan
Chongqing Medical University Affiliated Children's Hospital
Tao Liu
Chongqing Medical University Affiliated Children's Hospital
Mingyan Shi
Chongqing Medical University Affiliated Children's Hospital
Xing Liu (liuxingda@126.com)
Chongqing Medical University Affiliated Children's Hospital

Research article

Keywords: Ultrasonography, Humeral shaft fracture, Conservative treatment, Pediatric fracture

Posted Date: July 19th, 2021

DOI: https://doi.org/10.21203/rs.3.rs-682240/v1

Abstract

Background: Most of humeral shaft fractures in children could be treated satisfactorily by conservative treatment. This study aimed to evaluate the application value of ultrasonography in conservative treatment of humeral shaft fracture in children.

Methods*:* We retrospectively reviewed children admitted to our hospital, for humeral shaft fracture from January 2014 to March 2018. The patients were divided into two groups: ultrasonography group and X-ray group. All patients were instructed to evaluat the prognosis according to the Disabilities of Arm, Shoulder and Hand (DASH) score at 12 months.

Results*:* A total of 37 children were divided into ultrasonography group, 32 children were divided into X-ray group. There was no significant difference in DASH between the two groups. The mean number of radiation exposures of ultrasonography group was less and ultrasonic examination found radial nerve injury, and using ultrasound reduced the chance of direct or in direct contact with infected peoples.

Conclusions: Ultrasound is a non-invasive, non-radioactive test, which could decrease risk of COVID-19 infection and detect the vascular nerve injury caused by fracture. Ultrasonography may be the examination method for follow-up conservative treatment of humeral shaft fracture in children during the epidemic period.

Background

Fractures of the humeral shaft are relatively rare in children, which account for approximately 0.4-3% of all pediatric fractures[1–3]. Most of pediatric humeral shaft fractures are treated conservatively, such as skin traction, casts and functional bracing, and demonstrate good prognosis. The widely accepted indication for operative treatment of pediatric humeral shaft fractures are open fractures, pathologic fractures and neurovascular compromise[4].

Due to the lack of rigid internal fixation of fracture, conservative treatment of humeral shaft fracture is accompanied by high risk of increasing displacement of fracture, and X-rays need to be re-examined frequently. Excessive radiation exposure increases patient's family anxiety about radiation damage. At 7 AM Beijing Time, on January 26, 2021, the cumulative number of confirmed cases of COVID-19 in the world had exceeded 100 million. There was report showed environmental contamination of radiology departments resulting in cross-infection of COVID-19[5]. X-rays are often required for out-patient review of pediatric humeral shaft fractures, but febrile children with high infection risk of COVID-19 also need X-rays. If children with fractures contact with febrile children, it will increase the potential risk of COVID-19.

In recent years, as ultrasonic technology advance, the advantages of non-invasive, portable and safe are increasingly prominent, and it is more widely used in the diagnosis and reduction of fracture in children[6, 7]. Bodner G et al study showed that ultrasonography has obvious advantages compared with X-ray for accurate evaluation of the radial nerve in patients with nerve palsy associated with humeral shaft

fracture[8]. This study aimed to evaluate the application value of ultrasonography in conservative treatment of humeral shaft fracture in children and evaluate whether ultrasonography could be used as an alternative to X-ray for humeral shaft fracture review during the epidemic period.

Methods

Setting

The date of this study collected from our hospital, which is the largest Children hospital in southwest China. We retrospectively reviewed children with humeral shaft fractures admitted to our hospital from January 2014 to March 2018. The inclusion criteria were as follows: 1. The patients were under 16 years; 2. patients with humeral shaft fractures and underwent conservative treatment by skin traction or functional bracing. And the exclusion criteria were: 1. Open fractures, multiple fractures, pathological or comminuted fractures; 2. Brachial plexus, or vascular injury requiring surgery; 3. Conservative management failed, surgical intervention was required; 4. Incomplete follow-up. The patients who were followed up by ultrasound were included in the ultrasound group, and others were included in the X-ray group. The patients of ultrasound group were instructed to re-examined by ultrasound at 1 day, 5 days, 10 days, 15 days, 1 month, 2 months, 6 months and 12 months, and re-examined by X-ray at 1 mouth, 6 mouths from the date of fracture reduction. If the great fracture displacement was detected by ultrasound or cartilage couldn't be found 15 days after injury, X-ray should be reviewed promptly. The patients of X-ray group were instructed to re-examined by X-ray at 1 day, 5 days, 10 days, 15 days, 1 month, 2 months, 6 months and 12 months from the date of fracture reduction. All patients were evaluated the prognosis according to the Disabilities of Arm, Shoulder and Hand (DASH) score at 12 months (Fig. 1).

Examination procedure

In this study, the ultrasound machine was Philips-CX50 color ultrasonic diagnostic apparatus (Philips, Amsterdam, Netherlands), select high frequency linear probe L3-12, probe frequency 5-MHz, the bedside X-ray machine was Japanese R-20C (Toshiba Corporation, Tokyo, Japan), the highest tube voltage 150kVP. The procedure of high frequency ultrasound examination: after the affected limb was supported by skin traction or functional bracing, and applied coupling agent (Corfu Medical Technology Co Ltd, Changsha, China) on the skin surface of fracture, transverse and longitudinal scanned with ultrasonic probe in anterior, medial and lateral position of fracture. Determined the location of continuous interruption of hyperechoic optical band of bone cortex according to ultrasonic image, evaluated the angle, displacement, shortening of the fracture site, and judged whether existed soft tissue incarceration or nerve disconnection (Fig. 2). The procedure of X-ray examination: Bedside anteroposterior film of humerus for children with skin traction, anteroposterior and lateral film of humerus for children with functional bracing or outpatient review.

Statistical Analysis

The statistical analysis was performed using SPSS 25 (IBM, Armonk, New York, USA) and differences were assessed with Pearson χ^2 for categorical variables. The critical *P*-value for significance was set at 0.05.

Results

A total of 39 boys and 30 girls with humeral shaft fractures were enrolled in the study, and 37 children were divided into ultrasonography group, 32 children were divided into X-ray group (Table 1). We assessed the prognosis of fractures by DASH questionnaire at 12 months after fractures. The mean score of ultrasonography group was 10.73±5.84 and X-ray group was 9.53±6.36, there was no statistically significant difference between two groups. The mean number of radiation exposures of ultrasonography group was 3.22±0.48, and the X-ray groups was 10.28±0.58, the radiation exposure time of the ultrasonography group was significantly shorter than that of the X-ray group (Figure 3). There were 4 children showed radial nerve with a circumscribed swelling by the B-ultrasound image, the nerve swelling disappeared during conservative treatment of fracture and patients did not show signs of the radial nerve injury after the fractures were healed.

Table 1: The general results of this study.

	ultrasonography group	X-ray group	P
Gender			
Male	21	18	0.966
Female	16	14	
Mean age (years)	5.68±3.58	6.72±4.42	0.282
Treatment methods			
Skin traction	23	19	0.813
Functional bracing	14	13	
DASH (mean score)	10.73±5.84	9.53±6.36	0.418
Frequency of radiation exposure	3.22±0.48	10.28±0.58	0.05

Discussion

The healing ability and plastic ability of fracture in children were better than adults, as such, the preferred treatment for humeral shaft fractures in children is conservative treatment[1, 9, 10]. As lack of rigid fixation at fracture sites during conservative treatment, frequent X-ray examination was in need to ensure position of fracture broken end and growth of fracture callus. But frequent X-ray examination means more radiation exposure time, children are considerably more sensitive to the carcinogenic effects of

radiation than adults, and the risk of cancer increases with increasing time of radiation exposure time such as cancer of the thyroid, breast, brain and skin, as well as leukemia. Risks of radiation-related cancer are greater as patients younger, also these risks will last a lifetime[11-13]. Therefore, it is an inevitable trend of medical development to find methods of examination which would not cause additional damage in the process of diagnosis and treatment.

Ultrasonography was originally used for soft tissue examination, as its real-time imaging, multiplanar capabilities, cost-effectiveness, portability, patient comfort and absence of radiation exposure, ultrasonography was widely used in musculoskeletal system examination[14, 15]. HERREN et al[16] used ultrasound to examine 201 children with forearm fractures, the sensitivity and specificity of diagnosing fractures were higher than 99.5%. Ultrasound also was used to treat displaced radial neck fractures by our hospital, ultrasonography guidance can reduce X-ray radiation exposure and the risk of posterior interosseous nerve injury[7]. In this study we used ultrasonography and X-ray to follow up humeral shaft fracture children with conservative treatment, the DASH score did not show a statistical difference, and radiation exposure time of ultrasonography group was significantly less than the X-ray group.

It has been more than a year since COVID-19 pandemic was first reported in China at the end of 2019[17], but the epidemic has not been well controlled, the number of newly infected individuals and daily number of deaths were increased every day. As CT and X-ray were important tool for screening, preliminary diagnosis and severity assessment of COVID-19[18], the radiology department inevitably became a gathering place with infected and potentially infected patients. Although countries and hospitals presented relevant measures to prevent the spread of the epidemic in the radiology department[19-21], there was report showed radiology departments as infectious source in cross-infection of COVID-19[5].

Ultrasonography has the advantages of no trauma, simple inspection, easy to disinfect and repeatability, separate ultrasound equipment can be provided in the hospital department or clinic. Children with fractures could be reexamined by ultrasound in the hospital department or clinic, and the ultrasound probe could be quickly disinfected after the examination. Some studies have shown that proper use of ultrasound could reduce the risk of virus transmission[22, 23]. Using ultrasound to follow-up of children with fractures significantly reduces the possibility of direct or in direct contact with infected peoples and minimized the transmission risk of COVID-19.

Due to the specificity of ultrasonography for soft tissue imaging, besides fracture sites, vessels, nerves and muscles are also well demonstrated with ultrasonography. It is significant to detect the arterial resistance index (RI) by ultrasonography to predict the prognosis of fracture, according to CARUSO's study[24], when RI<0.6, it predicts good blood supply and fracture healing will be well, when RI>0.7, it predicts poor blood supply and delay fracture healing or nonunion in fracture repair. Our previous studies have shown that ultrasonography could detect callus earlier than X-ray, delay fracture healing could be found early and treated timely[25].

Radial nerve is one of the most vulnerable nerves in humeral shaft fracture[3]. Children often can't cooperate with physical examination well when injury because of their special age, and radial nerve injury can't be determined by physical examination, it is difficult for doctors to decide whether to operate or not. Ultrasonography has absolute advantages over X-ray in examining nerve damage, studies have shown radial nerve injury can be detected early by ultrasound, and if there is no entrapment or rupture of the radial nerve, most of the radial nerve injuries will be recovered after conservative treatment[8]. In this study, there were 4 children showed radial nerve with a circumscribed swelling by the B-ultrasound image, the nerve swelling disappeared during conservative treatment of fracture, and there were no special manifestations of nerve injury on plain films in these 4 children. With the help of ultrasound, nerve injury could be better defined, and clinicians would decide whether to have surgical treatments easier.

During the ultrasound examination, the doctor can communicate with the patient to eliminate the patient's fear. At the same time, the patients can tell the doctor how they feel and examine the specific site to find the damage, unclear neurovascular injury can be further clarified by comparative examination of both limbs. The epiphysis as unique tissue structure of children, which isn't well displayed on plain films, but the epiphyseal injury could be defined by ultrasound examination[26]. But ultrasound also has some disadvantages, for example, 1.It requires an experienced operator with a great knowledge of the ultrasound appearance of different soft-tissue structures; 2. Ultrasound is inferior to plain film in overall view of fracture; 3.The ultrasound probe needs to be in direct contact with the children's skin[8]. Overall, Ultrasonography could be used as an alternative to X-ray examination for humeral fractures.

Limitations

The main limitation of the study was mainly due to the characteristic of a limited sample size, and patients were followed up for a short time. Bias during the research seemed to be unavoidable.

Conclusions

This study shows that ultrasonography could be used as an examination method to follow up humeral fractures in children, and basically replaced X-ray. The use of ultrasonography to follow up humeral fractures has the following advantages: 1.Ultrasound is a non-invasive, convenient, and comfortable test that can protect children from radiation damage from X-ray; 2.The humeral fractures were reexamined by ultrasound could avoid direct or indirect contact between patients and gathered people, and ultrasonic equipment could be quickly sterilized to further avoid the spread of COVID-19; 3. Ultrasonic examination of vascular and nerve injury caused by fracture has obvious advantages over X-ray. The radial nerve is the vulnerable nerve of humeral shaft fracture. Physical examination of children often fails to determine the degree of radial nerve injury, but ultrasonography can intuitively show radial nerve injury and determine whether or not surgery should be performed. In conclusion, ultrasonography may be the examination method for follow-up conservative treatment of humeral shaft fracture in children during the epidemic period.

Abbreviations

coronavirus disease 2019 (COVID-19); Disabilities of Arm, Shoulder and Hand score (DASH)

Declarations

Ethics approval and consent to participate

The patient's family and patient consented to this study and ethical was approval from our hospital.

Consent for publication

Publication has been approved by patient's parents.

Availability of data and materials

Data will be made available upon requesting the corresponding author on reasonable request.

Competing interests

The authors have no relevant financial or non-financial interests to disclose.

The authors have no conflicts of interest to declare that are relevant to the content of this article.

All authors certify that they have no affiliations with or involvement in any organization or entity with any financial interest or non-financial interest in the subject matter or materials discussed in this manuscript.

The authors have no financial or proprietary interests in any material discussed in this article.

Funding

This study was supported by Chongqing science and technology commission basic and frontier exploration general project (No.csct2018jcyjA0259), the Key Project of Chongqing Health Planning Commission of Research Fund (No.2019ZDXM047) and Yuzhong science and technology commission basic and frontier exploration general project (No.20180115).

Authors' contributions

Contributors' Statement Page: Dr Jun Li and Professor Xing Liu conceptualised and designed the study, drafted the original manuscript, and reviewed and revised it. Dr Xiaowei Yuan, Dr Xin Tan, Dr Tao Liu, Dr Pan Gou, Dr Xiang Li and Dr Mingyan Shi, gathered the data, conducted a preliminary analysis and reviewed and revised the manuscript.

All authors accept the final submission and agree to be responsible for all aspects of the work

Acknowledgements

We thank all staffs who work in Department of Orthopedic for your help.

References

1. Caviglia H, Garrido CP, Palazzi FF, et al. Pediatric fractures of the humerus. Clin Orthop Relat Res. 2005:49-56. https://doi.org/10.1097/01.blo.0000156452.91271.fb.
2. Rämö L, Sumrein BO, Lepola V, et al. Effect of Surgery vs Functional Bracing on Functional Outcome Among Patients With Closed Displaced Humeral Shaft Fractures: The FISH Randomized Clinical Trial. JAMA. 2020;323:1792-801. https://doi.org/10.1001/jama.2020.3182.
3. Shaughnessy MA, Parry JA, Liu H, et al. Management of paediatric humeral shaft fractures and associated nerve palsy. J Child Orthop. 2019;13:508-15. https://doi.org/10.1302/1863-2548.13.190012.
4. Canavese F, Marengo L, Cravino M, et al. Outcome of Conservative Versus Surgical Treatment of Humeral Shaft Fracture in Children and Adolescents: Comparison Between Nonoperative Treatment (Desault's Bandage), External Fixation and Elastic Stable Intramedullary Nailing. J Pediatr Orthop. 2017;37:e156-156e163. https://doi.org/10.1097/BPO.0000000000000843.
5. Xing Y, Wong G, Ni W, et al. Rapid Response to an Outbreak in Qingdao, China. N Engl J Med. 2020;383:e129. https://doi.org/10.1056/NEJMc2032361.
6. Malahias MA, Manolopoulos PP, Kadu V, et al. Bedside Ultrasonography for Early Diagnosis of Occult Radial Head Fractures in Emergency Room: A CT-Comparative Diagnostic Study. Arch Bone Jt Surg. 2018;6:539-46.
7. Su Y, Jin C, Duan X, et al. Treatment of displaced radial neck fractures under ultrasonographic guidance in children. Int Orthop. 2020;44:2337-42. https://doi.org/10.1007/s00264-020-04630-w.
8. Bodner G, Buchberger W, Schocke M, et al. Radial nerve palsy associated with humeral shaft fracture: evaluation with US–initial experience. Radiology. 2001;219:811-6. https://doi.org/10.1148/radiology.219.3.r01jn09811.
9. Slongo T, Audigé L, Schlickewei W, et al. Development and validation of the AO pediatric comprehensive classification of long bone fractures by the Pediatric Expert Group of the AO Foundation in collaboration with AO Clinical Investigation and Documentation and the International Association for Pediatric Traumatology. J Pediatr Orthop. 2006;26:43-9. https://doi.org/10.1097/01.bpo.0000187989.64021.ml.
10. Wang H, Feng C, Liu H, et al. Epidemiologic Features of Traumatic Fractures in Children and Adolescents: A 9-Year Retrospective Study. Biomed Res Int. 2019;2019:8019063. https://doi.org/10.1155/2019/8019063.
11. Kleinerman RA. Cancer risks following diagnostic and therapeutic radiation exposure in children. Pediatr Radiol. 2006;36 Suppl 2:121-5. https://doi.org/10.1007/s00247-006-0191-5.
12. Leung RS. Radiation Protection of the Child from Diagnostic Imaging. Curr Pediatr Rev. 2015;11:235-42. https://doi.org/10.2174/1573396311666150729121930.

13. Shulan JM, Vydro L, Schneider AB, et al. Role of biomarkers in predicting the occurrence of thyroid neoplasms in radiation-exposed children. Endocr Relat Cancer. 2018;25:481-91. https://doi.org/10.1530/ERC-17-0408.
14. Kwee RM, Kwee TC. Ultrasound for diagnosing radiographically occult scaphoid fracture. Skeletal Radiol. 2018;47:1205-12. https://doi.org/10.1007/s00256-018-2931-7.
15. Wu Z, Yi X, Li Y, et al. Decreased Radiation Exposure Using Ultrasound-Assisted Reduction and Fixation of Femoral Shaft Fractures in Children: A Pilot Study. Ultrasound Med Biol. 2020;46:3154-61. https://doi.org/10.1016/j.ultrasmedbio.2020.07.026.
16. Herren C, Sobottke R, Ringe MJ, et al. Ultrasound-guided diagnosis of fractures of the distal forearm in children. Orthop Traumatol Surg Res. 2015;101:501-5. https://doi.org/10.1016/j.otsr.2015.02.010.
17. Li Q, Guan X, Wu P, et al. Early Transmission Dynamics in Wuhan, China, of Novel Coronavirus-Infected Pneumonia. N Engl J Med. 2020;382:1199-207. https://doi.org/10.1056/NEJMoa2001316.
18. Li K, Wu J, Wu F, et al. The Clinical and Chest CT Features Associated With Severe and Critical COVID-19 Pneumonia. Invest Radiol. 2020;55:327-31. https://doi.org/10.1097/RLI.0000000000000672.
19. Huang Z, Zhao S, Li Z, et al. The Battle Against Coronavirus Disease 2019 (COVID-19): Emergency Management and Infection Control in a Radiology Department. J Am Coll Radiol. 2020;17:710-6. https://doi.org/10.1016/j.jacr.2020.03.011.
20. Mossa-Basha M, Meltzer CC, Kim DC, et al. Radiology Department Preparedness for COVID-19: Radiology Scientific Expert Review Panel. Radiology. 2020;296:E106-106E112. https://doi.org/10.1148/radiol.2020200988.
21. Wan YL, Schoepf UJ, Wu CC, et al. Preparedness and Best Practice in Radiology Department for COVID-19 and Other Future Pandemics of Severe Acute Respiratory Infection. J Thorac Imaging. 2020;35:239-45. https://doi.org/10.1097/RTI.0000000000000529.
22. Abramowicz JS, Basseal JM. World Federation for Ultrasound in Medicine and Biology Position Statement: How to Perform a Safe Ultrasound Examination and Clean Equipment in the Context of COVID-19. Ultrasound Med Biol. 2020;46:1821-6. https://doi.org/10.1016/j.ultrasmedbio.2020.03.033.
23. Bonadia N, Carnicelli A, Piano A, et al. Lung Ultrasound Findings Are Associated with Mortality and Need for Intensive Care Admission in COVID-19 Patients Evaluated in the Emergency Department. Ultrasound Med Biol. 2020;46:2927-37. https://doi.org/10.1016/j.ultrasmedbio.2020.07.005.
24. Caruso G, Lagalla R, Derchi L, et al. Monitoring of fracture calluses with color Doppler sonography. J Clin Ultrasound. 2000;28:20-7. https://doi.org/10.1002/(sici)1097-0096(200001)28:1<20::aid-jcu3>3.0.co;2-w.
25. Chen J, Liu X, Zhang R, et al. High frequency ultrasound in evaluation of traction efficacy among children with femoral fractures. Journal of Third Military Medical University. 2019.
26. Piccolo CL, Galluzzo M, Ianniello S, et al. Pediatric musculoskeletal injuries: role of ultrasound and magnetic resonance imaging. Musculoskelet Surg. 2017;101:85-102. https://doi.org/10.1007/s12306-017-0452-5.

Figures

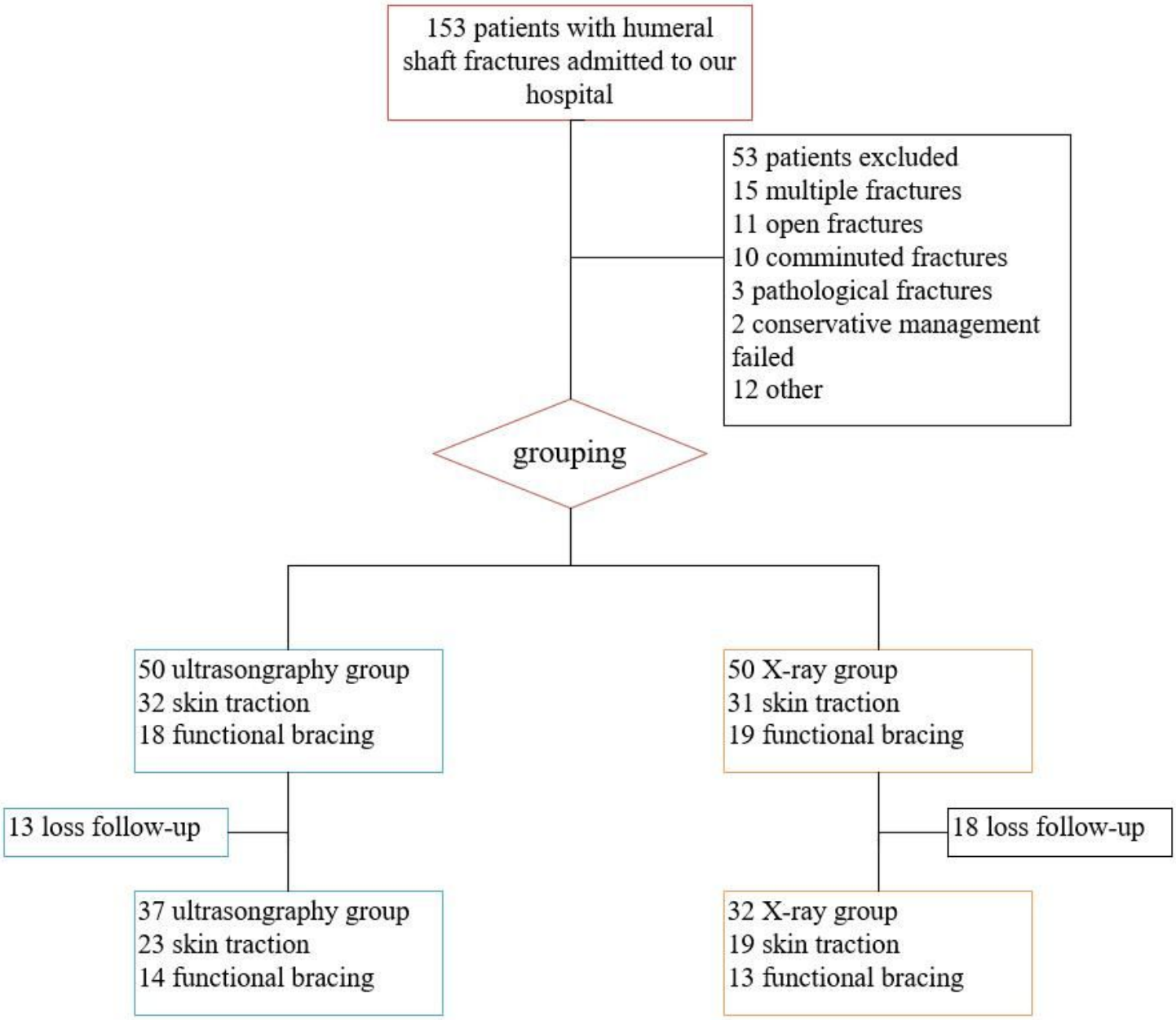

Figure 1

The flowchart of method.

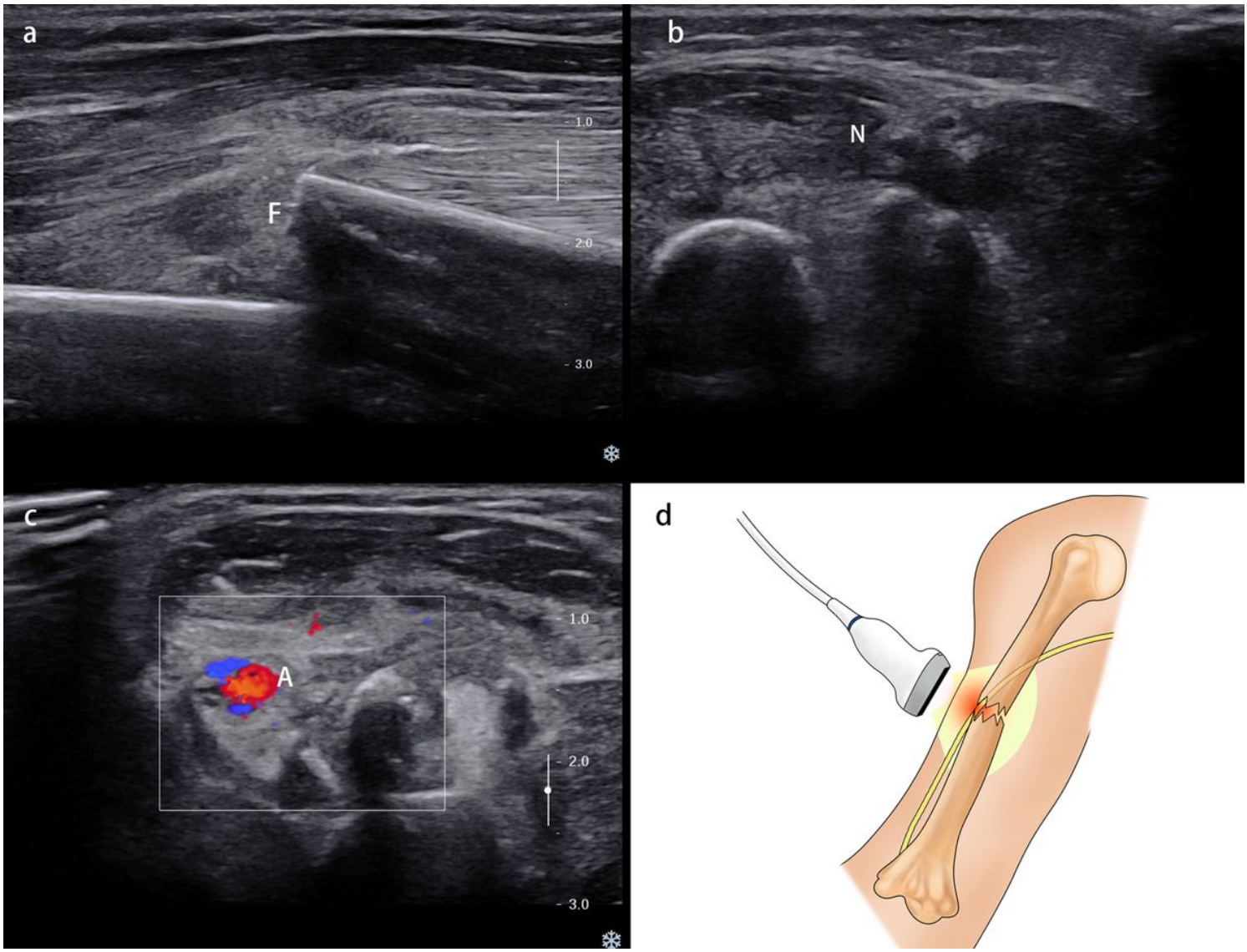

Figure 2

a: The end of the fracture was clearly shown (F); b: N indicated the swelling radial nerve; c: A represented brachial artery at fracture site; d: schematic diagram of fracture examined by ultrasound.

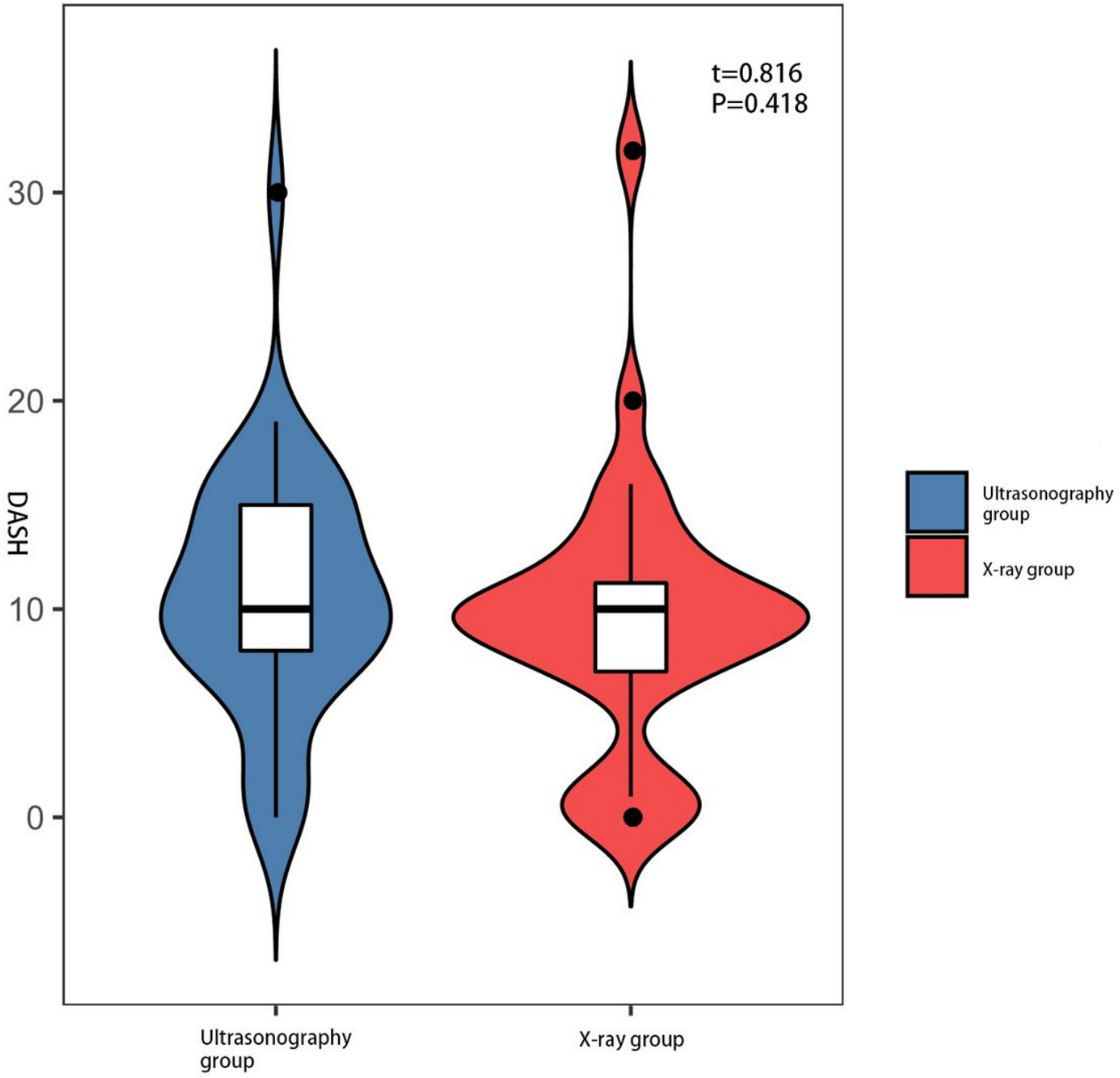

Figure 3

There was no statistically significant difference in Disabilities of Arm, Shoulder and Hand (DASH) score between ultrasonography group and X-ray group at 12 months after fractures.