A novel surgical approach for treating hiatal hernia with gastroesophageal reflux disease: the laparoscopic total left-side surgical approach

Zhi Zheng
Capital Medical University Affiliated Beijing Friendship Hospital
Xiaoye Xiaoye Liu
Capital Medical University Affiliated Beijing Friendship Hospital
Chenglin Xin
Capital Medical University Affiliated Beijing Friendship Hospital
Weitao Zhang
Capital Medical University Affiliated Beijing Friendship Hospital
Yan Gao
Capital Medical University
Na Zeng
Capital Medical University Affiliated Beijing Friendship Hospital
Mengyi Li
Capital Medical University Affiliated Beijing Friendship Hospital
Jun Cai
Capital Medical University Affiliated Beijing Friendship Hospital
Fandong Meng
Capital Medical University Affiliated Beijing Friendship Hospital
Dong Liu
Capital Medical University Affiliated Beijing Friendship Hospital
Jie Zhang
Capital Medical University Affiliated Beijing Friendship Hospital
Jie Yin
Capital Medical University Affiliated Beijing Friendship Hospital
Zhang Jun (zhangjun5986@ccmu.edu.cn)
Capital Medical University Affiliated Beijing Friendship Hospital
Zhongtao Zhang
Capital Medical University Affiliated Beijing Friendship Hospital

Research article

Keywords: Total left-side surgical approach (TLSA), Fundoplication, Hiatal hernia, Gastroesophageal reflux disease, Vagus nerve

Posted Date: July 8th, 2021

DOI: https://doi.org/10.21203/rs.3.rs-683019/v1

Abstract

Background

Although the traditional bilateral surgical approach can provide local protection of the vagus nerve, the integrity of the entire vagus nerve cannot be evaluated. Therefore, we developed total left-side surgical approach (TLSA), which theoretically eliminates injury to the vagus nerve, and evaluated its safety and effectiveness.

Methods

We initially performed a cadaver study to explore the characteristics of the vagus nerve, and then prospectively evaluated the TLSA in 5 patients with hiatal hernia and gastroesophageal reflux disease between June 2020 and September 2020. Demographic characteristics, surgical parameters, perioperative outcomes, and follow-up findings were analyzed.

Results

The patients were 40–64 years old and all 5 patients underwent TLSA successfully without any major complications. The median total operative time was 114 min, the median blood loss was 50 mL, and the median postoperative hospital stay was 3.8 days. Gastrointestinal function recovered within 4 days in all patients. The 6-month follow-up gastroscopy examination revealed well-established gastroesophageal flap valves. Relative to the baseline results, the 6-month follow-up revealed lower values for the total GerdQ score (12.4 vs. 6.2) and the total esophageal acid exposure time (3.48% vs. 0.38%). Based on the EORTC QLQ-STO52 questionnaire results, the incidences of dysphagia and flatulence decreased over time after the procedure.

Conclusions

TLSA provides a clear and broad surgical field, less trauma, rapid recovery, and is technically simple. Although our results suggest that the TLSA provides good safety and short-term efficacy, long-term results from a larger clinical trial are needed to validate these findings.

Trial registration

ChiCTR2000034028, registration date is June 21, 2020.

Introduction

Hiatal hernia (HH) is a condition that involves herniation of abdominal contents into the mediastinum via the diaphragmatic hiatus and is characterized by a dilated esophageal hiatus [1]. This condition is considered a major cause of gastroesophageal reflux disease (GERD), which may also be related to abnormal lower esophageal sphincter pressure [2]. Therefore, many patients with HH have GERD. Patients whose GERD does not respond to proton pump inhibitors (PPIs) may undergo laparoscopic HH repair with anti-reflux surgery [3, 4], which aims to reconstruct the local anatomical structures and address function deficiencies at the esophagogastric junction [5]. The current primary treatment in this setting involves using the traditional bilateral surgical approach (TBSA) to perform laparoscopic HH repair and Nissen fundoplication [6]. While this procedure can provide local protection of the vagus nerve, the integrity of the entire vagus nerve cannot be evaluated. Furthermore, the vagus nerve trunk and its branches are located in the lesser omentum, which must be incised during TBSA procedures. Therefore, while the vagus nerve trunk can be easily protected, small vagus nerve branches within the lesser omentum are usually not visible, which can lead to inadvertent injury during incision of the lesser omentum. These injuries can affect the patient's reflux symptoms and quality of life [7, 8].

We have developed a new surgical approach that we have called the "total left-side surgical approach" (TLSA) for laparoscopic HH repair with fundoplication. The potential advantages of the TLSA are that it is technically simple and completely preserves the lesser omentum and the hepatogastric ligament based on the anatomical characteristics of the vagus nerve. This technique may also help improve postoperative quality of life among patients with HH or GERD. This report describes our findings regarding the anatomical characteristics of the vagus nerve from a cadaver study, which we used to develop the TLSA, and preliminary results regarding the operative technique, safety, and short-term effectiveness of the TLSA in 5 patients who underwent surgical treatment for HH and GERD. We present the following article in accordance with the CONSORT reporting checklist.

Materials And Methods

Cadaver study

Chest and abdomen specimens had been collected from deceased donors. Formalin-fixed cadaveric specimens were provided by the Capital Medical University. This study was approved by the ethics committee of Beijing Friendship Hospital, Capital Medical University (2019-P2-060-02). The preliminary findings were used to judge the anatomical characteristics of the vagus nerve and the feasibility of the TLSA before it was used in patients.

Registered clinical trial

We have initiated a prospective trial of laparoscopic TLSA for treating HH. The trial protocol is registered at the Chinese Clinical Trial Registry website (http://www.chictr.org.cn/index.aspx, ChiCTR2000034028) and was approved by the ethics committee of Beijing Friendship Hospital, Capital Medical University (L-2020-019). The clinical trial was launched in July 2020 and is scheduled to end in December 2023. During the research period, patients will be recruited from the Beijing Friendship Hospital for treatment and must provide written informed consent before undergoing the procedures.

Inclusion criteria

The inclusion criteria are listed as follows. i) Patients must have HH with GERD that is diagnosed via gastroscopy, high-resolution esophageal manometry, and 24-h esophageal pH monitoring. ii) Patients must have typical reflux symptoms, such as acid reflux, heartburn, and burning pain in the chest area, which do not respond well to standard conservative medical treatment. iii) Patients must be 18–65 years old, regardless of sex. iv) Patients must have an Eastern Cooperative Oncology Group score of ≤ 2 points, an American Society of Anesthesiologists score of ≤ 2 points, and be able to tolerate the HH repair procedure. v) The enrolled patients must be able to comply with the research protocol during the study period and provide informed consent. vi) Patients must be willing to attend follow-up visits and cooperate with medical staff to collect relevant data. vii) Patients must not have a history of digestive system tumors or previous thoracic and abdominal surgery.

Patients and follow-up

The present report covers the characteristics and short-term outcomes of 5 patients with HH and GERD who underwent procedures via the TLSA in the general surgery department of Beijing Friendship Hospital Affiliated, Capital Medical University between June 2020 and September 2020. The patients had been followed for ≥ 6 months after the operation via outpatient visits, inpatient visits, telephone contact, or mailed correspondence. Demographic characteristics, surgical parameters, perioperative outcomes, and follow-up findings were analyzed

Surgical methods

Surgeon positioning

Based on the cadaver study results, we developed a new surgical approach for performing laparoscopic esophageal HH repair and fundoplication via the TLSA. The degree of fundoplication was determined based on the esophageal manometry and pH monitoring results. If the HH was > 5 cm, or if the diaphragm appeared weak on both sides of the defect, a surgical non-absorbable mesh was used. Surgery was performed in all cases with the patient in the supine position after successful general anesthesia induction and tracheal intubation. The surgeon stood on the patient's left side throughout the operation and the first assistant stood on the patient's right side. A second assistant stood between the patient's legs to manipulate the laparoscope (Fig. 1).

Port placements

The port placements are shown in Fig. 2. A 12-mm trocar is inserted through a transverse incision at 1 cm above the navel to establish pneumoperitoneum (maintained at 12–15 mmHg) and accommodate the laparoscope. A left anterior axillary subcostal incision is made to accommodate a 12-mm trocar as the surgeon's primary operating port. A left central clavicle incision is made approximately 2 cm above the navel to accommodate an auxiliary 5-mm trocar. A right central clavicle incision is also made approximately 2 cm above the navel to accommodate a 12-mm trocar for the assistant's instruments. A right anterior axillary subcostal incision is made to accommodate a 5-mm trocar. Finally, an incision is made approximately 2 cm below the xiphoid process to accommodate a 5-mm trocar for exposing the left liver lobe.

Operative technique

The operative technique is shown in Fig. 3. First, on the stomach's greater curvature, the gastrocolonic ligament is incised along the avascular area between the left and right gastric omentum vessels, and the gastric fundus is lifted vertically to the cardia to protect the vagus nerve. Second, the cardia, lower esophagus, and diaphragm are exposed, and the confluence of the left and right crus of the diaphragm is revealed. The retroperitoneum is incised at the left and right crus of the diaphragm, and the lower esophagus is dissociated for approximately 3–5 cm. The gastric fundus and posterior wall of the esophagus were fully dissociated from the upper spleen. Third, intermittent non-absorbable sutures are used at the left and right crus of the diaphragm to reconstruct the esophageal hiatus (approximate diameter: 1.5 cm). If required, the surgeon inserts the mesh and fixes it to on the crus of the diaphragm with staples. A small incision (approximately 2–3 cm) is then made above the bifurcation of the anterior vagal trunk and the hepatic branch of the vagus nerve. The fundus of the stomach is then rotated around the posterior aspect of the abdominal esophagus to the right anterior aspect of the esophagus, using intermittent non-absorbable sutures, and then fixed to the right crus of the diaphragm and the right side of the esophagus. The left side of the gastric fundus is also sutured to the anterior esophagus and the left crus of the diaphragm, which avoids vagus nerve injury. Finally, the surgeon completes the fundoplication and inserts the abdominal drainage tubes.

Results

Anatomical characteristics of the vagus nerve

The left and right branches of the vagus nerve are distributed in the anterior and posterior walls of the esophagus below the bronchial bifurcation. The left branch of the vagus nerve travels in the right anterior wall of the esophagus, where it forms the anterior trunk of the vagus nerve, and the right branch of the vagus nerve travels to the right posterior wall of the esophagus, where it forms the posterior trunk of the vagus nerve. Both branches pass through the hiatus of the diaphragmatic esophagus and then give off additional nerve branches.

Anterior vagal trunk

The anterior vagal trunk is located between the muscular layer and the peritoneum of the anterior esophageal wall of the abdominal segment. A single trunk is a common type and travels from the upper left aspect to the lower right aspect of the anterior esophageal wall. It closely adheres to the muscular layer of the esophagus and can be easily damaged if it is not carefully identified during surgery. At the level of the cardia, the anterior vagal trunk divides into hepatic branches and the anterior gastric branch. The hepatic branches mainly accompany the proper hepatic artery and travel to the hepatic portal to participate in the formation of the hepatic plexus, which is distributed throughout the liver and biliary tract, where it helps regulate the secretion activities of the hepatobiliary

system. After dividing into the hepatic branch, the anterior vagal trunk continues traveling down the lesser curvature of the stomach to form the anterior gastric branch, which is often close to the lesser curvature of the stomach (< 1 cm). This branch travels down to the gastric angle and forms the anterior 'crow's claw' branch, which travels between the two peritoneal layers of the lesser omentum (Fig. 4).

Posterior vagal trunks

The posterior vagal trunk is generally thicker than the anterior trunk and travels in loose tissue outside the muscular layer of the right posterior wall of the abdominal esophagus. The posterior vagal trunk is simple to identify and dissect in the gastropancreatic fold, where it gives off the celiac branch below the cardia, which is closely related to the left gastric artery. The celiac branch travels diagonally to the lower right aspect of the abdominal ganglion and participates in the formation of the abdominal nerve plexus. After the celiac branch is removed, the posterior vagal trunk continues to travel inferiorly along the posterior wall of the stomach's lesser curvature to form the posterior gastric branch, which adheres to the lesser curvature and continues to form the posterior 'crow's claw' branch at the gastric angle, where it further divides into 3–4 branches that are distributed to the posterior wall of the pylorus. The posterior vagal trunk and its branches are located in the triangular area created by the right crus of the diaphragm, the lateral margin of the stomach's lesser curvature, and the left gastric artery. The posterior vagal trunk and the celiac branch are variable and prone to injury during the operation (Fig. 5).

Surgical outcomes

Five patients underwent surgery via the TLSA. All patients were women and their demographic characteristics and operative results are shown in Table 1. The procedures included Nissen fundoplication (1 patient), Toupet fundoplication (3 patients), and Dor fundoplication (1 patient). The median total operative time was 114 min (range: 60–150 min), the median estimated blood loss was 50 mL, and none of the patients required conversion to open surgery or a second operation. There were no major complications, such as infection, bleeding, esophageal perforation, or death. Gastrointestinal function recovered within 4 days after the procedure in all patients. The median postoperative hospital stay was 3.8 days (range: 3–5 days).

Table 1
Patient demographic characteristics and operative results

Patient	Sex	Age (years)	BMI (kg/m^2)	Fundoplication degree	Total operation time (min)	Estimated Blood loss (ml)	Time for gastrointestinal recovery (days)	Postoperative hospital stays (days)	Second Operation
1	F	64	20.70	Toupet	150	20	2	3	No
2	F	52	30.86	Toupet	60	10	2	4	No
3	F	40	20.83	Nissen	120	10	4	3	No
4	F	64	26.04	Toupet	140	10	1	4	No
5	F	52	25.00	Dor	100	50	3	5	No

The patients attended a comprehensive follow-up visit after 6 months. Relative to the preoperative condition, the follow-up endoscopic examination revealed that the Hill grade of the gastroesophageal flap valve had improved from grade 1 to grades 2–4, and that 2 patients experienced complete resolution of their esophagitis. Moreover, the mean total GerdQ score improved from 12.4 to 6.2 and the total esophageal acid exposure time improved from 3.48–0.38%, which supports the short-term effectiveness of anti-reflux procedures that are performed via the TLSA (Table 2).

Table 2
Postoperative reexamination after 6 months

	Baseline				6-months Follow-up			
Patient	Hill	LA	TEAE time (%)	Gerd-Q	Hill	LA	TEAE time (%)	Gerd-Q
1	□	—	1.4	10	□	—	0.8	6
2	□	—	5.7	14	□	—	0.3	6
3	□	—	1.2	12	□	—	0.3	6
4	□	C	5.6	15	□	—	0.4	6
5	□	B	3.5	11	□	—	0.1	7
TATE time: total esophageal acid exposure time								

The incidence of complications was estimated using the EORTC QLQ-STO52 questionnaire at 1 month, 3 months, and 6 months after the procedure (Table 3). Relative to baseline, the dysphagia and flatulence scores had increased in the 1-month follow-up, although these scores gradually decreased over time. There were no significant changes in abdominal pain.

Table 3
The EORTC QLQ-STO52 scores from baseline to the 6-month follow-up

	Baseline			1-month Follow-up			3-months Follow-up			6-months Follow-u	
Patient no.	Dysphagia	Flatulence	Abdominal pain	Dysphagia	Flatulence	Abdominal pain	Dysphagia	Flatulence	Abdominal pain	Dysphagia	Flatu
1	1	2	2	1	2	2	1.3	2	1	1	1
2	1	1	1	1.3	2	1	1	3	2	1	2
3	1	2	2	2.7	2	2	2	3	2	1.3	1
4	1	1	1	2.3	3	2	1.3	1	1	1	1
8	1	1	3	1.3	3	2	1.3	1	2	1.3	1

Gastroscopy findings

All 5 patients underwent gastroscopy before and 6 months after the procedure, although the results were not specifically analyzed because all patients exhibited a good response after the procedure. Representative preoperative and postoperative gastroscopy findings from the 1 patient who underwent Nissen fundoplication are shown in Fig. 6. The preoperative evaluation revealed a large hernia sac protruding into the chest, which disappeared after the Nissen fundoplication. The gastric fundus flap was clearly visible at the 6-month follow-up.

Discussion

The Society of American Gastrointestinal and Endoscopic Surgeons issued guidelines for the management of HH in 2013 [9]. However, these guidelines did not provide detailed techniques for the HH repair or how to avoid nerve damage and protect organ functions during the operation. Moreover, there is still a lack of cadaver studies and clinical trials regarding the treatment of functional diseases, such as HH and GERD [10, 11].

Developments in laparoscopic tools and techniques, as well as the advantages of these techniques (less trauma, rapid recovery, and operative flexibility), have led to increasing adoption of minimally invasive techniques for treating HH. As a result, the primary treatment for HH now involves laparoscopic repair with fundoplication via the TBSA [12, 13]. However, the TBSA can create a complicated operation where it is difficult to expose important anatomical structures. The vagus nerve can be locally protected during procedures performed via the TBSA, although the integrity of the entire vagus nerve cannot be evaluated. Thus, some cases involve unidentified injury to the hepatobiliary branch of the vagus nerve injury, which only becomes apparent after the patient experiences postoperative complications, such as bile secretion disorder and gastrointestinal dysfunction, that seriously affect their quality of life [5, 7, 14, 15].

We performed a cadaver study to evaluate the anatomical characteristics of the vagus nerve and used the results to develop our novel TLSA, which is currently being tested in a clinical trial among patients with HH and GERD. The TLSA completely preserves the omentum and theoretically eliminates the risk of iatrogenic injury to the trunk of the vagus nerve and its branches, which are distributed throughout the omentum. Therefore, the TLSA can theoretically provide complete protection of the vagus nerve's physiological functions (and the innervated organs), which is supported by the fact that none of our 5 patients experienced any serious adverse events or complications. Moreover, relative to the TBSA, the TLSA may help enhance the patient's postoperative quality of life based on improvements in the DeMeester score, gastrointestinal recovery, and blood glucose and lipid concentrations. Moreover, the TLSA permits full dissociation of the gastrosplenic ligament at the stomach's greater curvature, which allows the surgeon to stretch the stomach to the right and obtain a broader surgical field. The increased working area may permit better outcomes in terms of the laparoscopic hiatus reconstruction, mesh placement, suturing, and fixation. Finally, the TLSA may help shorten the operation time, reduce surgical trauma, improve short-term therapeutic effects, and improve postoperative quality of life.

In conclusion, the TLSA provides a broad and clear surgical field, less trauma, rapid recovery, and a technically simple operation, which may make it especially suitable for elderly patients and patients with substantial comorbidities. However, the findings of this study are limited by the small sample size, short follow-up time, and single-center design. Therefore, a large prospective trial with prolonged follow-up is needed to confirm our preliminary findings of good safety and short-term efficacy.

Declarations

Funding

This work was supported by the Beijing Municipal Science & Technology Commission (No. D171100006517003), Beijing Municipal Administration of Hospitals Incubating Program (No. PX2020001), and the Research Foundation of Beijing Friendship Hospital, Capital Medical University (Y2018-3). The funder had no influence on the design of this trial or in the writing of the manuscript and presented the study outcomes, and had no role in the collection, analysis, and interpretation of data.

Competing interests

All authors have completed the ICMJE uniform disclosure form. All authors declare that they have no any conflict of interests.

Availability of data and material

We will transfer the CRFs to the EDC (https://edc-cloud.medsci.cn/#/login), which will be stored in a hard disk and cloud system. Detailed results will be openly shared after study completion.

Code availability

Not applicable.

Authors' contributions

With J Z1 corresponding to Jun Zhang, and J Z2 corresponding to Jie Zhang. J Y, J Z1, and ZT Z are the principal researchers and carried out the studies in all the phases of trial design. XY L, Z Z and CL X participated in data collection and obtained written informed consent from patients. WT Z and N Z performed the statistical analysis and participated in its design. MY L, J C, FD M, D L and J Z2 are responsible for formulating the Standard Operation Procedure. Y G provide anatomical guidance. Z Z, XY L and CL X helped to draft the manuscript. J Y and J Z1 revised the manuscript. All authors read and approved the final manuscript.

Ethics approval

The cadaver study (2019-P2-060-02) and registered clinical trial (L-2020-019) both have been reviewed and approved by the Ethics Committee of Beijing Friendship Hospital, Capital Medical University.

Consent to participate

The authors are accountable for all aspects of the work in ensuring that questions related to the accuracy or integrity of any part of the work are appropriately in investigated and resolved. According to the requirements of the ethics committee, the prospective study was conducted after the enrolled patients signed the informed consent and agreed to complete the scheduled postoperative 6-month follow-up. The study was conducted according to the principles of the Declaration of Helsinki (as revised in 2013).

Consent for publication

Not applicable.

Acknowledgments

We would like to thank Editage (www.editage.cn) for English language editing.

References

1. Yun JS, Na KJ, Song SY, Kim S, Kim E, Jeong IS, Oh SG. (2019) Laparoscopic repair of hiatal hernia. J Thorac Dis 11:3903–88.https://doi.org/ 10.21037/jtd.2019.08.94.
2. Philpott H, Sweis R. (2017) Hiatus Hernia as a Cause of Dysphagia. Curr Gastroenterol Rep19:40. https://doi.org/ 10.1007/s11894-017-0580-y.
3. Palser TR, Ceney A, Navarro A, Swift S, Bowrey DJ, Beckingham IJ. (2018) Variation in laparoscopic anti-reflux surgery across England: a 5-year review. Surg Endosc 32:3208–14. https://doi.org/ 10.1007/s00464-018-6038-y.
4. Freedberg DE, Kim LS, Yang YX. (2017) The Risks and Benefits of Long-term Use of Proton Pump Inhibitors: Expert Review and Best Practice Advice From the American Gastroenterological Association. Gastroenterology152:706–715. https://doi.org/ 10.1053/j.gastro.2017.01.031.
5. Yadlapati R, Hungness ES, Pandolfino JE. (2018) Complications of Antireflux Surgery. Am J Gastroenterol 113:1137–47. https://doi.org/ 10.1038/s41395-018-0115-7.
6. Bouazza F, Simoens C, Smets D, Ngongang C, Mendes da Costa P. Laparoscopic nissen's fundoplication: retrospective study of 168 cases, long-term follow-up. Hepatogastroenterology. 2007;54:1449–53.
7. van Rijn S, Rinsma NF, van Herwaarden-Lindeboom MY, Ringers J, Gooszen HG, van Rijn PJ, Veenendaal RA, et al (2016) Effect of Vagus Nerve Integrity on Short and Long-Term Efficacy of Antireflux Surgery. Am J Gastroenterol 111:508–15. https://doi.org/ 10.1038/ajg.2016.42.
8. Cockbain AJ, Parameswaran R, Watson DI, Bright T, Thompson SK. (2019) Flatulence After Anti-reflux Treatment (FAART) Study. World J Surg 43:3065–73. https://doi.org/ 10.1007/s00268-019-05144-2.
9. Peters JH. (2013) SAGES guidelines for the management of hiatal hernia. Surg Endosc 27:4407–8. https://doi.org/ 10.1007/s00464-013-3212-0.
10. Maret-Ouda J, Markar SR, Lagergren J. (2020). Gastroesophageal Reflux Disease. JAMA 324:2565. https://doi.org/ 10.1001/jama.2020.21573.
11. Smith RE, Shahjehan RD. Hiatal Hernia. StatPearls. Treasure Island (FL); 2021.
12. DeMeester SR. (2020) Laparoscopic Hernia Repair and Fundoplication for Gastroesophageal Reflux Disease. Gastrointest Endosc Clin N Am 30:309–24. https://doi.org/ 10.1016/j.giec.2019.12.007.
13. Omura N, Tsuboi K, Yano F. Minimally invasive surgery for large hiatal hernia. Ann Gastroenterol Surg. 2019;3:487–95. https://doi.org/10.1002/ags3.12278.
14. Hashimoto N, Wakagi M, Ippoushi K, Takano-Ishikawa Y. Involvement of the hepatic branch of the vagus nerve in the regulation of plasma adipokine levels in rats fed a high-fructose diet. J Nutr Biochem. 2019;71:90–7. https://doi.org/10.1016/j.jnutbio.2019.06.003.

15. Lu KH, Cao J, Oleson S, Ward MP, Phillips RJ, Powley TL, Liu Z. (2018) Vagus nerve stimulation promotes gastric emptying by increasing pyloric opening measured with magnetic resonance imaging. Neurogastroenterol Motil 30:e13380. https://doi.org/ 10.1111/nmo.13380.

Figures

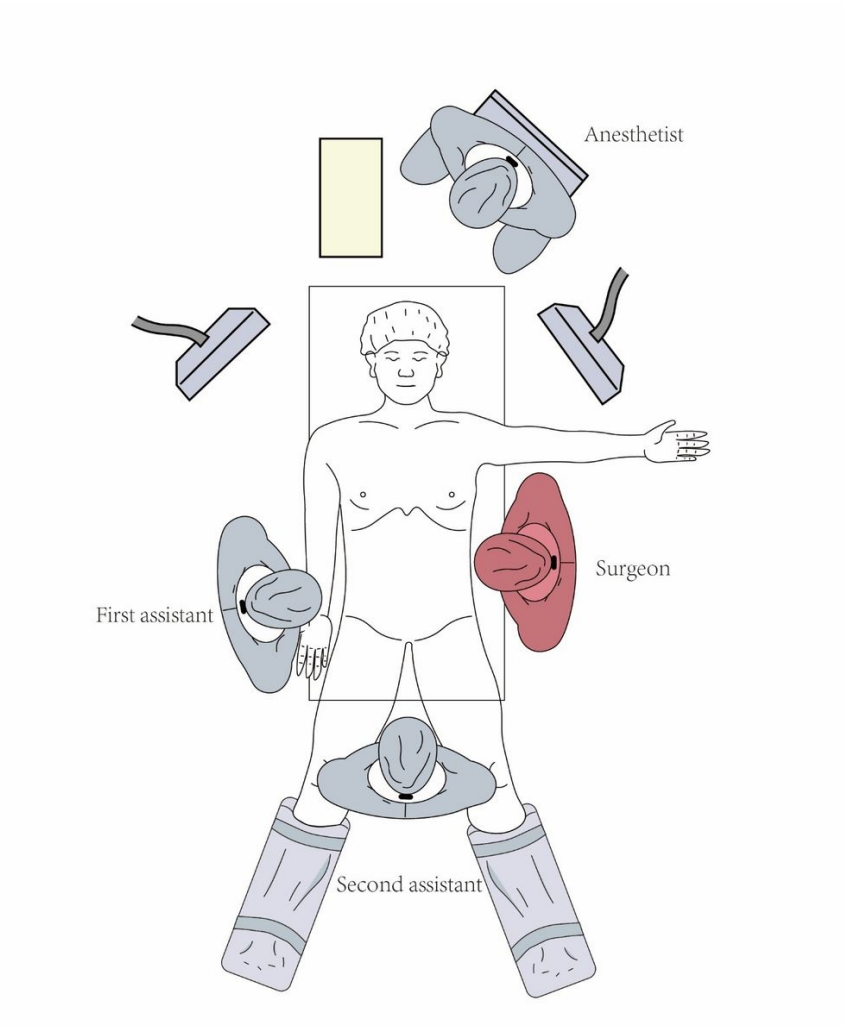

Figure 1

Surgeon position. The surgeon stands on the patient's left side throughout the operation, while the first assistant stands on the patient's right side and the second assistant stands between the patient's legs and manipulates the laparoscope.

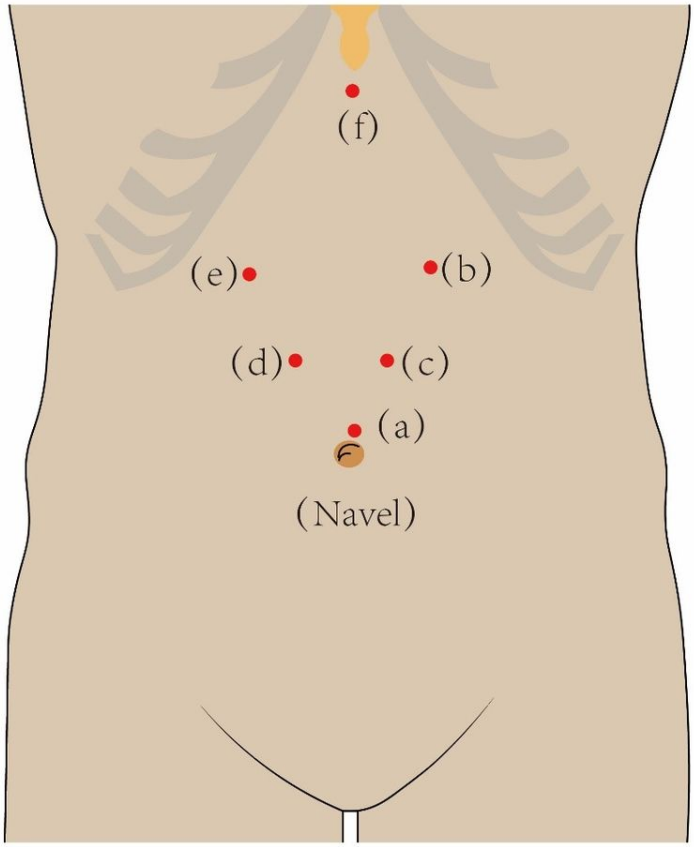

Figure 2

Puncture port placement. (a) A 12-mm trocar is inserted through a transverse incision 1.0 cm above the navel to establish pneumoperitoneum and insert the laparoscope. (b) A left anterior axillary subcostal incision is created to accommodate the primary 12-mm trocar. (c) A left central clavicle incision is made 2.0 cm above the navel to accommodate an auxiliary 5-mm trocar. (d) A right central clavicle incision is made 20 mm above the navel to accommodate a 12-mm trocar for the assistant's instruments. (e) A right anterior axillary subcostal incision is made to accommodate a 5-mm trocar. (f) An incision is made 2.0 cm below the xiphoid process to accommodate a 5-mm trocar that is used to expose the left liver lobe.

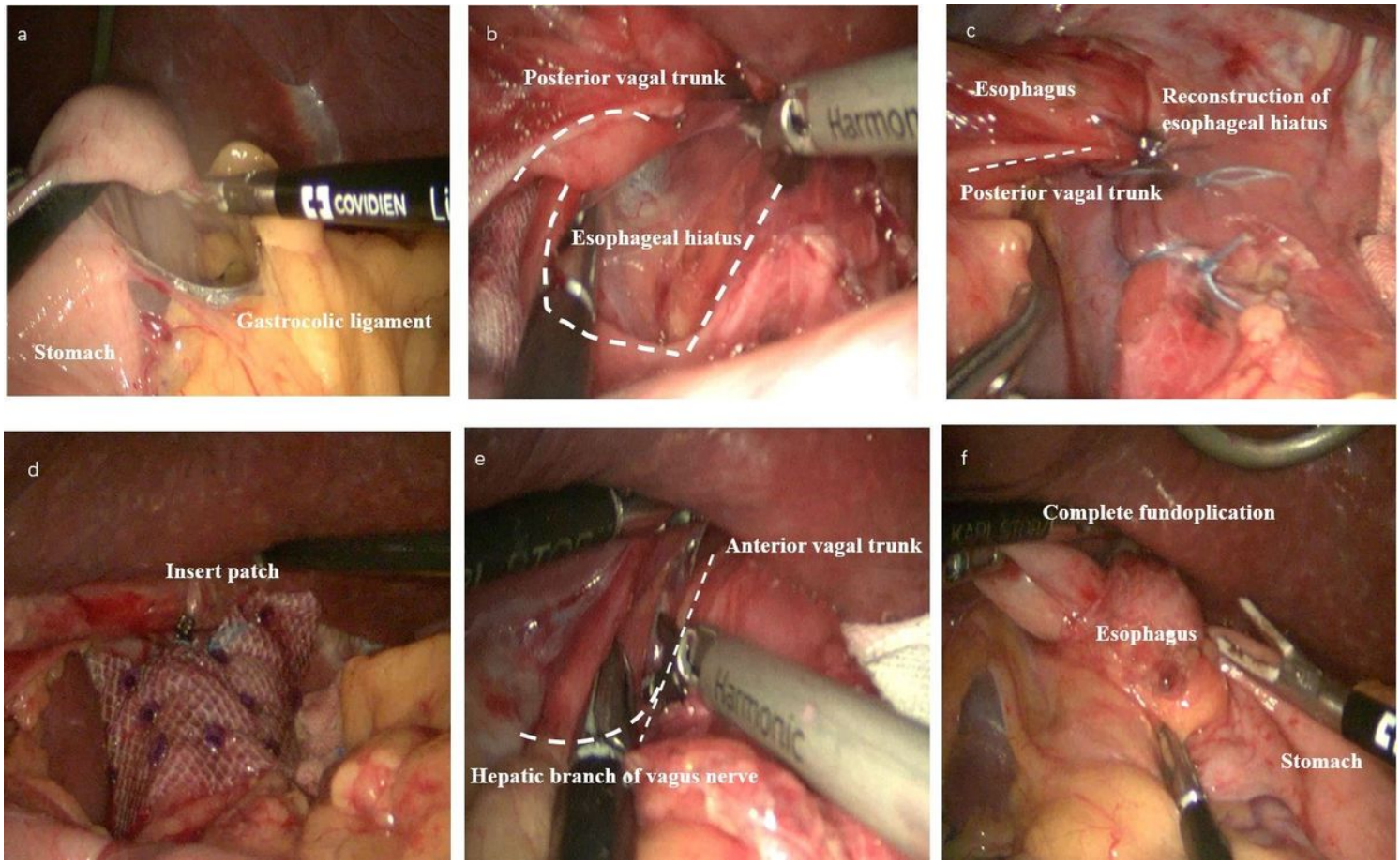

Figure 3

Operative technique. (a) On the stomach's greater curvature, the gastrocolonic ligament is incised along the avascular area between the left and right gastric omentum vessels, and the gastric fundus is lifted vertically toward the cardia to protect the vagus nerve. (b) The cardia, lower esophagus, and diaphragm are exposed, and the confluence of the left and right crus of the diaphragm is revealed. The retroperitoneum is incised at the left and right crus of the diaphragm, and the lower esophagus is dissociated for approximately 3–5 cm. The gastric fundus and the posterior wall of the esophagus are fully dissociated from the upper spleen. (c) Non-absorbable intermittent sutures are used at the left and right crus of the diaphragm to reconstruct the esophageal hiatus (diameter: approximately 1.5 cm). (d) The surgeon inserts the mesh and fixes it to the crus of the diaphragm with staples. (e) A small incision (approximately 2–3 cm) is made above the bifurcation of the anterior vagal trunk and the hepatic branch of the vagus nerve. (f) The fundus of the stomach is rotated around the posterior aspect of the abdominal esophagus to the right anterior aspect of the esophagus, using intermittent non-absorbable sutures, and then fixed to the right crus of the diaphragm and the right side of the esophagus. The left side of the gastric fundus is also sutured to the anterior esophagus and the left crus of the diaphragm, which this avoids vagus nerve injury. Finally, the surgeon completes the fundoplication.

Figure 4

Anatomical characteristics of the anterior vagal trunk. (a) The anterior vagal trunk travels from the upper left to the lower right of the anterior esophageal wall (red dotted line). (b) It is located between the muscular layer and the peritoneum of the anterior abdominal esophageal wall, where it is closely adhered to the

muscular layer of the esophagus (red dotted line).

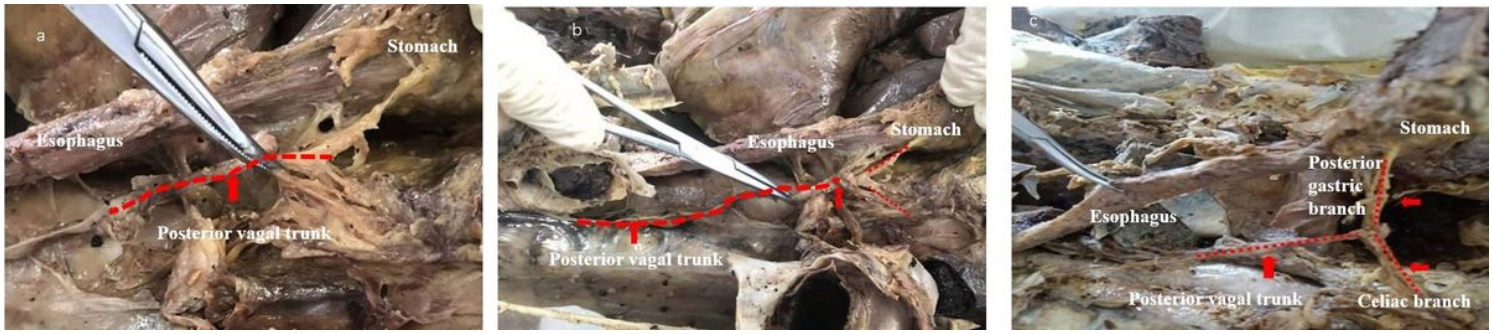

Figure 5

Anatomical characteristics of the posterior vagal trunk. (a) The posterior vagal trunk is generally thicker than the anterior trunk and travels in the loose tissue outside the muscular layer of the right posterior wall of the abdominal esophagus (red dotted line). (b) The posterior vagal trunk produces nerve branches below the cardia (red dotted line) and (c) the celiac branch and posterior gastric branch (red dotted line).

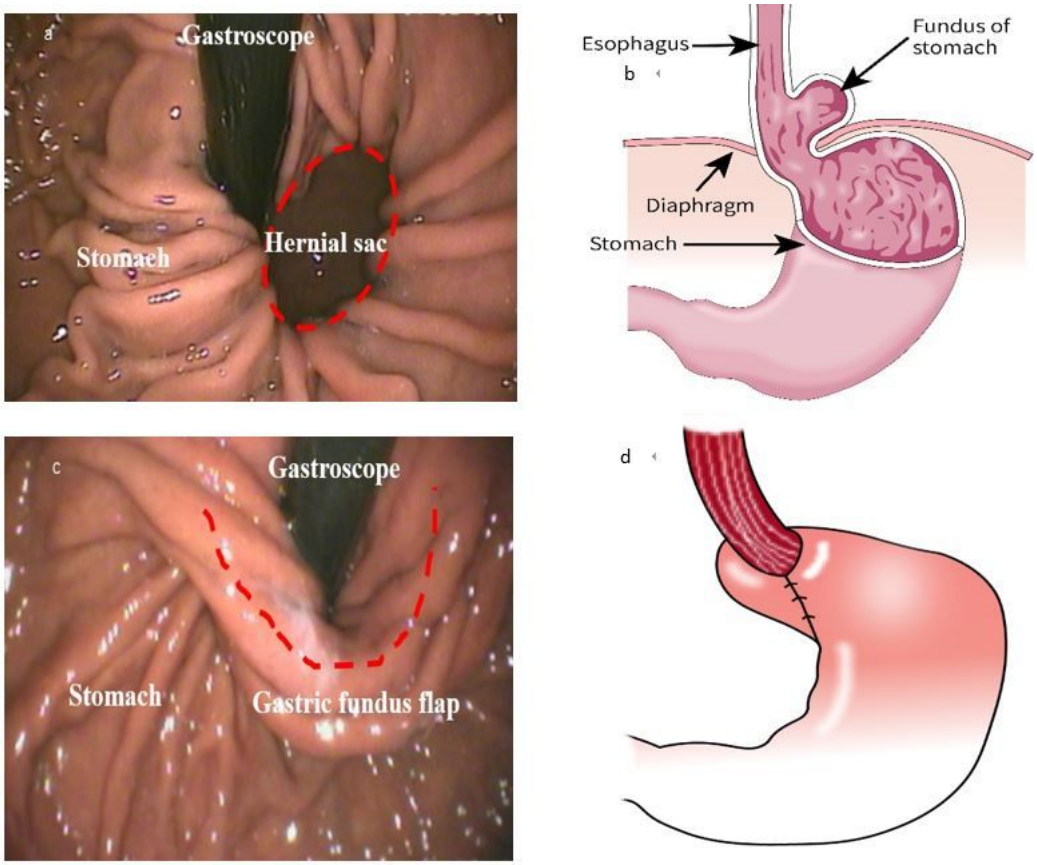

Figure 6

Comparing the findings from gastroscopy before and 6 months after the procedure. (a) Preoperative gastroscopy reveals a large hernia sac (red dotted circle) protruding into the chest. (b) A schematic diagram of the hiatal hernia. (c) The hernia sac disappeared after Nissen fundoplication and the gastric fundus flap was visible (red dotted line). (d) A schematic diagram showing the results of the Nissen fundoplication.

Supplementary Files

This is a list of supplementary files associated with this preprint. Click to download.

- 10.CONSORT2010Checklist.doc