Bone Bruises of the Ankle and Mid-foot Often Associate with Ankle Sprain

Hidefumi Koiwai
Koiwai Clinic
Mikio Kamimura
Kamimura Clinic
Akira Taguchi
Matsumoto Shika Daigaku
Keiji Tensho
Shinshu Daigaku
Yukio Nakamura (yxn14@aol.jp)
Shinshu University School of Medicine
Jun Takahashi
Shinshu Daigaku

Case report

Keywords: ankle sprain, magnetic resonance imaging, bone bruises

Posted Date: October 9th, 2020

DOI: https://doi.org/10.21203/rs.3.rs-68756/v1

Abstract

Background: Ankle sprains are one of the most common musculoskeletal injuries. However, they may be more serious than commonly believed since many patients reportedly experience chronic problems afterwards. It is necessary to improve the treatment, such as the method and duration of fixation, of sprained ankles.

Methods: Magnetic resonance imaging of 70 patients with acute moderate or advanced ankle sprains presenting consecutively between November 2014 and December 2019 were reviewed for analysis of bone bruising associated with ankle sprains. The patients were treated conservatively with a solid splint or cast until walking pain could be resolved without external fixation. In cases with pain at the time of weight bearing after solid fixation, crutches were prescribed for pain relief. The fixation period ranged from 8 days to 72 days (mean: 29.5 days). Afterwards, 54.0% of patients had walking pain and required the use of crutches. The ankle joint pain disappeared after conservative treatment in all patients.

Results: The incidence of bone bruises detected by magnetic resonance imaging in the ankle and midfoot associated with ankle sprain was 81.4%. Bone bruises of the midfoot, including the tarsal bone and Chopart joint, were found in 34.3% of ankle sprains. Bone bruises of the talus were the most common, being present in 60% of ankle sprains. Bone bruises were also evident in the tibia (44.3%), the calcaneus (21.4%), and the tarsal bone (25.7%). There was a significant association between bone bruises of the talocrural joint surface and use of the crutches after fixation (P=0.041). Multiple regression analysis adjusted for age and gender revealed that bone bruises of the talocrural joint surface of the talus was a significant independent predictor of crutch use (P=0.045), with an odds ratio (95% confidence interval) of 3.03 (1.03-8.94).

Conclusion: Bone bruises of the ankle and midfoot are often present in ankle sprains. In moderate or advanced cases of ankle sprain, external solid fixation of both the ankle and midfoot should be performed. In cases with pain at weight bearing following solid fixation, crutches are advised for pain relief and proper ligament and bone healing.

Background

Ankle sprains are one of the most common musculoskeletal injuries. A recent systematic review and meta-analysis of ankle sprain cases revealed an estimated incidence rate of 11.6 per 1000 exposures and a prevalence of 11.9% [1]. The most frequent mechanism of ankle sprain is a combination of inversion and adduction of the foot in plantar flexion, which can cause damage to the lateral ankle ligaments.

The aims of ankle sprain treatment are to manage pain and protect joint function. Hubbard et al. reported rigid immobilization of the ankle as an effective means to help restore ankle joint stability [2]. In the acute phase of healing, the most important structures that should be protected are the lateral ligaments of the ankle because the traumatic mechanism has caused laxity [2]. However, many studies have shown that ankle sprains are more serious than commonly believed since patients can develop chronic problems

after the injury [3, 4, 5], including chronic pain, recurrent swelling, and chronic instability [3, 4]. Konradsen et al. reported that 32% of patients had chronic problems after 7 years in an observational study of 648 individuals with an ankle sprain [6]. Since numerous symptoms may appear after treatment, it is necessary to improve the methods and/or fixation period in the treatment of sprained ankles.

The midtarsal joint has been shown to be damaged at the same time of ankle sprain.Isolated midtarsal sprains reportedly occur in only 5.5% of ankle sprains, suggesting they are rare [7]. On the other hand, some reports indicate they are more common, occurring in up to 33% of inversion ankle injuries [8]. In general, however, midtarsal sprains are not recognized as commonly associated with ankle sprains [7, 9, 10].

Pure ligament injuries of the ankle do not usually cause joint pain at the time of weight bearing if rigid fixation, such as with a plaster cast, is applied appropriately. However, in the clinical setting, casting sometimes causes joint pain during weight-bearing gait. This fact suggests that ankle sprains may include injuries of not only the ligaments of the ankle, but also other structures around the ankle.

Recently, many researchers have focused on the association of bone bruises with joint disease. Some reports have proposed that the pathophysiology of osteoarthritis (OA) and associated joint pain may be microfractures or other bone alterations based on radiographic and magnetic resonance imaging (MRI) findings [11, 12, 13]. Bone bruises related to ankle sprains have also appeared in the literature [14, 15, 16]. Patients with moderate or advanced ankle sprains are treated conservatively at our institutions and are routinely examined by MRI of the bones around ankle, including the forefoot. This study assessed the regions around the ankle joint using MRI for signal changes in the peripheral bones as well as the midfoot.

Methods

Our standard treatment policy for ankle sprains is fixation with a flexible soft supporter for mild cases and fixation from the leg to the forefoot with a solid splint or cast for moderate or advanced cases. Seventy patients who were diagnosed as having a moderate or advanced ankle sprain presenting consecutively between November 2014 and December 2019 were included in this study. The bones around the ankle and forefoot were examined using MRI. The patients were treated conservatively using a solid splint or cast until the absence of walking pain without external fixation. In cases of pain at the time of weight bearing after solid fixation, one or a pair of crutches were prescribed for pain relief. Patients having a slight sprain were excluded from this study and treated conservatively using a soft splint.

The cohort included 37 males and 33 females. Mean age (range) was 32.5 years (10–93 years). The right and left ankles were involved in 32 patients and 38 patients, respectively. The rate of ankle sprain due to sports was 57.1%. The period from trauma to the first visit ranged from 0 days to 16 days (mean: 2.2 days). The period from trauma to MRI examination ranged from 3 days to 28 days (mean: 11.1 days). Sixty-seven patients were treated with a splint and three patients received a cast. After fixation, 54.0% of patients had residual walking pain and required the use of crutches. The fixation period of 4 cases were

unknown. Three cases were dropped out after MRI examination. About the remaining 63 cases, fixation period ranged from 8 days to 72 days (mean: 29.5 days). The remaining 67 cases, ankle joint pain disappeared after conservative treatment.

MRI was performed using a 1.5 T unit (Siemens Symphony TIM; Siemens) with an extremity coil around the ankle. The patient's foot was held in a relaxed position with slight plantar and external rotation. The MRI acquisition parameters for T1-weighted imaging of sagittal views were TR: 661 (SI), FA: 150 (SI), and TE: 12 (SI). Those of coronal views were TR: 500 (SI), FA: 150 (SI), and TE: 12 (SI). Those of axial views were TR: 500 (SI), FA: 150 (SI), and TE: 12 (SI).

The MRI acquisition parameters for short τ inversion recovery (STIR) imaging of sagittal views were TR: 4000 (SI), FA: 150 (SI), TE: 96 (SI), and TI: 150 (SI). Those of coronal views were TR: 4640 (SI), FA: 150 (SI), TE: 83 (SI), and TI: 150 (SI). Those of axial views were TR: 4500 (SI), FA: 150 (SI), TE: 79 (SI), and TI: 160 (SI).

Regions displaying high signal intensity in STIR and low signal intensity in T1-weighted imaging were carefully evaluated by two independent board-certified orthopedic surgeons and one radiologist. Bone signal intensity was usually judged as present in the bone when alterations were detected by both imaging modalities. For evaluating small-bone signal changes, signal intensity was judged using STIR alone. Finally, two independent board-certified orthopedic surgeons evaluated the MRI findings. Consensus was reached by discussion for any discrepancies between the observers.

This study was approved by the Institutional Ethics Committee of Shinshu University School of Medicine. Written informed consent was obtained from all patients.

Statistical analysis

Univariate regression analysis was first performed to evaluate the association between bone bruises detected by MRI and use of the crutches after fixation. For bone bruises in which a significant association was observed in univariate analysis, multivariate logistic regression analysis with forward selection adjusted for age and gender (binary) was used to calculate the odds ratio (OR) and 95% confidence interval (CI) of having bone bruises detected by MRI according to the use of the crutches (yes). Data were analyzed using the Statistical Package for the Social Sciences (SPSS, version 22.0; IBM Inc., Chicago, IL, USA). P-values of < 0.05 were considered statistically significant.

Results

The incidence of bone bruises detected by MRI in the ankle and midfoot associated with ankle sprain was 81.4%. Lesions were predominant in the inside ankle foot and weight-bearing areas. Bone bruises of the midfoot, including the tarsal bone and Chopart joint, were found in 34.3% of ankle sprains.

Bone bruises were observed in the tibia in 44.3% of cases. The incidence of bone bruises of the lateral malleolus was 11.4%, whereas that of the medial malleolus was 32.9%. Relatively more bone bruises were observed in the joint surface of the ankle joint. However, bone bruises of the joint surface of the tibial weight-bearing area were comparatively infrequent at 11.4% (Table 1).

Table 1
Number of subjects (% subjects) and P-value in univariate analysis

Area		P-value
All areas	57 (81.4%)	0.97
Fibula (Lateral malleolus)	8 (11.4%)	0.80
Intraosseous area	4 (5.7%)	0.23
Joint surface	7 (10.0%)	0.52
Tibia	31 (44.3%)	0.69
Weight-bearing area (Talocrural joint)	8 (11.4%)	0.80
Non-weight-bearing area	11 (15.7%)	0.99
Attachment area of the anterior inferior tibio-fibular ligament	8 (11.4%)	0.62
Posterior horn	5 (7.1%)	0.79
Medial malleolus	23 (32.9%)	0.20
Joint surface	13 (18.6%)	0.97
Intraosseous area	16 (22.9%)	0.34
Talus	42 (60%)	0.38
Intraosseous area	6 (8.6%)	0.053
Joint surface	38 (54.3%)	0.76
Weight-bearing area	27 (38.6%)	0.19
Talocrural joint	20 (28.6%)	0.041
Talocalcaneal joint	14 (20.0%)	0.81
Non-weight-bearing area	29 (41.4%)	0.90
Lateral joint	5 (7.1%)	0.11
Medial joint	22 (31.4%)	0.63
Chopart joint	11 (15.7%)	0.99
Posterior tubercle	5 (7.1%)	0.23
Calcaneus	15 (21.4%)	0.62
Joint surface	10 (14.3%)	0.70

weight-bearing area (talocalcaneal joint)	6 (8.6%)	0.52
Non-weight-bearing area (Chopart joint)	8 (11.4%)	0.62
Saddle-shaped area	3 (4.3%)	0.66
Intraosseous area	2 (2.9%)	0.90
Tarsal bones	18 (25.7%)	0.90
Inner row of bones	9 (12.9%)	0.42
Navicular	9 (12.9%)	0.42
Three cuneiforms	2 (2.9%)	0.90
Outer row of bones Cuboid	14 (21.4%)	0.93
Cuboid(Chopart joint)	11 (15.7%)	0.50
Cuboid(Lisfranc joint)	10 (14.3%)	0.096

Appearing in 60% of ankle sprains, bone bruises of the talus were observed the most frequently. The incidence of bone bruises of the joint surface of the talus, including the weight- and non-weight-bearing areas, was high at 54.3%. In the weight-bearing area of the talus, the incidence of bruises of the joint surface in the ankle, the joint surface in the talocalcaneal joint, and the internal bones of the talus was 38.6%, 20.0%, and 8.6%, respectively (Table 1).

The incidence of bone bruises of the calcaneus was 21.4% and less than that of the talus. Similarly to the talus, calcaneous bone bruises were frequently found at the joint surface (Table 1).

Bone bruises of the tarsal bone were observed in 25.7% of ankle sprains. As the tarsal bones were small, it was impossible to distinguish between articular surface and intraosseous injuries. The incidence of bone bruises in the inner row of bones consisting of the navicular and three cuneiforms was 12.9%, while that in the outer row of bones containing the cuboid was 21.4% (Table 1).

Kissing lesions were confirmed in 34.3% of joint surface injuries and in 27.1% of non-weight-bearing areas. It was noteworthy that weight-bearing area kissing lesions were confirmed in the talocalcaneal joint in 7.1% cases and in the talocrural joint in 5.7% of cases; in weight-bearing areas, it is assumed that axial forces cause joint surface injuries, while in non-weight bearing areas, it is presumed that twisting forces cause kissing lesions.

Univariate analysis revealed a significant association between bone bruises of the talocrural joint surface and the use of the crutches after fixation (P = 0.041). Crutch use after fixation also tended to associate

with bone bruises within the intraosseous area of the talus (P = 0.053) and in the Lisfranc joint of the cuboid (P = 0.096) (Table 1).

Multiple regression analysis adjusted for age and gender revealed that having bone bruises of the talocrural joint surface of the talus detected by MRI was a significant independent predictor of crutch use (P = 0.045), with an OR (95% CI) of 3.03 (1.03–8.94) (Table 2).

Table 2
Significant items in multivariate analysis(modified odds ratio by age and gender)

Area	Cases requiring the use of crutches
Intraosseous area of the talus	NS
Talocrural joint of the talus	3.03 (1.03–8.94) P = 0.045
Lisfranc joint of the tarsal bones	NS
NS: Not signifcant	

Case Presentation

Case 1

A 16-year-old male presented with right ankle and foot pain. Tenderness and swelling on the lateral side of the ankle was observed. He was injured while landing from a jump during basketball three days prior. Treatment consisted of cast fixation for 42 days. Afterwards, he had no walking pain and did not require crutches. MRI was taken 13 days after the injury (Fig. 1).

Case 2

A 26-year-old male presented with right ankle and foot pain. Tenderness and swelling on the lateral side of the ankle was noted. He had tripped on a step earlier that day and was injured. Treatment consisted of splint fixation for 18 days. Afterwards, he had walking pain and required the use of crutches. MRI was performed 10 days after the injury (Fig. 2A, B).

Case 3

A 10-year-old female presented with left ankle and foot pain. Tenderness, swelling, and a subcutaneous hematoma from the lateral side of the ankle to the back of the foot were observed. She had fallen while

running that day. She received splint fixation for 65 days. Afterwards, she had no walking pain and did not require crutches. MRI was performed 12 days after the injury (Fig. 3A, B, and C).

Discussion

In this MRI-based study of moderate and severe ankle sprains, bone bruises were observed in as many as 81.4% of patients. The bruises were widespread, often on weight-bearing areas as well as the midfoot. Low-intensity findings on T1-weighted imaging and high-intensity findings on T2-weighted imaging usually imply bone marrow edema or hemorrhage. These results are not specific to bone fractures, although Yao and Lee have described that occult or microfractures can be detected on T2-weighted imaging [17]. Karthiga et al. reported that MRI was helpful to identify bone marrow edema as a sign of recent fracture at the injury site [18]. Guermazi et al. recently reviewed that MRI signal changes (i.e., bone bruises) in joints sometimes suggested a microfracture, which could be a cause of OA [11]. In this study, bone bruises were frequently observed, and might be similar to the microfractures witnessed in OA.

Pure ligament injuries do not usually cause joint pain by weight bearing if rigid fixation of the ankle, such as casting, is performed properly. In this study, 38 of 70 patients (54.0%) complained of ankle joint pain at weight bearing even following external solid fixation. Univariate analysis revealed a significant association between bone bruises of the talocrural joint surface and use of the crutches after fixation ($P = 0.041$). Furthermore, multiple regression analysis uncovered that the OR (95% CI) of having bone bruises of the talocrural joint of the talus in relation to the use of the crutches was 3.03 (1.03–8.94). Therefore, in the treatment of ankle sprain, if the patient complains of joint pain even after solid fixation, it may be necessary to avoid weight bearing by means of crutches to ensure bone damage recovery. Furman et al. reported that post-traumatic arthritis (PTA) was one of the most frequent causes of ankle joint OA in America and suggested the major mechanism in PTA development to be cartilage fracture [19]. In the present study, bone bruises of the weight-bearing surface of the talus were significantly associated with crutch use due to pain during weight bearing ($P = 0.041$). Although it is not possible to judge cartilage damage using MRI, it is feasible that micro-fractures of joint surfaces have cartilage fractures. Therefore, crutches may be advised to prevent PTA in patients with pain at weight bearing even after solid fixation of the ankle.

Various fixation periods have been proposed for the external fixation of ankle sprains, ranging from short- to long-term. A short period of immobilization was shown to be advantageous even for severe ankle sprains [20, 21]. A meta-analysis by Kerkhoffs et al. found that functional treatment appeared to be a favorable strategy for treating acute ankle sprains when compared with long-term immobilization [22]. Conversely, other reports described that fixation of over 6 weeks was needed for proper ligament healing [23, 24, 25], and Hubbard and Cordova observed that ankle laxity did not significantly decrease during 8 weeks [26]. Such evidence indicated the need for more stringent and long-term immobilization for ligament healing and restoration of joint stability after an ankle sprain. In this study, the period of external fixation required to reduce pain varied from 8 days to 72 days (average: 29.5 days). Considering the wide range in degrees of bone and ligament damage, a large variation in the fixation period is expected. As this

period should be adjusted depending on the case, recommending a strictly set fixation period may be suboptimal.

The current study revealed that the incidence of bone bruises detected by MRI in the midfoot associated with ankle sprain was 34.3%. Since MRI could not evaluate ligament damage in the midfoot, we considered that damage to the midfoot may have been more prevalent if ligament damage was assessed and included. Lohrer et al. suggested that midtarsal sprains should be treated differently to ankle sprains, with more aggressive and longer immobilization [27]. Although various external fixation methods have been proposed for ankle sprains, fixing the midfoot is often overlooked. Fixation is often performed by limiting the range of immobilization to the ankle joint, restricting the lateral movement of the ankle joint, and preserving some ankle dorsiflexion and plantarflexion. In moderate or severe cases of ankle sprain, external fixation for not only the ankle, but also the midfoot, should be performed in consideration of the possibility of midfoot injury.

Lastly, as 57 of 70 patients (81.4%) in our cohort had bone bruises around the ankle joint, examination using MRI might be helpful for more accurate evaluation of ankle joint sprains. From the viewpoint of treatment, however, it appears important to presume the presence of both bone bruise and ligament injury in the ankle and midfoot and perform detailed visual inspection and palpation to pinpoint the area of the injured site. The affected area should then be fixed for an appropriate period. If pain develops with walking after fixation, crutches should be provided to reduce weight-bearing stress. Ultimately, MRI may not be necessary if such a treatment course is followed.

Limitations

Since the subjects in this study visited orthopedic clinics, the cohort might not have included very severe ankle sprains with more extensive bruising. Furthermore, the mean period of fixation in this investigation was 29.5 days; longer fixation might be necessary in severe cases.

Conclusions

Bone bruises not only of the ankle, but also the midfoot, were observed by MRI in the majority of cases of ankle joint sprain. This study revealed a statistically significant association between bone bruise of the talocrural joint surface and the use of the crutches after fixation (P=0.041). Multiple regression analysis also uncovered that bone bruise of the talocrural joint surface of the talus was a significant independent predictor of the use of the crutches, with an OR (95% CI) of 3.03 (1.03-8.94). In moderate or advanced cases of ankle sprain, an area of external solid fixation extending to the midfoot might be warranted. For residual pain at the time of weight bearing after solid fixation, one or a pair of crutches is recommended for pain relief and proper ligament and bone healing.

List Of Abbreviations

OA=osteoarthritis, MRI=magnetic resonance imaging, OR=odds ratio, CI=confidence interval, STIR=short τ inversion recovery, PTA=post-traumatic arthritis

Declarations

Ethics approval and consent to participate

Informed consent was obtained from all patients for publication of this study and any accompanying images.

Consent for publication

Written informed consent was obtained from all patients for publication of this study and any accompanying images.

Availability of data and materials

The datasets analyzed during the current study are available from the corresponding author upon reasonable request.

Competing interests

Hidefumi Koiwai, Mikio Kamimura, Akira Taguchi, Keiji Tensho, Yukio Nakamura, and Jun Takahashi all declare that they have no conflicts of interest.

Funding

None.

Authors' contributions

MK and HK directed and designed this study. HK and MK wrote the main text. AT analyzed the data. AT, KT, YN, and JT gave suggestions on this study. All authors have read and approved the final manuscript.

Acknowledgements

Not applicable.

References

1. Doherty C, Delahunt E, Caulfield B, Hertel J, Ryan J, Bleakley C. The incidence and prevalence of ankle sprain injury: a systematic review and meta-analysis of prospective epidemiological studies. Sports Med (Auckland, NZ). 2014;44(Suppl 1):123–40.
2. Tricia J Hubbard, Erik A Wikstrom Ankle sprain: pathophysiology, predisposing factors, and management strategies. Open access journal of sports medicine. 2010 Jul 16;1:115-22.
3. Gerber JP, Williams GN, Scoville CR, Arciero RA, Taylor DC (1998) Persistent disability associated with ankle sprains: a prospective examination of an athletic population. Foot Ankle Int 19(10):653–660
4. Van Rijn RM, Van Os AG, Bernsen RMD, Luijsterburg PA, Koes BA, Bierma-Zeinstra SMA (2008) What is the clinical course of acute ankle sprains? A systematic literature review. Am J Med 121:324–331
5. Verhagen RA, de Keizer G, van Dijk CN (1995) Long-term follow-up of inversion trauma of the ankle. Arch Orthop Trauma Surg 114(2):92–96
6. L Konradsen, L Bech, M Ehrenbjerg, T Nickelsen. Seven years follow-up after ankle inversion trauma. Scandinavian journal of medicine & science in sports. 2002 Jun;12(3):129-35 (Konradsen L et al.2002)
7. Lohrer H, Nauck T. Augmented periosteal flap repair of the chronically unstable calcaneocuboid joint: a series of six cases. J Bone Joint Surg Am2006; 88:1596–1601
8. Søndergaard L, Konradsen L, Holmer P, Jorgensen LN, Nielsen PT. Acute midtarsal sprains: frequency and course of recovery. Foot Ankle Int 1996; 17:195–199
9. Andermahr J, Helling HJ, Maintz D, Monig S, Koebke J, Rehm KE. The injury of the calcaneocuboid ligaments. Foot Ankle Int 2000; 21:379–384
10. Lohrer H, Nauck T, Arentz S, Vogl TJ. Dorsal calcaneocuboid ligament versus lateral ankle ligament repair: a case-control study. Br J Sports Med 2006; 40:839–843
11. Guermazi, A. et al. MRI-based semiquantitative scoring of joint pathology in osteoarthritis. Nat Rev Rheumatol. 9, 236–251 (2013).
12. Komatsu M, Kamimura M, Nakamura Y, Mukaiyama K, Ikegami S, H Masanori, Uchiyama S, and Kato H. Bony findings detected by MRI may reflect the pathophysiology of osteoarthritis with thumb carpometacarpal joint pain. International Journal of Rheumatic Diseases. 2017 Dec;20(12);1950-1957.
13. Nakamura Y, Uchiyama S, Kamimura M, Komatsu M, Ikegami S, Kato H. Bone alterations are associated with ankle osteoarthritis joint pain. Scientific Reports 2016 Jan 18;6;18717.
14. Umile Giuseppe Longo, Mattia Loppini, Giovanni Romeo, C Niek van Dijk, Nicola Maffulli, Vincenzo Denaro. Bone bruises associated with acute ankle ligament injury: do they need treatment? Knee surgery, sports traumatology, arthroscopy : official journal of the ESSKA. 2013 Jun;21(6);1261-8. doi: 10.1007/s00167-013-2383-5.
15. V O Chan, D E Moran, S Shine, S J Eustace. Medial joint line bone bruising at MRI complicating acute ankle inversion injury: what is its clinical significance? Clinical radiology. 2013 Oct;68(10); e519-23.

doi: 10.1016/j.crad.2013.05.093.

16. H Pinar, D Akseki, I Kovanlikaya, S Araç, M Bozkurt. Bone bruises detected by magnetic resonance imaging following lateral ankle sprains. Knee surgery, sports traumatology, arthroscopy : official journal of the ESSKA. 1997;5(2);113-7.
17. Yao L, Lee JK. Occult intraosseous fracture: detection with MR imaging. Radiology 1988; 167: 749-51.
18. Karthiga S, Dubey S, Garber S, Watts R. Scurvy: MRI appearance. Rheumatology (Oxford). 2008; 47: 1109.
19. Furman, B. D., Olson, S. A. & Guilak, F. The development of posttraumatic arthritis after articular fracture. J Orthop Trauma. **20,** 719–25 (2006).
20. Carl G Mattacola, Maureen K Dwyer. Rehabilitation of the Ankle After Acute Sprain or Chronic Instability.Journal of athletic training. 2002 Dec;37(4):413-429.
21. Wolf Petersen, Ingo Volker Rembitzki, Andreas Gösele Koppenburg. Treatment of acute ankle ligament injuries: a systematic review.Archives of orthopaedic and trauma surgery. 2013 Aug;133(8);1129-41. doi: 10.1007/s00402-013-1742-5.
22. G M M J Kerkhoffs, B H Rowe, W J J Assendelft, K Kelly, P A A Struijs. Immobilisation and functional treatment for acute lateral ankle ligament injuries in adults. The Cochrane database of systematic reviews. 2002;(3):CD003762.
23. Freeman MAR. Treatment of ruptures of the lateral ligament of the ankle. J Bone Jt Surg. 1965;47B:661–668.
24. Konradsen L, Holmer P, Sondergaard L. Early mobilizing treatment for grade III ankle ligament injuries. Foot and Ankle. 1991;12:69–73.
25. Brostrom L. Sprained ankles V. Treatment and prognosis in recent ligament ruptures. Acta Chir Scand. 1966;132:537–550.
26. Hubbard TJ, Cordova ML. Mechanical Instability after an Acute Lateral Ankle Sprain. Arch Phys Med Rehabil. 2009;90:1142–1146.
27. Lohrer H, Arentz S. Calcaneocuboid joint instability: a novel operative technique for anatomic Foot Ankle Int 2004; 25:349–356.

Figures

Figure 1

Right foot of a 16-year-old male. Coronal STIR image shows a bone bruise in the joint surface of the lateral malleolus (arrow) and from the joint surface to the intraosseous area of the medial malleolus (arrowhead).

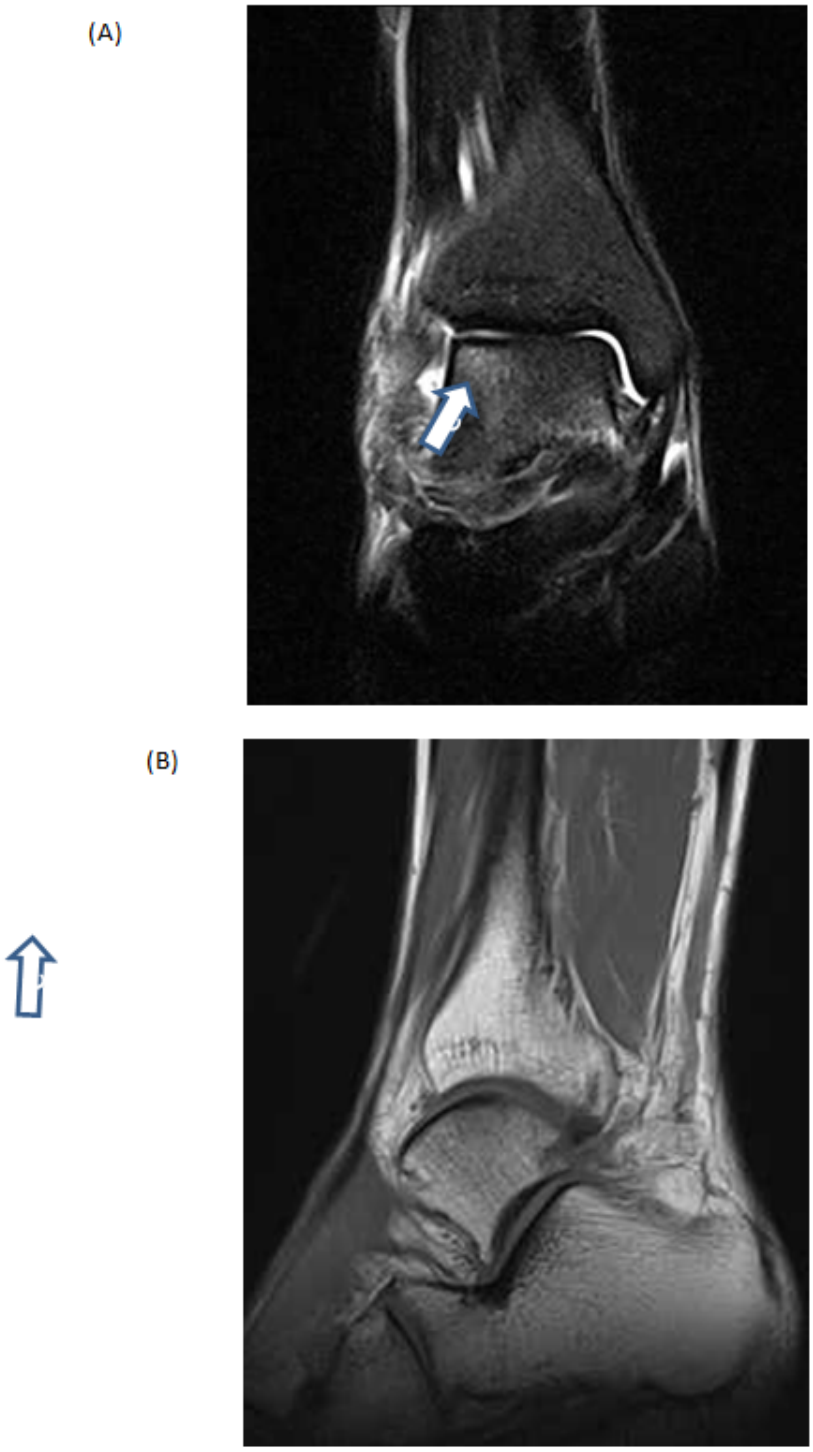

Figure 2

Right foot of a 26-year-old male. A) Coronal STIR image shows a bone bruise in the joint surface of the lateral side of the talocrural joint (arrow). B) Sagittal T1-weighted image shows a bone bruise in the joint surface of the center of the talocrural joint (arrow).

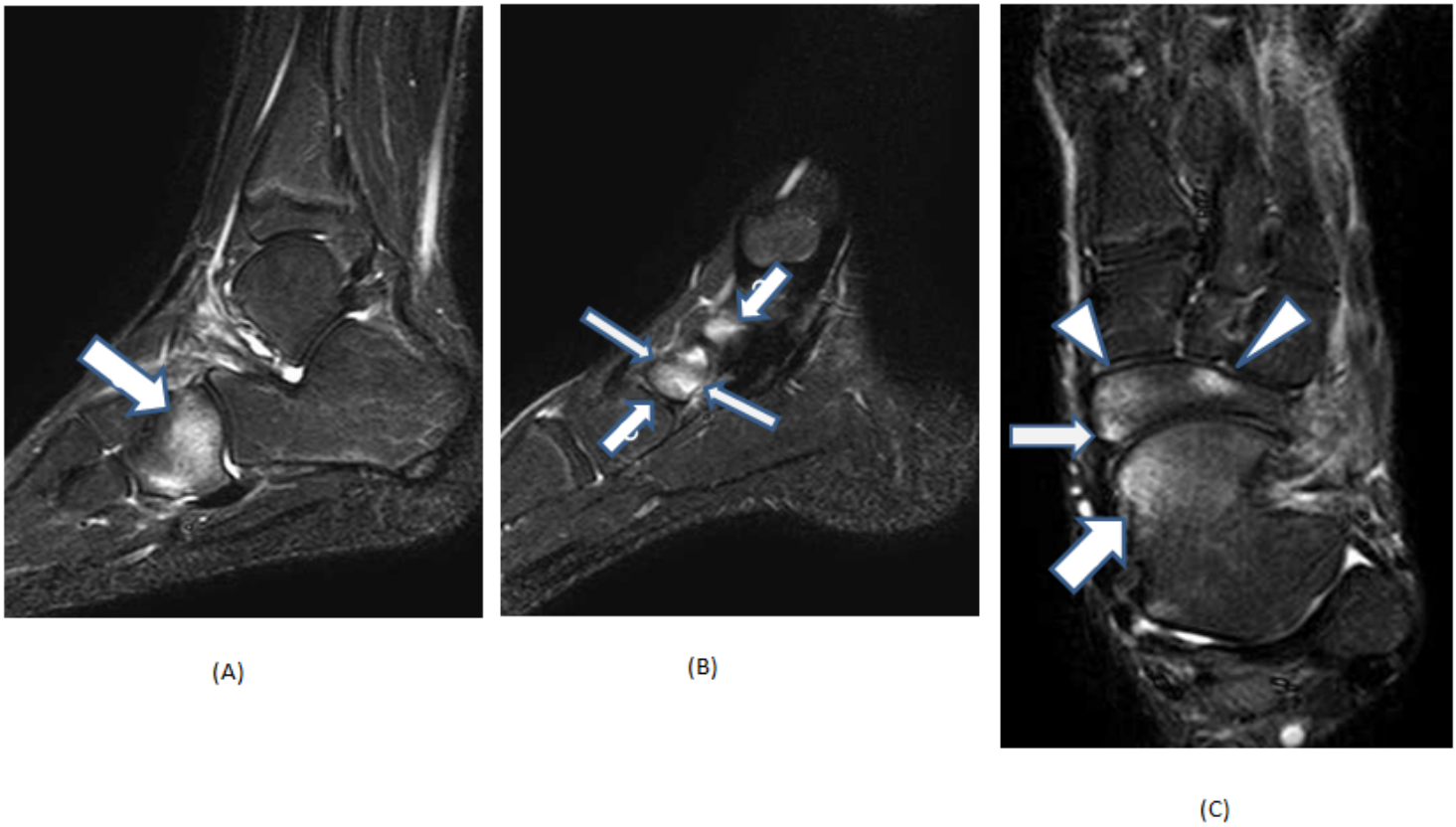

Figure 3

Left foot of a 10-year-old female. A) Sagittal STIR image shows a bone bruise in the joint surface of the calcaneocuboid joint and the metatarsocuboid joint of the cuboid bone (arrow). B) Sagittal STIR image shows bone bruises in the joint surface of the cuneonavicular joint of the navicular (thin arrows), the joint surface of the talonavicular joint of the navicular bone (thick arrow), and the talus (arrowhead). C) Axial STIR image shows bone bruises in the joint surface of the talonavicular joint of the navicular bone (thin arrow), the talus (thick arrow), and the joint surface of the cuneonavicular joint of the navicular (arrowheads).

Supplementary Files

This is a list of supplementary files associated with this preprint. Click to download.

- renamed9c1a1.docx