Improved Access in Minimally Invasive Temporomandibular Joint Surgery via A Novel Endaural Template

Matthias Krause
Leipzig University: Universitat Leipzig
Mohammad Kamal
Kuwait University
Daniel Kruber
HTWK Leipzig: Hochschule fur Technik Wirtschaft und Kultur Leipzig
Dirk Halama
Leipzig University: Universitat Leipzig
Thomas Hierl
HELIOS Vogtland-Klinikum Plauen
Bernd Lethaus
Leipzig University: Universitat Leipzig
Alexander K. Bartella (alexander.bartella@medizin.uni-leipzig.de)
Leipzig University: Universitat Leipzig https://orcid.org/0000-0002-3545-1341

Methodology

Keywords: TMJ surgery, template, endaural template, minimally invasive temporomandibular joint surgery

Posted Date: September 9th, 2020

DOI: https://doi.org/10.21203/rs.3.rs-68788/v1

Abstract

Background: Digitally designed surgical templates for minimally invasive temporomandibular joint (TMJ) surgery (MITMJS) are a promising tool for improving the safety in these procedures. Given the anatomy of the TMJ, the fitting of the template and intraoperative overview are the most important issues to conduct the surgery safely. This article describes an endaural surgical template based on the Moses approach as a possible solution.

Material and Methods: Three patients with internal derangement were treated with guidance of a MITMJS- template based on cone beam computed tomography (CBCT) and a surface imprint of the periauraural region. None of the patients needed an additional open surgical procedure. Fitting of the templates was judged in terms of position and rotational stability. Surgical side effects and complications were recorded for each patient.

Results: The template design and clinical use performed the MITMJS satisfactory. The templates showed satisfying fit and good visibility. In the study cohort, no bleeding, facial nerve injury, or other complications occurred after the procedure, and no visible scars were noted postoperatively.

Conclusion: Our feasibility report on template-guided MITMJS shows a promising new application of templates. It points an improved access in arthroscopy or arthrocentesis of TMJ- surgery via an endaural access with increased level of safety during surgery.

Introduction

The advocation of minimally invasive approaches to temporomandibular joint (TMJ) surgery was first published in 1975 [1]. Proposed advantages of such controlled access include lower surgical morbidity, faster surgical recovery, and a decreased chance of complications, such as facial nerve injury, bleeding, perforation of the external acoustic meatus or the articular cavity are described in previous studies. [1–3] However, proper conduction of minimally invasive treatment requires advanced level of expertise in the field of minimally invasive temporomandibular joint surgery (MITMJS). To simplify and standardize the approach, we have previously described the use of a computer aided designed and computer aided manufactured (CAD-CAM) template for TMJ-surgery in 2019, yet several modifications have been proposed to this promising technology. [4] Most of the described modifications require a 3D imaging (e.g. CT, cone beam CT, MRI) of the corresponding TMJ and the surrounding tissue, in addition to an optical three-dimensional (3D) scan of the face. Out of this data, a stereolithic template is designed. Given the anatomy of the TMJ, the fitting and unique placement of the template is of utmost importance to conduct the surgery safely.

For ensuring proper fitting of the 3D surgical template, several designs have been proposed. Some surgeons prefer extensions of the template to the zygomatic bone and the forehead, others rely on occlusal and dental stabilization methods. Each design has it own drawbacks, as the design may position the fixation out of the primary field of view of the surgeon, so if the template dislocates slightly,

this might go unnoticed, leading to fixations errors. Besides, dental fixation of the template may lead to an increased exposure to bacteria of the oral cavity. Another drawback in the currently described templates is that they are designed to be utilized only through the preauricular approach. This bares the risk of accidentally perforating the external acoustic meatus. Additionally, visualization and instrumentation of the lateral and medial joint landmarks might be difficult to handle due to anatomical limitations. This is a known surgical problem in arthroscopic TMJ-surgery, which was addressed by Moses and Poker in 1989 [5]. They described an enaural approach to the TMJ leading to increased field view and allowing for an improved surgical handling.

In our study, we evaluated the conductibility of TMJ surgery using a CAD/CAM based template through Moses' endural approach.

Material And Methods

Patients and selection

The study was approved by the Local Ethics Committee at Leipzig University Hospital following the Declaration of Helsinki on medical protocols and ethics (Eth-30/17, 12/06/2017). Three patients with the need of MITMS were included in the study from March to August 2020. Patients were diagnosed with an internal derangement (ID) of the TMJ, which was classified according the Wilkes classification system [6]. All patients underwent TMJ surgery using the guided endaural template. None of the patients needed additional open surgical procedure. Fitting of the templates were judged in terms of position and rotational stability. Surgical side effects and complications were recorded for each patient.

Template manufacturing

The production of an endaural template was conducted according to the following four steps:

1. First of all, a 3D data set of the patient`s skull had to be created. This was done via computed tomography (CT), cone beam computed tomography (CBCT), or magnetic resonance imaging (MRI). In our cohort, CBCT data sets were used (Kodak 9500 3D; Carestream Health, Toulouse, France).
2. In the second step, the surface imprint of the end- and preauricular region needed to be assessed. A precise acquisition was necessary for the template's position and rotational stability (Figure 1). The external acoustic meatus was used as a "key lock structure" and an impression has to be taken using silicone material (Omnisil; Omnident Dental, Rodgau, Germany). The transfer of the imprint to a digital model might be performed with an optical scanner or with a CBCT from the plaster model (Figure 2). Due to the availability of the device and ease of image fusion, the authors use a CBCT scan to create a 3D data set (Figure 3).
3. Next, the data sets need to be fused in a planning software (Facial Analysis Tool (FAT)). Now it was possible to create the template with two pilot channels for the endoscope and the manipulation instruments from the superior-posterolateral and endaural approach. The alignment was directed to the upper joint space (Figure 4).

4. Finally, the template was manufactured using a 3D printer (Formlab 2; Formlabs Inc., Somerville, USA),) and a CE certified biocompatible photopolymer resin (Dental SG Resin; Formlabs, Somerville, USA) (figure 5).

Surgical procedure

The surgical procedure was conducted under sedation or under general anesthesia. The template was positioned in the ear and the skin was marked through the pilot channel for the desired incision after insertion of the trocar. The template was temporarily removed and the subcutaneous tissue spread with a fine, point scissor. After the guide had been repositioned, while the mandible was distracted downward and forward, the anterior wall of the external auditory canal was perforated with the sharp trocar up to the capsule (endaural access). Next, the endoscope was inserted via the other pilot channel after marking and incising the skin likewise (figure 6). The authors preferred a 0° arthroscopic cannula for the procedures.

Results

Three patients with internal derangement of 3 joints were treated with template guidance. The mean age was 51 years. One patient was treated with a lavage followed with injections of platelet rich fibrin (PRF). One was suffering from Wilkes class II and the other from Wilkes class IV (Table 1). No bleeding, facial nerve injury, or other complications occurred after the procedure. The fitting of the template was satisfactory. It was stable in terms of positioning and rotation. The template workflow took additional 120 minutes.

Table 1
Patient data and performed surgical procedures (n = 3). It is shown the number of patients, gender, age, diagnosis, and procedure.

Gender	Age	Diagnosis	Wilkes stage	Procedure
Female	34	Internal derangement	II	arthroscopy, lavage, intra- articulary injection
Female	67	internal derangement	IV	
Male	52	internal derangement	IV	
Average	51			

Discussion

The results of the study lead us to suggest having this procedure as the preferred method for diagnosis in patients with TMJ disorders in our clinical practice. Minimally invasive surgery is widely utilized and sometimes regarded as the gold standard of treatment in several fields of medicine [7–9]. However, it is

difficult in TMJ surgery in particular due to the close proximity of anatomical structures. Several approaches are described in literature for minimal invasive temporomandibular joint (MITMJ) surgery. The major drawback of the common approaches from anterior are potential complications such as facial nerve injury or otic injury [10]. A solution to this problem was suggested by Moses et al. and their endaural approach to the TMJ [5].

Until now, this approach could not be transferred to a template. The major difficulties for transferring the pilot channels appeared the insufficient detection of the internal acoustic meatus by the face scanner which are used in planning, a problem that we also faced in the treatment process. To solve it, we used a silicone impression of the external meatus. It has the drawback, that the workflow is not entirely digital. However, the impression material can be easily digitalized and it leads to a perfect fit of the template. Until further improvement of 3D-scanning is achieved, it remains the only reliable option to capture the anatomical morphological details.

Another drawback of templates that was described in literature is the potential for intraoperative dislocation and loss of positional accuracy. Most templates are designed with wings which reach to the zygomatic bone or the forehead. However, given the elasticity of the skin and subdermal tissue, intraoperative dislocation might occur. Due to the design of the templates, dislocation might appear without the surgeon noticing it. Because of the anatomical proximity to neighboring structures, it potentially leads to accidental nerve or vessel injury or perforations of temporomandibular fossa or the acoustic meatus. The use of the external acoustic meatus as the locking structure for the template allows a reliable and solid fixation. Furthermore, the surgeon has the complete template in his/her field of vision to detect a potential dislocation.

From the surgical point of view, the Moses and Poker’s approach offers a safe and considerably easy approach to the mandibular joint. Described advantages, such as facial nerve protection, can be confirmed in template guided minimal invasive approach without visible scars. However, the study sample is quite small and certainly higher number of patients are needed to confirm these findings.

Conclusion

Our feasibility report on template-guided MITMJS shows a promising new application of templates. It proposes an improved and safe access in arthroscopy or arthrocentesis of temporo-mandibular joint surgery via a novel endaural template.

Declarations

Ethics approval and consent to participate

This study was approved by the Ethic Committee of the Berlin Medical Chamber (Eth-30/17, 12/06/2017). This report followed the Declaration of Helsinki on medical protocol and ethics.

Competing interests

The authors declare that they have no conflicts of interest.

Funding

The author did not obtain a funding for the conduction and/or presentation of the study.

Consent for publication

All authors consent for publication.

Availability of data and material

All data can be shared

Acknowledgements

Not applicable.

Authors contributions

All authors have reviewed the paper and contributed to the manuscript. M. Krause, D. Gruber and T. Hierl designed the template. M. Kamal, B. Lethaus and A. Bartella had a major role in study organization and draft writing.

References

1. Onishi M: **[Arthroscopy of the temporomandibular joint (author's transl)]**. *Kokubyo Gakkai Zasshi* 1975, **42**(2):207-213.
2. Gonzalez-Garcia R, Rodriguez-Campo FJ, Escorial-Hernandez V, Munoz-Guerra MF, Sastre-Perez J, Naval-Gias L, Gil-Diez Usandizaga JL: **Complications of temporomandibular joint arthroscopy: a retrospective analytic study of 670 arthroscopic procedures**. *J Oral Maxillofac Surg* 2006, **64**(11):1587-1591.
3. Gonzalez-Garcia R: **The current role and the future of minimally invasive temporomandibular joint surgery**. *Oral Maxillofac Surg Clin North Am* 2015, **27**(1):69-84.
4. Krause M, Dorfler HM, Kruber D, Humpfner-Hierl H, Hierl T: **Template-based temporomandibular joint puncturing and access in minimally invasive TMJ surgery (MITMJS) - a technical note and first clinical results**. *Head Face Med* 2019, **15**(1):10.
5. Moses JJ, Poker ID: **Temporomandibular joint arthroscopy: the endaural approach**. *Int J Oral Maxillofac Surg* 1989, **18**(6):347-351.
6. Wilkes CH: **Internal derangements of the temporomandibular joint. Pathological variations**. *Arch Otolaryngol Head Neck Surg* 1989, **115**(4):469-477.

7. Lin HF, Chen YD, Chen SC: **Value of diagnostic and therapeutic laparoscopy for patients with blunt abdominal trauma: A 10-year medical center experience**. *PLoS One* 2018, **13**(2):e0193379.
8. Lu Q, Qu H, Liu C, Wang S, Zhang Z, Zhang Z: **Comparison of Laparoscopy and Laparotomy in Surgical Staging of Apparent Early Ovarian Cancer: 13-year Experience**. *Medicine (Baltimore)* 2016, **95**(20):e3655.
9. Al-Juburi A, Granger S, Barnes J, Voeller G, Beech D, Amiri H, Abell TL: **Laparoscopy shortens length of stay in patients with gastric electrical stimulators**. *JSLS* 2005, **9**(3):305-310.
10. Soni A: **Arthrocentesis of Temporomandibular Joint- Bridging the Gap Between Non-Surgical and Surgical Treatment**. *Ann Maxillofac Surg* 2019, **9**(1):158-167.

Figures

Figure 1

The conventional imprint with polyvinylsiloxane. Detailed capture of the three-dimensional external meatus is possible.

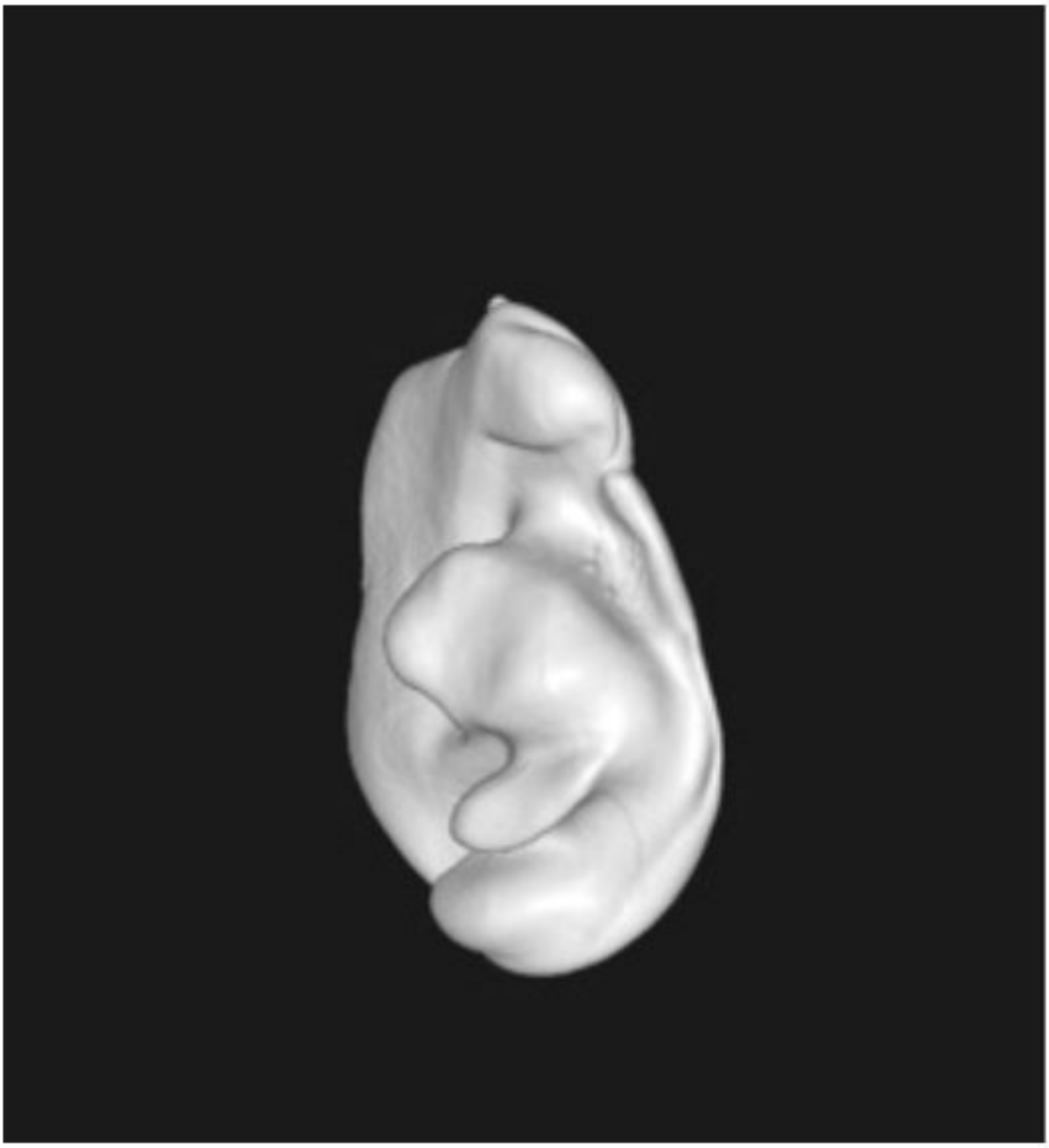

Figure 2

Converting the impression to a virtual three-dimensional data set that can be imported to planning software. In this case, a CBCT-scan was used.

Figure 3

Import of the previously generated 3D data set and design of the template. It was planned in FAT software. The view with skin surface is displayed.

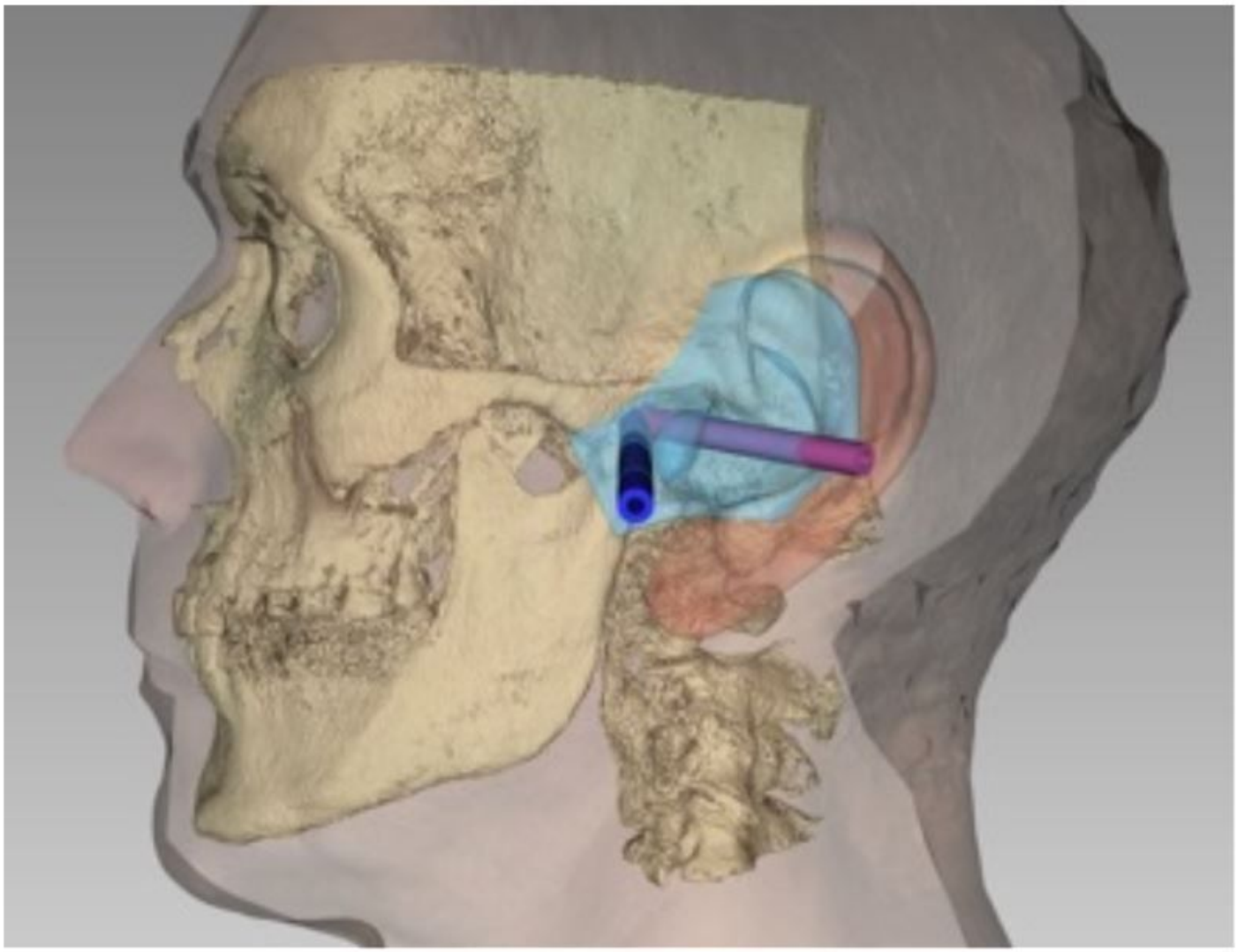

Figure 4

Planning the pilot channels in FAT software. View in bone surface and direction of the pilot channels. They end at the TMJ capsule.

Figure 5

The final template 3D printed. They are composed of biocompatible photopolymer resin.

Figure 6

Intraoperative situation after insertion of the printed template for arthroscopy. The endaural approach is marked with an * and the arthroscopic instruments are inserted via the pilot channel. The trocar for cannula or manipulations instruments is inserted via the posterolateral approach (#). The authors recommend a 0° angle for the optic.