Treatment of Distal Clavicle Fractures using a Scorpion Plate and Influence of Timing on Surgical Outcomes: A Retrospective Cohort Study of 105 Cases

Ryogo Furuhata (ryogo4kenbisha@gmail.com)
National Hospital Organization Tokyo Medical Center

Masaaki Takahashi
National Hospital Organization Tokyo Medical Center

Teppei Hayashi
National Hospital Organization Tokyo Medical Center

Miyu Inagawa
National Hospital Organization Tokyo Medical Center

Aki Kono
National Hospital Organization Tokyo Medical Center

Noboru Matsumura
Keio University School Of Medicine

Yasuhiro Kiyota
National Hospital Organization Tokyo Medical Center

Yusaku Kamata
National Hospital Organization Tokyo Medical Center

Akira Yoshiyama
National Hospital Organization Tokyo Medical Center

Hiroshi Arino
National Hospital Organization Tokyo Medical Center

Hideo Morioka
National Hospital Organization Tokyo Medical Center

Research article

Keywords: distal clavicle fracture, plate, Scorpion plate, outcome, complication, union, timing of surgery

Posted Date: October 21st, 2019

DOI: https://doi.org/10.21203/rs.2.16276/v1

Version of Record: A version of this preprint was published on March 4th, 2020. See the published version at https://doi.org/10.1186/s12891-020-3169-9.

Abstract

Background Plate fixation is the established method of treating unstable distal clavicle fractures. However, the appropriate timing of surgery for acute distal clavicle fractures remains unclear. The present study aimed to evaluate the clinical outcomes of osteosynthesis using a Scorpion plate and to assess the influence of surgery timing on the surgical outcomes for acute unstable distal clavicle fractures.

Methods We retrospectively reviewed 105 patients who underwent fixation for acute unstable distal clavicle fractures (Neer type II and V) using the Scorpion plate between 2008 and 2018. Patients were divided into early (45 patients) and delayed (60 patients) treatment groups based on the timing of the surgical intervention (within or after seven days). The outcomes were postoperative complications (delayed union, peri-implant fracture, plate loosening, plate-related pain, and stiffness). We evaluated the outcomes from X-ray radiographs and clinical notes.

Results Among the 105 patients, delayed union, plate loosening, plate-related pain, and stiffness were observed in six patients (5.7%), four patients (3.8%), seven patients (6.7%), and one (1.0%) patient, respectively. The delayed union rate was significantly higher in the delayed treatment group than that in the early treatment group (P=0.036). Although the difference was not significant, plate loosening and stiffness were only observed in the delayed treatment group.

Conclusion Our results demonstrated that osteosynthesis using Scorpion plates achieved satisfactory surgical outcomes for unstable distal clavicle fractures . In addition, this study suggested that performing surgery within six days after injury is recommended to reduce postoperative complications .

Background

Distal clavicle fractures have a high nonunion risk (22–50%) in patients treated non-surgically due to the instability caused by the two opposing forces of trapezius traction and the weight of the upper extremity [1–3]. Therefore, for unstable distal clavicle fractures classified as Neer type II or V [4, 5], surgical treatment is usually indicated [6]. To date, we have used the anatomical non-locking plates, “SCORPION®” (Fig. 1A and 1B) and “SCORPION® NEO” (Fig. 2A and 2B) (Aimedic MMT, Tokyo, Japan), to treat unstable distal clavicle fractures. In the fixation with Scorpion plate, the distal bone fragment is grasped by the plate arm and fixed with one or two screws, while the proximal bone fragment is fixed with three screws. The bending stiffness and torsional stiffness of the Scorpion plate were reported to be significantly higher than those of tension band wiring and were equivalent to those of hook plates [7]. Therefore, Scorpion plates can be expected to yield outcomes equivalent to those of other plate types. However, there have been no large clinical studies on the clinical results of osteosynthesis using Scorpion plates.

Plate fixation for distal clavicular fractures has been reported to achieve satisfactory bone union rates [8–14]; however, one of the important clinical problems is the rate of postoperative complications. While hook plates showed good outcomes for fractures with comminuted distal bone fragments, various

complications, such as peri-implant fracture, dislocation, and limited range of motion were reported [6, 10, 15]. On the other hand, plates that are fixed proximal to the acromioclavicular joint have been reported as leading to fewer complications than the hook plate, since the plates do not disturb the acromioclavicular joint motion [14, 16, 17]. However, complications such as plate fracture due to trauma, nonunion, and plate loosening can occur, albeit at a lower frequency, and some cases require re-operation [18, 19]. Nevertheless, risk factors for these postoperative complications remain largely unknown. The incidence of postoperative complications is reported to be high in patients for whom more than four weeks had elapsed since the injury [16, 20]. These reports suggest that the time to surgery may affect the occurrence of postoperative complications. However, the appropriate timing of surgery for acute distal clavicle fractures is still unclear.

The purpose of this study was to evaluate the clinical outcomes for distal clavicle fractures using the Scorpion plate and to assess the appropriate timing of surgery for acute unstable distal clavicle fractures.

Methods

Patient selection

This was a retrospective study of patients who underwent osteosynthesis using Scorpion plates for unstable distal clavicle fractures (Neer type II or V) between 2008 and 2018. During this period, SCORPION® plates were used from April 2008 to March 2014, and SCORPION® NEO plates were used from April 2014 to March 2018. The procedures were performed at a single general hospital by 14 surgeons (all trainees who were not specialized in shoulder surgery). We included patients with acute clavicle fractures within three weeks of injury. We excluded patients with insufficient follow-up, which prevented radiographic fracture union to be determined.

We identified 110 patients who met the inclusion criteria. Five patients were excluded due to inadequate follow-up. The mean (± standard deviation) age of patients at the time of surgery was 47.0 ± 16.7 years (range: 14–89 years). The affected side was the right for 58 patients and the left for 47 patients. There were 55 smokers (52.3%). The type of clavicle fracture was Neer classification type IIA in 23 patients (22.0%), type IIB in 63 patients (60.0%), and type V in 19 patients (18.1%) [4, 5]. Patients who met these criteria were further divided into two groups based on a previous report on the treatment of acute proximal humeral fractures; an early treatment group (early group), which included patients for whom the time from injury to surgery was within six days, and a delayed treatment group (delayed group), which included patients for whom time to surgery was seven days or more, according to a previous report on the treatment of acute proximal humeral fractures[21]. The early group included 45 patients and the delayed group included 60 patients (Table 1).

Surgical procedure

All patients underwent fracture fixation in a beach chair position under general anesthesia. The approach was from the superior side of the clavicle, and the acromioclavicular joint capsule was preserved. After temporarily fixing distal bone fragments with 2.0 mm Kirschner wires under fluoroscopy, if any third bone fragments were present, we sutured these fragments to the clavicle using high-strength absorption thread. We finally fixed these fracture fragments with a SCORPION® plate (Fig. 1C) or a SCORPION® NEO plate (Fig. 2C). If the fixation was considered to be insufficient, fixation with 2.0 mm Kirschner wire, or coracoclavicular ligament reconstruction with a suture-anchor, were added. While seven and 13 patients received additional fixation with a Kirshner wire and a suture-anchor, respectively, there was no significant difference in additional fixation between the early and delayed groups (Table 1). After surgery, the affected arm was kept in a sling for 1–3 weeks depending on the postsurgical fixation strength. Pendulum exercises were started the day after surgery and passive and active range of motion exercises were permitted after one week. Implant removal was performed when bone union was obtained at least six months after the operation and the patient requested the removal.

Outcomes

The outcomes were the occurrence of complications (delayed union, peri-implant fracture, plate loosening, plate-related pain, and stiffness requiring arthroscopic capsulotomy). A single examiner evaluated plain radiograph images and clinical notes. According to a previous report [22], delayed bone union was defined as a lack of bone bridging after more than 12 months after injury. We defined plate loosening as any screws backing out or a plate displacement >3 mm above the clavicle. Pain from the plate fixation was evaluated based on patient complaints 6 months after surgery (prior to implant removal).

Statistical analysis

All statistical analyses were conducted using SPSS version 26.0.0.0 (IBM, Armonk, NY). We used Student's *t*-tests to compare the average of continuous values (age and time from injury to surgery) and chi-square tests to compare the proportion of discrete variables (sex, the side of injury, smoking, and type of fracture, additional fixation with Kirschner wire or suture anchor) between the early and delayed groups. When comparing the proportion of variables, especially if the expected value of the variable was less than five (delayed union, plate loosening, peri-implant fracture, plate-related pain, and stiffness requiring arthroscopic capsulotomy), Fischer's exact test was used. Continuous data are presented as mean ± standard deviations (SD). The threshold for significance was $P<0.05$.

Results

Among the 105 patients, delayed union and plate loosening were observed in six (5.7%) and four patients (3.8%), respectively. Among the six patients with delayed union, only one patient experienced shoulder pain during elevation and a mild limitation of the range of motion, while other patients were

asymptomatic. In addition, a loosening of the screw inserted into the distal bone fragment was observed on radiographic images in two patients (Fig. 3). All patients with delayed union were treated nonoperatively and bone union was finally obtained within 1.5 years (Table 2).

Although there was a significant difference in the time from injury to surgery between the early and delayed groups ($P < 0.001$), there were no significant differences in age, sex, affected side, smoking rate, and the type of clavicle fracture (Table 1). Delayed union was only observed in the delayed group, and the frequency of delayed union was significantly higher in the delayed group than that in the early group ($P = 0.036$). Plate loosening was also only observed in the delayed group, but no significant difference was observed in comparison with the early group. Peri-implant fractures were not observed in either group. There was no significant difference in the frequency of plate-related pain at six months after surgery between the two groups. In addition, postoperative shoulder stiffness was observed in one patient in the delayed group, which required arthroscopic capsulotomy two years after surgery (Table 3).

Discussion

In this study, we made two important clinical observations. First, results of this study indicated that osteosynthesis using Scorpion plates constitute a promising surgical treatment for unstable distal clavicle fractures. Second, this study suggested that delaying the surgical intervention for more than six days after injury is associated with the increased occurrence of delayed union one year after surgery in distal clavicle fractures.

First, our present results demonstrated that osteosynthesis using Scorpion plates for unstable distal clavicle fractures led to high bone union and low complication rates even though trainees, and not shoulder specialists, performed the surgeries, suggesting that this plate can compensate for the lack of surgical expertise. In this study, six patients (5.7%) experienced delayed bone union and one patient was symptomatic. However, bone union was ultimately achieved in all patients within 1.5 years after surgery. Previous studies investigating the clinical outcomes of at least 30 patients with distal clavicle fractures showed a bone union rate of 94–100% with hook plates [10,12,14] and 97–100% with plates not fixed across the acromioclavicular joint [13,14]. Our findings suggest that the postoperative bone union rate observed with Scorpion plates can be equivalent to that of other plates. In distal clavicle fractures, distal fragments are fragile and often comminuted; therefore, stable fixation with screws is not always obtained. Scorpion plates can be used to fix distal fragments in a manner such that its arms wrap them with soft tissue en bloc. However, plate loosening was observed in four patients (3.8%), presumably because Scorpion plates do not have locking screws. In all these patients, the loosening of screws inserted into distal bone fragments was observed, and the length of the distal screw was considered insufficient. These observations indicate that when performing fixation with the Scorpion plate, it is crucial to select the optimal distal screw length since distal bone fragments were fixed with only one or two screws in addition to the plate arm.

Second, this study demonstrated that the rate of delayed union was significantly higher when surgery was delayed for seven days or more after injury. In addition, although the difference in frequency was not significant, plate loosening and stiffness were only seen in the delayed surgery group. These results suggest that delaying the surgical intervention for seven or more days after injury may be associated with an increase in prostoperative complications. Regarding the timing of distal clavicle fracture surgery, postoperative complications have been reported to increase in subjects that undergo surgery more than four weeks after injury [1, 21]; however, the timing of surgery for acute fractures remains unclear. Recently, proximal humerus fracture fixation within five days of the fracture event was recommended, since a delayed intervention (six or more days after the injury) is related to a significant increase in complications [21], which is similar to the results of this study. Furthermore, a delayed surgical intervention is thought to complicate the anatomical fracture reduction and increase soft tissue dissection, which may result in a longer fracture union time [23]. This hypothesis raised by Tang et al. can explain our finding of a higher delayed union rate in the delayed surgery group. In this study, one patient who experienced delayed bone union one year after the operation was symptomatic (16.6%), but reoperation was not required, and bone union was finally obtained 1.5 years after surgery. However, considering that some cases of nonunion or plate loosening associated with delayed union were reported to require reoperation with iliac bone [18, 19] grafting, performing surgery for acute distal clavicle fractures within six days after the injury would be preferable.

There are two major strengths to this study. Whereas a majority of previous studies on the surgical outcomes for distal clavicle fractures had a sample size of 50 or less, we were able to perform a large clinical study on more than 100 patients over 10 years. Second, we used Scorpion plates for all unstable distal clavicle fractures and the surgical procedure was standardized during the period, suggesting that the generalization of clinical results using Scorpion plates is possible. On the other hand, there are several major limitations to this study. First, it is difficult to accurately evaluate the superiority or inferiority of Scorpion plate to other implants since this study was not a comparative study between different implants. Second, because of this study's observational design, biases from unobserved differences may have affected the results. For example, the procedures were performed by 14 surgeons; however, the influence of the abilities of the surgeons or the assistants were not evaluated. Although smoking was reported as a risk factor for nonunion of distal clavicle fractures [19], smoking status was adjusted between the early and delayed groups in this study. Finally, since questionnaire surveys were not administered in this study, it was not possible to determine additional objective functional outcomes.

Conclusions

This study provides new information on the clinical effectiveness of Scorpion plates in the treatment of distal clavicle fractures. Further, as a treatment for acute unstable distal clavicle fractures, performing surgery within six days after injuries is recommended to reduce postoperative complications.

Declarations

List of abbreviations

Standard deviation: SD

Ethics approval and consent to participate: This study was approved by the National Hospital Organization Tokyo Medical Center Independent Ethics Committee (No.R19–037), and opt-out consent was performed for each patient on our hospital's bulletin board and Web site. Opt-out consent relies on implicit consent, where willingness to participate is tacit or presumed, and can be retracted by active objection.

Consent for publication: Not Applicable

Availability of data and materials: Data that support the findings of this study are available from the corresponding author on reasonable request.

Competing interests: The authors declare that they have no competing interests.

Funding: The authors certify that they or their institutions did not receive any support (e.g. grants, funding, payment or other benefits) or a commitment or agreement to provide such benefits in connection with the research or preparation of this manuscript. We also have no funding body in the design of the study and collection, analysis, and interpretation of data and in writing the manuscript.

Authors' contributions: All authors contributed to the study conception and design. Material preparation, data collection and analysis were performed by RF, MT, TH, MI, AK, YK1, and AY. The first draft of the manuscript was written by RF and MT. NM, YK2, HA, and HM contributed to previous versions of the manuscript. All authors read and approved the final manuscript. YK1 corresponds to Yasuhiro Kiyota and YK2 corresponds to Yusaku Kamata.

Acknowledgements: Not Applicable

References

1. Nordqvist A, Petersson C, Redlund-Johnell I. The natural course of lateral clavicle fracture. 15 (11–21) year follow-up of 110 cases. Acta Orthop Scand 1993;64:87–91.
2. Robinson CM, Court-Brown CM, McQueen MM, Wakefield AE. Estimating the risk of nonunion following nonoperative treatment of a clavicular fracture. J Bone Joint Surg Am 2004;86:1359–65.
3. Rokito AS, Zuckerman JD, Shaari JM, Eisenberg DP, Cuomo F, Gallagher MA. A comparison of nonoperative and operative treatment of type II distal clavicle fractures. Bull Hosp Jt Dis 2002;61:32–9.

4. Neer CS. Fractures and dislocations of the shoulder. In: Rockwood CA Jr, Green DP, editors. Fractures in adults. Lippincott: Philadelphia; 1984. p. 711–2.
5. Neer CS. Fractures of the distal third of the clavicle. Clin Orthop Relat Res 1968;58:43–50.
6. Banerjee R, Waterman B, Padalecki J, Robertson W. Management of distal clavicle fractures. J Am Acad Orthop Surg 2011;19:392–401.
7. Sakai R, Matsuura T, Tanaka K, Uchida K, Nakao M, Mabuchi K. Comparison of internal fixations for distal clavicular fractures based on loading tests and finite element analyses. Sci World J 2014;2014.
8. Fan J, Zhang Y, Huang Q, Jiang X, He L. Comparison of Treatment of Acute Unstable Distal Clavicle Fractures Using Anatomical Locking Plates with Versus without Additional Suture Anchor Fixation. Med Sci Monit 2017;23:5455–61.
9. Fleming MA, Dachs R, Maqungo S, du Plessis JP, Vrettos BC, Roche SJ. Angular stable fixation of displaced distal-third clavicle fractures with superior precontoured locking plates. J Shoulder Elbow Surg 2015;24:700–4.
10. Flinkkilä T, Ristiniemi J, Lakovaara M, Hyvönen P, Leppilahti J. Hook-plate fixation of unstable lateral clavicle fractures: a report on 63 patients. Acta Orthop 2006;77:644–9.
11. Ibrahim S, Meleppuram JJ. Retrospective study of superior anterior plate as a treatment for unstable (Neer type 2) distal clavicle fractures. Rev Bras Ortop 2017;53:306–13.
12. Kashii M, Inui H, Yamamoto K. Surgical treatment of distal clavicle fractures using the clavicular hook plate. Clin Orthop Relat Res 2006;447:158–64.
13. Martetschläger F, Kraus TM, Schiele CS, Sandmann G, Siebenlist S, Braun KF, Stöckle U, Freude T, Neumaier M. Treatment for unstable distal clavicle fractures (Neer 2) with locking T-plate and additional PDS cerclage. Knee Surg Sports Traumatol Arthrosc 2013;21:1189–94.
14. Zhang C, Huang J, Luo Y, Sun H. Comparison of the efficacy of a distal clavicular locking plate versus a clavicular hook plate in the treatment of unstable distal clavicle fractures and a systematic literature review. Int Orthop 2014;38:1461–8.
15. Lee W, Choi CH, Choi YR, Lim KH, Chun YM. Clavicle hook plate fixation for distal-third clavicle fracture (Neer type II): comparison of clinical and radiologic outcomes between Neer types IIA and IIB. J Shoulder Elbow Surg 2017;26:1210–5.
16. Klein SM, Badman BL, Keating CJ, Devinney DS, Frankle MA, Mighell MA. Results of surgical treatment for unstable distal clavicular fractures. J Shoulder Elbow Surg 2010;19:1049–55.
17. Xiong J, Chen JH, Dang Y, Zhang DY, Fu ZG, Zhang PX. Treatment of unstable distal clavicle fractures (Neer type II): A comparison of three internal fixation methods. J Int Med Res 2018;46:4678–83.
18. Brouwer KM, Wright TC, Ring DC. Failure of superior locking clavicle plate by axial pull-out of the lateral screws: a report of ffour cases. J Shoulder Elbow Surg 2009;18:e22–5.
19. Jarvis NE, Halliday L, Sinnott M, Mackenzie T, Funk L, Monga P. Surgery for the fractured clavicle: factors predicting nonunion. J Shoulder Elbow Surg 2018;27:e155–9.

20. Meda PV, Machani B, Sinopidis C, Braithwaite I, Brownson P, Frostick SP. Clavicular hook plate for lateral end fractures:- a prospective study. Injury 2006;37:277–83.
21. Siebenbürger G, Van Delden D, Helfen T, Haasters F, Böcker W, Ockert B. Timing of surgery for open reduction and internal fixation of displaced proximal humeral fractures. Injury 2015;46:S58–62.
22. Neer CS. Fracture of the distal clavicle with detachment of the coracoclavicular ligaments in adults. J Trauma 1963;3:99–110.
23. Tang X, Liu L, Tu CQ, Li J, Li Q, Pei FX. Comparison of early and delayed open reduction and internal fixation for treating closed tibial pilon fractures. Foot Ankle Int 2014;35:657–64.

Tables

Table 1. Patient demographics

	Early group (n=45)	Delayed group (n=60)	**P value**
Time from injury to surgery (days)	3.9±1.5	10.7±3.4	<0.001 *
Age (years)	44.4±14.9	49.0±17.6	0.194
Male/Female	35/10	50/10	0.473
Side of Injury, Right/Left	27/18	31/29	0.395
Smoker/Non-smoker	26/19	29/31	0.338
Neer Type IIa	7	16	0.173
Neer Type IIb	30	33	0.227
Neer Type V	8	11	0.942
Additional fixation with Kirschner wire or suture anchor	7	13	0.430

* P<0.001

Table 2. Details of patients experiencing delayed bone union. (0 females, 6 males, age range 24-72 years, median 38.5 years)

	Type (Neer)	Symptoms	Imaging findings	Clinical results
Patient 1	IIA	Asymptomatic	Residual postoperative fracture gap (>3mm)	Conservative treatment Bone union at 1.2 years
Patient 2	IIB	Asymptomatic	-	Conservative treatment Bone union at 1.3 years
Patient 3	IIB	Mild limitation inelevation (135°) Pain at elevation	Distal screw loosening	Conservative treatment Bone union at 1.5 years
Patient 4	V	Asymptomatic	-	Conservative treatment Bone union at 1.3 years
Patient 5	IIB	Asymptomatic	Distal screw loosening	Conservative treatment Bone union at 1.5 years
Patient 6	V	Asymptomatic	-	Conservative treatment Bone union at 1.3 years

Table 3. Comparison of incidence of postoperative complications (early group vs. delayed group)

	Early group (n=45)	Delayed group (n=60)	**P value**
Delayed union	0 (0%)	6 (10%)	0.036*
Plate loosening	0 (0%)	4 (6.7%)	0.133
Peri-implant fracture	0 (0%)	0 (0%)	-
Plate-related pain	3 (6.7%)	4 (6.7%)	1
Stiffness requiring arthroscopic capsulotomy	0 (0%)	1 (1.7%)	1

* $P<0.05$

Figures

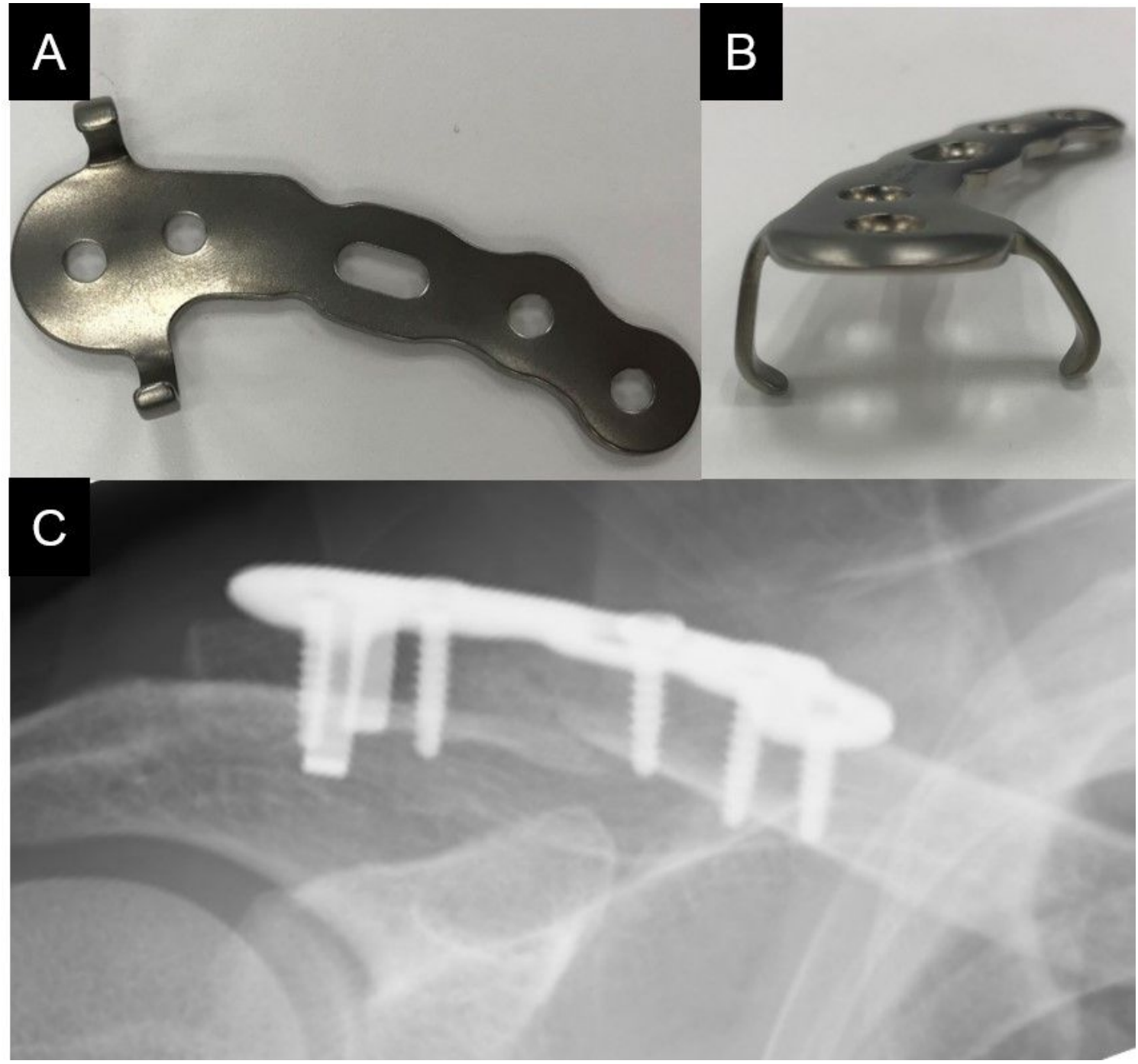

Figure 1

The photo images demonstrate a SCORPION® plate (A and B). Plain radiograph showing osteosynthesis using a SCORPION® plate within six days after injury (C).

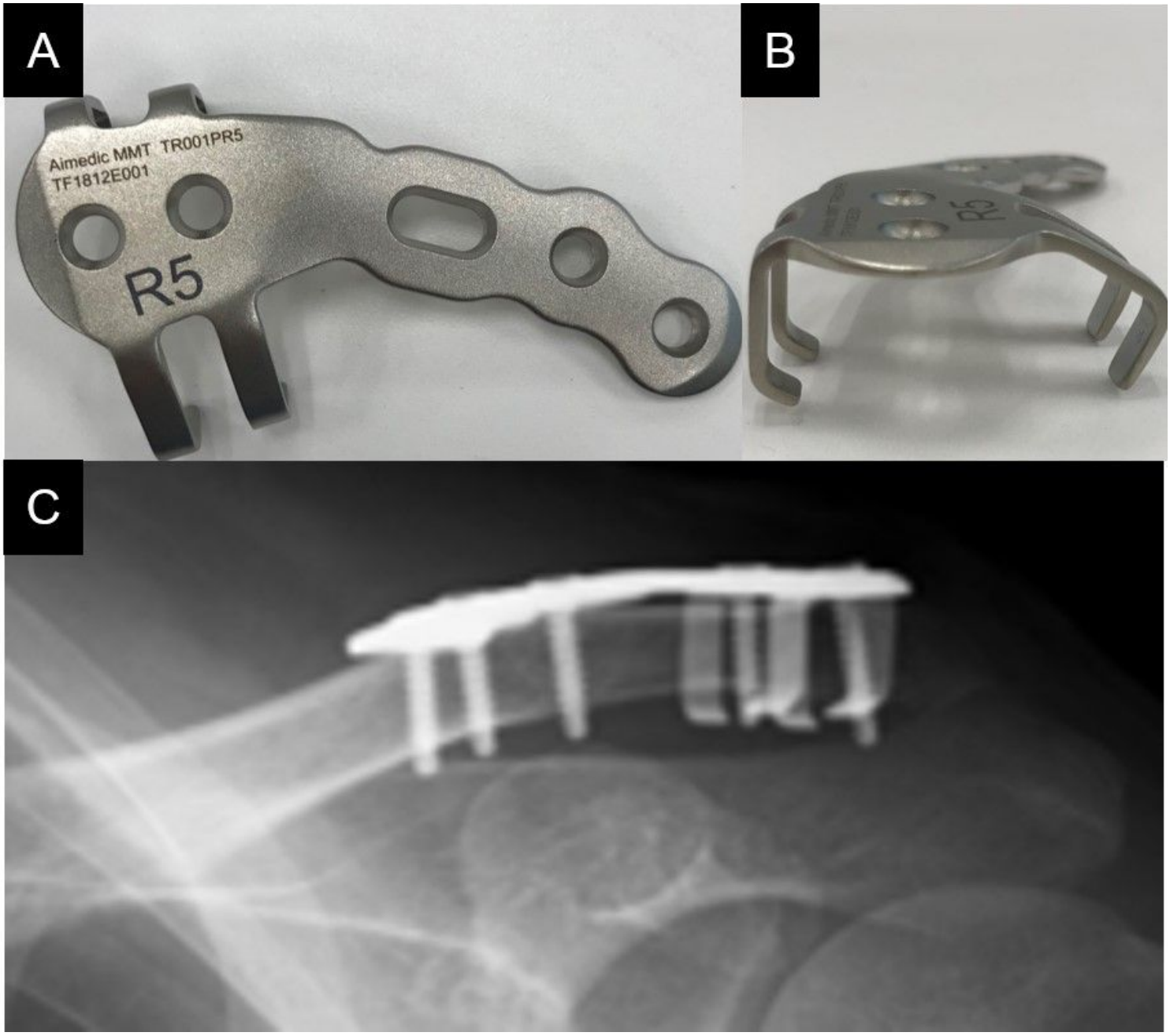

Figure 2

The photo images demonstrate a SCORPION® NEO plate (A and B). Plain radiograph showing osteosynthesis using a SCORPION® NEO plate within six days after injury (C).

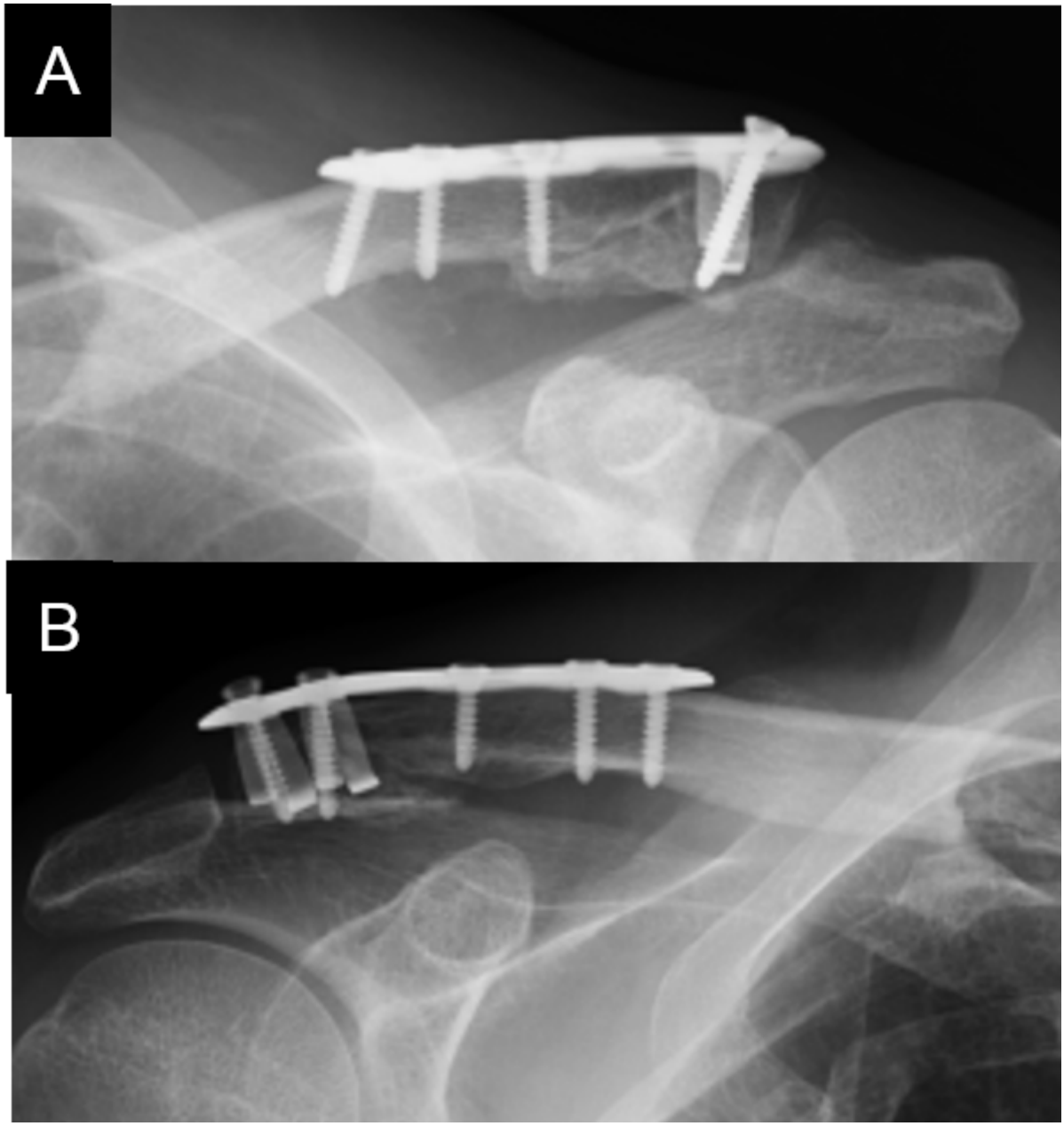

Figure 3

Plain radiographs showing delayed bone union. Post-operative radiographs performed 1 year after surgery revealed that the fracture line is visible and the distal screws were loosening (A and B).