Ten- Year-Old Female with Dieulafoy Lesion Treated with Therapeutic Endoscopy And Literature Review

Ying Chen
Shengjing Hospital of China Medical University
Mei Sun
Shengjing Hospital of China Medical University
Xu Teng (tengx@sj-hospital.org)
Shengjing Hospital of China Medical University https://orcid.org/0000-0002-0566-5859

Case report

Keywords: Pediatrics, Dieulafoy lesion, gastrointestinal hemorrhage, endoscopy

Posted Date: September 9th, 2020

DOI: https://doi.org/10.21203/rs.3.rs-69381/v1

Abstract

Background There are many causes of sudden gastrointestinal bleeding in children, Dieulafoy lesion is very rare. This vascular abnormality can be fatal without appropriate treatment.

Case presentation Retrospective analysis of the clinical manifestations, endoscopic features and treatment of a Chinese child with Dieulafoy lesion and review relevant literatures.

Result A 10-year-old girl was admitted to hospital with sudden massive hematemesis and melena. Abdominal CT revealed suspected submucosal bleeding in the stomach. Finally the disease was diagnosed due to the typical manifestations with endoscopy. Meanwhile, we used electrocoagulation and hemoclips to hemostasis under endoscopy. No recurrence of hematemesis identified during the 4-weeks follow-up.

Conclusion Dieulafoy lesion in children is rare cause of sudden gastrointestinal hemorrhage. But differential diagnosis cannot ignore it. Endoscope is the optimize choice for diagnosis and treatment.

Background

Dieulafoy lesion (DL),also known as Dieulafoy disease, is a rare but fatal cause of gastrointestinal hemorrhage[1]. Early diagnosis and appropriate treatment are vital. We report a ten-year-old female, presenting with hematemesis and melena, who was diagnosed with Dieulafoy lesion and treated with electrocoagulation and hemoclips successfully.

Case Presentation

A 10-year-old Chinese girl, with history of hematemesis, was admitted to pediatrics intensive care unit(PICU) of Shengjing hospital of China Medical University with massive hematemesis and melena. She denied surgical history and was not taking any medicine. No known significant gastrointestinal (GI) conditions within the family. On admission physical examination, her temperature was 36.5℃, heart rate of 134 beats per minute, blood pressure was 95/56 mmHg, respiratory rate of 25 per minute. Her body weight was 40 kg. She was pale, and abdominal examination was unremarkable. No other phycial abnormalities were noted. Her initial laboratory testing revealed white cell count of 12.7×10^9/L(normal: $4–10 \times 10^9$/L) hemoglobin(HB) of 7.8 g/dL (normal: 12-15.5 g/dL), platelet count of 134×10^9/L (normal: $100–300 \times 10^9$/L). The results of other laboratory tests (including coagulation function test) were unremarkable. An abdominal computed tomography (CT) revealed suspected mucosal hemorrhage in the cardia of gastric, and slight dilation of small submucosal blood vessels.

On the day of admission, she was managed with proton pump inhibitor (1 mg/kg.d), intravenous fluids and nutritional support, and diet resistance. However, she developed another massive melena and her HB had decreased to 6.9 g/dl. She was subsequently transferred to our department and two units of packed red blood cells were transfused. An gastroscopy with a transparent hood over the head was urgently

performed, and bright red blood was noted in the stomach. A careful examination revealed the presence of an actively bleeding protruding vessel in the posterior wall of the body of stomach (Fig. 1).We treated it with a cautery probe, during which the lesion initially oozed. Two endoscopic hemoclips were applied with full control of bleeding (Fig. 2). The rest of the stomach mucosa did not show any other bleeding lesion and ulceration. The patient had no further complaints at her follow-up at the outpatient clinic 4 weeks later.

Discussion And Conclusions

Dieulafoy lesion(DL), described by French pathologist Dieulafoy first, manifests itself with spontaneous recurrent gastrointestinal bleeding (GIB). It is observed in about 0.3–6.7% percent of the causes of upper GIB[2]. There is no accurate statistics on the incidence of this disease in children. DL is a large penetrating artery which is a normal vessel with an unexpectedly large diameter, the vessel caliber is 1–3 mm. This penetrating artery creates a small wall defect with fibrinoid necrosis found at the base. It does not known clearly about the mechanisms of the pathologic bleeding of DL in date. Newborn cases suggest DL can be congenital and a congenital anomaly may develop acute ruptures. The mechnical friction, chemical corrosion or drugs can induce protruding vessel ruptured and massive bleeding[3, 4]. In adult, DL is more common in men than women and middle aged and old people have more cases [5]. Unlike adult patients, the pediatric cases do not appear to have a gender preference [6].

The small nature of the lesion and the special sites of the hemorrhage are the two features of DL. Most lesions are in the proximal stomach, particularly within 6–10 cm of the lesser curvature of the stomach, where blood supply comes directly from the arteriae gastrica sinistra [7]. Nongastric sites are also involved in DL such as the duodenum, jejunum, ileum, rectum and even in the bronchus[8].

It is challenging to diagnose DL exactly because of the features of the disease. Endoscopy, angiography and surgical search are the primary diagnostic modalities. RBC scintigraphy can also detect the site of bleeding. Undoubtedly, endoscopy is the most feasible method. Initial endoscopies can diagnose precisely over 71% cases [9]. As the subtle lesions exist, multiple endoscopies are needed in some patients.

The endoscopic visual criteria of DL includes: (A) active arterial spurting or micro pulsatile streaming from a mucosal defect < 3 mm, (B) visualization of a vessel protruding from a slight defect or normal mucosa, or (C) a fresh blood clot adherent to a minute mucosal defect or a normal-appearing mucosa [10, 11].

To diagnose a Dieulafoy lesion clearly and safely, these principles should be included in endoscopic exam [12]: (1) During period of active bleeding, emergency endoscopy should be performed under the anti-shock therapy. (2) The lesion may be exposed by cleaning gastral cavity with moderate endoscopic perfusion.(3)During the endoscopy, patients need to change their body position if necessary.(4) Don’t stop searching for the causes of hemorrhage after finding mild peptic ulcer and esophageal varicose veins, especially sudden massive hematemesis.(5) If DL is suspected, focal tissue biopsy is strictly prohibited.

Timely endoscopy and treatments can decrease the mortality of DL sharply [13]. Endoscopy is recommended as the first-line method of treatment[14]. Endoscopic treatments include thermal electrocoagulation, heat probe coagulation, laser photocoagulation, regional injection-epinephrine, sclerotherapy, norepinephrine injection, band ligation and hemoclips[15, 16]. Mechanical banding and hemoclips are more effective than thermal electrocoagulation and injection[17]. The combination of electrocoagulation and hemoclips may be more reliable. As in our case the procedure was adopted.

To patients who failing endoscopic therapy, angiography with gel foam embolization should be suggested [18]. Surgical management, regarded as the only treatment initially available before, is reserved for patients who are refractory to endoscopy and angiography. Endoscope combined with laparoscopic surgery is a new attempt, which is less invasive than traditional surgery and easy to be accepted by patients [19].

In general, DL as a cause of life-threatening bleeding is rare occurrences in the pediatric population. But pediatrician should be aware of

it as a differential diagnosis of pediatric GIB. Endoscopy is still the primary diagnostic tool and the first-line method of treatment. Early diagnosis and treatment are of great significance to the prognosis of children.

Abbreviations

Dieulafoy lesion (DL), pediatrics intensive care unit(PICU), gastrointestinal (GI), computed tomography (CT), gastrointestinal bleeding (GIB)

Declarations

Ethical approval and consent to participate: The use of history records and clinical data was reviewed and approved by the ethics committee of the Shengjing Hospital of China Medical University. The waiver of the study participant consent is approved by the ethics committee of the Shengjing Hospital of China Medical University.

Consent for publication: All authors read and approved the manuscript

Availability of data and materials: not applicable

Competing interests: The authors report no conflicts of interest.

Funding: None

Author contribution

CY, TX: Writing.

CY: Data collection.

SM,TX: Study design and review.

Acknowledgements: None

References

[1] Zamulko OY, Zamulko AO, Dawson MJ.Introducing GIST and Dieulafoy - Think of Them in GI Bleeding and Anemia. S D Med. 2019,72(11):528-530.

[2] Chaer RA, Helton WS. Dieulafoy's Disease. J Am Coll Surg. 2003,196(2):290-296.

[3]Chen QK, He GX, Zhu ZH. Diagnosis of digestive diseases [M].Beijing People's Medical Publishing House, 2006 418. ISBN:9787117074629

[4]Gambhire PA, Jain SSm, Rathi PM, Amarapurkar AD. Dieulafoy disease of stomach-an uncommon cause of gastrointestinal system bleeding. J Assoc Physicians India. 2014,62(6):526-528.

[5] Holleran G, Hussey M, McNamara D. Small bowel Dieulafoy lesions: An uncommon cause of obscure bleeding in cirrhosis. World J Gastrointest Endosc,2016,8(16):568-571.

[6]Senger JL, Kanthan R. The Evolution of Dieulafoy's Lesion Since 1897: then and now-a journey through the lens of a pediatric lesion with literature review. Gastroenterol Res Pract. 2012;2012:432517.

[7]Tang P, Wu T, Li C, Lv C, Huang J, et al. Dieulafoy disease of the bronchus involving bilateral arteries: A case report and literature review. Medicine. 2019,98(44):e17798.

[8] Joarder AI, Faruque MS, Nur-E-Elahi M, Jahan I, Siddiqui O, et al. Dieulafoy's lesion: an overview. Mymensingh Med J. 2014,23(1):186-194.

[9] Driver CP, Bruce J, An unusual cause of massive gastric bleeding in a child. Journal of Pediatric Surgery, 1997, 32(12), 1749–1750.

[10] Chung IK, Kim EJ, Lee MS, Kim HS, Park SH,et al. Bleeding Dieulafoy's lesions and the choice of endoscopic method: comparing the hemostatic efficacy of mechanical and injection methods. Gastrointest Endosc. 2000, 52:721-724.

[11] Apiratpracha W, Ho JK, Powell JJ, Yoshida EM. Acute lower gastrointestinal bleeding from a dieulafoy lesion proximal to the anorectal junction post-orthotopic liver transplant. World Journal of Gastroenterology. 2006,12(46): 7547–7548.

[12] Xu X, Zhang YS. Diagnosis and treatment of dieulafoy disease [J]. Chinese Journal of Gastroenterology and Hepatology. 2009,18(9):870-871

[13] Alshumrani G, Almuaikeel M. Angiographic findings and ndovascular embolization in Dieulafoy disease: a case report and literature review. Diagn Interv Radiol. 2006, 12:151-154.

[14] Jeon HK, Kim GH. Endoscopic Management of Dieulafoy's Lesion.

Clin Endosc. 2015,48(2):112-120.

[15] Baxter M, Aly EH. Dieulafoy's lesion: current trends in diagnosis and management. Annals of the Royal College of Surgeons of England. 2010, 92(7): 548–554.

[16] Alis H, Oner OZ, Kalayci MU, Cho YK, Kim HU, et al. Is endoscopic band ligation superior to injection therapy for Dieulafoy lesion? Surgical Endoscopy and Other Interventional Techniques. 2009,23(7):1465–1469.

[17] Chung K, Kim EJ, Lee MS, Kim HS, Park SH, et al, Bleeding Dieulafoy's lesions and the choice of endoscopic method: comparing the hemostatic efficacy of mechanical and injection methods, Gastrointest. Endosc. 2000,52:721–724.

[18] Ganganah O, Guo S. Endobronchial ultrasound and bronchial artery embolization for Dieulafoy's disease of the bronchus in a teenager: A case report. Respir Med Case Rep. 2015,16:20-23.

[19]Yilmaz TU, Kozan R. Duodenal and jejunal Dieulafoy's lesions: optimal management. Clin Exp Gastroenterol. 2017,10: 275-283.

Figures

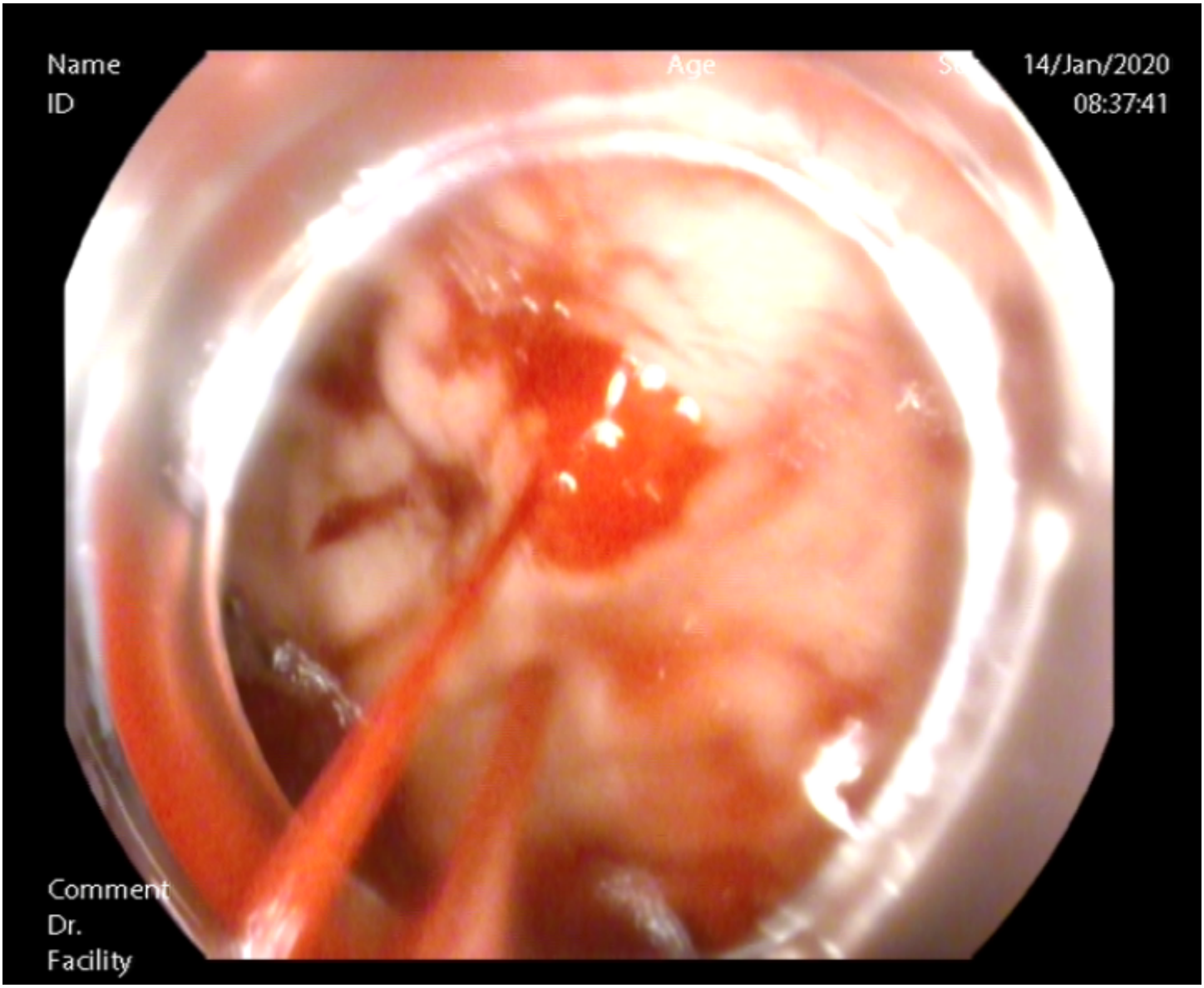

Figure 1

Persistent pulsatile bleeding

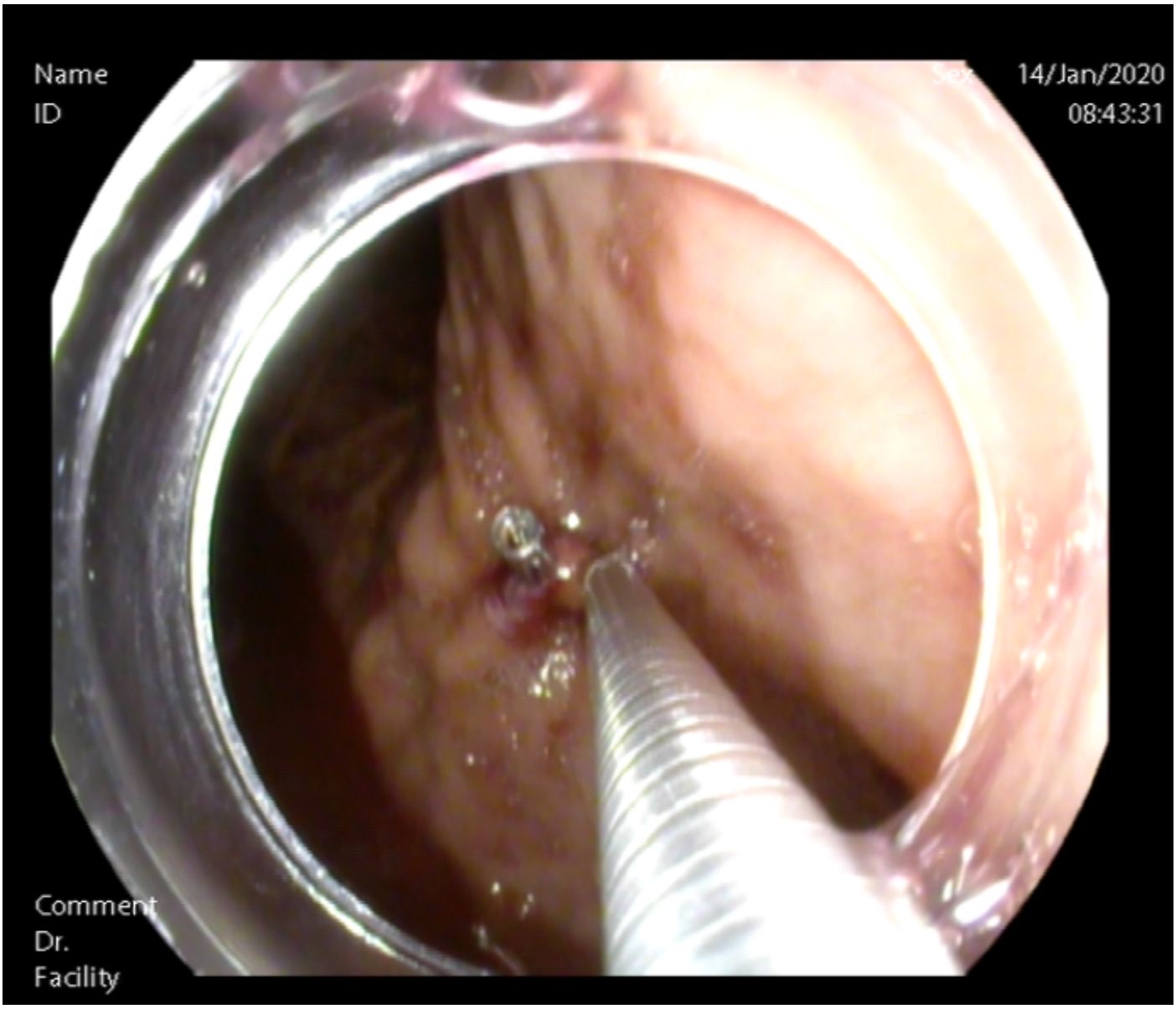

Figure 2

Hemostasis controled after electrocoagulation and hemoclips.