Sparganum in the Lumbosacral Canal: a Case Report

Jian Feng Fan
Xiangya Hospital Central South University https://orcid.org/0000-0003-2437-3592
Sheng Huang
Xiangya Hospital Central South University
Jing Li
Central South University Xiangya School of Medicine
Ren-Jun Peng
Xiangya Hospital Central South University
He Huang
Xiangya Hospital Central South University
Xi-Ping Ding
Xiangya Hospital Central South University
Li-Ping Jiang
Central South University Xiangya School of Medicine
Jian Xi (xijian3001@126.com)
Xiangya Hospital Central South University

Case Report

Keywords: sparganosis, lumbosacral spine, Sparganum, praziquantel

Posted Date: July 19th, 2021

DOI: https://doi.org/10.21203/rs.3.rs-699461/v1

Abstract

Background: Sparganosis is a rare parasitic infection caused by invasion of the larvae of tapeworms *Spirometra mansoni* called sparganum. It often lodges in human eyes, subcutaneous body of limbs, oral and maxillofacial regions. However, lumbosacral spinal canal invasion is extremely rare and the diagnosis is very difficult. We herein report a case of spinal sparganosis.

Case presentation: A 56-year-old man presented at the hospital after having experienced perianal pain for a week. MRI of the lumbosacral spine with gadolinium contrast study revealed an enhancing mass at the S1-S2 level that was clinically suggestive of a tumor. The patient underwent laminectomy from S1 to S2. We detected a live worm in inferior margin of L5 and spinal sparganosis was diagnosed by histological examination. He had a history of ingesting undercooked frog meat in his youth. Both in CSF and serum samples, we detected anti-sparganum antibodies. A dose of praziquantel, albendazole and dexamethasone was administered to the patient because we did not remove the parasitic mass completely.

Conclusions: Sparganosis of the central nervous system is extremely rare, especially spinal sparganosis. The mainly treatments spinal sparganosis are surgical removal of the larva and administration of high-dose praziquantel, albendazole and dexamethasone.

Background

Sparganosis is a rare parasitic infection caused by invasion of the larvae of tapeworms (sparganum), belong to the genus *Spirometra*, and it occurs worldwide. Most human cases have been recognized in Southeast Asian countries [1]. Forms of disease include subcutaneous nodules, ocular manifestations, central nervous system disease, and visceral involvement. The cases of eye sparganosis and subcutaneous sparganosis have been reported previously, but very few cases of spinal sparganosis have been covered so far. We herein present a case of spinal sparganosis in Hunan, China.

Case Presentation

A 56-year-old man presented with a 1-week history of perianal pain. No history of dysuria or difficulties in defecation were reported. And the muscle strength of the bi-upper and bi-lower limbs was grade 5 in the MRC scale. The muscle tonus of the four limbs was normal, with normal tendon reflexes in the upper and lower limbs. And laboratory assessment revealed that white blood cell count of 6.2*10^9/L (reference range 4–10*10^9/L), with 1.9% eosinophil count (reference range 0.4-8.0%). Further examination such as blood biochemistry, routine stool examination, and urine analysis were within normal range. MRI of the lumbosacral spine with gadolinium contrast study showed a 1.7*1.5*5.4-cm heterogeneous enhancing mass at the S1-2 level (Fig. 1). We initially considered the possibility of a neoplastic lesion. The patient underwent laminectomy from S1 to S2. On the operative view, we found that the dural tension was very high, the arachnoid membrane was thickened and yellowish-white due to severe inflammation and

adhesion. We detected a live worm in inferior margin of L5 (Fig. 2a), proliferative inflammatory granulation tissue (Fig. 2b) surrounding the nerve tissue of cauda equina, which is not easy to remove. We did not remove inflammatory granulation tissue, just only took the worm body out from it. An additional movie file shows this in more detail [see Additional file 1]. Both rapid intraoperative and routine postoperative pathological diagnosis (Fig. 3) revealed a parasite.

On further carefully inquiring, our patient had a history of ingesting undercooked frog meat in his youth. Blood and cerebrospinal fluid samples were further collected and sent to the Department of Parasitology, Xiangya Medical College, Central South University for immunological diagnosis. The specific anti-body IgG against tissue-dwelling parasites (*Clonorchis sinensis*, *Paragonimus Westermani*, *Schistosoma japonicum*, *Echinococcus granulosus*, and *Trichinella spiralis*) were assayed by ELISA method and the results were all negative. But both in CSF and serum sample, the specific anti-sparganum antibody IgG was positive. A dose of praziquantel (50mg/kg once a day), albendazole (15mg/kg once a day), and dexamethasone 0.1mg/kg once a day) was administered to the patient. After a month of treatment, the patient's perianal pain was relieved significantly, but he also had positive anti-sparganum antibody.

Discussion

Sparganosis, a zoonotic parasitic disease caused by the larvae of tapeworms named sparganum, has been recognized worldwide, but it is commonly seen in China, Korea, Japan and eastern Asia. The adult tapeworm parasitizes in small intestine of definitive hosts such as cats, dogs and other carnivores, and their eggs Passed to outsides with feces. Under appropriate conditions, the eggs are hatched in water and release coracidia after 2-5weeks. If coracidia are ingested by cyclops, the first intermediate host, then they will develop into procercoid, and when procercoid are swallowed by second intermediate hosts such as amphibians, reptiles and other mammals, especially frogs in which they will accordingly develop into plerocercoid called sparganum [1]. The majority of sparganum in the human body remain their larval states, but they will invade various tissues and organs of the human body, and cause varying degrees of lesions. They can lodge in human body in the number of dozens, surviving in human tissues for 12 years, or even up to 36 years. There are three ways of human infection with sparganum [2]: (1) Using raw meat or skin from frogs or snakes as poultices; (2) Eating raw or undercooked frog or snake meat and ingestion of live tadpoles; (3) Drinking water contaminated with intermediate hosts. Sparganum can invade the human body through wounds or normal skin and mucous membranes, and then migrate to various tissues of the body. However, the adult *Spirometra mansoni* seldom parasitizes the human body and has little pathogenicity to humans [3]. But the infected patients may be reported with some mild symptoms such as discomfort or slight pain in the epigastrium and central abdomen, even nausea and vomiting. Human sparganosis caused by sparganum is far more harmful than that caused by adult *Spirometra mansoni*. Besides, lesions vary with the migration and residence of sparganum. Sparganum could lodge in human eyes, subcutaneous body of limbs, oral and maxillofacial regions, followed by central nervous system lesions. It is also reported that they are found in internal organs such as lungs, scrotal and bladder [4, 5]. However, lumbosacral spinal canal involvement is extremely rare. spinal

sparganosis patients may present with radicular pain, neurogenic bladder, and paraparesis. In our case, however, the patient showed only perianal pain.

In the case of cerebral sparganosis, the typical signs on CT include hypodensity of the white matter, irregular or nodular-enhancing lesions and small dot-like calcification. MRI findings may include aggregated ring-like enhancement (often three to six bead-shaped rings), "tunnel sign" with enhancement of lesions, and migration of radiographic lesions as larvae migrate. In our case, the lumbosacral MRI revealed heterogeneous enhancing lesion at the S1-2 level. The gold standard for diagnosis of sparganosis remains histological examination [6]. In addition, IgG antibodies to sparganum from serum or CSF can be detected by ELISA, which has high sensitivity and specificity [7]. However, the diagnosis mainly depends on surgical detection of the worms due to the rare presence of sparganosis. In our case, the ELISA for anti-sparganum antibodies was positive in both plasma and CSF collected on the day after operation.

In terms of treatment, it is essential to completely remove sparganum even their cephalic segment. The mainly methods are surgical removal of the larva and administration of high-dose praziquantel. Surgically,sparganum should be removed completely and thoroughly in case that the residual scolex leads to recurrence. And as for drug treatment, praziquantel has been proved a suitable option. A recent retrospective study indicated that 94 percent of patients with central nervous system sparganosis have improved radiographically after treating with a high-dose regimen of praziquantel [8]. As for our patient, the proliferative inflammatory granulation adhered to his nerve tissue of cauda tightly. Therefore, we just took out the live worm rather than removing inflammatory granulation tissue in case of any risks. After operation, the patient has been continuously treated with medicine including praziquantel, albendazole, and dexamethasone. Serological tests were repeated at appropriate intervals to evaluate the efficacy of treatment.

Conclusion

Although spinal sparganosis is a very rare infection, the patients who had the history of eating raw or undercook frogs or snakes and drinking contaminated water should be suspected of infecting sparganosis, especially in endemic areas. Preoperative ELISA is useful for the diagnosis so as to figure out a more favorable treatment plan.

Abbreviations

ELISA: Enzyme-linked immunosorbent assay

MRI: Magnetic resonance imaging

CSF: Cerebrospinal fluid

CT: Computed tomography

Declarations

Acknowledgements

We would like to acknowledge all staff of the department of neurosurgery at Xiangya Hospital Central South University.

Authors' contributions

Jian-Feng Fan and Sheng Huang co-wrote the first and final drafts of this case report. Jing Li collected patient's medical records. Ren-Jun Peng, He Huang, Xi-Ping Ding made significant contributions to the first major revision of the manuscript and final manuscript revisions. Jian Xi and Li-Ping Jiang contributed to conceptualization, data analysis, manuscript editing, project administration and funding acquisition. All authors have read and agreed to the published version of the manuscript.

Funding

This work was supported by grants from teaching reform programs of Central South University (Project No. 2020ALK91 and No.7 for Pathogenic Organisms and Human Health).

Availability of data and materials

Data sharing is not applicable to this article as no datasets were generated or analyzed during the current study.

Ethics approval and consent to participate

Written informed consent for publication was obtained from the patient.

Consent for publication

Written informed consent for publication of their clinical details was obtained from the patient. A copy of the consent form is available for review by the editor of this journal.

Competing interests

All authors of this manuscript declare no competing interests.

References

1. Liu Q, Li M-W, Wang Z-D, Zhao G-H, Zhu X-Q. Human sparganosis, a neglected food borne zoonosis. Lancet Infect Dis. 2015;15(10):1226-1235.
2. Lu G, Shi D-Z, Lu Y-J, et al. Retrospective epidemiological analysis of sparganosis in mainland China from 1959 to 2012. Epidemiol Infect. 2014;142(12):2654-2661.

3. Lin X, Liu C, Zhang H, et al. [Epidemiological investigation on sparganosis mansoni and animal experiments]. Zhongguo Ji Sheng Chong Xue Yu Ji Sheng Chong Bing Za Zhi. 2010;28(2):132-134.
4. Yun SJ, Park M-S, Jeon H-K, Kim Y-J, Kim W-J, Lee S-C. A Case of Vesical and Scrotal Sparganosis Presenting as a Scrotal Mass. Korean J Parasitol. 2010;48(1):57-59.
5. Matsuki M, Higashiyama A. Pulmonary Sparganosis: Tunnel Sign and Migrating Sign on Computed Tomography. Intern Med. 2021;60(4):601-604.
6. Liao H, Li D, Zhou B, et al. Imaging characteristics of cerebral sparganosis with live worms. J Neuroradiol J Neuroradiol. 2016;43(6):378-383.
7. Cui J, Li N, Wang ZQ, Jiang P, Lin XM. Serodiagnosis of experimental sparganum infections of mice and human sparganosis by ELISA using ES antigens of Spirometra mansoni spargana. Parasitol Res. 2011;108(6):1551-1556.
8. Hong D, Xie H, Wan H, An N, Xu C, Zhang J. Efficacy comparison between long-term high-dose praziquantel and surgical therapy for cerebral sparganosis: A multicenter retrospective cohort study. de Silva N, ed. PLoS Negl Trop Dis. 2018;12(10):e0006918.

Figures

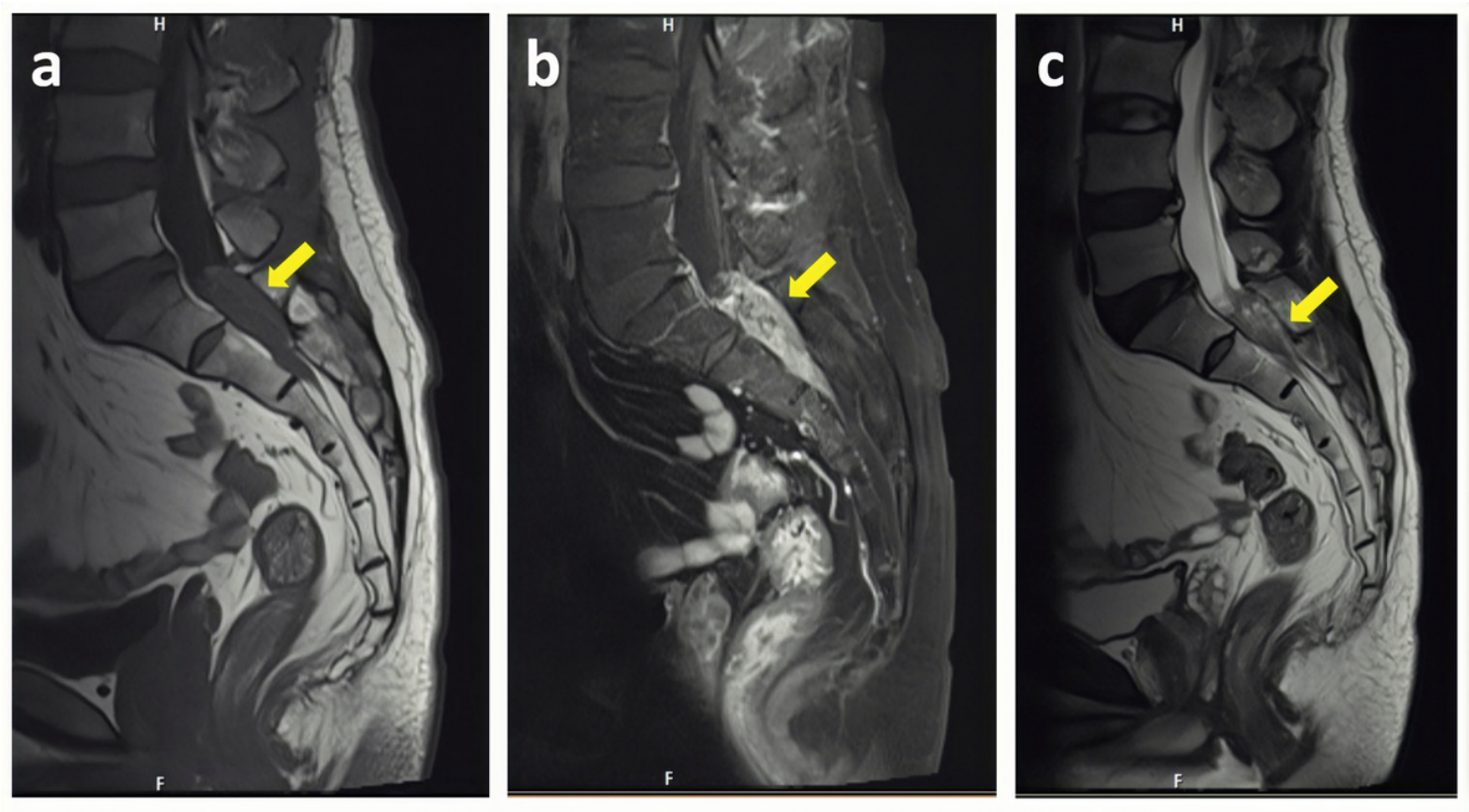

Figure 1

Magnetic resonance imaging lumbosacral spines, sagittal plane: T1WI (a), gadolinium-enhanced T1WI (b) and T2WI (c) showed a 1.7*1.5*5.4-cm lesion (yellow arrow) at the S1-S2 level. The lesion exhibited

mixed isosignal intensity at T1WI, iso/hypersignal intensity at T2WI and heterogeneous and irregular enhancement at T1WI with GD. And there are cystic changes within the lesion.

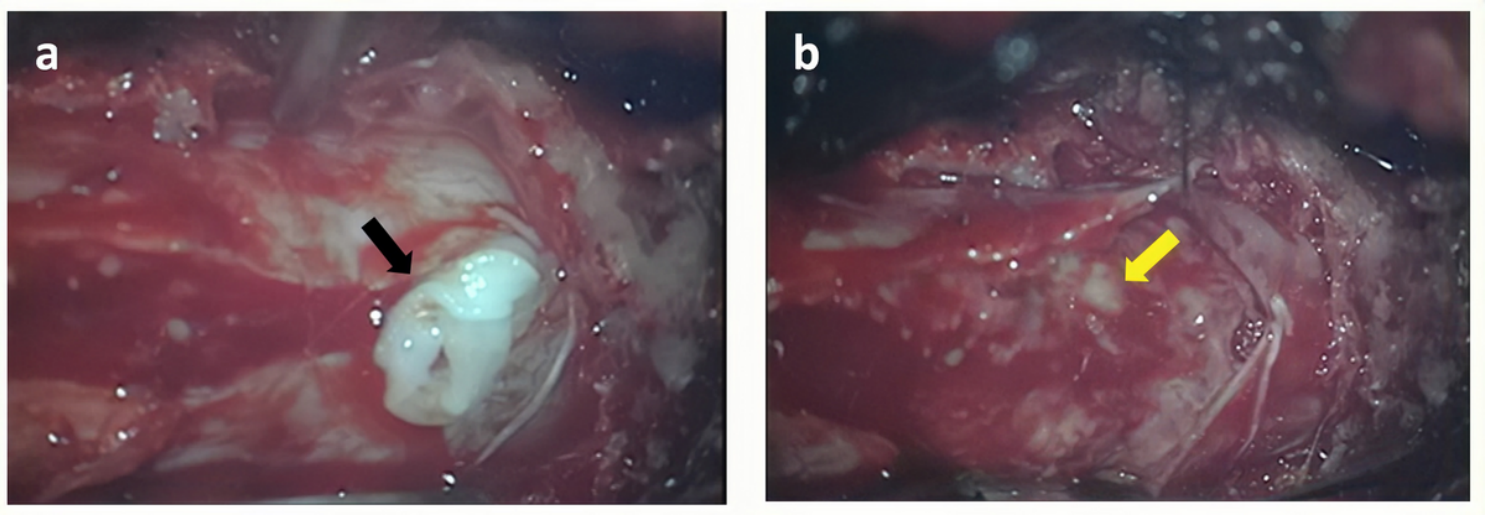

Figure 2

Operative field pictures: After incision of the dura, the live worm (a, black arrow) was located at inferior margin of L5. After removal of the worm, obvious proliferation of subdural granulation tissue was observed (b, yellow arrow).

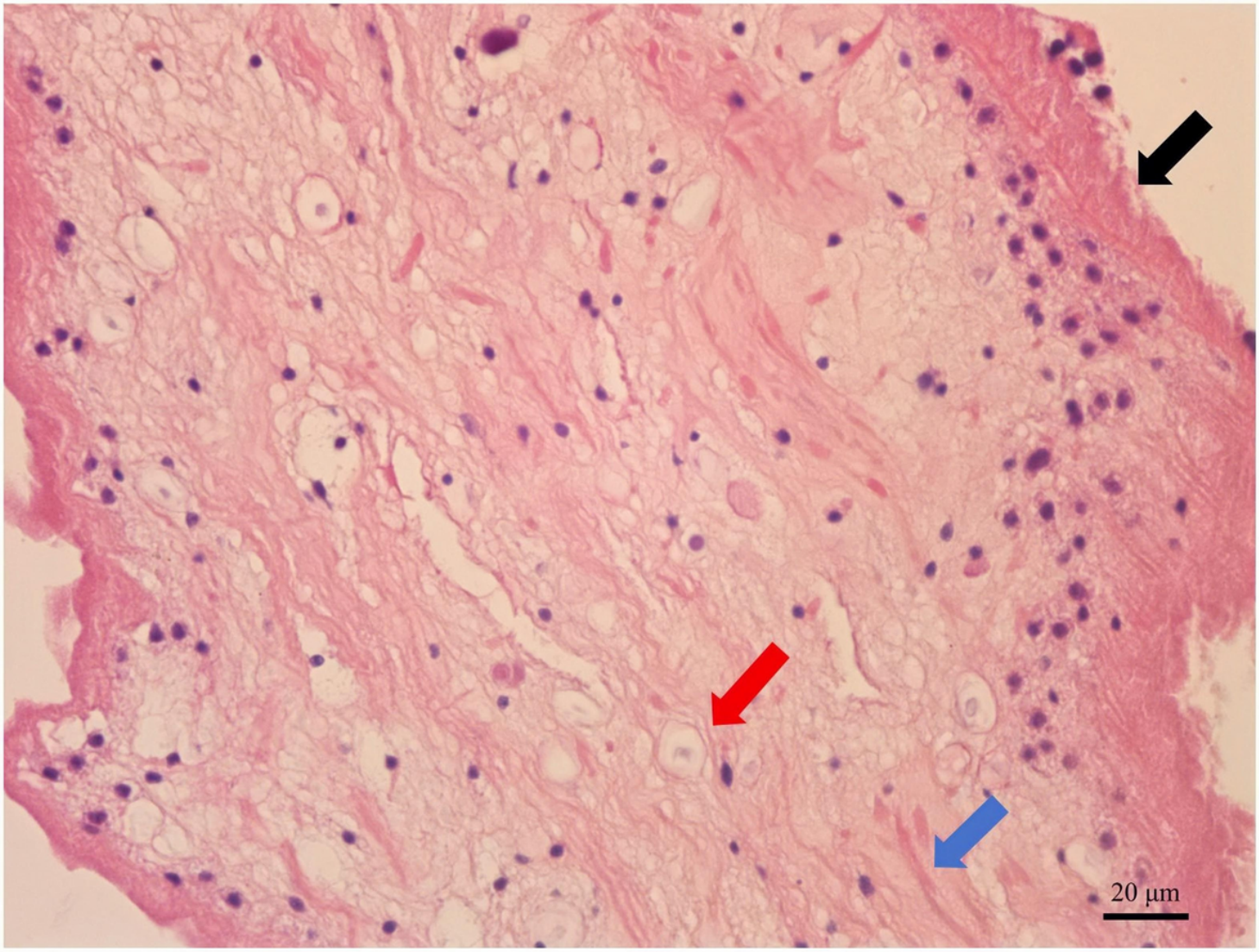

Figure 3

Hematoxylin and eosin-stained section: the pathological photograph revealed a parasitic worm with a thick eosinophilic tegumental structure (black arrow), The subtegumental layer showed several calcareous corpuscles (red arrow) and muscle fibres (blue arrow) in a loose parenchyma.

Supplementary Files

This is a list of supplementary files associated with this preprint. Click to download.

- Additionalfile1.mp4