Does Conventional Specimen Radiography After Neoadjuvant Chemotherapy of Breast Cancer Help To Reduce The Rate of Second Surgeries?

Benedikt Schaefgen (b.schaefgen@gmx.de)
University Clinic Heidelberg https://orcid.org/0000-0002-9725-1716

Annika Funk
UniversitätsKlinikum Heidelberg Frauenklinik: UniversitatsKlinikum Heidelberg Frauenklinik

Peter Sinn
Universitatsklinikum Heidelberg Pathologisches Institut

Thomas Bruckner
Universitatsklinikum Heidelberg IMBI: Universitatsklinikum Heidelberg Institut fur Medizinische Biometrie

Christina Gomez Andreu
UniversitätsKlinikum Heidelberg Frauenklinik: UniversitatsKlinikum Heidelberg Frauenklinik

Aba Harcos
UniversitätsKlinikum Heidelberg Frauenklinik: UniversitatsKlinikum Heidelberg Frauenklinik

Anne Stieber
Universitätsklinikum Heidelberg: Klinik für Radiologie

Annabelle Haller
UniversitätsKlinikum Heidelberg Frauenklinik: UniversitatsKlinikum Heidelberg Frauenklinik

Juliane Nees
UniversitätsKlinikum Heidelberg Frauenklinik: UniversitatsKlinikum Heidelberg Frauenklinik

Riku Togawa
UniversitätsKlinikum Heidelberg Frauenklinik: UniversitatsKlinikum Heidelberg Frauenklinik

André Pfob
UniversitätsKlinikum Heidelberg Frauenklinik: UniversitatsKlinikum Heidelberg Frauenklinik

André Hennigs
UniversitätsKlinikum Heidelberg Frauenklinik: UniversitatsKlinikum Heidelberg Frauenklinik

Johanna Hederer
UniversitätsKlinikum Heidelberg Frauenklinik: UniversitatsKlinikum Heidelberg Frauenklinik

Fabian Riedel
UniversitätsKlinikum Heidelberg Frauenklinik: UniversitatsKlinikum Heidelberg Frauenklinik

Sarah Fastner
UniversitätsKlinikum Heidelberg Frauenklinik: UniversitatsKlinikum Heidelberg Frauenklinik

Christof Sohn
UniversitätsKlinikum Heidelberg Frauenklinik: UniversitatsKlinikum Heidelberg Frauenklinik
Joerg Heil
UniversitätsKlinikum Heidelberg Frauenklinik: UniversitatsKlinikum Heidelberg Frauenklinik
Michael Golatta
UniversitätsKlinikum Heidelberg Frauenklinik: UniversitatsKlinikum Heidelberg Frauenklinik

---

Research Article

Keywords: breast cancer, breast conserving therapy, surgical margins, intraoperative re-excision, specimen radiography, neoadjuvant chemotherapy

Posted Date: August 9th, 2021

DOI: https://doi.org/10.21203/rs.3.rs-700849/v1

Version of Record: A version of this preprint was published at Breast Cancer Research and Treatment on December 8th, 2021. See the published version at https://doi.org/10.1007/s10549-021-06466-3.

Abstract

Purpose

This is the first study to systematically evaluate the diagnostic accuracy of intraoperative specimen radiography on margin level and its potential to reduce second surgeries in patients treated with neoadjuvant chemotherapy.

Methods

This retrospective study included 174 cases receiving breast conserving surgery (BCS) after neoadjuvant chemotherapy (NACT) of primary breast cancer. Conventional specimen radiography (CSR) was performed to assess potential margin infiltration of the target lesion and recommend an intraoperative re-excision of any radiologically positive margin. The histological workup of the specimen served as gold standard for the evaluation of the accuracy of CSR and the potential reduction of second surgeries by CSR-guided re-excisions. A subgroup analysis was performed for patients with and without clinical complete response.

Results

1044 margins were assessed. Of 47 (4.5%) histopathological positive margins, CSR identified 9 correctly (true positive). 38 infiltrated margins were missed (false negative). This resulted in a sensitivity of 19.2%, a specificity of 89.2%, a PPV of 7.7% and a NPV of 95.9%. The rate of secondary procedures was reduced from 23 to 16 with a number needed to treat (NNT) of CSR guided intraoperative re-excisions of 25.

In the subgroup of patients with cCR, the prevalence of positive margins was 10/510 (2.0%), PPV was 1.9% and the NNT was 85.

Conclusion

Positive margins after NACT are rare and CSR has only a low sensitivity to detect them. Thus, the rate of secondary surgeries cannot be significantly reduced by recommending targeted re-excisions, especially in cases with cCR.

Introduction

In the past decades, breast conserving surgery (BCS) has become the standard of care for most women with early breast cancer, and leads to equal[1, 2] or superior[3, 4] overall survival compared to mastectomy. Additionally, neoadjuvant chemotherapy (NACT) has become the standard approach for high-risk cancer patients and often leads to a significant reduction of tumor mass. Often this allows a further reduction of the extent of breast surgeries, which contributes to an improvement of the aesthetic outcome and patient satisfaction[5–7] as well as a higher quality of life[8, 9] and a reduced risk of postoperative complications. The surgeon should try to remove as little healthy tissue as possible whilst

avoiding tumor-infiltrated (positive) resection margins, which are a risk factor for local recurrence[10]. Conventional specimen radiography (CSR) using mammography in two orthogonal orientations is used to assess the margin status and recommend intraoperative re-excision if necessary. Ideally, this leads to tumor free resection margins and can help to avoid a secondary re-excision. One recent study performed at our breast unit assessed the efficacy of CSR on both margin and case level for the recommendation of targeted resections in a cohort of patients with primary surgical treatment[11]. In this study with patients who did not receive NACT, a reduction of infiltrated margins from 11–4%, translating to a reduction of secondary procedures from 34.5–21.7% on case level, was reported[12] [13]. The authors concluded that CSR is a helpful tool to support the approach of tissue-sparing surgery since CSR helps to prevent secondary procedures by identifying infiltrated margins and recommending selective re-excisions.

However, the proportion of patients who actually benefit from CSR depends on the prevalence of initially positive margins. Thanks to more frequent administration and more effective systemic treatment options, an increasing number of patients achieve a pathological complete response (pCR) after NACT[14]. Thus, the prevalence of initially positive margins is expected to be lower in patients after NACT and the use of CSR might be questionable in the postneoadjuvant setting[15]. In this study, we evaluate the diagnostic accuracy and efficacy of CSR after NACT to address this increasingly frequent constellation.

Material And Methods

This study was approved by the ethics committee of the University's Medical Faculty under file number S-468/2016.

Patient Population

Patients treated at the Breast Unit with BCS after NACT of invasive breast cancer between January 2014 and December 2015 were included consecutively in the analysis. Cases that did not receive CSR (n = 57), mostly for reasons of palpability, or did not receive NACT (n = 471) were excluded from further analysis. For subgroup analysis, patients´ response to NACT was classified as clinical complete response (cCR; defined as the absence of evidence of residual tumor in clinical examination, ultrasound, and mammography after NACT) and non-cCR.

Conventional specimen radiography and surgical procedure

According to current guidelines, preoperative wire-localization using ultrasound or stereotactic guidance was performed and controlled by mammography. Tumors with good palpability or direct vicinity to the skin were not wire-marked.

Directly after resection, the specimen orientation was marked by sutures of different lengths on the cranial, medial and lateral surface according to institutional standard operating procedures. CSR was performed in the breast unit using Mammomat Inspiration (Siemens AG, Erlangen, Germany) with 1.4x direct magnification in two orthogonal views. One of six physicians with more than ten years of

experience in diagnostic mammography and CSR evaluated the position of the target lesion and its relation to the resection margins. If any of the margins appeared to be infiltrated, the radiologist advised the surgeon to perform an intraoperative re-excision of the same orientation.

The pathologic workup of the specimen and the re-excisions was the gold standard for the evaluation of the diagnostic accuracy of CSR. According to the national guideline at the time of data collection (2014–2015), a positive margin was defined as < 1mm in invasive carcinoma and < 2mm in ductal carcinoma in situ (DCIS)[16], defining the indication for re-excision. According to the guideline of 2017, a clear margin was defined as “no ink on tumor”[17].

Statistical Analysis

Descriptive analyses were performed to assess patient and tumor characteristics using IBM SPSS Statistics Version 26, (Armong, NY, USA). Sensitivity and specificity of CSR was calculated along with 95% confidence intervals using SAS 9.4 WIN (Cary, NC, USA). One sided Chi-square-test was used to assess the level of significance of the differences in sensitivity and specificity among the subgroups. P-values are not adjusted for multiplicity and must be interpreted descriptively.

The primary endpoint was the NNT to avoid a second surgery by CSR-guided intraoperative resections.

Results

174 patients received BCS after NACT and were included in this analysis (Table 1). For each primary resection specimen, six margins were assessed (1044 in total).

85 Patients (48.9%) had a clinical complete response (cCR), whereas 89 (51.1%) had no cCR. In 82 cases (47.1%), NACT resulted in a pCR (ypT0).

Histopathological margin infiltration by orientations

The histopathological workup of the main specimen (without re-excisions), showed an infiltration of 47 (4.5%) margins. The cranial and dorsal orientation most frequently showed margin involvement (14 positive margins, 1.3%), the least frequently infiltrated orientation was medial and lateral (three positive margins, 0.3%).

Table 1
Patient and tumor characteristics

number of patients	(n = 174) (percentages in brackets)
age	
mean	51.4 (12.2)
range	24 to 82
ethnicity	not systematically assessed, mostly European
cup size	
A	5 (2.9)
B	46 (26.4)
C	26 (14.9)
D	14 (8.0)
E	2 (1.1)
F	1 (0.6)
unknown	80 (45.4)
menopausal status	
premenopausal	62 (35.6)
menopausal	22 (12.6)
postmenopausal	90 (51.7)
remission status	
cCR	85 (48.9)
with pCR (%)	58 (68.2)
non cCR	89 (51.1)
with pCR (%)	25 (28.1)
final T-stadium (ypT)	

number of patients	(n = 174) (percentages in brackets)
0	82 (47.1)
is	11 (6.3)
1	62 (35.6)
– 1mic	1 (0.6)
– 1a	19 (10.9)
– 1b	14 (8.0)
– 1c	28 (16.1)
2	17 (9.8)
3	1 (0.6)
4	-
median specimen weight	
primary resection	38.0g (range 5; 268)
re-resection	7.6g (range 1; 41)
Histologically Infiltrated margins by orientation	
total	47 (4.5)
medial	3 (0.3)
lateral	3 (0.3)
kranial	14 (1.3)
kaudal	9 (0.9)
ventral	4 (0.4)
dorsal	14 (1.3)

cCR: clinical complete response, pCR: pathological complete response

Margin assessment by CSR

In total, 1044 margins were analyzed with CSR (Table 2), of which 117 (11.2%) were radiologically positive. Nine (0,9%) were histologically and radiologically positive (true positive CSR). Based on the correct identification by CSR, these margins could be re-resected in the same surgery, potentially reaching a final negative margin state in the same surgery.

108 (10.3%) histopathologically clear margins were falsely assessed as positive by CSR. In these cases, healthy tissue was re-resected unnecessarily if the surgeon followed the recommendation for re-excision.

Of 927 radiologically negative margins, 38 (4.1%) were histologically infiltrated (false negative CSR). In these cases, no recommendation for re-excision was given based on CSR and the final margin status in the first surgery was positive (unless the surgeon performed a re-excision based on gross-inspection), resulting in the necessity for a second surgery.

Comparison of of margin assessment between cCR and non-cCR patients

Regarding all 1044 margins, CSR had a sensitivity of 19.2%, specificity of 89.2%, PPV of 7.7% and NPV of 95.9%.

In 510 margins of the subgroup of cCR patients, the prevalence of histologically positive margins was 10 of 510 (2.0%). One of these margins was correctly diagnosed as radiologically positive (true positive CSR, 10.0%). In contrast, 51 of 500 histologically negative margins (10.2%) were false positive in CSR.

Compared to the non-cCR patients, there was no relevant difference in specificity (89.8% versus 88.5%, $p = 0.542$). Sensitivity (10.0% versus 21.6%, $p = 0.660$) and PPV (1.9% versus 12.3%, $p = 0.076$) were lower in the cCR subgroup, but the differences were not statistically significant.

Table 2

Evaluation of Conventional Specimen Radiography on a margin level for the whole and for patients with clinical complete response versus no clinical complete response.

	overall cohort		**clinical complete response (cCR)**		**no clinical complete response (non-cCR)**		**total––no. (%)**
	CSR positive	CSR negative	CSR positive	CSR negative	CSR positive	CSR negative	–
reference test positive*	9	38	1	9	8	29	–
reference test negative**	108	889	51	449	57	440	–
total––no. (%)	1044 (100%)		510 (100%)		534 (100%)		–
		(95% CI)		95% CI)		95% CI)	*P* value***
sensitivity––% (95% CI)	19.2%	(9.2–33.3%)	10.0%	(0.3–44.5%)	21.6%	(9.8–38.2%)	0.660
specificity––% (95% CI)	89.2%	(87.1–91.0%)	89.8%	(86.8–92.3%)	88.5%	(85.4–91.2%)	0.542
PPV––% (95% CI)	7.7%	(3.6–14.1)	1.9%	(0.1–10.3%)	12.3%	(5.5–22.8%)	0.076
NPV––% (95% CI)	95.9%	(94.4–97.1%)	98.0%	(96.3–99.1%)	93.8%	(91.2–95.8)	0.001
margin conversion through CSR––no. (%)	15	(1.4%)	1	(0.2%)	14	(2.6%)	
NNT	70		510	38			

cCR: clinical complete response, CSR: Conventional Specimen Radiography, NACT: neoadjuvant chemotherapy, NNT: number needed to treat, NPV: negative predictive value, PMR: positive margin rate, PPV: positive predictive value

* tumor infiltrated margin in histopathologic evaluation of the surgical specimen

** no tumor infiltrated margin in histopathologic evaluation of the surgical specimen

*** for clinical complete response versus no clinical complete response

Intraoperative re-excisions and final positive margin status on case level

In 95 (54.6%) patients, at least one intraoperative re-excision was performed *(*Table 3*)*. In 79 (83.2%) cases, this turned out to be unnecessary, because all margins were histopathologically negative. In 16 (9.2%) cases, margin infiltration was confirmed in histopathological examination. In 6 (3.4%) cases, all histologically infiltrated margins were correctly identified by CSR. In the remaining 10 (5.7%) cases, at least one histologically infiltrated margin was missed by CSR. Through intraoperative re-excisions, the number of infiltrated margins could be reduced from initially 47 (4.5%) to 32 (3.1%).

Effect of CSR-guided resections on secondary procedures

In the whole cohort, 23 patients would have required further surgery if no margin assessment and no re-excisions had been carried out. Through intraoperative re-excisions based on CSR together with the gross assessment by the surgeon, clear margins were reached in 16 patients in the primary surgery. Thus, the rate of secondary procedures was reduced by 30.4%, resulting in a NNT of 25. In the cCR subgroup, the rate of secondary surgeries was reduced by 14.3% from seven to six patients by CSR guided re-excisions. This translates to a NNT of 85 in the cCR subgroup.

Table 3 shows the effect of CSR guided re-resections on the final margin status and reduction of secondary surgeries on case level.

Table 3
Effect of CSR guided re-resections on the final margin status and reduction of secondary surgeries case level

	overall cohort	**cCR after NACT**	**non-cCR after NACT**
number of cases	174 (100%)	85 (100%)	89 (100%)
initial PMR	25 (14.3%)	7 (8.2%)	18 (20.2%)
final PMR	17 (9.8%)	6 (7.1%)	11 (12.4%)
conversion of margin status through CSR	8 (4.6%)	1 (1.1%)	7 (7.9%)
NNT for conversion of margin status through CSR	22	85	13
secondary surgeries	16 (9.2%)	6 (7.1%)	10 (11.2%)
number of secondary surgeries avoided through CSR	7 (4%)	1 (1.1%)	6 (6.7%)
NNT to avoid secondary surgeries through CSR	25	85	15

cCR: clinical complete response, CSR: Conventional Specimen Radiography, NACT: neoadjuvant chemotherapy, NNT: number needed to treat, PMR: positive margin rate

Comparison with the efficacy of CSR in a cohort of patients without NACT

In Table 4, we compare the results to the previously published data from a cohort without NACT from the same breast unit. On the margin level, we found a similar specificity (86.8%, versus 89.8%, p = 0.055), but a significantly lower sensitivity (19.2%) in the NACT cohort compared to the non-NACT cohort (36.8%; p = 0.012). Due to the low prevalence of infiltrated margins after NACT 47 (4.5%), the PPV is much lower after NACT than in the non-NACT cohort (7.7% vs. 25.6%). This means that a radiologically positive margin in CSR is also histologically positive with a chance of 7.7%.

Table 4
Analysis of CSR in Patients with and without NACT on margin level

	no NACT[a]		**NACT**		**p-value**
total margins	(n = 2826)	(95% CI)	(n = 1044)	(95% CI)	
infiltrated margins	310 (11.0%)		47 (4.5%)		
sensitivity	36.8%	(31.4–42.2%)	19.1%	(9.2–33.3%)	0.012*
specificity	86.8%	(85.5–88.1%)	89.2%	(87.1–91.0%)	0.055*
positive predictive value (PPV)	25.6%	(21.6–29.7%)	7.7%	(3.6–14.1%)	< 0.001*
negative predictive value (NPV)	91.8%	(90.7–92.9%)	95.9%	(94.4–97.1%)	< 0.001*

[a] data from a previously published analysis[11]. CI: confidence interval, NACT: neoadjuvant chemotherapy

Discussion

There are numerous studies on the use of CSR, but comparability of the results is limited, mostly because the accuracy of CSR is not evaluated on a margin level[12, 18–21]. A meta-analysis by Versteegden et al. reported a large range of sensitivity from 22–77%, specificity from 51–100% and PPV from 51–100%, due to a large clinical and methodological diversity with low comparability of the studies.[22] While some studies[23–25], including a recent review by Gray et al.[26], indicate that CSR is not able to reduce the rate of positive margins and hence, the reoperation rate, Ciccarelli et al. and Chagpar et al. describe a reduction of the rate of second surgeries from 31–21% [12] and 37.8–28.9% [13].

The diagnostic accuracy of CSR in the present study including only patients after NACT was comparable to the results reported in the literature for non-selected cohorts, with sensitivity and specificity of 19.2% and 89.2%, respectively. However, the prevalence of initially positive margins was low in the overall cohort (n = 47, 4.5%) and even lower in the cCR-cohort (n = 10, 2.0%). One should note that the NNT depends on the prevalence of initially positive margins. Consequently, only a few patients can potentially benefit from intraoperative re-excisions led by CSR, even if CSR had a higher sensitivity. Accordingly, the NNT were 25

in all NACT patients and 85 in the cCR subgroup. This means that 84 of 85 patients with a cCR would not benefit from CSR, while one second surgery could be avoided. Whether this is an acceptable rate, has to be discussed from a patient-based, clinical perspective. Listening to our patients' voice has gained more importance during the past years and should be considered as the tipping point in such controversial risk-benefit evaluations[27].

Notably, a positive margin status after the primary surgery usually results in residual disease, potentially effecting the oncologic safety. In these cases, a secondary re-excision will be recommended based on the pathological workup of the specimen. Yet, some patients might decline a second surgery and thus do not achieve a finally negative margin. In this constellation, an intraoperative re-excision could have a relevant positive impact on long-term patient related outcomes. On the other hand, not in all cases with R1-status, a re-resection will be performed, e.g. if the dorsal margin is infiltrated, but the primary resection already reached the dorsal muscle fascia.

If a second surgery can be avoided, patients also have a psychological advantage, because they do not have to wait one or two weeks for the surgical treatment to be completed. Additionally, even though a second surgery is usually a short procedure with a low complication rate, it includes a second general anesthesia with according risks. Lastly, esthetic outcome tends to be worse if two surgeries are necessary for definite treatment[28].

False positives

The false positive rate of all assessed margins was 10.3%, which could lead to the unnecessary removal of healthy tissue if the recommendation for an intraoperative re-excision was followed. In general, the amount of healthy tissue removed should be kept to a minimum. The impact of the re-excision on the esthetic outcome depends on the relation between the removed tissue and the breast size. [5, 29] The median specimen weight of the re-excisions in our study was 7.6g (range 1; 41). Five patients (2.9%) had cup A, 46 patients (26.4%) had cup B. In these patients with small breasts, even minimal re-excisions with unnecessary removal of tissue could have a relevant effect on the esthetic outcome.

One explanation for the high false positive rate might be that the radiologist performing CSR might intuitively judge a false positive diagnosis as less severe than a false negative for maximum oncologic safety and would in unclear cases more likely report a positive than a negative margin. In addition, there is no consensus on which radiological margin width should result in a recommendation for re-excision.

Another possible explanation might be shrinkage of the surgical specimen described as "pancake phenomenon" by Graham et al. Upon resection, the specimen decreases in height and volume and appears flattened, which results in apparently smaller safety margins and can contribute to a false positive margin assessment. Inadequate compression of the specimen during CSR further contributes to a distortion of the tumor-margin-relation[30]. A dedicated training of radiology technicians emphasizing the specific requirements of CSR should be performed to avoid excessive specimen compression.

Finally, a large part of the lesion can be necrotic or fibrotic due to therapy induced tumor regression after NACT, which can falsely appear like residual tumor and lead to decreased accuracy of the radiological assessment [31, 32].

Comparison of cCR versus non-cCR cases

With increasing efficacy of NACT, more and more patients reach a pathological complete response (pCR). In the literature, pCR rates around 30–60% depending on breast cancer subtype are reported[14, 33, 34]. A clinical complete response (cCR) predicts a pCR with a NPV of 44–61%. This means that in patients with a cCR, there is a high chance that the complete remission is confirmed histologically[35]. In our analysis, this applied to 68.2% of all cCR cases. Transferred to the question of margin assessment, one would expect a very low prevalence of positive margins in patients with a cCR, since many of these will have no residual tumor. In our analysis, we found only 10/510 (2.0%) positive margins in the cCR cohort, compared to 37/534 (6.9%) in the non-cCR cases. This very low prevalence of infiltrated margins and a true positive rate of 0.2% lead to a PPV of only 1.9% in the cCR group, compared to a PPV of 12.3% in the non-cCR group. As a result, the NNT of 85 to avoid one second surgery on case level is very high in the cCR group, versus 15 in the non-cCR group. In fact, when costs and risks of CSR guided re-resections are balanced, CSR does not seem to be an appropriate approach for patients with a cCR after NACT. Considering current efforts to eliminate breast cancer surgery in exceptional responders to NACT, the clinical use of CSR for these patients may further decrease[36].

Limitations

Since this is a retrospective study, no change of clinical practice can be recommended based on the results. Although we assessed 1044 margins, the power of the statistical analysis is limited by the low prevalence of positive margins especially in the cCR-subgroup. Due to the increasing effectivity of NACT, it can be expected that the rate of initially positive margins will further decrease in the future, making this an even more relevant aspect questioning the use of CSR after NACT. In the future, CSR might be used to confirm that a clip-marked, regressive tumorbed is included in the specimen, with less focus on the margin assessment.

One limitation in the study design is that re-excisions could be performed not only based on the recommendation of CSR but also on the subjective assessment of the surgeons (e.g according to their clinical impression after gross inspection of the specimen and palpation of the operation site). In future studies, the surgeon should be asked to document systematically what influenced their decision to perform a re-excision (recommendation from CSR versus subjective decision).

An important source of error is the orientation and marking of the specimen. In the literature, rates of disorientation up to 31.1%, are reported, particularly in small specimens[37]. At our clinic, there are clear instruction for a standardized marking of the specimen orientation, which should help to reduce the error rate. Still, depending on size, form and texture of the specimen, a clear marking can be challenging.

Due to the low prevalence of positive margins in the whole cohort, we did not perform a subgroup analysis by tumor biology. However, tumor subtypes differ regarding the patterns of tumor regression, which leads to heterogeneous radiological appearances. It seems likely that this also influences the accuracy of CSR. In future studies with sufficient sample size for subgroup analyses, tumor biological subtypes should be considered.

Conclusion

The prevalence of initially positive margins after NACT and the sensitivity of CSR to detect them are low. Thus, very few patients after NACT benefit from a CSR guided intraoperative re-excision, especially in cases with cCR. A large proportion of patients might be overtreated if CSR is performed and the recommendation for re-excision is followed. Balancing the benefit of a few spared second surgeries in relation to the much more frequent unnecessary or even harmful re-excisions after CSR, the use of CSR cannot be generally recommended after NACT, particularly if a cCR was reached.

Abbreviations

BCS: breast conserving surgery

cCR: clinical complete response

CI: confidence interval

CSR: Conventional Specimen Radiography

NACT: neoadjuvant chemotherapy

NNT: number needed to treat

NPV: negative predictive value

pCR: pathological complete response

PMR: positive margin rate

PPV: positive predictive value

Declarations

Funding: Not applicable

Conflicts of interest

Conflict of Interest: The authors declare that they have no conflict of interest related to this study.

Availability of data and material: Upon request from the corresponding author

Code availability: not applicable

authors' contributions:

- Benedikt Schaefgen: Conceptualization, Methodology, Investigation, Writing - Original Draft

- Annika Funk: Conceptualization, Methodology, Investigation, Writing - Review & Editing

- Peter Sinn: Investigation, Resources, Writing - Review & Editing

- Thomas Bruckner: Formal analysis, Data Curation;

- Christina Gomez Andreu, Aba Harcos, Anne Stieber, Annabelle Haller, Juliane Nees, Riku Togawa, André Pfob, André Hennigs, Johanna Hederer, Fabian Riedel, Sarah Fastner: Investigation, Resources, Writing - review & editing, Christof Sohn: Supervision; Resources;

- Joerg Heil: Investigation, Resources, Supervision, Writing - Review & Editing;

- Michael Golatta: Conceptualization, Investigation, Resources, Writing - Review & Editing, Project administration

Ethics approval: This study was approved by the ethics committee of the University's Medical Faculty under file number S-468/2016.

Consent to participate: not applicable (retrospective analysis of anonymized data

Consent for publication: given for all authors

References

1. Fisher B, Anderson S, Bryant J, Margolese RG, Deutsch M, Fisher ER, Jeong JH, Wolmark N: **Twenty-year follow-up of a randomized trial comparing total mastectomy, lumpectomy, and lumpectomy plus irradiation for the treatment of invasive breast cancer**. *N Engl J Med* 2002, **347**(16):1233-1241.

2. Veronesi U, Cascinelli N, Mariani L, Greco M, Saccozzi R, Luini A, Aguilar M, Marubini E: **Twenty-year follow-up of a randomized study comparing breast-conserving surgery with radical mastectomy for early breast cancer**. *The New England journal of medicine* 2002, **347**(16):1227-1232.

3. Hofvind S, Holen A, Aas T, Roman M, Sebuodegard S, Akslen LA: **Women treated with breast conserving surgery do better than those with mastectomy independent of detection mode, prognostic and predictive tumor characteristics**. *European journal of surgical oncology : the journal of the European Society of Surgical Oncology and the British Association of Surgical Oncology* 2015, **41**(10):1417-1422.

4. Hwang ES, Lichtensztajn DY, Gomez SL, Fowble B, Clarke CA: **Survival after lumpectomy and mastectomy for early stage invasive breast cancer: the effect of age and hormone receptor status**. *Cancer* 2013, **119**(7):1402-1411.

5. Hennigs A, Hartmann B, Rauch G, Golatta M, Tabatabai P, Domschke C, Schott S, Schutz F, Sohn C, Heil J: **Long-term objective esthetic outcome after breast-conserving therapy**. *Breast Cancer Res Treat* 2015, **153**(2):345-351.

6. Foersterling E, Golatta M, Hennigs A, Schulz S, Rauch G, Schott S, Domschke C, Schuetz F, Sohn C, Heil J: **Predictors of early poor aesthetic outcome after breast-conserving surgery in patients with breast cancer: initial results of a prospective cohort study at a single institution**. *J Surg Oncol* 2014, **110**(7):801-806.

7. Volders JH, Negenborn VL, Haloua MH, Krekel NMA, Jozwiak K, Meijer S, van den Tol PM: **Breast-specific factors determine cosmetic outcome and patient satisfaction after breast-conserving therapy: Results from the randomized COBALT study**. *J Surg Oncol* 2018, **117**(5):1001-1008.

8. Heil J, Holl S, Golatta M, Rauch G, Rom J, Marme F, Gebauer G, Sohn C: **Aesthetic and functional results after breast conserving surgery as correlates of quality of life measured by a German version of the Breast Cancer Treatment Outcome Scale (BCTOS)**. *Breast* 2010, **19**(6):470-474.

9. Waljee JF, Hu ES, Ubel PA, Smith DM, Newman LA, Alderman AK: **Effect of esthetic outcome after breast-conserving surgery on psychosocial functioning and quality of life**. *J Clin Oncol* 2008, **26**(20):3331-3337.

10. Horst KC, Smitt MC, Goffinet DR, Carlson RW: **Predictors of local recurrence after breast-conservation therapy**. *Clin Breast Cancer* 2005, **5**(6):425-438.

11. Funk A, Heil J, Harcos A, Gomez C, Stieber A, Junkermann H, Hennigs A, Rauch G, Sinn HP, Riedel F *et al*: **Efficacy of intraoperative specimen radiography as margin assessment tool in breast conserving surgery**. *Breast Cancer Res Treat* 2020, **179**(2):425-433.

12. Ciccarelli G, Di Virgilio MR, Menna S, Garretti L, Ala A, Giani R, Bussone R, Canavese G, Berardengo E: **Radiography of the surgical specimen in early stage breast lesions: diagnostic reliability in the analysis of the resection margins**. *Radiol Med* 2007, **112**(3):366-376.

13. Chagpar AB, Butler M, Killelea BK, Horowitz NR, Stavris K, Lannin DR: **Does three-dimensional intraoperative specimen imaging reduce the need for re-excision in breast cancer patients? A prospective cohort study**. *Am J Surg* 2015, **210**(5):886-890.

14. von Minckwitz G, Untch M, Blohmer JU, Costa SD, Eidtmann H, Fasching PA, Gerber B, Eiermann W, Hilfrich J, Huober J *et al*: **Definition and impact of pathologic complete response on prognosis after**

neoadjuvant chemotherapy in various intrinsic breast cancer subtypes. *J Clin Oncol* 2012, **30**(15):1796-1804.

15. Heil J, Kuerer HM, Pfob A, Rauch G, Sinn HP, Golatta M, Liefers GJ, Vrancken Peeters MJ: **Eliminating the breast cancer surgery paradigm after neoadjuvant systemic therapy: current evidence and future challenges**. *Ann Oncol* 2020, **31**(1):61-71.

16. **Interdisziplinäre S3-Leitlinie für die Diagnostik, Therapie und Nachsorge des Mammakarzinoms** [http://www.awmf.org/uploads/tx_szleitlinien/032-045OL_k_S3__Brustkrebs_Mammakarzinom_Diagnostik_Therapie_Nachsorge_2012-07.pdf]

17. Fachgesellschaften AdWM: **Interdisziplinäre S3-Leitlinie für die Früherkennung, Diagnostik, Therapie und Nachsorge des Mammakarzinoms**. 2017.

18. McCormick JT, Keleher AJ, Tikhomirov VB, Budway RJ, Caushaj PF: **Analysis of the use of specimen mammography in breast conservation therapy**. *Am J Surg* 2004, **188**(4):433-436.

19. Hisada T, Sawaki M, Ishiguro J, Adachi Y, Kotani H, Yoshimura A, Hattori M, Yatabe Y, Iwata H: **Impact of intraoperative specimen mammography on margins in breast-conserving surgery**. *Mol Clin Oncol* 2016, **5**(3):269-272.

20. Schmachtenberg C, Engelken F, Fischer T, Bick U, Poellinger A, Fallenberg EM: **Intraoperative specimen radiography in patients with nonpalpable malignant breast lesions**. *Rofo* 2012, **184**(7):635-642.

21. Mazouni C, Rouzier R, Balleyguier C, Sideris L, Rochard F, Delaloge S, Marsiglia H, Mathieu MC, Spielman M, Garbay JR: **Specimen radiography as predictor of resection margin status in non-palpable breast lesions**. *Clin Radiol* 2006, **61**(9):789-796.

22. Versteegden DPA, Keizer LGG, Schlooz-Vries MS, Duijm LEM, Wauters CAP, Strobbe LJA: **Performance characteristics of specimen radiography for margin assessment for ductal carcinoma in situ: a systematic review**. *Breast Cancer Res Treat* 2017.

23. Rua C, Lebas P, Michenet P, Ouldamer L: **Evaluation of lumpectomy surgical specimen radiographs in subclinical, in situ and invasive breast cancer, and factors predicting positive margins**. *Diagn Interv Imaging* 2012, **93**(11):871-877.

24. Laws A, Brar MS, Bouchard-Fortier A, Leong B, Quan ML: **Does intra-operative margin assessment improve margin status and re-excision rates? A population-based analysis of outcomes in breast-conserving surgery for ductal carcinoma in situ**. *J Surg Oncol* 2018, **118**(7):1205-1211.

25. Laws A, Brar MS, Bouchard-Fortier A, Leong B, Quan ML: **Intraoperative Margin Assessment in Wire-Localized Breast-Conserving Surgery for Invasive Cancer: A Population-Level Comparison of Techniques**. *Annals of surgical oncology* 2016, **23**(10):3290-3296.

26. Gray RJ, Pockaj BA, Garvey E, Blair S: **Intraoperative Margin Management in Breast-Conserving Surgery: A Systematic Review of the Literature**. *Annals of surgical oncology* 2017.

27. Heil J, Pfob A: **Patients should be the tipping point of individualizing breast cancer surgery: Commentary on 'Eliminating the breast cancer surgery paradigm after neoadjuvant systemic therapy: current evidence and future challenges'**. *Ann Oncol* 2020, **31**(9):1264.

28. Dahlback C, Manjer J, Rehn M, Ringberg A: **Determinants for patient satisfaction regarding aesthetic outcome and skin sensitivity after breast-conserving surgery**. *World J Surg Oncol* 2016, **14**(1):303.

29. Cochrane RA, Valasiadou P, Wilson AR, Al-Ghazal SK, Macmillan RD: **Cosmesis and satisfaction after breast-conserving surgery correlates with the percentage of breast volume excised**. *Br J Surg* 2003, **90**(12):1505-1509.

30. Clingan R, Griffin M, Phillips J, Coberly W, Jennings W: **Potential margin distortion in breast tissue by specimen mammography**. *Arch Surg* 2003, **138**(12):1371-1374.

31. Helvie MA, Joynt LK, Cody RL, Pierce LJ, Adler DD, Merajver SD: **Locally advanced breast carcinoma: accuracy of mammography versus clinical examination in the prediction of residual disease after chemotherapy**. *Radiology* 1996, **198**(2):327-332.

32. Moskovic EC, Mansi JL, King DM, Murch CR, Smith IE: **Mammography in the assessment of response to medical treatment of large primary breast cancer**. *Clin Radiol* 1993, **47**(5):339-344.

33. Goorts B, van Nijnatten TJ, de Munck L, Moossdorff M, Heuts EM, de Boer M, Lobbes MB, Smidt ML: **Clinical tumor stage is the most important predictor of pathological complete response rate after neoadjuvant chemotherapy in breast cancer patients**. *Breast Cancer Res Treat* 2017, **163**(1):83-91.

34. Kagihara JA, Andress M, Diamond JR: **Nab-paclitaxel and atezolizumab for the treatment of PD-L1-positive, metastatic triple-negative breast cancer: review and future directions**. *Expert Rev Precis Med Drug Dev* 2020, **5**(2):59-65.

35. Schaefgen B, Mati M, Sinn HP, Golatta M, Stieber A, Rauch G, Hennigs A, Richter H, Domschke C, Schuetz F *et al*: **Can Routine Imaging After Neoadjuvant Chemotherapy in Breast Cancer Predict Pathologic Complete Response?** *Ann Surg Oncol* 2016, **23**(3):789-795.

36. Pfob A, Sidey-Gibbons C, Lee HB, Tasoulis MK, Koelbel V, Golatta M, Rauch GM, Smith BD, Valero V, Han W *et al*: **Identification of breast cancer patients with pathologic complete response in the breast after neoadjuvant systemic treatment by an intelligent vacuum-assisted biopsy**. *Eur J Cancer* 2021, **143**:134-146.

37. Molina MA, Snell S, Franceschi D, Jorda M, Gomez C, Moffat FL, Powell J, Avisar E: **Breast specimen orientation**. *Ann Surg Oncol* 2009, **16**(2):285-288.

Figures

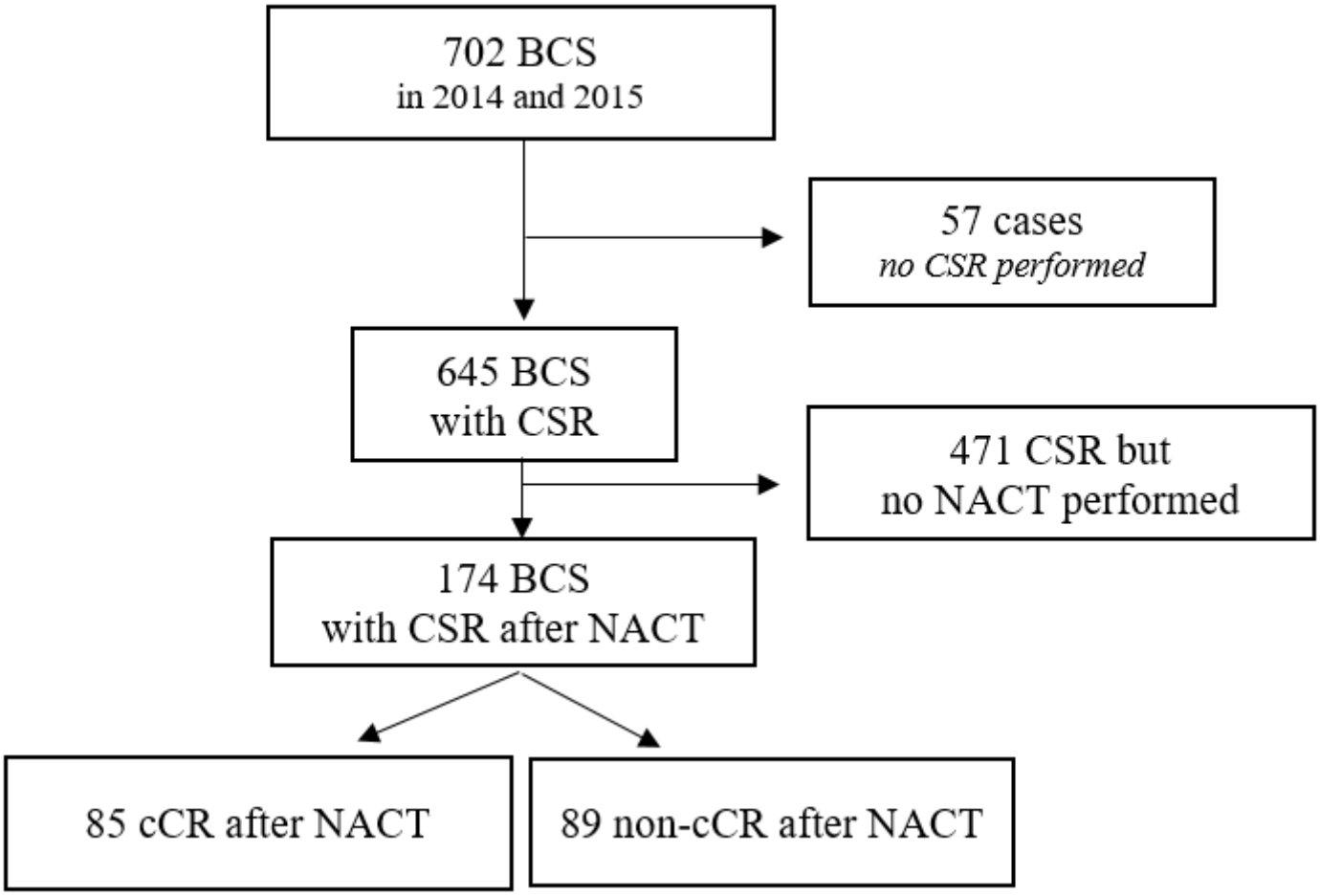

Figure 1

Flow diagram of patient population

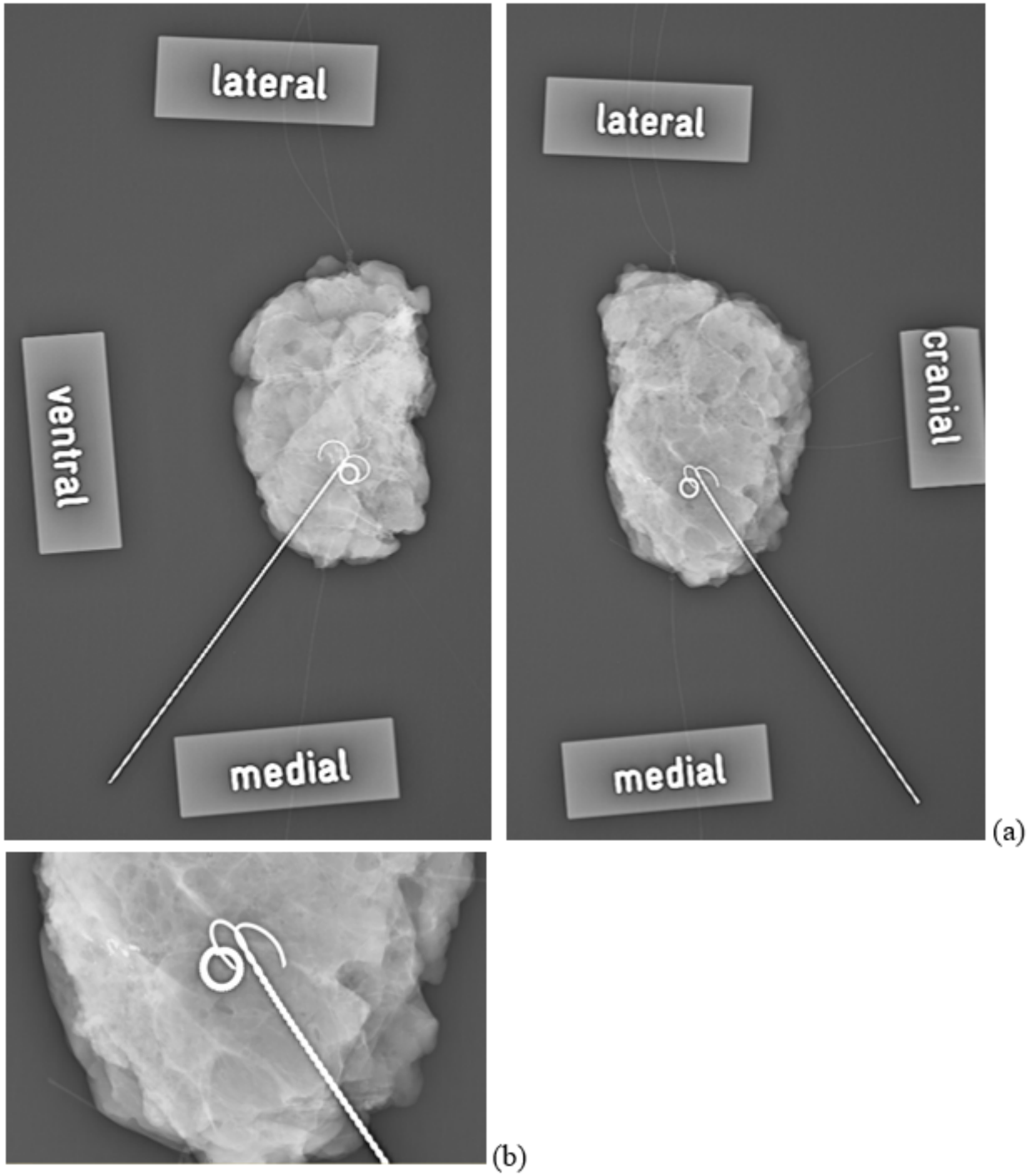

Figure 2

Example of a conventional two-view specimen radiograph of a cCR patient. Marking wire and clipmarker are visible in the former tumor bed (a). In the 2-fold magnification of CSR, residual microcalcifications with insufficient margin width in the dorsal direction are visible, so re-exsicion was recommended in this direction (b). In contrast, the pathological workup showed a pCR (false positive CSR).