The Corkscrew Technique – A Minimally Invasive, Transnasal Anterior Skull Base Reconstruction Using a Wedge-shaped Construct for Treatment of Cerebro-Spinal Fluid Leak

Yazid Samih Badarny (y_s_b12@hotmail.com)
Rambam Medical Center: Rambam Health Care Campus https://orcid.org/0000-0003-2639-2076
Iddo Paldor
Rambam Medical Center: Rambam Health Care Campus
Samih Badarny
Nahariya Western Galilee Hospital: Galilee Medical Center
Ziv Gil
Rambam Medical Center: Rambam Health Care Campus
Gill Sviri
Rambam Medical Center: Rambam Health Care Campus

Research Article

Keywords: transnasal approach, standard technique (ST), CSF leak, Cerebro-spinal fluid

Posted Date: September 24th, 2021

DOI: https://doi.org/10.21203/rs.3.rs-707136/v1

Abstract

Background : Cerebro-spinal fluid rhinorrhea may follow surgical and traumatic events, and may be spontaneous. Various techniques have been employed for reconstruction of the skull base following a CSF leak. Recent years have seen the development of endoscopic, transnasal techniques for reconstruction of the anterior skull base. We describe our experience with a novel corkscrew technique (CST), which entails harvesting a fascia lata graft, and placement of a wedge-shaped construct above the aperture in the skull base dura. This technique serves to prevent dislodgement of the construct extracranially, and lateral displacement of the construct away from the opening.

Methods : We operated 28 cases of CSF leak, in 26 patients, with a transnasal endoscopic approach. Twelve were operated using the CST and 16 with standard technique (ST), with a mean follow-up of over 5 years.

Results : The success rate in alleviating the leak was 91.7% in the CST group, and 87.5% in the ST group. Altogether, our complication rate was 8.3% in the CST group, and 37.5% in the ST group. None of the differences were statistically significant.

Conclusions : We recommend the use of a wedge-shaped, fascia lata based construct for transnasal endoscopic repair of anterior skull base CSF leaks.

Keywords: rhinorrhea, pituitary adenoma, CSF leakage, endoscopic transnasal approach, fascia lata.

Introduction

Leakage of cerebro-spinal fluid (CSF) results from an abnormal communication between the subarachnoid space and the extra-cranial space. Persistent CSF leaks (CSFL) usually imply the development of a CSF fistula. There are various reasons for the development of such a fistula, including trauma, tumors of the skull base, and congenital defects. Such fistulae may also develop following skull base surgery, post-traumatically or spontaneously [11, 12, 19, 27]. When CSFL involves the anterior skull base, it usually presents as rhinorrhea [11, 27].

Once a fistula has been identified and localized, treatment of the leak is pursued. In some of the cases, CSF diversion – temporary or permanent, may be considered. When CSF diversion is not used, or is unsuccessful in alleviating the CSFL, an anterior skull base reconstruction (ASBR) is employed. ASBR may be approached by the endonasal approach or trans-cranially, via a craniotomy. Factors affecting the approach decision include the etiology of the leak, the exact location of the leak (if located), the flow of the leak, the estimated size of the fistula and other considerations. There has been ample research aimed at describing the success rate of ASBR: Failure rates have ranged between 0–30% in different series, on first attempt of reconstruction, and 0–14% on second attempt [2, 3, 7–9, 13, 14, 17, 22, 26].

Open intracranial approaches, or non-endoscopic endonasal accesses have historically been used for the treatment of ASBR, but in recent decades these have largely been replaced by Endonasal Endoscopic approaches (EES) that show high success rate and low morbidity [4–6, 9, 10, 18, 21, 23, 24].

There is a variety of materials available in EES to obstruct CSFL. These include fat, bone, vascularized grafts, fascia lata, muscle, and other, artificial materials. These include fibrin glues and various sealants to secure these materials in place [13, 20, 25, 27].

The size of the defect is a significant determinant of success rates in ASBR. A major challenge of ASBR in case of large defect or high flow CSF leak is to overcome the CSF pressure and brain pulsation, that may push the implanted graft to protrude extracranially [1, 16, 28]. Several techniques have been described to overcome this problem: Warmold and McDonogh described a fat “bathplug” closure for small (1 cm) cranial defects, and entailed a success rate of 94% from the first attempt and a 100% success from the second attempt. [28], Luginbuhl et al proposed a bilayer button technique

for a high-flow CSF leak, with 10% postoperative CSF leak [16]. Leng et al suggested the “gasket seal” technique and reported no postoperative leak, albeit in a small cohort of 10 patients [15].

The purpose of this paper is to describe our single-center experience in the EES approach for management of CSF leak. Herein we present the use of a novel technique, we named the "corkscrew technique", and evaluate the outcomes in those treated with the corkscrew technique (CST) applied in an EES procedure, for ASBR.

Methods

The corkscrew technique was developed to overcome the major challenge of ASBR in case of high flow CSF leak – where CSF pressure and brain pulsation can push the implanted graft extracranially.

A corkscrew endoscopic reconstruction technique is defined as the use of a strip of fascia lata as an inlay graft in the shape of a corkscrew, with a relatively large part of the inlay placed above the fistula, thereby reducing the risk of graft prolapse in patients with intraoperative high-flow CSF leak [15].The lower part of the construct is wedged into the aperture in the dura, to prevent lateral migration of the construct sideways, away from the opening. The basis for this procedure is by harvesting a 10-cm fascia lata graft, such that the width of the graft is usually double the size of the cranial defect, and its width-to-length ratio is 1:4. The narrow aspect of the fascia is introduced first through the bony and dural defects. After the strip is inserted through the cranial defect, the tendency of the graft is to form a dome-shaped cap so that its external margins are compressed between the bone and the arachnoid. Thus, a wedge-shaped construct is built, with CSF pressure from above compressing the construct into the defect. A portion of the fascia graft is externalized at the aperture of the defect, preventing displacement of the reconstruction. A depiction of the corkscrew technique is presented in Fig. 1.

This novel method has been used in our service since 2013. We retrospectively reviewed the charts of all patients treated surgically by EES approach for treatment of CSFL in The Rambam (Maimonides) Medical Center between the years 2013–2019. All patients were included, whether their leak was spontaneous, post-traumatic or post-operative. All patients underwent an endoscopic endonasal repair of a CSF leak. Patients were categorized in 2 groups: those who underwent a repair using corkscrew technique (CST group) and those who underwent repair using standard technique (ST group). For our analysis, patients who were operated more than once are reported as two separate cases. All patients, in both groups, underwent routine evaluation by both ENT and neurosurgery for a minimum of 3 years postoperatively.

CSF leak management protocol

A clinical diagnosis of CSF leak was based on history of clear watery nasal drainage, unilateral or bilateral, amount and frequency, increasing drainage while performing Valsalva maneuver or while leaning down. We considered a leak to be of CSF if it was proven by beta-2-transferrin detected in the fluid, or in suggestive cases where the patient had proven meningitis accompanied by a persistent leak. The suspected cause of CSFL was also noted, including a history of trauma, previous surgery involving paranasal sinuses, previous endonasal endoscopic surgery for tumor removal and unknown causes.

All patients underwent MRI or CT myelography or CT cisternography preoperatively, to identify the site of the fistula. However, in cases of a proven, persistent CSF rhinorrhea, we performed an ASBR even without supporting imaging evidence of a leak or a localization of the fistula.

Operative technique: After intraoperative localization of the fistula and assessment of its size, a decision was made about the method of fistula closure. For small defects, in which we believed the hole could support the corkscrew construct, or for defects with suspected high CSF pressure, a corkscrew reconstruction was undertaken. In cases where we performed

CST, a nasoseptal flap (NSF) was also used, except in re-operation cases, or in cases where a NSF was not possible to harvest.

A lumbar drain was placed intraoperatively, or immediately after surgery, for 3–5 days after surgery, if the attending neurosurgeon deemed it necessary. Generally, a lumbar drain was placed if a high-flow leak was noted, if high pressure was suspected, or if the fistula was large on intraoperative evaluation.

The following parameters were noted and compared between the two groups:

- Demographic characteristics including age and gender
- Preoperative imaging, and whether or not these yielded a localization of the defect
- Etiology of the leak was classified into three groups: post-traumatic CSFL, following head trauma, post-surgical CSFL and spontaneous CSFL.
- surgical techniques including materials used to repair the defect, CST vs. ST
- Surgical complications: Intraoperative and postoperative complications, outcome of CSFL,
- Follow-up measures included the need for CSF diversion and repeat operations.

Patients who were operated more than once were analyzed as separate cases for each operation.

Results

Between the years 2013–2017, we performed 28 ASBR procedures on 26 patients, using EES techniques for treatment of CSFL. There were 11 male patients (42.3%) and 15 females (57.7%). Both cases that were operated twice were female. The age of the patients ranged from 23 to 77 years. Mean age (+/-SD) was 51.1 ± 14.2 years. Twelve cases were operated using the CST, and 16 with ST for ASBR.

When comparing both groups, the patients who underwent CST were somewhat older. Mean age ± SD was 46.5 ± 14.6 in the ST group, compared to 60 ± 11.6 in the CST group. 8 of the 16 cases in the ST group were female patients (50%), and 9 of 12 in the CST group were female (75%).

Preoperative evaluation

Of the 28 cases, 19 had a spontaneous CSF leak (67.9%), 4 patients post-traumatic CSFL (14.3%), and 5 patients had undergone previous endoscopic endonasal surgery (including paranasal sinuses surgery, 17.8%).

For 16 patients (57%) Beta-2 transferrin test was performed and was positive. The remaining had previously suffered meningitis and/or persistent CSF leaks.

In 6 cases (21.4%), preoperative high resolution MRI was sufficient for localization of the fistula. In 20 patients (71.4%), the MRI was not considered definitive, and they underwent CT myelography for localization of the fistula. In 17 of twenty (85%), CT myelography was successful in identifying the site of the leak, and in 3 it was not. In two cases the operation was a second operation for treatment of CSFL, and the location of the leak was known preoperatively, therefore we did not require localizing imaging before the second operation. All in all, brain CT/MRI/CT myelography/ CT cisternography was successful in identifying the site of the fistula in 23 of 26 cases (88.5%).

Patient baseline data and preoperative details are provided in Table 1

Table 1

patient	age	gender	Imaging test results	closure material	CORCKSCREW	complication	LP/VP SHUNT	pre op meningitis
1	25	m	ethmoidal leak	FL	No	Leak recurrence	ϖ	No
2	37	f	normal	FL	No	No	ϖ	No
3	37	m	ethmoidal leak	FL	No	No	ϖ	No
4	49	f	normal	FL	Yes	Anosmia + Leak recurrence	ϖ	No
5	50	f	normal	FL + fat	No	anosmia	LP	No
6	23	m	LT cribriform	FL	No	otorrhea	ϖ	Yes
7	77	m	RT cribriform	NSF	No	No	VP	No
8	57	f	ethmoidal leak	FL	No	No	ϖ	No
9	63	f	ϖ	FL	Yes	No	ϖ	Yes
10	62	f	sphenoidal sinus	FL	Yes	No	ϖ	No
11	64	m	ϖ	FL + NSF	No	anosmia	ϖ	Yes
12	37	m	normal	FL + NSF	No	No	ϖ	No
13	58	m	RT cribriform	FL + NSF	No	brain abscess	ϖ	Yes
14	60	f	ϖ	FL + NSF	No	No	ϖ	No
15	48	m	LT ethmoidal mucocele	FL	Yes	No	ϖ	No
16	46	f	LT cribriform	FL + NSF	Yes	No	ϖ	No
17	42	f	ϖ	FL + NSF	No	Pneumocephalus + Leak recurrence	ϖ	No
18	43	f	sphenoidal sinus	FL	No	No	LP	No
19	64	f	RT cribriform	FL + NSF	Yes	No	ϖ	
20	36	f	ϖ	FL + NSF	No	No	ϖ	No

LT = left, RT = right, CD = continuous drainage, LP shunt = lumboperitoneal shunt, VP shunt = ventriculo peritoneal shunt, FL = fascia lata, NSF = nasoseptal flap,

ϖ = not done

patient	age	gender	Imaging test results	closure material	CORCKSCREW	complication	LP/VP SHUNT	pre op meningitis
21	53	f	LT frontal encephalocele	FL + NSF	No	No	ϖ	No
22	68	f	sphenoidal sinus	FL + NSF	Yes	No	ϖ	No
23	42	m	ϖ	FL + NSF	Yes	No	ϖ	No
24	63	m	ϖ	FL + NSF	No	otorrhea	VP	Yes
25	72	f	LT cribriform	FL + NSF	Yes	No	ϖ	Yes
26	32	f	RT cribriform	FL + NSF	Yes	No	ϖ	Yes
27	58	f	ϖ	FL + NSF	Yes	No	ϖ	No
28	64	m	RT cribriform	FL + NSF	Yes	No	ϖ	No
LT = left, RT = right, CD = continuous drainage, LP shunt = lumboperitoneal shunt, VP shunt = ventriculo peritoneal shunt, FL = fascia lata, NSF = nasoseptal flap,								
ϖ = not done								

Operative procedure

12 patients underwent ASBR using a CST, and 16 patients underwent ST for the repair of their leak. One patient was operated twice with use of ST, because her fistula was too large for CST. Another patient underwent CST as primary operation, and after failure had a standard technique re-operation. All patients, operated with either technique, had a vascularized naso-septal flap placed, if it was available.

A lumbar drain was placed intraoperatively or immediately after surgery for 3–5 days after surgery in 13 patients. We placed a drain in 6 of the 16 patients operated with ST (37.5%) and in 7 of 12 patients operated with CST (58.3%)

Outcome and complications

We had follow-up for a mean of 62 months after the original operation (Range 36–86 months). All patients were followed for at least 3 years in both neurosurgery and ENT clinic.

2 patients in the ST group (12.5%) and 1 patient in the CST group (8.3%) had persistent rhinorrhea after the operation. The two ST group patients continued to a re-operation (using ST, one patient) or a VP shunt placement (one patient). The patient in the CST group with the persistent rhinorrhea, described above, underwent a second operation using ST, and a LP shunt placed in the same operation. Following this second operation she enjoyed resolution of the leak. Therefore, the success rate in alleviating the leak was 91.7% in the CST group, and 87.5% in the ST group. One patient in the ST group had a brain abscess in the area above the operation. There were no postoperative infectious complications in the CST group. 3 of the 16 patients who underwent ST (18.8%) lost the sense of smell after the operation. We observed this complication in none of the CST cases.

Altogether, 3 patients in the ST group (18.8%) required CSF diversion procedures – VP shunt or LP shunt. The patient mentioned above, who required a CST, then a ST operation with LP shunt placement, was the only patient in the CST

group who required CSF diversion (1/12, 8.3%)

All in all, complications (including CSF leak, anosmia, need for re-operation, permanent CSF diversion or infection) were encountered in 1 of 12 patients in the CST group (8.3%), and in 6 of the 16 patients who had a ST operation (37.5%). All the differences between the two groups were not statistically significant ($p > 0.05$)

A summary of outcomes and complications is presented in Table 2

Table 2

	CORCKSCREW, yes; N = 12	**X,=16**	**Total N = 28**	**P**
Complication	0	7 (44%)	7 (25%)	**P = 0.01**
Age	55.7 ± 12.1	47.6 ± 15.0	51.1 ± 14.2	P = 0.14
Gender- female	9 (75%)	8 (50%)	17 (61%)	P = 0.25
leak recurrence yes	1 (8%)	2 (12.5%)	3 (11%)	P = 1.00
pre op meningitis yes	3 (25%)	4 (25%)	7 (25%)	P = 1.00
LP/VP SHUNT	0	4 (25%)	4 (14%)	P = 0.11
CD yes	7 (58%)	6 (37.5%)	13 (46%)	P = 0.44
Imaging test normal Else (found defect/no imaging test)	N = 9 1/9 = 11%) 8/9 (89%)	N = 11 2/11 (18%) 9/11 (82%)	N = 20 3/20 (15%) 17/20 (85%)	P = 1.00
BETA TRANSFERRIN Positive Negative	7 (58%) 5 (42%)	9 (56%) 7 (44%)	16 (57%) 12 (43%)	P = 1.00
CD = continuous drainage, LP = lumbar-peritoneal shunt,				
VP = ventriculoperitoneal shunt				

Discussion

We found the Corkscrew technique to be a useful and efficacious technique to prevent CSFL. The success rate in alleviating the leak was 91.7% in the CST group, and 87.5% in the ST group. The overall complication rate was 8.3% in the CST group, and 37.5% in the ST group. Due to its relatively high success rate and low complication rate, we consider CST today as treatment for post-traumatic, post-surgical and for spontaneous CSF leak cases.

The main shortcoming of most EES techniques described in the literature is two forms of migration. The first is protrusion of the construct extracranially due to the pulsating pressure of CSF from above. The CST gives, in our experience, an acceptable solution for this problem, whereby the cone shape of the construct uses the downward-pulsating pressure to wedge the construct further into the opening, yet the larger part above the opening prevents extracranial migration. The second form of migration is lateral displacement of the construct to different areas atop the skull base. This is why we

insist to place the edge of the wedge-shaped construct into the aperture, thus anchoring it and preventing this lateral migration.

A wide range of ASBR techniques has been described using different type of materials, were most of these techniques appear to be effective.

The use of fascia lata as the material for the construct is not novel, and has been used by many other authors. As we have not attempted the use of different materials, we cannot comment on the comparison between different materials. However, we found the use of a wedge-shaped construct to be very efficacious and we urge skull-base neurosurgeons to use this type of construct for reconstructing the skull base for discontinuation of CSFL.

As our cohort is small, no meaningful statistical analysis can be made regarding the comparison of CST to ST. Furthermore, we acknowledge an inherent bias in our comparison between groups, in that the size of the fistula was the basis for the choice of technique used. Thus, the comparison between the two groups is given in descriptive terms, and not in quantitative, statistical analysis.

The purpose of this article is to present the efficacy and safety of this technique. However, we found CST to provide better results in both recurrent leaks and complications – which would suggest the use of this technique in treatment of all CSF leak regardless site and size of the defect and regardless of intraoperative low/high-flow CSF leak.

Despite the EES success, some patients still need to have a LP or VP shunt to prevent recurrent CSF leak.

Further research is required to demonstrate the efficacy of the CST when compared to other techniques and methods.

Conclusion

The Corkscrew technique is a useful and efficacious method for reconstruction of the anterior skull base in cases of CSF leak.

Abbreviations

CSF=cerebro-spinal fluid, CSFL=CSF leak, ASBR=anterior skull base reconstruction, EES=endonasal endoscopic approach, CST=corkscrew Technique, ST=standard (non-CST) technique, ENT=ear, nose and throat, MRI=magnetic resonance imaging, CT=computerized tomography, NSF=nasoseptal flap, SD=standard deviation, LP =lumboperitoneal shunt, VP =ventriculoperitoneal

Declarations

Ethics approval and consent to participate: ethical approval of Rambam Medical Center, local committee 12.06.20219, approval no. 201913751

Consent for publication: not applicable

Availability of data and materials: the datasets used and/or analysed during the current study are available from the corresponding author on reasonable request

Competing interests: the authors report no conflict or interests related to this work.

Funding: no funding was supplied for this work.

Authors' contributions: IP= design of the work, analysis, interpretation of data, revised. YB= design of the work, analysis, interpretation of data, revised drafted. SB= contributions to the conception, revised, drafted the work. ZG= analysis, interpretation of data. GS= conception, design, revised. All authors have read and approved the manuscript

Acknowledgements: not applicable

References

1. Amit M, Margalit N, Abergel A, Gil Z (2013) Fascia lata for endoscopic reconstruction of high-flow leaks: The champagne cork technique. Otolaryngol - Head Neck Surg (United States) 148:697–700. doi:10.1177/0194599813476463
2. Banks CA, Palmer JN, Chiu AG, O'Malley BW, Woodworth BA, Kennedy DW (2009) Endoscopic closure of CSF rhinorrhea: 193 cases over 21 years. Otolaryngol - Head Neck Surg. doi:10.1016/j.otohns.2008.12.060
3. Bernal-Sprekelsen M, Alobid I, Mullol J, Trobat F, Tomás-Barberán M (2005) Closure of cerebrospinal fluid leaks prevents ascending bacterial meningitis. Rhinology
4. Costa H, Cerejo A, Baptista A, Vaz R, Gonçalves M, Guimara˜es A, Amarante J, Cruz C, Guimara˜es F (1993) The galea frontalis myofascial flap in anterior fossa CSF leaks. Br J Plast Surg. doi:10.1016/0007-1226(93)90225-Z
5. DANDY WE (1926) PNEUMOCEPHALUS (INTRACRANIAL PENUMATOCELE OR AEROCELE). Arch Surg. doi:10.1001/archsurg.1926.01130050003001
6. Dohlman G (1948) Spontaneous cerebrospinal rhinorrhoea: Case operated by rhinologic methods. Acta Otolaryngol. doi:10.3109/00016484809129635
7. Gilat H, Rappaport Z, Yaniv E (2011) Endoscopic transnasal cerebrospinal fluid leak repair: A 10 year experience. Isr. Med. Assoc. J
8. Harvey RJ, Parmar P, Sacks R, Zanation AM (2012) Endoscopic skull base reconstruction of large dural defects. A Systematic Review of Published Evidence, Laryngoscope
9. Hegazy HM, Carrau RL, Snyderman CH, Kassam A, Zweig J (2000) Transnasal endoscopic repair of cerebrospinal fluid rhinorrhea: A0 meta- analysis. Laryngoscope. doi:10.1097/00005537-200007000-00019
10. Hirsch O (1952) Successful closure of cerebrospinal fluid rhinorrhea by endonasal surgery. AMA Arch Otolaryngol. doi:10.1001/archotol.1952.00710020018001
11. Kim E, Russell PT (2010) Prevention and management of skull base injury. Otolaryngol. Clin. North Am
12. Korem M, Ovadia H, Paldor I, Moses AE, Block C, Eliashar R, Hirshoren N (2015) False negative β-2 transferrin in the diagnosis of cerebrospinal fluid leak in the presence of streptococcus pneumoniae. Laryngoscope. doi:10.1002/lary.24940
13. Lanza DC, O'Brien DA, Kennedy DW (1996) Endoscopic repair of cerebrospinal fluid fistulae and encephaloceles. Laryngoscope. doi:10.1097/00005537-199609000-00015
14. Lee TJ, Huang CC, Chuang CC, Huang SF (2004) Transnasal endoscopic repair of cerebrospinal fluid rhinorrhea and skull base defect: Ten-year experience. Laryngoscope. doi:10.1097/00005537-200408000-00029
15. Leng LZ, Brown S, Anand VK, Schwartz TH (2008) "Gasket-seal" watertight closure in minimal-access endoscopic cranial base surgery. Neurosurgery. doi:10.1227/01.neu.0000326017.84315.1f
16. Luginbuhl AJ, Campbell PG, Evans J, Rosen M (2010) Endoscopic repair of high-flow cranial base defects using a bilayer button. Laryngoscope. doi:10.1002/lary.20861
17. Mao VH, Keane WM, Atkins JP, Spiegel JR, Willcox TO, Rosen MR, Rews D, Zwillenberg D (2000) Endoscopic repair of cerebrospinal fluid rhinorrhea. Otolaryngol - Head Neck Surg doi. 10.1016/S0194-5998(00)70144-6

18. Oakley GM, Orlandi RR, Woodworth BA, Batra PS, Alt JA (2016) Management of cerebrospinal fluid rhinorrhea: An evidence-based review with recommendations. Int Forum Allergy Rhinol. doi:10.1002/alr.21627
19. Ommaya AK (1976) Spinal fluid fistulae. Clin Neurosurg. doi:10.1093/neurosurgery/23.cn_suppl_1.363
20. Papay FA, Maggiano H, Dominquez S, Hassenbusch SJ, Levine HL, Lavertu P (1989) Rigid endoscopic repair of paranasal sinus cerebrospinal fluid fistulas. Laryngoscope. doi:10.1288/00005537-198911000-00018
21. Park JI, Strelzow VV, Friedman WH (1983) Current management of cerebrospinal fluid rhinorrhea. Laryngoscope. doi:10.1002/lary.1983.93.10.1294
22. Soudry E, Turner JH, Nayak JV, Hwang PH (2014) Endoscopic reconstruction of surgically created skull base defects: A systematic review. Otolaryngol - Head Neck Surg (United States). doi:10.1177/0194599814520685
23. Stamm A (2002) Microendoscopic surgery of the paranasal sinuses - Basic concepts. Rev. Bras. Otorrinolaringol
24. Stammberger H, Greistorfer K, Wolf G, Luxenberger W (1997) Operativer Verschluß von Liquorfisteln der vorderen Schädelbasis unter intrathekaler Natriumfluoreszeinanwendung. Laryngo-Rhino-Otologie. doi: 10.1055/s-2007-997487
25. Stankiewicz JA (1991) Cerebrospinal fluid fistula and endoscopic sinus surgery. Laryngoscope. doi:10.1288/00005537-199103000-00006
26. White DR, Dubin MG, Senior BA (2003) Endoscopic repair of cerebrospinal fluid leaks after neurosurgical procedures. Am J Otolaryngol - Head Neck Med Surg. doi:10.1016/S0196-0709(03)00031-0
27. Wigand ME (1981) Transnasal ethmoidectomy under endoscopical control. Rhinology
28. Wormald PJ, McDonogh M (2003) The bath-plug closure of anterior skull base cerebrospinal fluid leaks. Am J Rhinol. doi:10.1177/194589240301700508

Figures

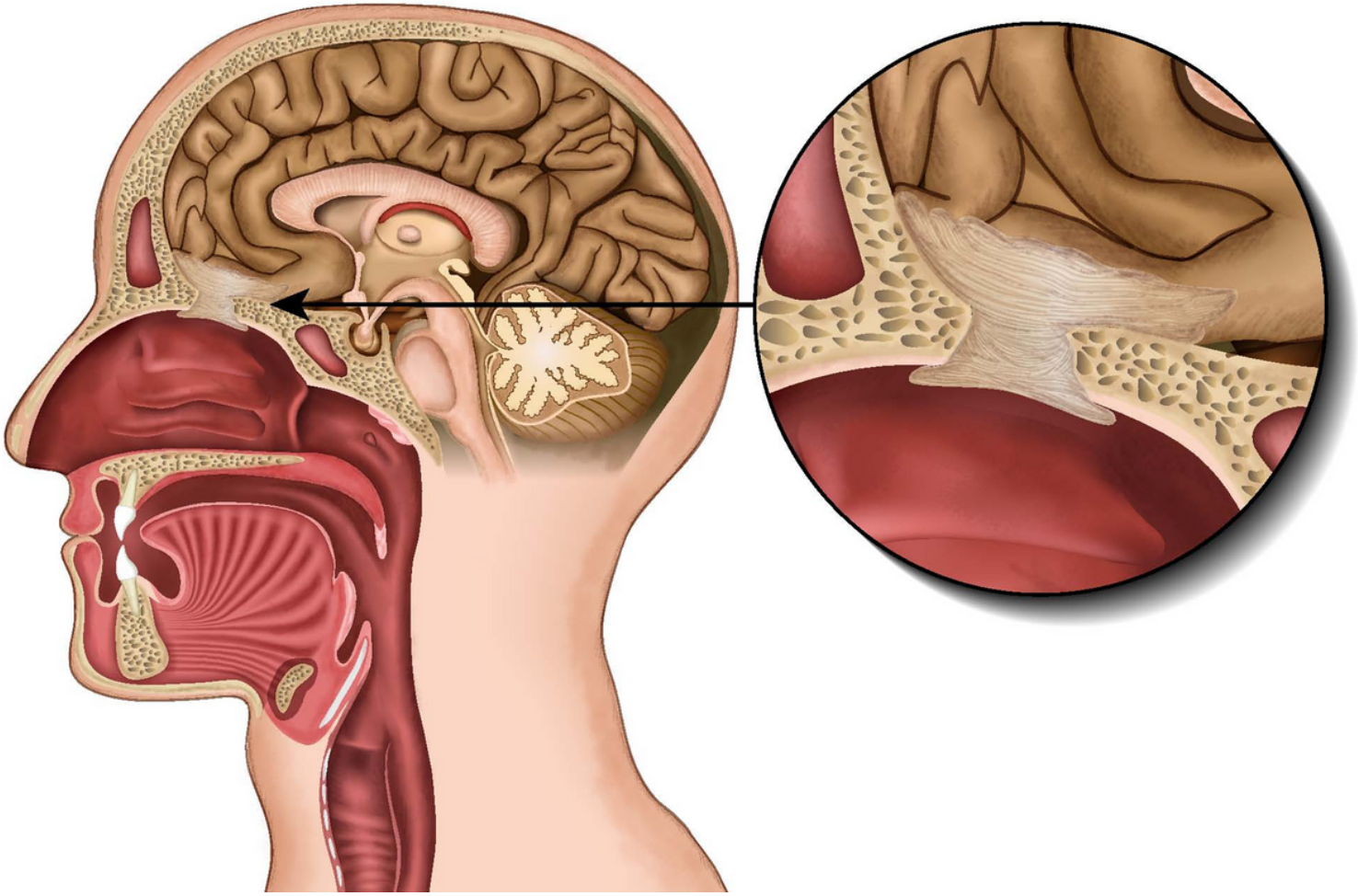

Figure 1

Mid-sagittal anatomical depiction of anterior skull base reconstruction using the Corkscrew technique.