74 Days Dynamic Changes of Chest CT Images of Coronavirus Disease 2019 (COVID-19) in Hebei Province, China

jianqin Liang (ljqbj309@163.com)
8th Medical Center of Chinese PLA General Hospital https://orcid.org/0000-0001-9173-7101

Guizeng Liu
Nanpi county people's hospital

Shuzhuang Yu
Nanpi County People's Hospital

Yang Yang
Nanpi County People's Hospital

Yanchun Li
Nanpi county people's Hospital

Hongli Tian
Nanpi County People's Hospital

Zhe Chen
Xianju County People's Hospital

Research

Keywords: COVID-19, Chest, Computed tomography, Dynamic, Imaging

Posted Date: September 9th, 2020

DOI: https://doi.org/10.21203/rs.3.rs-70721/v1

Abstract

Background

Since December 2019, the COVID-19 infection broke out in many parts of the world with confirmed and death cases rapidly increasing, which posed a great threat to human life and health. Current nucleic acid detection and antibody testing for the SARS-CoV-2 were the main methods for diagnosis of COVID-19, but not so sensitive, with high false negative rate and missed diagnosis rate. Imaging changes of COVID-19 not only precede symptomatic changes, but also have different imaging characteristics in different periods. We conducted 74 days of dynamic chest CT imaging observation on COVID-19 patients in Hebei province, aiming to understand the dynamic characteristics of the chest CT changes of COVID-19, so as to find the source of infection early, take early intervention measures, and judge the prognosis. **Methods** Chest CT examinations at intervals 1 to 4 days were conducted for 11 patients with a diagnosis of COVID-19. On the 74th day after onset, chest CT was reexamined to analyze the characteristics of chest CT in each stage. **Results** Of the 11 cases, 1 case was imported from Wuhan, 10 cases were infected for family clustering after close contact with confirmed COVID-19 cases. There were 3 ordinary cases, 3 severe cases and 5 critical cases. Among them, 2 critical cases died for old age and complications of underlying diseases, while 9 cases were cured by April 7, 2020. The changes of chest CT imaging in 1 child appeared prior to the clinical symptoms. 1–4 days after onset of the initial symptom were the early stages: Chest CT was mainly characterized by single lung quasi-circular ground glass shadow and fine mesh shadow. 5–10 days were the progressive stages: The lesion spread along the axial interstitium of the bronchi and gradually diffused to the whole lung, and reach the peak on day 6 to 9, which was characterized by consolidation, paving stone sign, halo sign, reversed halo sign, and even 'white lung' for the critical patients. The recovery stages began on day 11 after onset: The fiber cord, ground glass and consolidation shadow were gradually absorbed. After 74 days of follow-up, no serious permanent lung injury was found. **Conclusion** Chest CT could determine the different stages of COVID-19. Dynamic follow-up chest CT showed a good prognosis of COVID-19 in Hebei Province, China

1 Background

The diagnosis of novel coronavirus disease 2019(COVID-19)was mainly based on positive nucleic acid of the novel coronavirus found by real-time fluorescent RT-PCR, or virus gene sequence highly homologous to the known novel coronavirus, or positive specific IgM and IgG antibody(1). However, some patients' pulmonary imaging findings predated clinical symptoms, and different imaging characteristics appeared in different periods. Therefore, in the 'Guidelines for Diagnosis and Treatment of COVID-19 (Trial Version 5)' of China, the suspected cases with pneumonia found by imaging findings from Hubei Province were listed as clinically confirmed cases (2). So, the imaging diagnosis was very important, which was significant to guide the early isolation and treatment. The purpose of this study was to understand the dynamic characteristics of the chest CT changes of the 11 cases of COVID-19 treated from January 16 to February 16, 2020, and to find the source of infection early, take early intervention measures, and judge the prognosis.

2 Methods

2.1 Patients

Eleven cases of novel coronavirus infection treated at Nanpi County People's Hospital in Cangzhou City, Hebei Province, China between January 16 and February 16, 2020, case 1 to 11 for convenience of description. This study followed the guidelines of the Declaration of Helsinki and was approved by the Institute Review Board of the 8th Medical Center of Chinese PLA General Hospital and Nanpi County People's Hospital. Written informed consent was obtained from all patients involved before enrolment.

The patients were enrolled in the study when the following baseline criteria were fulfilled according to the 'Guidelines for Diagnosis and Treatment of Coronavirus disease 2019 (COVID-19) (Trial Version 7)' of China (1). For all patients, detection of nasopharyngeal swabs was performed by Chinese Center of Disease Control and Prevention (CDC), which showed negative influenza A virus RNA, negative influenza B virus RNA, negative adenovirus DNA, and positive 2019-nCoV RNA. Based on relevant epidemiological investigation, clinical manifestations and nucleic acid testing, their pathogen was identified as SARS-CoV-2 by the CDC, and the cases were confirmed as COVID-19.

The disease was divided into five types: mild, ordinary, sever, and critical. The diagnosis was classified as suspected and confirmed cases (1). The stages of COVID-19 were divided into 4 phases according to the 'Guide for imaging diagnosis of novel coronavirus-infected pneumonia' (the 1st edition, 2020) (3): early, progressive, recovery and critical stage. The critical stage was combined in the progressive stage in this paper because imaging progress occurred mostly in progressive stage.

2.2 CT techniques and images analysis

The Definition AS + 64-slice 128-layer spiral CT machine of Siemens, German was used for the scanning. The patients were in the supine position during end-inspiration. The scanning range was from the thorax to the lower margin of the bilateral costal arch. The scanning parameters were 120KV, automatic milliampere-second based on the body thickness. All CT images were reconstructed to 1.25-mm thin slices. Every image was read and reported by two or more radiologists, who had 7–20 years' experience in interpreting chest CT.

The observation indicators were the clinical data and dynamic characteristics of chest CT imaging of the 11 patients, and features and dynamic changes of each stage of CT images.

2.3 Principles for treatment and criterion of cure

The treatment included antiviral, anti-inflammatory, symptomatic treatment, and the treatment of traditional Chinese medicine.

Patients were considered to be cured if they met all of the following criteria: (1) clinical symptoms and signs were disappearance; (2)complete blood count and blood biochemical index returned to normal; (3) nucleic acid test of nasopharyngeal swabs or sputum detected by real-time fluorescent RT-PCR was negative for 2 times (sampling time should be at least 24 hours apart); (4) blood oxygen saturation in non-oxygen state was > 93%; (5) chest CT showed no abnormal or residual fine fiber cord shadow.

3 Results

Our study was composed of 11 patients (5 men and 6 women; age range, 7 ~ 80 years; mean age, 50 ± 0.92 years). All were confirmed cases. There were 3 ordinary cases, 3 severe cases, and 5 critical cases. Two critical cases had a smoking index of 40 × 20 year cigarettes. The Notification of Medical Conditions and the Informed Consent for treatment were signed by all of the patients.

3.1 Clinical features

Among the 11 cases, 10 cases (90.91%) began with fever. Case 11 patient was a child of 7 years old, without any uncomfortable symptoms, such as fever, and with body temperature 36.3 ℃ at maximum. The child was examined for nasopharyngeal swab twice routinely because her mother was confirmed. The nucleic acid tests were positive for both times, with lesions found by chest CT. The diagnosis of COVID-19 was confirmed. The other 10 cases got fever, with body temperature between 38 ℃ and 39 ℃, and the average temperature was 38.29 ± 0.69 ℃. The longest course of fever was 11 days, while the shortest was 2 hours. Other manifestations included dry cough, weakness, aches and discomfort. Relevant clinical symptoms were not specific. The main laboratory test results were as follows. The mean lymphocyte count of 11 cases was decreased to 0.83×10^9/L (the lower limit of normal range: 1.8×10^9/L). The mean C-reactive protein (CRP) was increased to 42.16 mg/L (the upper limit of normal range: 5 mg/L). The mean procalcitonin (PCT) was increased to 0.34 ng/mL (the upper limit of normal range: 0.05 ng/mL). Case 6, 7, 8, and 9 patients were a family, and Case 10 and 11 patients were a family. Of the 11 patients, only Case 1 patient had the experience travelling in Wuhan, while all of the other 10 patients were close contacts of COVID-19 confirmed cases. By the end of April 7, 2020, Case 1 and Case 6 patients died for old age and complications of underlying diseases, and the other 9 cases were cured.

3.2 Chest CT features

We summarized the lesion properties of progressive stage of chest CT among the 11 cases.

Various nature of lesions was showed: 8 cases (72.73%) with ground glass shadow, 4 cases (36.36%) with nodular infiltrating shadow accompanied by halo sign, 4 cases (36.36%) with fine mesh shadow, 4 cases (36.36%) with consolidation combined with ground glass, 2 cases (18.18%) with consolidation accompanied by air bronchogram sign, and 2 cases (18.18%) with reversed halo sign.

The lesions showed different locations: unilateral pulmonary change in 2 cases (18.18%), and bilateral pulmonary change in 9 cases (81.82%).Single lobe lesion was found in 1 case (9.09%), and multi-lobar lesions in 10 cases (90.91%), including 5 lobar lesions in 4 cases (40%), 2 lobar lesions in 3 cases (30%), 3 lobar lesions in 2 cases (20%), and 4 lobar lesions in 1 case (10%). The lesions were more located at lung periphery close to pleura, which gradually spread to the whole lung. No pleural effusion, cavitation or lymphadenoma were observed among all patients. (Table 1)

3.2.1 CT findings in early stage

The CT findings within 1 to 4 days after onset of the initial symptom were considered as the early stages in our study. Among 11 cases, eight cases (72.73%) showed quasi-circular irregular patchy ground glass density shadow (Fig. 1). Case 11 was a child of 7 years old, with small flaky consolidation accompanied by halo sign of peripheral ground glass (Fig. 1F). The image of child was unlike that of adult, and it was relatively limited, and interstitial lesion was not obvious. Five cases (45.45%) showed small lamellar shadow of a single lobe in a single lung (Fig. 1A-C). 1 case showed multi-lobar lesions in both lungs, accompanied by fine mesh shadow and consolidation (Fig. 1D).

3.2.2 CT findings in progressive stage

The CT findings between 5 to 10 days after onset of the initial symptom were considered as the progressive stages in our study. Enlarged and fused lesion range, multiple lobular foci, and thickened pulmonary interstitium and interlobular septum were mainly accompanied by ground glass shadow and fine mesh shadow. Among them, 4 cases developed to 50% of lesion area in both lungs within 3 days, 2 cases within one week, and 1 case within 12 days. Cord shadow and consolidation of the lesions gradually appeared, and some the ground glass shadows were accompanied by halo sign. Most of the lesions spread along the axial interstitium of the bronchi and gradually diffused to the whole lung, with air bronchogram, paving stone sign, halo sign and reversed halo sign. There was no thickened bronchial wall and no occluded lumen. For critical cases, diffuse fine mesh shadow was found in both lungs, presenting as ‘white lung’ (Fig. 2).

3.2.3 CT findings in recovery stage

The recovery stages began on day 11 after onset of the initial symptom. At this stage, some cases began to show that the lesions were absorbed and the range was limited from the 11th day after the onset, mainly with fiber cord and light ground glass shadow, and the most obvious manifestations were from 14 to 21 days. Further absorption of fiber cord and ground glass shadow were improved. At the 74th day of follow-up, the lesions were basically stable, with only sparse line-like shadows remaining. No enlarged lymph node, pleural effusion, cavity were observed throughout the course of the disease (Fig. 3).

4 Discussion

Since December 2019, the COVID-19 infection broke out in many parts of the world with confirmed and death cases rapidly increasing, which posed a great threat to human life and health. COVID-19 was mainly characterized by respiratory tract infection and easily transmissible in human. Up to 86% of the infected cases developed pneumonia, and some of them progressed to severe pneumonia or even death (4, 5). Because radiographic changes preceded clinical symptoms in some COVID-19 cases, chest CT features and dynamic changes among COVID-19 were conducive to early detection of infectious sources, early isolation and intervention, and prognosis as well.

In this study, Case 11 was an asymptomatic COVID-19 confirmed case. Her early chest CT findings showed consolidation of nodules with halo sign of slow progress, different from the early chest CT findings of adults. The early chest CT findings of adults showed fine mesh and ground glass shadows for interstitial change, which rapidly progressed after 3 to 4 days. This paper summarized dynamic changes of chest CT imaging for COVID-19 as follows. 1–4 days after onset of the initial symptom were the early stages: most commonly, the lesion was limited in peripheral subpleural lesion in a single lobe of a single lung, and this was consistent with literature reports (6, 7). The lesion was mostly interstitial infiltration, with 72.73% (8/11) presenting as quasi-circular ground glass shadow due to increased density in the lung for alveolar swelling, a small amount of alveolar exudation and alveolar septal inflammation (8). 5–10 days after onset of the initial symptom were the progressive stages: the lesion was enlarged, and it became multi-lobar lesions of a single lung (18.18%) or multi-lobar lesions of both lungs (81.82%). With progress of the disease, lesions spread from the periphery to the center (3). The lesions still were mostly interstitial infiltration, with 4 cases (36.36%) presenting as ground glass shadow accompanied by consolidation, or air bronchogram sign, paving stone sign, and halo sign as literature(5–9).A critical patient progressed to adult respiratory distress syndrome with blood oxygen decreased significantly, CT features of high density consolidation and mesh shadows diffuse (white lung) in both lungs as literature reports (1, 7–9). The recovery stage was after 11 days of onset of the initial symptom: except for two cases (18.18%) who died for underlying diseases, 9 cases (81.82%) had reduced distribution range of lesions. Within 2 to 3 weeks after onset, severe and critical cases presented as gradually sparse mesh shadow of both lungs, and after 3 weeks, the lesion was characterized by fiber cords. Jin et al. (10) described CT characteristic of COVID-19 as super early, early, rapid progress, consolidation and dissipation stages. Super early referred to 1 to 2 weeks after infection exposure, no clinical symptoms but CT displayed the subpleural single or multiple limitations, nodular shadows with air-filled bronchi. Among the 11 confirmed cases, only 7 years old children was up to the super early stage, and the lesions on chest CT did not increase into the progressive phase, but directly into the recovery stages after active treatment intervention and gradually cured. The CT dynamic changes of the remaining 10 cases conformed to the process of early (1–3 days of onset), progressive and consolidation (3–14 days of onset) reported by Pan et al. (9) and Jin et al. (10). However, our cases entered the recovery period 11 days after the onset. They were different from that reported in the literature (9–12) which reached the recovery stages 14 to 21 days after the onset. The reason may be that the cases studied by the above scholars were from Wuhan, Hubei province. Because of the concentration of cases in Wuhan, the relative severity of the disease had a certain relationship. Our study cases were from Hebei province, and our cases were found early, the inflammatory response was not severe, and the symptoms and CT changes were relatively mild. This feature was similar to the cases in Zhejiang province reported by Wang (13), in which 75.0% of the patients rapidly progressive within 6–9 days, 76.9% of the patients significant recovery of the lesion within 10–14 days. This indicated that the CT dynamic changes of COVID-19 in Hebei province were slightly different from those in Hubei province.

Y.W et al. (14) reported that 94% of patients discharged after 1 month of treatment had residual lesions in the final CT scan, and ground-glass shadow was the most common mode. We observed that chest CT was again performed until 74 days. Fibrosis was rare in mild cases, and fibrosis and ground glass shadows were gradually absorbed in severe and critical cases, and chest CT showed sparse linear shadows, which had no effect on lung function and achieved clinical cure. This feature was different from the lung fibrosis and permanent lung injury of SARS and MERS (5).

Li et al. (15) reported a multi-center study of CT image changes of COVID-19 in southwest China. With the observation time of 43 days, they had not study on the correlation between disease course and imaging. Pan et al. (9) discussed in detail the correlation between the disease course and imaging in 21 cases of COVID-19 from Wuhan, and divided these cases into 4 stages. With the observation time of 26 days, and no follow-up was conducted on the discharged cases. Our cases were followed up for 74 days by April 7, 2020. Except for 2 deaths, the 9 cases reached the clinical cure standard, which is the longest follow-up time reported in the current literature.

5 Conclusion

The dynamic changes of chest CT of COVID-19 were as follows: 1–4 days after the onset of the initial symptom were the early stages, and the single lobe ground glass lesions in the peripheral periphery of the subpleural lung were more common. 5 to 10 days after the onset of the initial symptom were the progressive stages, and the lesion spread from the periphery to the center, and formed consolidation and fusion. With active treatment intervention, the recovery stages began on day 11 after onset, and the fiber cord, ground glass and consolidation shadow were gradually absorbed. Only sparse line-like shadows were remained after 74 days of follow-up, and no serious permanent lung injury was found.

Our research limitations were as follows: The number of samples was small, and only descriptive studies were conducted on the imaging manifestations of COVID-19 in different stages; There was only one case of children, which didn't fully explain the imaging characteristics of children; There was no grouping control analysis of mild and severe cases.

Declarations

Ethical Approval and Consent to participate：All participants are Ethical Approval and Consent.

Consent for publication: yes.

Availability of supporting data：yes.

Competing interests The authors declare that they have no known competing financial interests or personal relationships that could have appeared to influence the work reported in this paper.

Funding : Not applicable

Authors' contributions: 1 guarantor of integrity of the entire study: Jianqin Liang and Guizeng Liu, as co-first authors; 2 study concepts and design: Guizeng Liu; 3 literature research: Jianqin Liang; 4 clinical studies: Shuzhuang Yu, Yanchun Li, Zhe Chen; 5 manuscript preparation: Jianqin Liang; manuscript editing: Guizeng Liu.

Acknowledgements Acknowledgements for the guidance of Dr. Wang Yi, Department of Radiology, Peking University People's Hospital.

Authors' information

Jianqin Liang: Tuberculosis Department and Tuberculosis Research Institution, the 8th Medical Center of Chinese PLA General Hospital, Beijing 100091, China

Guizeng Liu, Shuzhuang Yu, Yanchun Li, and Zhe Chen: CT Radiology Department, Nanpi County People's Hospital, Cangzhou, Hebei 061500, China

Yang Yang: Medical Education Department, Nanpi County People's Hospital, Cangzhou, Hebei 061500, China

Hongli Tian: Respiratory and Infectious Disease Department, Nanpi County People's Hospital, Cangzhou, Hebei 061500, China

References

1. General Office of National Health Commission, General Office of National Administration of Traditional Chinese Medicine. Diagnostic and treatment protocol for novel coronavirus pneumonia (Trial version 7). March 4, 2020. http://www.nhc.gov.cn/xcs/zhengcwj/202003/46c9294a7dfe4cef80dc7f5912eb1989. shtml (in Chinese) (accessed March 7, 2020)
2. General Office of National Health Committee, General Office of National Administration of Traditional Chinese Medicine. Diagnostic and treatment protocol for novel coronavirus pneumonia (Trial fifth edition). February 5, 2020. http://news.cri.cn/20200205/574bd04c-3223-3f67-31fa-664a4ae6c449.html (in Chinese) (accessed February 5, 2020)
3. Li H, Xu H. Guidelines for Imaging Diagnosis of Novel Coronavirus Pneumonia (First Edition 2020) (in Chinese). New Medicin (Online). 2020;30(1):22-34. DOI 10.12173/j.issn.1004-5511.2020.01.07.
4. Chan JF, Yuan S, Kok KH, et al. A familial cluster of pneumonia associated with the 2019 novel coronavirus indicating person-to-person transmission: a study of a family cluster. Lancet. 2020;395:514-523.
5. Hosseiny M, Kooraki S, Gholamrezanezhad A, et al. Radiology Perspective of Coronavirus Disease 2019 (COVID-19): Lessons From Severe Acute Respiratory Syndrome and Middle East Respiratory Syndrome. AJR Am J Roentgenol. 2020:214(5):1078-1082.
6. Chung M, Bernheim A, Mei X, et al. CT Imaging Features of 2019 Novel Coronavirus (2019-nCoV). Radiology. 2020;295:202-207.
7. Song F, Shi N, Shan F, et al. Emerging 2019 Novel Coronavirus (2019-nCoV) Pneumonia. Radiology. 2020;295:210-217.
8. Koo HJ, Lim S, Choe J, et al. Radiographic and CT Features of Viral Pneumonia. Radiographics. 2018;38:719-739.
9. Pan F, Ye T, Sun P, et al. Time Course of Lung Changes On Chest CT During Recovery From 2019 Novel Coronavirus (COVID-19) Pneumonia. Radiology. [serial online] Feb 13 2020 https://doi.org/10.1148/radiol.2020200370.
10. Jin Y, Cai L, Cheng ZS, et al. A rapid advice guideline for the diagnosis and treatment of 2019 novel coronavirus (2019-nCoV) infected pneumonia (standard version). Mil Med Res.2020;7(1):4.
11. Xiong Y , Sun D , Liu Y , et al. Clinical and High-Resolution CT Features of the COVID-19 Infection: Comparison of the Initial and Follow-up Changes. Invest Radiol. 2020;55(6):332-339.
12. ShiH, Han X , Jiang N, et al. Radiological Findings From 81 Patients With COVID-19 Pneumonia in Wuhan, China: A Descriptive Study. Lancet Infect Dis. 2020;20(4):425-434.
13. Wang J , Liu J , Wang Y et al. Dynamic Changes of Chest CT Imaging in Patients With Corona Virus disease-19 (COVID-19).(in Chinese) Zhejiang Da Xue Xue Bao Yi Xue Ban. 2020;49(2):191-197.
14. Wang Y, Dong C , Hu Y , et al. Temporal Changes of CT Findings in 90 Patients with COVID-19 Pneumonia: A Longitudinal Study. Radiology. [serial online] Mar 19 2020 https://doi.org/10.1148/radiol.2020200843.
15. Li X , Zeng W, Li X , et al. CT Imaging Changes of Corona Virus Disease 2019(COVID-19): A Multi-Center Study in Southwest China. J Transl Med. 2020;18(1):154.

Tables

Table 1 Characteristics and dynamic changes

with time course of chest CT imaging

Case	First imaging (Month/Day)	Ordinary to severe (Month/Day)	Severe to critical (Month/Day)	Dynamic change of lesion distribution in CT imaging (Month/Day)					Features of CT imaging for lesion Dynamic change (Month/Day)		Features of CT period
				Single lobe in a single lung	Multiple lobes in a single lung	Multiple lobes of in double lungs	50% of lesion area in double lungs	Diffuse in double lungs	Ground glass shadow Streak shadow Consolidation	Fibrosis	
1	Jan/13	Jan/16	Jan/19			Jan/13	Jan/16	Jan/16	Jan/16	Jan/19	Double lung di glass shadows
2	Jan/24	Jan/27				Jan/24	Jan/27		Jan/24	Feb/4	Double lung pe subpleuralcon glass shadows
3	Jan/24			Jan/25		Jan/30					Nodule shado sign at middle left lobe
4	Jan/24	Jan/27	Jan/30		Jan/24	Jan/27	Jan/30	Jan/30	Jan/30		Double lung m along vascula
5	Jan/24	Jan/27	Feb/3	Jan/25		Jan/27	Feb/6	Feb/6	Feb/3	Feb/6	Double lungpe subpleuralcon byair broncho glass shadow
6	Jan/23	Jan/23	Jan/27			Jan/23	Jan/27				Scattered patc withhalo sign remaining lun lobectomy
7	Jan/21					Jan/22					Right lung upp lamellar groun
8	Jan/23	Jan/27	Jan/30	Jan/23		Jan/27	Jan/30	Jan/30		Feb/4	Double lung m with ground gl
9	Feb/1	Feb/3				Feb/1	Feb/3			Feb/3	Left lung perip glass shadows with air bronch
10	Feb/6	Feb/9		Feb/6	Feb/9						Double lung gr and reversed h
11	Feb/16			Feb/16							Lower left sma consolidation glass and halo pleura

Figures

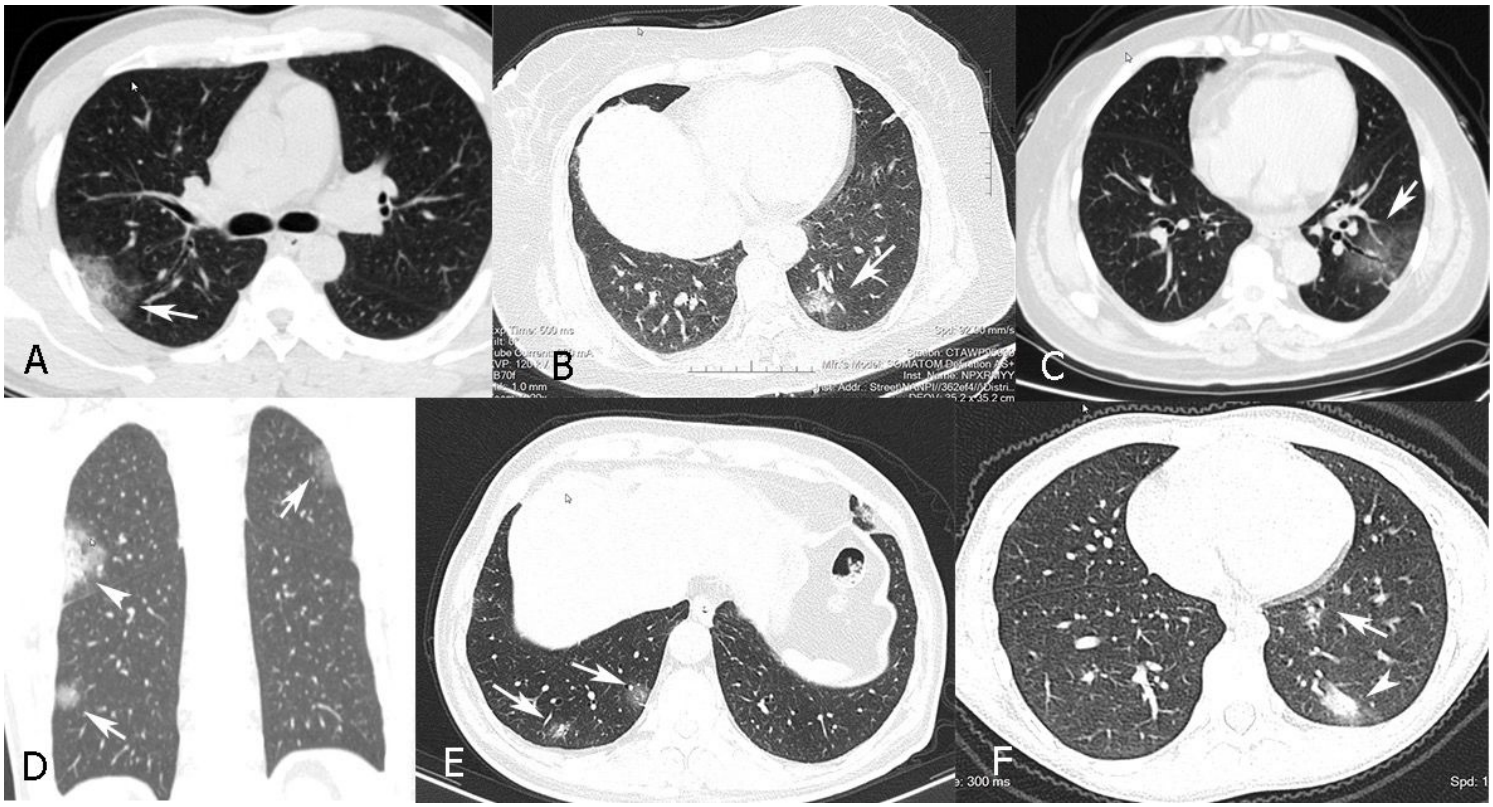

Figure 1

Chest CT findings in early stage of 6 cases. A. Male, 41 years old, with patchy ground glass shadow of single lobe in a single lung; B. Female, 62 years old, with quasi-circular ground glass shadow of single lobe in a single lung. C. Female, 55 years old, with patchy ground glass shadow of single lobe in a single lung. D. Male, 60 years old, with multi-lobar patchy ground glass shadow of double lungs. E. Male, 59 years old, with multi-focal round ground glass shadow of single lobe in a single lung. F. Female 7 years old, with small multi-focal round ground glass shadow of single lobe in a single lung, consolidation at the middle part of the posterior basal segment lesion, surrounded by halo sign of ground glass shadow.

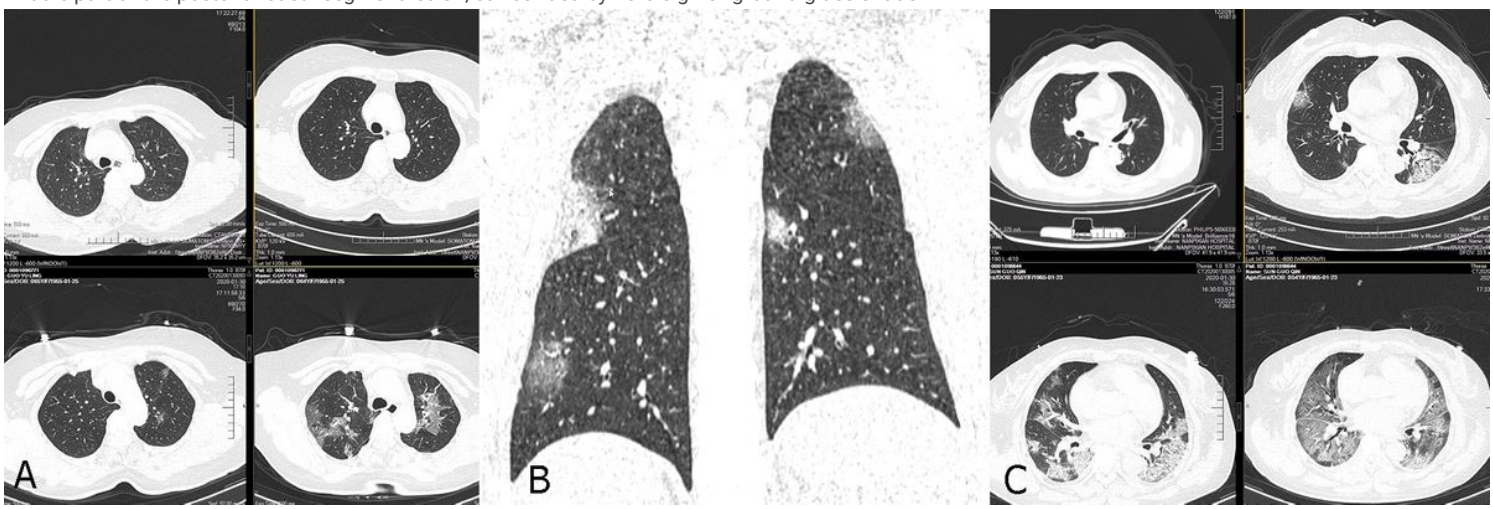

Figure 2

Chest CT findings in progressive stage in 3 cases. A. Female, 62 years old, examinations at onset, and on Days 3, 6 and 10 found that the lesion was gradually enlarged with ground glass shadow and interstitial fine mesh shadow. Consolidation and cord shadow gradually appeared. B. Male, 41 years old, examination 3 days after onset found multi-lobar lesions in double lungs with ground glass shadow and interstitial fine mesh shadow. C. Female, 55 years old, examinations at onset, and on Days 4, 7 and 10 found that the early manifestations were single-lobe ground glass lesion in a single lung. The range gradually increased after 4 days, with multi-lobar lesions in both lungs, presenting as ground glass shadow and fine mesh shadow. After Day 7, the range further increased to more than 50% of lesion area in double lungs. After Day 10, there were diffuse ground glass shadow, interstitial fine mesh shadow in double lungs.

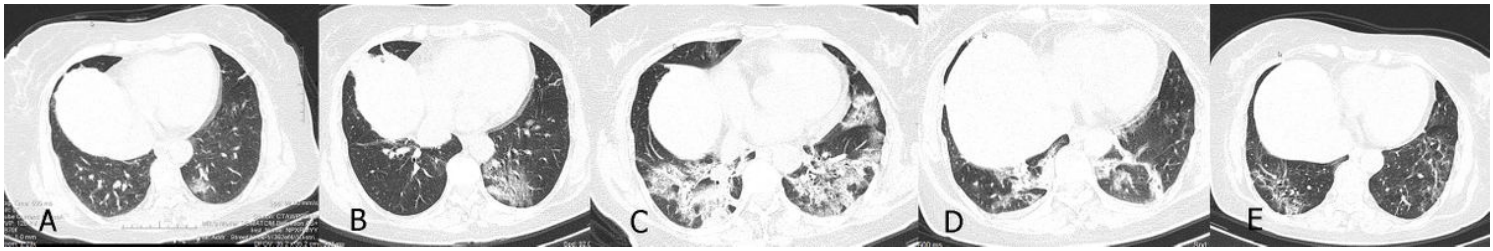

Figure 3

Chest CT findings of the time course from early stage, progressive stage, to recovery stage and the 74th day of Case 5. A. At the time of onset, there was single lobe round ground glass shadow in a single lung. B. On Day 3, the lesion was enlarged, with ground glass shadow and interstitial fine mesh shadow. C. On Day 6, the lesion was further enlarged, presenting as multiple lesions in both lungs, ground glass shadow and thick interstitial shadow. D. On Day 11, the lesion began to shrink, mainly with coarse fiber cord. E. On Day 74 of follow-up, the lesion was stable, and only the Sparse line-like shadow was observed.