Research Square

Preprints are preliminary reports that have not undergone peer review. They should not be considered conclusive, used to inform clinical practice, or referenced by the media as validated information.

Clinical Features and Surgical Outcomes of Pediatric Ocular Trauma in Southwest of China

Yan He
Southwest Eye Hospital, Southwest Hospital, Army Medical University

Songwen Nian
Southwest Eye Hospital, Southwest Hospital, Army Medical University

Nan Wu
Southwest Eye Hospital, Southwest Hospital, Army Medical University

Yi Wang
Southwest Eye Hospital, Southwest Hospital, Army Medical University

Tao Yu
Southwest Eye Hospital, Southwest Hospital, Army Medical University

Yong Liu (769588503@qq.com)
Southwest Eye Hospital, Southwest Hospital, Army Medical University https://orcid.org/0000-0003-0439-7167

Research Article

Keywords: pediatric ocular trauma, vitrectomy, surgical outcomes

Posted Date: December 12th, 2018

DOI: https://doi.org/10.21203/rs.2.71/v1

License: This work is licensed under a Creative Commons Attribution 4.0 International License. Read Full License

Abstract

Background: Ocular trauma is one of the major threats of monocular blindness in children. The purpose of the study was to investigate the epidemiology, clinical characteristics and surgical outcomes of pediatric ocular trauma in southwest of China.

Methods: The medical records of all patients with ocular trauma under 12 years old receiving three-port pars plana vitrectomy (PPV) in Southwest Eye Hospital from January 2007 to December 2017 were retrospectively analyzed in this study. Data records included age, gender, cause, type and time of injury, initial and final visual acuity (VA), type and times of operation.

Results: This study included 122 eyes of 122 pediatric patients over a 11-year period. The mean age was 6.6 ± 3.2 years with a male-to-female ratio of 4.3:1. There were 100 (82%) open globe injuries (OGI) and 22 (18%) closed globe injuries. Of the open globe injuries, penetrating injury caused by sharp metal objects accounted for the highest percentage (70%). PPV could significantly improve VA in children with ocular trauma (P 0.01). In addition, the successful rate of PPV was not related with the age ($P = 0.23$) but significantly associated with intraocular tamponade ($P < 0.05$).

Conclusions: The most common predisposing factor of pediatric ocular trauma in southwest of China was sharp metal objects resulting in penetrating injury. In our study, gas tamponade for vitrectomy had the highest successful rate, followed by balanced salt solution (BSS) and silicone oil. Unlike the age and injury classification, the preoperative VA was a solid prognostic indicator of postoperative vision.

Background

In young children, ocular trauma is one of the major threats of monocular blindness [1-4]. It was reported that the incidence of severe visual impairment or blindness caused by ocular trauma ranged from 2% to 14% in young children [5, 6]. Vision loss has long-term influence on personal psychological and social development [7, 8]. Therefore, it is necessary to evaluate the epidemiological characteristics of ocular trauma in children in order to reduce its incidence and severity.

Pars plana vitrectomy (PPV) is a major surgical intervention which has been used to manage severely damaged eyes [9]. Some studies have reported the epidemiological features of pediatric ocular trauma in developing countries, including India [10, 11], Egypt [1] and Turkey [7]. However, quite few studies described the clinical characteristics and outcomes of PPV in pediatric ocular trauma. This study covered the largest series of children that suffered ocular trauma and received PPV treatment in China. Herein, we reviewed our surgical interventions and outcomes of pediatric patients diagnosed with ocular trauma in the past 11 years and reported the results.

Methods

The medical records of children diagnosed with ocular trauma from January 2007 to December 2017 in Southwest Hospital, Chongqing, China, were retrospectively reviewed. This retrospective study was approved by the ethics committee of the Southwest Hospital (KY201858) and followed the tenets of the Declaration of Helsinki.

Children aged no more than 12 years old and receiving PPV treatment for ocular trauma were included in this study. Patients with anterior vitrectomy was excluded. The following data of ocular trauma were collected: demographic information including age, gender and injury time; characteristics of injury including cause, mechanism and types; ophthalmological examination including initial visual acuity (VA), slit lamp examination, B-scan and fundus examination if possible; surgical intervention including type and number of surgery and intraocular tamponades; follow-up data including final VA and final outcome of eye.

The patients were divided into two groups according to age: Group 1 (age < 7 years old) and Group 2 (age between 7-12 years old). The classification of ocular trauma was based on the Birmingham Eye Trauma Terminology (BETT)[12]. The grade of injury was defined by the presenting VA: grade 1, VA ≥ 0.1; grade 2, 0.02 ≤ VA< 0.1; grade 3, light perception (LP) ≤ VA < 0.02; grade 4, no light perception (NLP).

Statistical analysis was performed using SPSS software (version 13.0). Categorical covariates were individually assessed with the Chi-square test and *P* value less than 0.05 was considered to be statistically significant.

Results

This study included 122 eyes of 122 patients during the 11-year period. Sixty-seven patients were included in Group 1 (55%) and 55 were included in Group 2 (45%). The mean age was 6.6 ± 3.2 years and the mean follow-up time was 18.8 ± 21.2 months.

All the injuries were bilateral and no difference was showed between the affected eye: 64 right eyes and 58 left eyes. In this study, 99 patients (81%) were males and 23 (19%) were females. There was a statistically significant difference that males are more likely to suffer from ocular trauma than females ($P < 0.05$). Moreover, the ratio of male to female was 3.8:1 in Group 1 and 5.1:1 in Group 2 respectively, which seemed to increase as patients aged. However, there was no statistical significance. As showed in Fig 1, the frequency of ocular trauma decreased in both males and females as they grown up, especially in females.

The time distribution of the ocular trauma was shown in Fig 2. The majority of the injuries occurred in February (22%) and January (11%). On the contrary, the incidence of ocular trauma was quite low in October (3%) and June (4%). Besides, children ranged between 7 and 12 years old showed higher incidence only in February, March and November.

There were 100 eyes (82%) with open globe injuries and 22 eyes (18%) with closed globe injuries in this study (Fig 3). The open globe injuries included 70 penetrating injuries (70%), 15 intraocular foreign bodies (15%), 13 ruptures (13%) and 2 perforating injuries (2%). There were 14 eyes (64%) had blunt trauma in the closed globe injuries. The causes of injuries identified in patients were shown in Table 1. The three main causes were sharp metal objects (45%), wooden sticks (12%) and firecrackers (11%). Among the sharp metal objects, scissors (44%) were the most common one that caused ocular trauma. The other risks included needles (27%), knives (20%) and nails (9%). With regards to toys, toy bullets (67%) and slingshots (33%) were the most dangerous which might lead to ocular trauma. Besides, six children could not recall the cause of injury.

Table 1. Causes of ocular trauma in patients.

Causes of injury	Number	Total	Percentage (%)
Sharp metal objects (scissors/knife/needle/nail)	24/15/11/5	55	45
Wooden stick	15	15	12
Firecrackers	13	13	11
Fall	9	9	7
Toys (bullet/slingshot)	4/2	6	5
Pencil	5	5	4
Hit	4	4	3
Car accident	4	4	3
Glass	2	2	2
Fist	1	1	1
Spring	1	1	1
Firewood explosion	1	1	1
Not clear	6	6	5

Vitrectomy was ultimately applied in all 122 eyes. The averaged surgical procedures were 1.8 per eye. Specifically, silicone oil, gas or balance salt solution (BSS) tamponade was applied in 84 (69%), 33 (27%) or 5 eyes (4%), respectively. Silicone oil tamponade was used once in 66 eyes, twice in 10 eye, and three times in 8 eyes. The successful rate was 79% after the operation of tamponades. The failure cases were mostly given silicone oil (25 of 26 eyes). The final outcome of vitrectomy was significantly associated with intraocular tamponade ($P < 0.05$, Table 2). There was no statistically significance between successful rate of operation and age distribution ($P > 0.05$, Table 3).

Table 2. Final outcomes of vitrectomy with different intraocular tamponades.

Final condition	Silicone oil	Gas	BSS
Success	59	33	4
Failure	25	0	1
Successful rate (%)	70	100	80

($c^2 = 5.13$, df = 2, $P = 0.02$)

BSS: balanced salt solution.

Table 3. Final outcomes of vitrectomy of different age groups.

Final condition	Age groups(years)	
	≤ 7	7 – 12
Success	50	46
Failure	17	9
Successful rate (%)	75	84

We divided uncorrected VA into four grades as is shown in Table 4. Before the surgery, VA was less than 0.1 in majority of the injured eyes (98%). There was no statistically significance in initial VA between different age groups ($P > 0.05$). Significantly, PPV improved the visual acuity after the operation ($P < 0.05$) (Table 4). In addition, no difference was found between the final VA and either age ($P > 0.05$) or classification of injury ($P > 0.05$).

Table 4. Comparison of visual acuity before and after PPV.

Visual acuity	Pre-operation	Post-operation
	n (%)	n (%)
≥ 0.1	3 (2)	24 (20)
0.02 – 0.1	2 (2)	10 (8)
LP – 0.02	104 (85)	79 (65)
NLP	13 (11)	9 (7)

(c^2 = 25.81, df = 3, P = 0.00)

PPV: pars plana vitrectomy; LP: light perception; NLP: no light perception.

Discussion

In this study, our purpose was to obtain and summarize the demographics, etiologies and clinical characteristics of pediatric ocular trauma in Southwest of China over an 11-year period to provide evidence-based information for protection awareness education and further medical management. Children less than 12 years of age with PPV were included. The ratio of male to female was 4.3:1 (99 males and 23 females) in this study, higher than the sex ratio of 1.18:1 derived from the latest available census data in China [13]. Moreover, many studies reported a higher incidence of trauma in males than in females [7, 9, 13-16], showing an average male-to-female ratio which ranged between 1.2:1 and 5.2:1. In our study, the male to female ratio was increased as patients grew, which was consistent with a study conducted by Yu Du et al. [13] in Shanghai, China. They found the peak of sex ratio was at 12:1 around 10 – 12 years old. Other studies showed similar results as well [2, 7, 14, 17]. We also found that the incidence of ocular trauma decreased in both males and females as they grew up, especially in females. This could be explained by the fact that children receive primary health education and self-protection when they get older. Males are more likely to participate in dangerous and risky activities [18, 19], which might result in higher rate of ocular trauma in males compared to females.

With regards to the time distribution of ocular trauma in our study, there were over 20% of cases occurred in February, which was usually the season of Chinese New Year. Many children like playing firecrackers during this period. It might largely increase the risk of eye injury. In our study, firecrackers were the third major cause of ocular trauma, which was similar as the study of Xu et al [16]. However, Ilhan et al. observed that most frequently occurred in the autumn [7] and Podbielski et al. found that globe injuries most occurred in the summer [20]. These seasonal differences may be related with the climate characteristics and lifestyle of different areas [7].

Our finding was consistent with previous reports [13, 15, 16, 21, 22] on children ocular trauma that penetrating injury caused by sharp objects had absolute predominance. Other causes include wooden stick, firecrackers, recreational activities and accidental domestic injuries. But Puodžiuvienė et al [14] suggested that the most common type of ocular trauma was closed globe injury. Literatures showed that 90% of all ocular trauma was avoidable [23]. Figuring out the major cause of injury, it will help parents and doctors establish effective protection to reduce the incidence of ocular trauma in children.

PPV has been used to manage lens and posterior segment trauma when surgery is needed [24]. Previous studies mentioned the advances of PPV in treating severely damaged eyes and improved visual outcomes [9, 25]. In young children, it is very challenging to perform vitreoretinal surgery due to the complex features of the vitreous, retina, and the interface between them [26]. In this study, 74 eyes underwent 2 times or more surgeries, which suggested that those cases may arise serious complications, such as postoperative hypotony, retinal detachment, proliferative vitreoretinopathy and bacterial endophthalmitis [27, 28]. Anatomical successful rate in our study was 79%, and it was associated with intraocular tamponade. Silicone oil was used most in our study, and its outcome was worst compared to the other two tamponades, which might be related with severity of eye injury. Advantages of silicone oil include the high interfacial tension and a refractive index close to that of vitreous, so it becomes an attractive alternative for clinic application [9, 29].

In our study, 28% of patients achieved VA of 4/200 or better, and 20% achieved 20/200 or better after vitrectomy. Compared to previous studies [9, 26], the VA improvement in our study was not so well as the outcomes of all kinds of vitrectomy in pediatric patients [9, 26]. The possibility might include the preoperative degree of injury, severer underlying pathology or more extensive postoperative inflammation, hypotony [29], scarring and proliferative vitreoretinopathy [30]. Obviously, PPV improved both the anatomical and visual outcomes in the pediatric patients despite potential problems with proliferative vitreoretinopathy and deprivation amblyopia.

Initial VA was a strong prognostic indicator of final VA evaluation [7, 31, 32]. Nevertheless, causative factors related to the beneath retinal pathology seem to influence postoperative functional outcomes. Previous studies [6, 14, 17] suggested the final VA was associated to the injury type for open globe injury carried a poorer prognosis. But in our study, no statistically significant difference was found between the final VA and either age or classification of injury, which was consistent with the finding by Feng et al [7].

Conclusions

In conclusion, we found that the initial VA was an important predictor of the final VA. Additionally, over half of globe injuries in our study were penetrating injuries and resulted in severe visual impairments. Our findings showed that it should be effective to reduce the morbidity of pediatric ocular trauma by minimizing risk factors, which will benefit health awareness of many families.

References

1. Al Wadeai EA, Osman AA, Macky TA, Soliman MM: **Epidemiological Features of Pediatric Ocular Trauma in Egypt**. *J Ophthalmol* 2016, **2016**:7874084.

2. Niiranen M, Raivio I: **Eye injuries in children**. *The British journal of ophthalmology* 1981, **65**(6):436-438.

3. Salvin JH: **Systematic approach to pediatric ocular trauma**. *Current opinion in ophthalmology* 2007, **18**(5):366-372.

4. Brophy M, Sinclair SA, Hostetler SG, Xiang H: **Pediatric eye injury-related hospitalizations in the United States**. *Pediatrics* 2006, **117**(6):e1263-1271.

5. Al-Mahdi HS, Bener A, Hashim SP: **Clinical pattern of pediatric ocular trauma in fast developing country**. *International emergency nursing* 2011, **19**(4):186-191.

6. Lee CH, Su WY, Lee L, Yang ML: **Pediatric ocular trauma in Taiwan**. *Chang Gung medical journal* 2008, **31**(1):59-65.

7. Ilhan HD, Bilgin AB, Cetinkaya A, Unal M, Yucel I: **Epidemiological and clinical features of paediatric open globe injuries in southwestern Turkey**. *Int J Ophthalmol* 2013, **6**(6):855-860.

8. Murray CJ, Vos T, Lozano R, Naghavi M, Flaxman AD, Michaud C, Ezzati M, Shibuya K, Salomon JA, Abdalla S *et al*: **Disability-adjusted life years (DALYs) for 291 diseases and injuries in 21 regions, 1990-2010: a systematic analysis for the Global Burden of Disease Study 2010**. *Lancet* 2012, **380**(9859):2197-2223.

9. Feng X, Feng K, Hu Y, Ma Z: **Clinical features and outcomes of vitrectomy in pediatric ocular injuries-eye injury vitrectomy study**. *Indian J Ophthalmol* 2014, **62**(4):450-453.

10. Shah VD, Uddaraju M, Singh A, Das RR: **Clinical Profile, Etiology, and Outcome of Infantile Ocular Trauma: A Developing Country Perspective**. *Pediatr Emerg Care* 2017.

11. Singh S, Sharma B, Kumar K, Dubey A, Ahirwar K: **Epidemiology, clinical profile and factors, predicting final visual outcome of pediatric ocular trauma in a tertiary eye care center of Central India**. *Indian J Ophthalmol* 2017, **65**(11):1192-1197.

12. Kuhn F, Morris R, Witherspoon CD, Heimann K, Jeffers JB, Treister G: **A standardized classification of ocular trauma**. *Ophthalmology* 1996, **103**(2):240-243.

13. Du Y, He W, Sun X, Lu Y, Zhu X: **Traumatic Cataract in Children in Eastern China: Shanghai Pediatric Cataract Study**. *Scientific reports* 2018, **8**(1):2588.

14. Puodziuviene E, Jokubauskiene G, Vieversyte M, Asselineau K: **A five-year retrospective study of the epidemiological characteristics and visual outcomes of pediatric ocular trauma**. *BMC ophthalmology* 2018, **18**(1):10.

15. Movahedinejad T, Adib-Hajbaghery M, Zahedi MR: **A Study on Hospital Admissions For Eye Trauma in Kashan, Iran**. *Trauma monthly* 2016, **21**(2):e28073.

16. Xu YN, Huang YS, Xie LX: **Pediatric traumatic cataract and surgery outcomes in eastern China: a hospital-based study**. *International journal of ophthalmology* 2013, **6**(2):160-164.

17. Hosseini H, Masoumpour M, Keshavarz-Fazl F, Razeghinejad MR, Salouti R, Nowroozzadeh MH: **Clinical and epidemiologic characteristics of severe childhood ocular injuries in southern iran**. *Middle East African journal of ophthalmology* 2011, **18**(2):136-140.

18. Maltzman BA, Pruzon H, Mund ML: **A survey of ocular trauma**. *Survey of ophthalmology* 1976, **21**(3):285-290.

19. Pieramici DJ, Sternberg P, Jr., Aaberg TM, Sr., Bridges WZ, Jr., Capone A, Jr., Cardillo JA, de Juan E, Jr., Kuhn F, Meredith TA, Mieler WF *et al*: **A system for classifying mechanical injuries of the eye (globe). The Ocular Trauma Classification Group**. *Am J Ophthalmol* 1997, **123**(6):820-831.

20. Podbielski DW, Surkont M, Tehrani NN, Ratnapalan S: **Pediatric eye injuries in a Canadian emergency department**. *Canadian journal of ophthalmology Journal canadien d'ophtalmologie* 2009, **44**(5):519-522.

21. Adib-Hajbaghery M, Maghaminejad F: **Epidemiology of patients with multiple trauma and the quality of their prehospital respiration management in kashan, iran: six months assessment**. *Archives of trauma research* 2014, **3**(2):e17150.

22. Mowatt L, McDonald A, Ferron-Boothe D: **Hospitalization trends in adult ocular trauma at the University Hospital of the West Indies**. *The West Indian medical journal* 2012, **61**(6):605-609.

23. Sii F, Barry RJ, Abbott J, Blanch RJ, MacEwen CJ, Shah P: **The UK Paediatric Ocular Trauma Study 2 (POTS2): demographics and mechanisms of injuries**. *Clinical ophthalmology* 2018, **12**:105-111.

24. Machemer R, Buettner H, Norton EW, Parel JM: **Vitrectomy: a pars plana approach**. *Transactions - American Academy of Ophthalmology and Otolaryngology American Academy of Ophthalmology and Otolaryngology* 1971, **75**(4):813-820.

25. Yospaiboon Y, Intarapanich A, Laovirojjanakul W, Ratanapakorn T, Sinawat S, Sanguansak T, Bhoomibunchoo C: **Factors affecting visual outcomes after treatment of infectious endophthalmitis in northeastern Thailand**. *Clinical ophthalmology* 2018, **12**:765-772.

26. Cernichiaro-Espinosa LA, Berrocal AM: **Novel Surgical Technique for Inducing Posterior Vitreous Detachment during Pars Plana Vitrectomy for Pediatric Patients Using a Flexible Loop**. *Retinal cases & brief reports* 2017.

27. Kita M, Fujii Y, Hama S: **Twenty five-gauge endoscopic vitrectomy for proliferative vitreoretinopathy with severe corneal opacity**. *Japanese journal of ophthalmology* 2018, **62**(3):302-306.

28. Rivera-Sempertegui JO, Gallegos-Valencia AJ, Navarro-Lopez P, Ochoa-Contreras D: **[Vitreous surgery in paediatric population. Visual and anatomic outcomes]**. *Archivos de la Sociedad Espanola de Oftalmologia* 2005, **80**(2):93-98.

29. Gupta N, Punjabi OS, Steinle NC, Singh RP: **Rate of hypotony following 25-gauge pars plana vitrectomy**. *Ophthalmic surgery, lasers & imaging retina* 2013, **44**(2):155-159.

30. Sheard RM, Mireskandari K, Ezra E, Sullivan PM: **Vitreoretinal surgery after childhood ocular trauma**. *Eye* 2007, **21**(6):793-798.

31. Wadhwa N, Venkatesh P, Sampangi R, Garg S: **Rhegmatogenous retinal detachments in children in India: clinical characteristics, risk factors, and surgical outcomes**. *Journal of AAPOS : the official publication of the American Association for Pediatric Ophthalmology and Strabismus* 2008, **12**(6):551-554.

32. Faghihi H, Hajizadeh F, Esfahani MR, Rasoulinejad SA, Lashay A, Mirshahi A, Karkhaneh R, Tabatabaey A, Khabazkhoob M, Faghihi S: **Posttraumatic endophthalmitis: report No. 2**. *Retina* 2012, **32**(1):146-151.

Declarations

Ethics approval and consent to participate

This retrospective study was approved by the ethics committee of the Southwest Hospital (KY201858) and followed the tenets of the Declaration of Helsinki. Informed consent was not given, as patient records and information were anonymized and de-identified prior to analysis.

Consent for publication

Not applicable.

Availability of data and material

The datasets used and/or analyzed during the current study are available from the corresponding author on reasonable request.

Competing interests

The authors declare that they have no competing interests.

Funding

None.

Authors' contributions

Yong Liu conceived of the study and participated in its design and coordination. Yan He participated in drafting and revising the manuscript. Songwen Nian participated in statistical analysis and helped to draft the manuscript. Nan Wu, Yi Wang and Tao Yu contributed in study design and data collection. All authors read and approved the final manuscript.

Figures

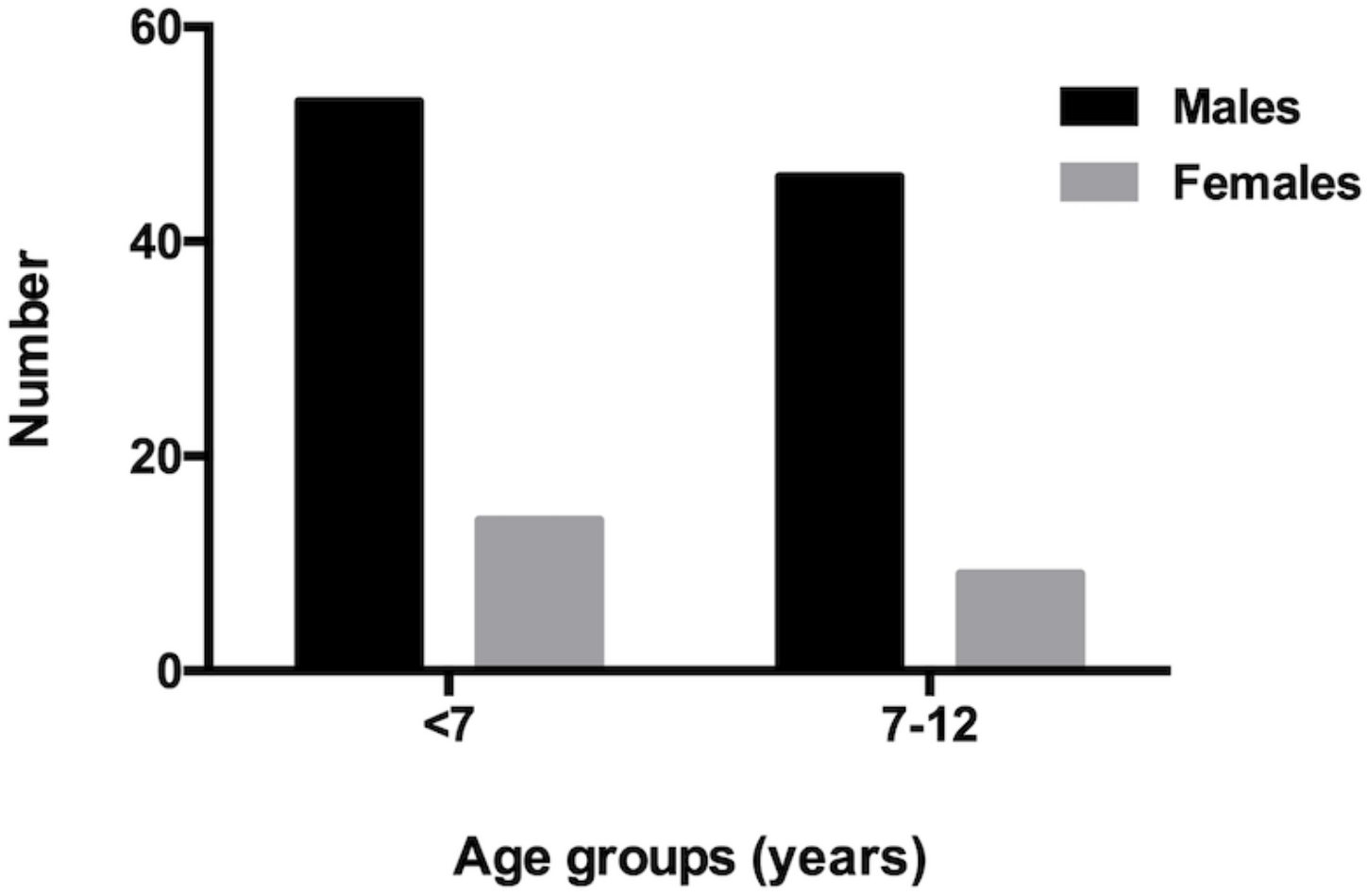

Figure 1

Distribution of trauma by gender and by age group (%). The proportion of ocular trauma decreased in both males and females at 7–12 years old compared to younger ones (< 7 years old). In the age range of 7–12 years, the incidence of ocular trauma was less in females than males.

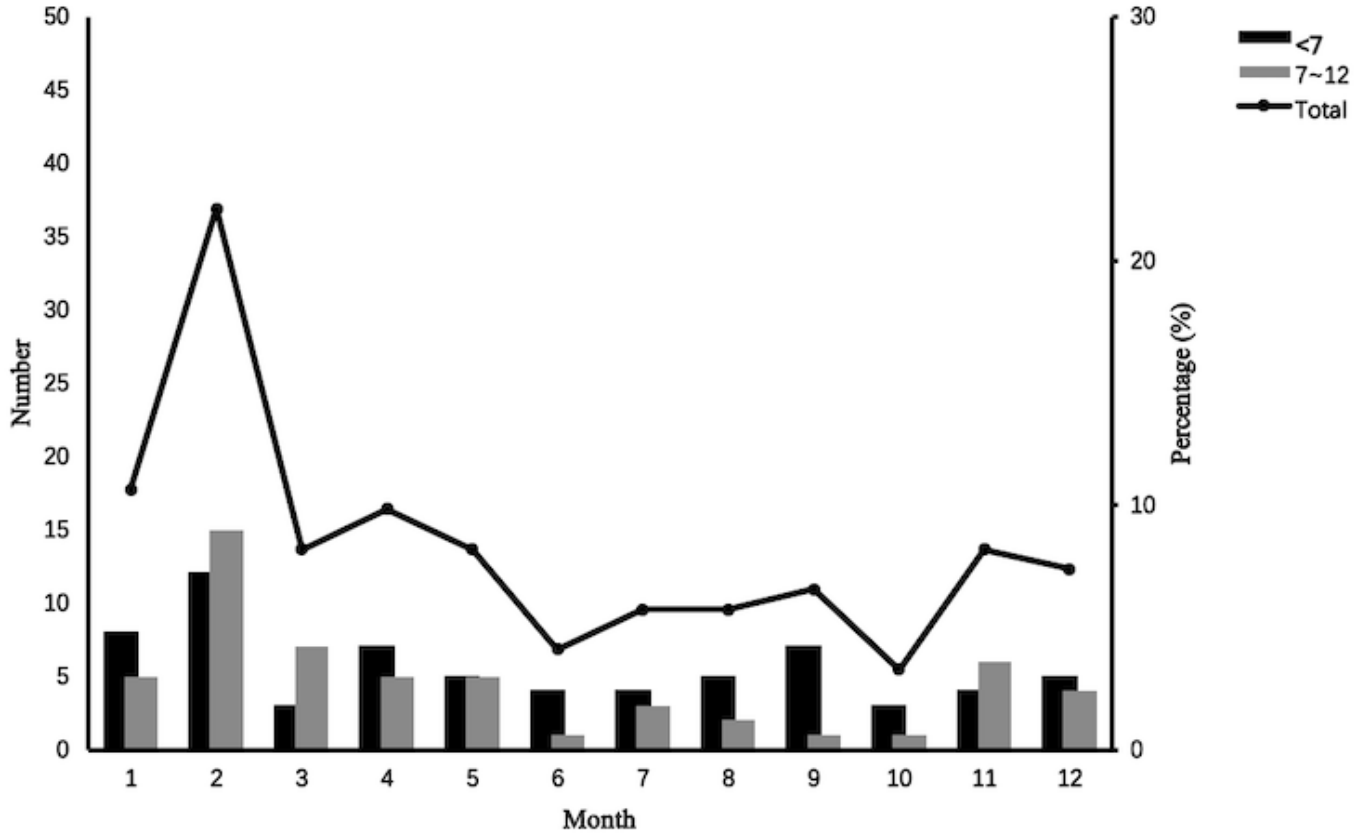

Figure 2

Month distribution of ocular trauma in different age groups. The most common month of pediatric ocular trauma happened in February.

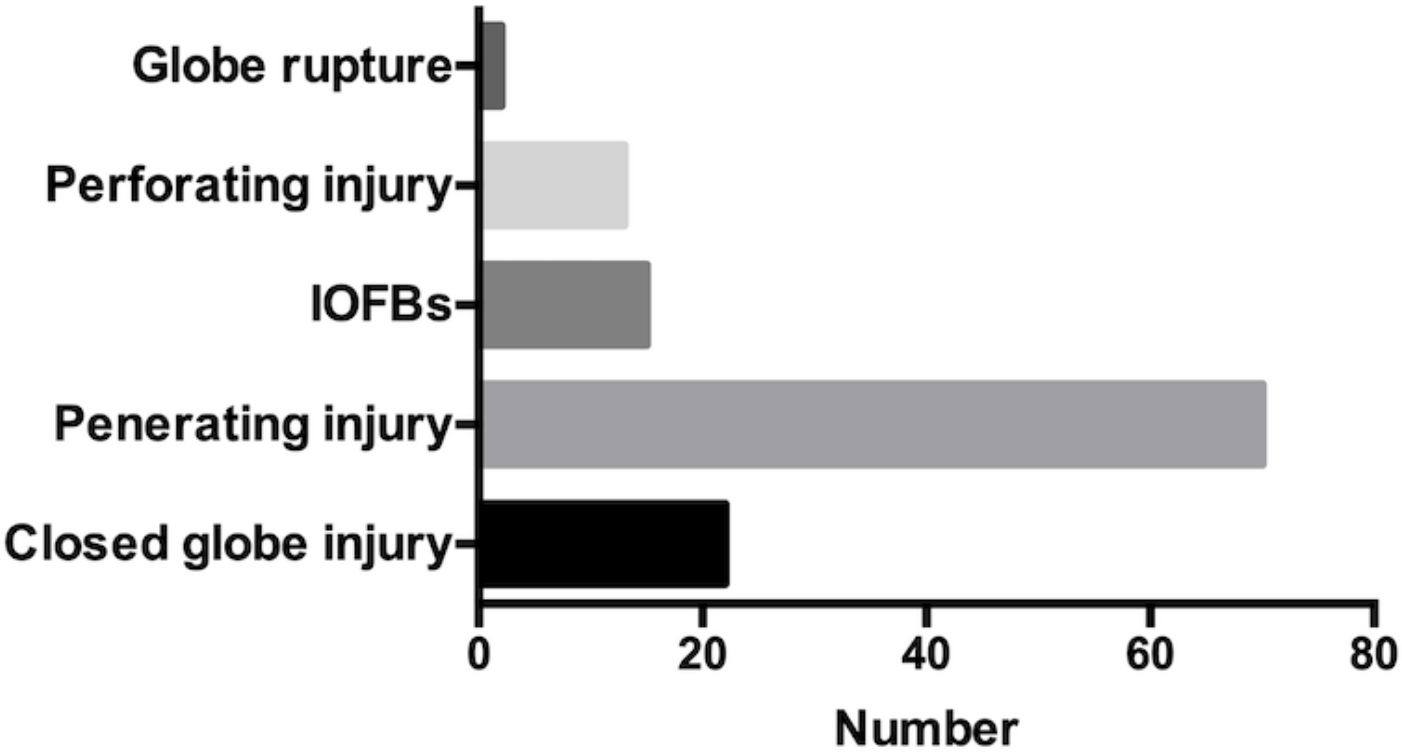

Figure 3

Distribution and classification of ocular trauma in our study. The pediatric ocular trauma was classified into closed globe injury, penetrating injury, intraocular foreign body, perforating injury and ruptured globes. The most common type was penetrating injury.