

Analysis on Pregnancy Outcomes and Risk Factors of Cervical Polypectomy During the First and Second Trimester Pregnancy

Yu-luan Huang

Zhejiang University School of Medicine Women's Hospital <https://orcid.org/0000-0001-8997-3447>

Rui-zhe Chen

Zhejiang University School of Medicine Women's Hospital

Fang Le (✉ lefang@zju.edu.cn)

Zhejiang University School of Medicine Women's Hospital

Research Article

Keywords: cervical polyp, polypectomy, deducial polyp, miscarriage, preterm delivery

Posted Date: August 5th, 2021

DOI: <https://doi.org/10.21203/rs.3.rs-714922/v1>

License:  This work is licensed under a Creative Commons Attribution 4.0 International License.

[Read Full License](#)

Analysis on pregnancy outcomes and risk factors of cervical polypectomy during the first and second trimester pregnancy

Yu-luan Huang^{1,a}, Rui-zhe Chen^{1,a}, Fang Le^{1,*}

¹ Women's Hospital, School of Medicine, Zhejiang University, Hangzhou 310006, China;

^a These authors contributed equally to this work.

* **Corresponding author:** Fang Le, Center of Reproductive Medicine, Zhejiang University School of Medicine Women's Hospital, Hangzhou, China, 1 Xueshi Road, Hangzhou, 310006, China; E-mail: lefang@zju.edu.cn

Abstract

Purpose: To evaluate the risk factors of miscarriage in patients attempted cervical polypectomy during the first and second trimester pregnancy.

Methods: Pregnant women with singleton infants who underwent cervical polypectomy during the first and second trimester between January 2013 to May 2019 were investigated. The study retrospectively reviewed the clinical features and pregnancy outcomes after cervical polypectomy. A multivariable regression was performed to predict the risk factors of miscarriage.

Results: A total of 307 pregnant females were eventually included in our study. 27 patients (8.8%, 27/307) had a miscarriage before 28 weeks, 37 patients (12.1%, 37/307) had a preterm delivery. After univariate analysis, we found that the presence of decidual polyps and vaginal bleeding after polypectomy were the risk factors for miscarriage. Moreover, the incidence of miscarriage was significantly higher in the patients with decidual polyps than in those with endocervical polyps (14.9% vs.5.6%, $p=0.010$).

Conclusion: The most suitable hemostasis method should be taken in the cervical polypectomy during pregnancy. The risk of miscarriage associated with polypectomy during pregnancy is higher in females with decidual polyps. If they do not cause excessive vaginal bleeding and can be ruled out the possibility of malignancy, conservative treatment may lead to a better outcome.

Keywords: cervical polyp, polypectomy, decidual polyp, miscarriage, preterm delivery

Introduction

Cervical polyp is a common gynecological disease, occurring in 2-5% of adult women [1]. During pregnancy, cervical polyps can be found irrespective of gestational age. The exact prevalence in pregnant women is unknown at present. In some cases a cervical polyp can be asymptomatic, which is incidentally discovered by routine pelvic examination[2, 3]. In others a pregnant woman with cervical polyp may present with vaginal discharge, vaginal bleeding, postcoital bleeding and cervical infection [4, 5]. Cervical polyps during pregnancy with recurrent vaginal bleeding may often be misdiagnosed as threatened abortion. These polyps can raise concern and discomfort to the pregnant women.

A controversial question is whether a cervical polyp during pregnancy needs to be removed. While, there are no standardized guidelines to answer this question. Some practitioners hold the opinion that cervical polyps detected during pregnancy increase the risk of chorioamnionitis, and hence favor to remove the polyps [6]. Others believe that patients undergoing polypectomy in pregnancy have high risks of miscarriage or spontaneous premature delivery [7-9]. Although most cervical polyps are benign, malignant change can be found in 0.2-1.63% of cases in the general population [1, 10, 11]. In pregnant persons the risk of malignancy is not clear and limited reports have describe rare forms of cancerous cervical polyps [12-14].

There is a lack of evidence to evaluate the risk for patients with cervical polyps and management to provide full information to patients on their chances of a healthy pregnancy. Finding factors that are associated with a poor prognosis could provide opportunities to improve the pregnancy outcome. Thus, firstly, the present study is aimed to analysis whether polypectomy of cervical polyps during pregnancy is associated with the adverse pregnancy outcomes. Secondly, we further to explore the risk factors associated with a poor prognosis for the pregnancy outcomes in patients with cervical polyps.

Materials and methods

Patient's characteristics

Pregnant women with singleton infants who were diagnosed with cervical polyps and underwent polypectomy during pregnancy at Women's Hospital School of Medicine Zhejiang University between January 2013 to May 2019 were evaluated. This study was approved by the Research Ethics Committee of the Women's Hospital School of Medicine Zhejiang University, China. The procedures used in this study adhere to the tenets of the Declaration of Helsinki. Exclusion criteria were as followed: termination of pregnancy due to an obstetric indication, such as abruption of the placenta, placental previa, and preeclampsia. Patients who delivered because of severe complications of medical

and surgical diseases, such as congenital heart disease, renal failure and appendicitis, were not included. Gestational weeks were calculated according to the last menstrual period and confirmed by ultrasound in early pregnancy. We retrospectively reviewed the patients' age, gravida, parity, relevant past gynaecological history, vaginal bleeding before polypectomy and the clinical course and pregnancy outcomes after polypectomy. **Treatment**

Approaches of cervical polypectomy: we resected cervical polyp by twisting and rotating the base of the polyp until it came off using a pair of ring forceps mostly without anesthesia; for polyps with a thick stalk usually require a electrosurgical excision or coil ligation removal. After the excision of cervical polyps, gauze packing could be used to prevent bleeding and taken out after 24 hours. Inhibitors of uterine contractions, progesterone preparations and antibiotics can be administered prophylactically during perioperative period. The inhibitors of uterine contractions are as follows: intravenous drip of 25% magnesium sulfate injection 30-40ml or phloroglucinol injection 80mg (in 5% glucose injection). Progesterone preparations are as follows: didrogestrone tablet 10mg twice daily and/or progesterone injection 20-60mg once daily intramuscular injection.

Every removed polyp must be sent for further histological examination to rule out malignancy. According to the histological patterns, the excised polyps were divided into four groups: decidual polyps, endocervical polyps, both and others. Endocervical polyps are focal, hyperplastic protrusions of endocervical folds, including the epithelium and substantia propria [15]. Decidual polyps include extruded fragments of decidua, a polypoid protrusion from the endocervix with the stromal pseudodecidual change. It frequently presents as a raised plaque or pseudopolyp if the pseudodecidual occurs on the exocervix. The cells develop abundant pink cytoplasm, with well-defined cellular border [15]. (Fig1)

Statistical analyses

The data were presented as the mean \pm standard deviation and analysed using IBM SPSS 21.0. Firstly, the distribution state of measurement data were tested. Kruskal-Wallis H test or Mann-Whitney U test were used for non-normal distribution data. Categorical data were compared using the χ^2 -test or Fisher's exact test where appropriate. The multivariate analysis was based on a logistic regression analysis. A p value < 0.05 was considered to be significant.

Results

A total of 307 pregnant females were eventually included in our study. Among them, 243 patients delivered at ≥ 37 weeks, 27 patients had a miscarriage before 28 weeks, others had a preterm delivery. Table 1 shows a comparison of clinical features between miscarriage, preterm delivery and term delivery. The maternal age, history of conization of cervix, frequency of preterm deliveries, the proportion of decidual polyps and bleeding after polypectomy were significantly different between three groups.

As shown in Table 2, the risk factors were identified by a univariate analysis and a multiple logistic regression analysis for patients in pregnancy who had undergone polypectomy. The independent risk factors identified by a multiple logistic regression analysis for miscarriage were the presence of decidual polyps [Odds Ratio (OR) 2.346, 95% confidence interval (CI) 1.330-4.141, $p=0.003$] and vaginal bleeding after polypectomy (OR 2.248, 95% CI 1.207-4.191, $p=0.011$).

The pathological diagnoses include 197 cases of endocervical polyps, 101 cases decidual polyps, 5 cases of both pathological changes and 4 others, no malignant or precancerous case was found. The clinical maternal demographics and clinical courses between decidual and endocervical polyps are demonstrated in Table 3. The proportion of nulliparity, use of inhibitors of uterine contractions during perioperative period and gestational age at polypectomy was significantly higher among the patients with endocervical polyps than in those with decidual polyps. The gestational weeks at polypectomy of decidual polyps group was significantly earlier than that of endocervical polyp group. The decidual polyp group had a higher percentage of progesterone drugs usage to protect the fetus during early pregnancy (64.4%-36.0%, $p<0.001$). The incidence of miscarriage (14.9%-5.6%, $p=0.010$) was significantly higher in the patients with decidual polyps than in those with endocervical polyps.

Discussion

Cervical polyps are uncommon in pregnant females and they are usually small and asymptomatic. Some cervical polyps with recurrent vaginal bleeding are usually misdiagnosed as an inevitable miscarriage. They can cause considerable emotional stress. However, the clinical treatment of pregnancy with cervical polyps is still controversial by far. Some scholars found that the granulocyte elastase activity in cervical mucus decreased significantly after polypectomy compared with prepolyectomy. They suggested that cervical polyp during pregnancy should be removed since the cervical polyp may increase the risk of inflammation and chorioamnionitis [6].

Our study showed that with cervical polypectomy during the first and second trimester, the frequency of miscarriage before 28 weeks of gestation was 8.8% (27/307), which was slightly higher than a Japanese study [7]. In present study, we found that "vaginal bleeding after polypectomy" was

identified as strong risk factors for miscarriage. The blood vessels rupture after cervical polyps removed which can cause vaginal bleeding. Prolonged vaginal bleeding can alter the cervix environment, especially in the condition of vaginal bacterial flora, it can aggravate the inflammatory response and promote ascending infections. In most research, cervical polyps during pregnancy were removed by forceps grasping the base and twisting. However, others prefer electrosurgery because they think this method has a better hemostasis [16]. Discussion on methods of cervical polypectomy during pregnancy has been ongoing. Shigeru et al. [8] reported a case of premature rupture of membrane (PROM) at 22 weeks of gestation in a 29-year-old primigravida who received a cervical polypectomy using an Endoloop polydioxanone suture (PDS) II™ at 11 weeks of gestation. Our study demonstrated that there was no significant difference in pregnancy outcome between different excision methods. Postoperative gauze filling didn't increase the risk of miscarriage and premature delivery. Therefore, it should pay attention to prevent postoperative vaginal bleeding when cervical polypectomy is undertaken during gestation period regardless of the method. If necessary, gauze or hemostatic material can be used for hemostasis.

Our study showed that the risk of miscarriage associated with polypectomy during pregnancy was related to the pathological type of cervical polyps. Females with decidual polyps were more likely to have a poor pregnancy outcome than females with cervical polyps. Cervical decidual polyp is uncommon, only sporadic reports have described this special type polyp. Seo et al. [17] described a case with a decidual polyp resulted in first trimester miscarriage after diagnostic polypectomy at gestation week 5. Tokunaka et al. [18] found that the removal of decidual polyps during pregnancy carried a risk of spontaneous abortion (12.2%) and preterm delivery (34.2%), which were higher than that of endocervical polyps.

Decidual polyps include decidualized endocervical polyps and prolapsed fragments of decidua. The removal of decidual polyps maybe cause trauma to the endometrial mucosa and/ or inflammation may affect the endometrium [18]. Levin et al. postulated that disruption of blood vessels and injury to the decidual membranes may promote local inflammation and procoagulant changes associated with placental abruption [19]. In addition, because the pedicle of some decidual polyps is often wide and deep, most of the surgical treatment can only be cut from the external os of cervix, but cannot achieve complete resection. So that decidual polypectomy is more likely to take a risk of miscarriage and/ or preterm delivery. Decidual polyps are presumably mediated by the high levels of progesterone during pregnancy. With the extensive development of assisted reproductive technology (ART), the application of luteal support may also increase the incidence of decidual polyps. In our study, there were a total of eight females who were pregnant by ART, and half of them were pathologically indicated to be

decidual polyps. Pregnant women often use progesterone in early pregnancy when they have symptoms of threatened abortion such as vaginal bleeding. Our research found that pregnant patients with decidual polyps had a significantly higher percentage of early progesterone use than those with endocervical polyps. Based on our results and the above studies, we suggest that if it is not necessary in the early stage of pregnancy, progesterone should not be used as much as possible, so as to avoid the development of decidual polyps which maybe lead to adverse pregnancy outcomes. Ectopic decidua can become smaller or regress in the second and third trimester and postpartum spontaneously without any complications [20]. Thus, we has reason to believe that asymptomatic deciduous polyps during pregnancy do not need any therapeutic intervention. In addition, according to our research, decidual polyps are more likely to be observed in multiparous women. It may be thought that recurrent childbirth increases the exposure of the cervical stroma to high levels of estrogen and progesterone.

Anyhow, decidual polyps because of the particularity of the growth way and the environment, increased the risk of spontaneous abortion. But polypectomy may also be at risk. If these polyps do not cause excessive vaginal bleeding and can be ruled out the possibility of malignancy, conservative treatment may lead to a better outcome. Mostly, cervical polyps during pregnancy are found in gynecological examination. However, it is difficult to distinguish cervical polyps from decidual polyps by their appearance. While, in fact, pathological diagnosis is needed to clear polyp type. Therefore, when decidual polyps are highly suspected, we suggest that biopsy of superficial polyps may be able to confirm the diagnosis and avoid surgical risk. For pregnant females with vaginal bleeding caused by decidual polyps, maybe we can perform surgery in stages: remove the necrotic surface first, and continue to observe if there is no subsequent bleeding. Further prospective case-control studies are needed to determine the optimal management of decidual polyps.

limitations

There are some potential limitations for our study. Only those who underwent cervical polypectomies during pregnancy were included. Patients who received conservative treatment for cervical polyps were excluded from our study and pregnancy outcomes were not compared between the two groups. It is unclear whether polypectomy or the polyps itself induce miscarriage and/ or preterm delivery. We also do not know if there is an underlying choriois that can cause miscarriage and preterm delivery before the cervical polypectomy. The clinical data were gathered from a single hospital, more higher-level evidence is needed.

Acknowledgements

We thank the members of our hospital for their support and valuable suggestions.

Declarations

Funding

This work was supported by the Natural Science Foundation of Zhejiang Province (LGD19H040001).

Availability of data and material

Data are available from the authors upon reasonable request.

Authors' contributions

In this paper, Yu-luan Huang and Fang Le designed the study. Rui-zhe Chen and Yu-luan Huang acquired data and performed the statistical analysis.

Compliance with ethical standards

Conflicts of interest

The authors declare that they have no competing interests.

Ethics approval

This study was approved by the ethics committee of the Women's Hospital, Zhejiang University School of Medicine. This article does not contain any studies with animals performed by any of the authors. All procedures performed in studies involving human participants were in accordance with the 1964 Helsinki Declaration and its later amendments or comparable ethical standards.

Informed consent

The consent of the study participants was deemed unnecessary as the study only concerned the retrospective review of the medical database. The need of informed consent was waived by the ethics committee {Medical Ethics Committee of the Women's Hospital, Zhejiang University School of Medicine} for this retrospective study.

References

1. A A Ozsaran IMI, S Sağol (1999) Endometrial hyperplasia co-existing with cervical polyps. *Int J Gynaecol Obstet* 66:185-186. doi: 10.1016/s0020-7292(99)00024-7
2. Tanos V, Berry KE, Seikkula J, Abi Raad E, Stavroulis A, Sleiman Z, Campo R, Gordts S (2017) The management of polyps in female reproductive organs. *International Journal of Surgery* 43:7-16. doi: 10.1016/j.ijso.2017.05.012
3. Budak A, Kanmaz AG (2019) Role of endometrial sampling in cases with asymptomatic cervical polyps. *Journal of Gynecology Obstetrics and Human Reproduction* 48:207-211. doi: 10.1016/j.jogoh.2019.01.005
4. Casey PM, Long ME, Marnach ML (2011) Abnormal Cervical Appearance: What to Do, When to Worry? *Mayo Clinic Proceedings* 86:147-151. doi: 10.4065/mcp.2010.0512
5. Kirbaş A, BiBeroğLu EH, DağLar HK, TİMUR H, Uygur D, DanişMan N (2015) Pregnancy

- Complicated with a Giant Cervical Polyp: Case Report. *Turkiye Klinikleri Journal of Gynecology and Obstetrics* 25:275-277. doi: 10.5336/gynobstet.2014-42238
6. Kanayama N, Terao T (1991) The relation between granulocyte elastase activity in cervical mucus and gestational cervical polyp. *Nihon Sanka Fujinka Gakkai Zasshi* 43:26-30.
 7. Fukuta K, Yoneda S, Yoneda N, Shiozaki A, Nakashima A, Minamisaka T, Imura J, Saito S (2020) Risk factors for spontaneous miscarriage above 12 weeks or premature delivery in patients undergoing cervical polypectomy during pregnancy. *BMC Pregnancy and Childbirth* 20. doi: 10.1186/s12884-019-2710-z
 8. Aoki S HM, Seki K, Hirahara F (2016) Preterm premature rupture of membrane after polypectomy using an Endoloop polydioxanone suture II(TM). *Clin Case Rep* 4:331-332. doi: 10.1002/ccr3.503
 9. Hamadeh S AB, Hamadeh N, Rahman J (2018) Conservative Management of Huge Symptomatic Endocervical Polyp in Pregnancy: A Case Report. *Afr J Reprod Health* 22:88-90. doi: 10.29063/ajrh2018/v22i2.10
 10. Levy RA, Kumarapeli AR, Spencer HJ, Quick CM (2016) Cervical polyps: Is histologic evaluation necessary? *Pathology - Research and Practice* 212:800-803. doi: 10.1016/j.prp.2016.06.010
 11. Pegu B, Srinivas BH, Saranya TS, Murugesan R, Priyadarshini Thippeswamy S, Gaur BPS (2020) Cervical polyp: evaluating the need of routine surgical intervention and its correlation with cervical smear cytology and endometrial pathology: a retrospective study. *Obstetrics & Gynecology Science* 63:735-742. doi: 10.5468/ogs.20177
 12. Albores-Saavedra J, Martinez-Benitez B, Luevano E (2008) Small Cell Carcinomas and Large Cell Neuroendocrine Carcinomas of the Endometrium and Cervix: Polypoid Tumors and Those Arising in Polyps May Have a Favorable Prognosis. *International Journal of Gynecological Pathology* 27:333-339. doi: 10.1097/PGP.0b013e31815de006
 13. Ohwada M, Suzuki M, Hironaka M, Irie T, Sato I (2001) Neuroendocrine Small Cell Carcinoma of the Uterine Cervix Showing Polypoid Growth and Complicated by Pregnancy. *Gynecologic Oncology* 81:117-119. doi: 10.1006/gyno.2000.6117
 14. Lüftl M, Neisius U, Schell H (2004) Pseudosarcomatous variant of a genital fibroepithelial stromal polyp in a pregnancy. *J Dtsch Dermatol Ges* 2:600-602.
 15. Thomas C BM, Alex F, eds (2011) *Benign diseases of the cervix. Blaustein's pathology of the female genital tract.* 6th ed. New York: Springer-Verlag:155-191.
 16. Costas Panayotidis LC (2013) Cervical Polypectomy during Pregnancy: The Gynaecological

- Perspective. *Journal of Genital System & Disorders* 02. doi: 10.4172/2325-9728.1000108
17. Seo N, Tachibana D, Misugi T, Koyama M, Tanaka S (2020) First trimester findings of decidual polyp: Caution to avoid polypectomy. *European Journal of Obstetrics & Gynecology and Reproductive Biology* 249:109-110. doi: 10.1016/j.ejogrb.2020.04.008
 18. Tokunaka M, Hasegawa J, Oba T, Nakamura M, Matsuoka R, Ichizuka K, Otsuki K, Okai T, Sekizawa A (2014) Decidual polyps are associated with preterm delivery in cases of attempted uterine cervical polypectomy during the first and second trimester. *The Journal of Maternal-Fetal & Neonatal Medicine* 28:1061-1063. doi: 10.3109/14767058.2014.942633
 19. Levin G, Rottenstreich A (2018) 2nd trimester miscarriage following decidual polypectomy. *European Journal of Obstetrics & Gynecology and Reproductive Biology* 225:262-263. doi: 10.1016/j.ejogrb.2018.04.026
 20. Kondi-Pafiti A GD, Kontogianni-Katsarou K, Papadias K, Kairi-Vassilatou E (2005) Ectopic decidua mimicking metastatic lesions--report of three cases and review of the literature. *Eur J Gynaecol Oncol* 26:459-461.

Figure Legend

Fig1: a. Endocervical polyp: this is the most common type of endocervical polyp which was composed of mucinous epithelium that lines crypts.

b. Decidual polyp: a polypid protrusion from the endocervix which contains cervical stromal pseudodecidual changes during pregnancy.

Figures

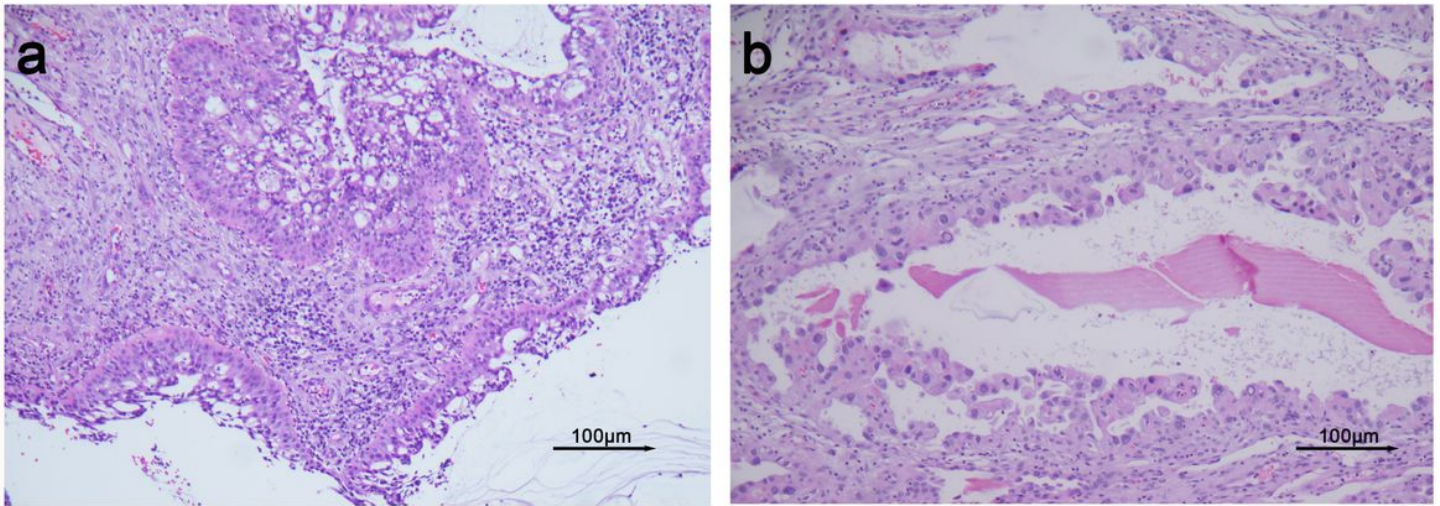


Figure 1

a. Endocervical polyp: this is the most common type of endocervical polyp which was composed of mucinous epithelium that lines crypts. b. Decidual polyp: a polypoid protrusion from the endocervix which contains cervical stromal pseudodecidual changes during pregnancy.

Supplementary Files

This is a list of supplementary files associated with this preprint. Click to download.

- [table.pdf](#)