The Clinical Value of ^{68}Ga-FAPI-04 PET/CT on Detection of Lymph Node Metastasis and Staging for Esophageal Carcinoma

Xiao Yang
The Affiliated Hospital of Southwest Medical University
Zhouxiang You
The Affiliated Hospital of Southwest Medical University
Lin Liu
The Affiliated Hospital of Southwest Medical University
Lei Lei
The Affiliated Hospital of Southwest Medical University
Chungru Mou
The Affiliated Hospital of Southwest Medical University
Tianyang Dai
The Affiliated Hospital of Southwest Medical University
Li Wang
The Affiliated Hospital of Southwest Medical University
Yue Chen
The Affiliated Hospital of Southwest Medical University
Zhi Hu
The Affiliated Hospital of Southwest Medical University
Huipan Liu (liuhuipan1573@163.com)
the Affiliated Hospital of Southwest Medical University https://orcid.org/0000-0001-7328-4241

Research Article

Keywords: 68Ga-FAPI, PET/CT, esophageal carcinoma, lymph node metastasis

Posted Date: July 24th, 2021

DOI: https://doi.org/10.21203/rs.3.rs-724372/v1

Abstract

Purpose To observe the clinical application value of ^{68}Ga-FAPI-04 PET/CT in the preoperative detection of lymph node metastasis and staging of esophageal cancer.

Methods A prospective analysis of 29 surgical patients was performed. ^{68}Ga-FAPI-04 PET/CT was performed within 1 week before the operation. All patients received enhanced CT during the same period. None of these patients had received preoperative treatment before the operation. The value of ^{68}Ga-FAPI-04 PET/CT and enhanced CT in the diagnosis of lymph node metastasis and preoperative staging of esophageal cancer was compared according to postoperative pathology.

Results Both ^{68}Ga-FAPI-04 PET/CT and CT detected the primary tumor (29/29 cases). 637 lymph nodes were surgically removed, of which 37 lymph nodes were metastasized. The sensitivity, specificity, accuracy, positive predictive value, and negative predictive value of PET/CT for lymph node metastasis detection were 71.1%, 99.4%, 97.8%, 90.0%, and 98.2%; The sensitivity, specificity, accuracy, positive predictive value, and negative predictive value of CT for lymph node metastasis detection were 36.8%, 98.9%, 95.3%, 70.0%, and 96.1%, respectively.

Conclusion ^{68}Ga-FAPI-04 PET/CT is better than enhanced CT in diagnosing lymph node metastasis and determining lymph node staging in esophageal cancer.

Introduction

With approximately 600,000 new diagnoses and 540,000 mortalities in 2020, esophageal cancer is the 6th leading cause of cancer-associated death worldwide with increased incidence over the past decade [1]. Squamous cell carcinoma (SCC) is the main histological type of esophageal cancer in Central and Southeast Asia, and adenocarcinoma is the most common form in Northern and Western Europe, North America and Oceania. Fibroblast activating protein (FAP) is overexpressed in cancer-associated fibroblasts (CAF) of various epithelial cancers, but the expression level is lower in normal tissues [2]. Gallium-68 (^{68}Ga)-labeled FAP inhibitor (^{68}Ga-FAPI) is a new and promising PET tracer that can be used for imaging a variety of cancers [2–4]. In addition, studies have shown that esophageal cancer expresses elevated levels of FAP and ^{68}Ga-FAPI has a good tumor-to-background ratio [5, 6]. There are also several case studies showing that ^{68}Ga-FAPI PET/CT can detect primary tumors and metastatic lymph nodes in esophageal cancer [6–8]. As a promising alternative to FDG in several tumor indications, the exact diagnostic use of ^{68}Ga-FAPI in esophageal cancer has not yet been systematically explored.

Herein, we use enhanced CT as a reference to explore the value of ^{68}Ga-FAPI-04 PET/CT in the diagnosis of lymph node metastasis and preoperative staging of esophageal cancer.

Patients, Materials, And Methods

Patients

Patients included in this study were recruited from January 2020 to January 2021 at the Affiliated Hospital of Southwest Medical University. The inclusion criteria of this study were: (1) patients with newly diagnosed esophageal cancer by pathological examination of endoscopic biopsy specimens; (2) esophagectomy had therapeutic purposes; (3) age 85 years and younger. The exclusion criteria were: (1) patients whose treatment had already started before their ^{68}Ga-FAPI PET/CT examination; (2) simultaneous malignant tumors other than esophageal cancer; (3) the inability or unwillingness of the research participant, parent, or legal representative to provide written informed consent.

This prospective study has been approved by the Institutional Review Committee of our hospital (AHSWMU-2020-035) and registered in Chinese Clinical Trail Register (ChiCTR2100044131). All patients have signed informed consent. A total of 29 patients (age 63.1 ± 7.7 years) were included in this study, including 28 males and 1 female. According to the American Joint Committee on Cancer (AJCC, 8th edition), the TNM staging standards for malignant tumors were jointly issued to classify tumors and disease. Resectability was determined by conventional staging, which included CT of the neck, chest, and abdomen, bone scan, and esophagography. In order to compare the pathological results with PET/CT images, we classified the location of lymph nodes according to the anatomical area (AJCC, 8th edition).

^{68}Ga-FAPI PET/CT

We purchased the precursor FAPI-04 from MCE (MedChemExpress, USA), with a purity of 98% and a quality of 872.91. The ^{68}Ga-FAPI labeling was carried out according to the method described previously [9]. The radiochemical purity of ^{68}Ga-FAPI exceeded 95%. The sterility test was performed by the radiochemical equipment of the Department of Nuclear Medicine, the Affiliated Hospital of Southwest Medical University. The final product was sterile and meet all the required standards of our institution before use.

The intravenous radiotracer dose was 1.85–2.59 MBq/kg, and imaging was performed 40–60 min after radiotracer injection (United Imaging UMI 780 PET/CT). All subjects were required to urinate as much as possible for imaging preparations, which reduced the influence of the residual radiotracer in the renal. The scope of the whole-body inspection was from the base of the skull to the base of the thigh, using 5 to 6 beds (3 min/bed). The matrix was 128 × 128, FOV 600mm, the PET layer thickness was 3 mm, and all PET images were reconstructed iteratively (OSEM). After the reconstruction was completed, the post-processing and fusion software of United Imaging was used for image analysis.

The image analysis

PET/CT study was independently reviewed by two experienced nuclear medicine physicians. Based on the understanding of the normal distribution of FAPI in the whole-body, compared with the normal tissues of the contralateral side and surrounding soft tissues, the positive lesion was determined to be a lesion with increased tracer uptake. If the uptake of FAPI increased significantly to moderately, the lesion was characterized as obvious or possibly abnormal. Diffuse mild uptake or no increased activity (in the case

of abnormalities found on CT, and no corresponding abnormalities on PET) was considered a normal or benign disease. The esophageal cancer uptake value of FAPI was measured by a semi-quantitative method-the maximum standardized uptake value (SUVmax). A circular area of interest with a diameter of 1.5 cm was placed on the highest intensity area of esophagus, and the uptake was automatically quantified as SUVmax, and calculated target/background rates (TBR) using normal esophagus SUVmean (Mean ± SD value). TBR of lymph node metastasis was calculated using SUVmean of normal adipose tissue.

CT Scan

All patients underwent CT scans of the neck, chest and abdomen. A 10 mm continuous scan was performed from the neck to the bottom of the liver. CT scan with intravenous contrast agent. 4 patients were scanned to the pelvis. CT was judged by an experienced radiologist, and evaluated esophageal lesions based on the size, location, extent and degree of invasion of adjacent structures. Lymph nodes were graded according to location and size (0-4mm, 5-9mm and 10 mm). To further narrow down these data, 0-4mm lymph nodes were classified as negative, 5-9mm lymph nodes classified as ambiguous, and lymph nodes 10 mm or larger classified as positive. In order to compare the pathological results with the CT images, we followed the previously described anatomical regions for positioning. According to visual inspection, possible metastases were recorded as no metastases, suspicious metastases or clear metastases. No metastases and suspicious metastases were classified as no metastases, and the size and location of the metastases were recorded.

The interval between CT examination and operation was 4 to 26 days, with an average of 12 days. The interval between PET/CT examination and surgery was 1 to 7 days, with an average of 4 days. The interval between CT and PET/CT examinations was 0–16 days, with an average of 5 days.

Accidental findings such as pleural effusion, lung or abdominal disease, or possibly other primary cancers have also been noticed.

Statistical analysis

The relation between the FAPI uptake and other parameters was determined using the analysis of variance method. A simple regression analysis was used to determine the relationship between FAPI uptake and tumor size and lymph node size. The chi-square test was used to compare the sensitivity, specificity, accuracy, positive predictive value, and negative predictive value of PET/CT and CT images, and the difference was statistically significant at $P < 0.05$.

Results

Primary Tumor

28 cases were squamous cell carcinoma and 1 case was adenocarcinoma. All primary lesions showed increased FAPI uptake (Fig. 1). The SUV and clinicopathological factors of FAPI uptake in 29 patients

were shown in Table 1. The longitudinal diameter of the primary lesion was about 5.07 ± 2.52cm, the SUVmax was about 14.2 ± 7.3, there was a positive correlation between the longitudinal diameter of the primary lesion and SUVmax of FAPI uptake (P = 0.01), and the TBR was about 11.6 ± 6.3. There was also a positive correlation between the size of the primary lesion and TBR (P = 0.007). As the depth of invasion increased, the uptake of FAPI was also increased (P = 0.002).

Table 1
FAPI uptake and clinicopathological characteristics of 29 cases of esophageal cancer

Parameter	No. of cases	FAPI uptake (SUV)(mean ± SD)	P value
Gender			
Male	26	14.7 ± 7.1	0.302
Female	3	10.1 ± 8.5	
Location			
Upper	3	14.8 ± 10.1	0.895
Middle	18	13.7 ± 7.4	
Lower	8	15.2 ± 6.7	
Tumor status			
T1	3	3.4 ± 0.1	0.002
T2	3	6.9 ± 3.7	
T3	20	16.5 ± 6.0	
T4	3	17.2 ± 7.6	
Lymph node status			
N0	14	14.4 ± 8.8	0.856
N1	10	14.2 ± 6.2	
N2	4	15.2 ± 5.2	
N3	1	7.9	
Pathologic stage			
I	3	3.4 ± 0.1	0.015
II	11	17.4 ± 7.4	
III	13	14.6 ± 5.9	
IV	2	10.6 ± 3.8	
Histologic grade			
G1	8	12.4 ± 8.3	0.581
G2	16	14.4 ± 7.2	
G3	5	16.8 ± 6.3	

Lymph Node Status

Surgical dissection of 637 lymph nodes, including 37 lymph nodes metastases. 27 lymph nodes metastases were positive on ^{68}Ga-FAPI PET/CT, and metastatic lymph nodes diameter was about 10 ± 5mm, SUVmax about 7.2 ± 5.2, and TBR was about 14.2 ± 10.1. There was a correlation between the SUVmax and lymph nodes diameter (P = 0.016). The sensitivity, specificity, accuracy, positive predictive value, and negative predictive value of PET/CT for lymph node metastasis detection were 71.1%, 99.4%, 97.8%, 90.0%, and 98.2%; The sensitivity, specificity, accuracy, positive predictive value, and negative predictive value of CT for lymph node metastasis detection were 36.8%, 98.9%, 95.3%, 70.0%, and 96.1%, respectively.

^{68}Ga-FAPI PET/CT imaging revealed that the smallest lymph node metastasis was 3mm. There were 11 lymph node metastases that were not found on ^{68}Ga-FAPI PET/CT scan, with an average size of 6.8mm (range 5-10mm), located at right supraclavicular (10mm), tracheobronchial (5 mm, 6 mm, 7mm), subcarinal (6 mm), paraesophageal (7 mm, 8 mm), left of gastric cardia (7 mm), left gastric artery (6 mm), hepatic gastric space (6 mm), and gastric curvature (6 mm); Only 1 lymph node corresponding CT showed positive, and the remaining 10 lymph nodes were also negative. ^{68}Ga-FAPI PET/CT reported 3 false-positive lymph nodes, including left lower trachea (7mm, SUVmax of 3.7), subcarinal (5mm, SUVmax of 3.7), and right left of gastric cardia (16mm, SUVmax of 6.7), and the difference between SUVmax of false positive lesions and lymph node metastasis was not statistically different (P = 0.415); Finally, pathologically confirmed that the esophagus cancer was associated with reflux esophagitis and lymph node inflammatory hyperplasia; the corresponding CT findings were 2 negative lymph nodes and 1 false positive lymph nodes.

Preoperative ^{68}Ga-FAPI PET/CT detected lymph node metastasis that CT failed to detect in 6 patients, and the preoperative staging was increased; 1 patient's preoperative staging was decreased due to negative uptake of ^{68}Ga-FAPI; ^{68}Ga-FAPI PET/CT was more accurate than CT in staging (7/29 cases).

Adverse events

All patients tolerated the ^{68}Ga-FAPI PET/CT examination well. There were no signs of drug-related pharmacological effects or physiological reactions.

Additional findings

4 patients had increased FAPI uptake of rib fracture with SUVmax of 5.4 ± 1.5; 2 patients with osteophytes (SUVmax of 4.0); 1 patient with nasal inverted papilloma (SUVmax5.8); 2 patients with shoulder arthritis (SUVmax8.9); 1 patient with thyroiditis (SUVmax4.5); 1 patient with pneumonia (SUVmax7.3).

Discussion

The main growth mode of esophageal cancer is local invasion and lymph node metastasis. Pre-treatment staging, especially lymph node staging, is an important basis for assisting clinicians in choosing reasonable treatment plans and evaluating prognosis. Anatomical images such as gastrointestinal barium meal, CT and transesophageal ultrasound are still commonly used staging methods in clinical practice, but the results of pathological verification are not ideal. There is evidence that ^{18}F-FDG PET/CT can improve the preoperative staging of esophageal cancer, with a sensitivity of 67%-74%, especially for the detection of non-regional lymphoid or blood-borne diseases [10]. Although these results may indicate the important role of ^{18}F-FDG, which is not a tumor-specific tracer, and false positive results may occur. For example, macrophages and neutrophils can show increased ^{18}F-FDG uptake, leading to false positive results. In addition, patients need to have an empty stomach and rest quietly before undergoing ^{18}F-FDG PET/CT examination.

In recent years, ^{68}Ga-FAPI, as a very promising tumor imaging agent, has shown good diagnostic performance for the detection of primary tumors and metastatic tumors. In this study, FAPI showed good detection ability for primary lesions (29/29). In addition, the sensitivity of ^{68}Ga-FAPI PET/CT for detecting lymph node metastasis is equivalent to that reported by previous researchers [4], but relatively low. One possible reason for these relatively low sensitivity values may be related to the inclusion criteria we used. In this study, only patients who underwent esophagectomy and lymph node dissection were included. Exclude patients receiving palliative care, preoperative chemotherapy or radiotherapy. Therefore, more cases of early disease and more patients with metastases under the microscope may be included in the current study. Our research shows that ^{68}Ga-FAPI PET/CT has higher sensitivity, specificity, accuracy, positive predictive value and negative predictive value for lymph node staging than CT.

In this study, 11 metastatic lymph nodes were false-negative in ^{68}Ga-FAPI PET/CT analysis. The reasons may be: (1) there are fewer tumor cells in the metastatic lymph nodes, resulting in less FAPI uptake; (2) the size of the metastatic lymph nodes is small, which is susceptible to the space limitation of PET and is affected by partial volume effects; (3) there is a large area in the metastatic lymph nodes necrosis. In CT scans, false negative results can be obtained, because metastasis may still occur in small or normal-sized lymph nodes; In addition, if there are inflammatory lymph nodes or lymph node swelling caused by granulomatous inflammation, false positive results can also be obtained. In this study, the smallest metastatic lymph node accurately detected by ^{68}Ga-FAPI PET/CT was 3 mm. In CT scans, metastatic lymph nodes are defined as lymph nodes larger than 1 cm. In view of this, we believe that ^{68}Ga-FAPI PET/CT is a more accurate diagnostic tool. In our study, a false positive result was found in 3 lymph nodes in patients with reflux esophagitis due to active inflammation. In addition, some studies have shown that benign lymph nodes may also have increased FAPI uptake, which needs to be differentiated from metastatic lymph nodes[11]. Nevertheless, due to the low incidence of false positive in PET imaging, we believe that it is accurate enough to be used as a basis for esophageal cancer treatment decisions. In view of the high specificity of ^{68}Ga-FAPI PET/CT, it also provides useful information for guiding the

choice of surgical methods. If a distant organ shows a positive result, there is no need to surgically remove the metastatic local lymph nodes.

Interestingly, in our study, increased FAPI uptake is also found in rib fractures, osteophytes, inverted papillomas, shoulder arthritis, thyroiditis, and pneumonia. These findings are consistent with some reported literature [12–19]. Therefore, further studies are needed to evaluate the diagnostic value of ^{68}Ga-FAPI PET/CT

Our research has limitations. First of all, the number of patients is relatively small (n = 29), and they are mainly squamous cell carcinoma and males. Therefore, due to the bias of patient distribution, the diagnostic performance of ^{68}Ga-FAPI PET/CT may be exaggerated. Prospective trials of larger patient populations are needed to further study the diagnostic effect of this diagnostic method. In addition, this study excluded patients with advanced esophageal cancer, the sensitivity and accuracy of the two methods for detecting lymph node metastasis may be underestimated. Moreover, the surgeon was instructed in preoperative CT and PET discovery. This fact may increase the verification bias. At the same time, since FAP immunohistochemistry has not been performed in histopathology, further analysis is needed for specific esophageal cancer FAP tissue quantification.

Conclusion

^{68}Ga-FAPI PET/CT can be used as a non-invasive diagnostic technique to assess tumor aggressiveness in patients with esophageal cancer. In the process of preoperative diagnosis, ^{68}Ga-FAPI PET/CT has higher sensitivity, specificity, accuracy, positive predictive value and negative predictive value for lymph node staging than CT.

Declarations

Funding: This study did not receive any funding.

Conflict of Interest: The authors declare that they have no conflicts of interest.

Informed consent and ethical approval: This prospective study has been approved by the Institutional Review Committee of our hospital (AHSWMU-2020-035) and registered in Chinese Clinical Trail Register (ChiCTR2100044131). All study participants provided informed consent.

References

1. Sung H, Ferlay J, Siegel RL, Laversanne M, Soerjomataram I, Jemal A, et al. Global Cancer Statistics 2020: GLOBOCAN Estimates of Incidence and Mortality Worldwide for 36 Cancers in 185 Countries. CA Cancer J Clin. 2021;71:209-49. doi:10.3322/caac.21660.
2. Kratochwil C, Flechsig P, Lindner T, Abderrahim L, Altmann A, Mier W, et al. (68)Ga-FAPI PET/CT: Tracer Uptake in 28 Different Kinds of Cancer. Journal of nuclear medicine : official publication,

Society of Nuclear Medicine. 2019;60:801-5. doi:10.2967/jnumed.119.227967.

3. Giesel FL, Kratochwil C, Lindner T, Marschalek MM, Loktev A, Lehnert W, et al. (68)Ga-FAPI PET/CT: Biodistribution and Preliminary Dosimetry Estimate of 2 DOTA-Containing FAP-Targeting Agents in Patients with Various Cancers. Journal of nuclear medicine : official publication, Society of Nuclear Medicine. 2019;60:386-92. doi:10.2967/jnumed.118.215913.
4. Chen H, Pang Y, Wu J, Zhao L, Hao B, Wu J, et al. Comparison of [(68)Ga]Ga-DOTA-FAPI-04 and [(18)F] FDG PET/CT for the diagnosis of primary and metastatic lesions in patients with various types of cancer. European journal of nuclear medicine and molecular imaging. 2020;47:1820-32. doi:10.1007/s00259-020-04769-z.
5. Ristau J, Giesel FL, Haefner MF, Staudinger F, Lindner T, Merkel A, et al. Impact of Primary Staging with Fibroblast Activation Protein Specific Enzyme Inhibitor (FAPI)-PET/CT on Radio-Oncologic Treatment Planning of Patients with Esophageal Cancer. Molecular imaging and biology : MIB : the official publication of the Academy of Molecular Imaging. 2020;22:1495-500. doi:10.1007/s11307-020-01548-y.
6. Zhao L, Chen S, Chen S, Pang Y, Dai Y, Hu S, et al. (68)Ga-fibroblast activation protein inhibitor PET/CT on gross tumour volume delineation for radiotherapy planning of oesophageal cancer. Radiotherapy and oncology : journal of the European Society for Therapeutic Radiology and Oncology. 2021;158:55-61. doi:10.1016/j.radonc.2021.02.015.
7. Zhao L, Chen S, Lin L, Sun L, Wu H, Lin Q, et al. [(68)Ga]Ga-DOTA-FAPI-04 improves tumor staging and monitors early response to chemoradiotherapy in a patient with esophageal cancer. European journal of nuclear medicine and molecular imaging. 2020;47:3188-9. doi:10.1007/s00259-020-04818-7.
8. Liu Q, Shi S, Xu X, Yu X, Song S. The superiority of [(68)Ga]-FAPI-04 over [(18)F]-FDG PET/CT in imaging metastatic esophageal squamous cell carcinoma. European journal of nuclear medicine and molecular imaging. 2021;48:1248-9. doi:10.1007/s00259-020-04997-3.
9. Zhou Y, Yang X, Liu H, Luo W, Liu H, Lv T, et al. Value of [(68)Ga]Ga-FAPI-04 imaging in the diagnosis of renal fibrosis. Eur J Nucl Med Mol Imaging. 2021. doi:10.1007/s00259-021-05343-x.
10. van Westreenen HL, Cobben DC, Jager PL, van Dullemen HM, Wesseling J, Elsinga PH, et al. Comparison of 18F-FLT PET and 18F-FDG PET in esophageal cancer. Journal of nuclear medicine : official publication, Society of Nuclear Medicine. 2005;46:400-4.
11. Gundogan C, Guzel Y, Can C, Alabalik U, Komek H. False-Positive 68Ga-Fibroblast Activation Protein-Specific Inhibitor Uptake of Benign Lymphoid Tissue in a Patient With Breast Cancer. Clin Nucl Med. 2021;46:e433-e5. doi:10.1097/RLU.0000000000003594.
12. Wu J, Liu H, Ou L, Jiang G, Zhang C. FAPI Uptake in a Vertebral Body Fracture in a Patient With Lung Cancer: A FAPI Imaging Pitfall. Clin Nucl Med. 2021;46:520-2. doi:10.1097/RLU.0000000000003560.
13. Liu H, Wang Y, Zhang W, Cai L, Chen Y. Elevated [(68)Ga]Ga-DOTA-FAPI-04 activity in degenerative osteophyte in a patient with lung cancer. Eur J Nucl Med Mol Imaging. 2021;48:1671-2. doi:10.1007/s00259-020-05090-5.

14. Liu H, Chen Z, Yang X, Fu W, Chen Y. Increased 68Ga-FAPI Uptake in Chronic Cholecystitis and Degenerative Osteophyte. Clin Nucl Med. 2021;46:601-2. doi:10.1097/RLU.0000000000003621.
15. Liu H, Yang X, Liu L, Lei L, Chen Y. Incidental Detection of Sinonasal Inverted Papilloma With 68Ga-FAPI PET/CT in a Patient With Esophageal Cancer. Clin Nucl Med. 2021. doi:10.1097/RLU.0000000000003733.
16. Zhou Y, He J, Chen Y. (68)Ga-FAPI PET/CT imaging in a patient with thyroiditis. Endocrine. 2021;73:485-6. doi:10.1007/s12020-021-02605-4.
17. Can C, Gundogan C, Guzel Y, Kaplan I, Komek H. 68Ga-FAPI Uptake of Thyroiditis in a Patient With Breast Cancer. Clin Nucl Med. 2021;46:683-5. doi:10.1097/RLU.0000000000003637.
18. Liu H, Yang X, Wang Y, Wang P, Chen Y. 68Ga-FAPI PET/CT Imaging of Graves Ophthalmopathy in a Patient With Esophageal Cancer. Clin Nucl Med. 2021. doi:10.1097/RLU.0000000000003703.
19. Liu H, Wang Y, Zhang W, Cai L, Chen Y. Elevated 68Ga-FAPI Activity in Splenic Hemangioma and Pneumonia. Clin Nucl Med. 2021;46:694-6. doi:10.1097/RLU.0000000000003638.

Figures

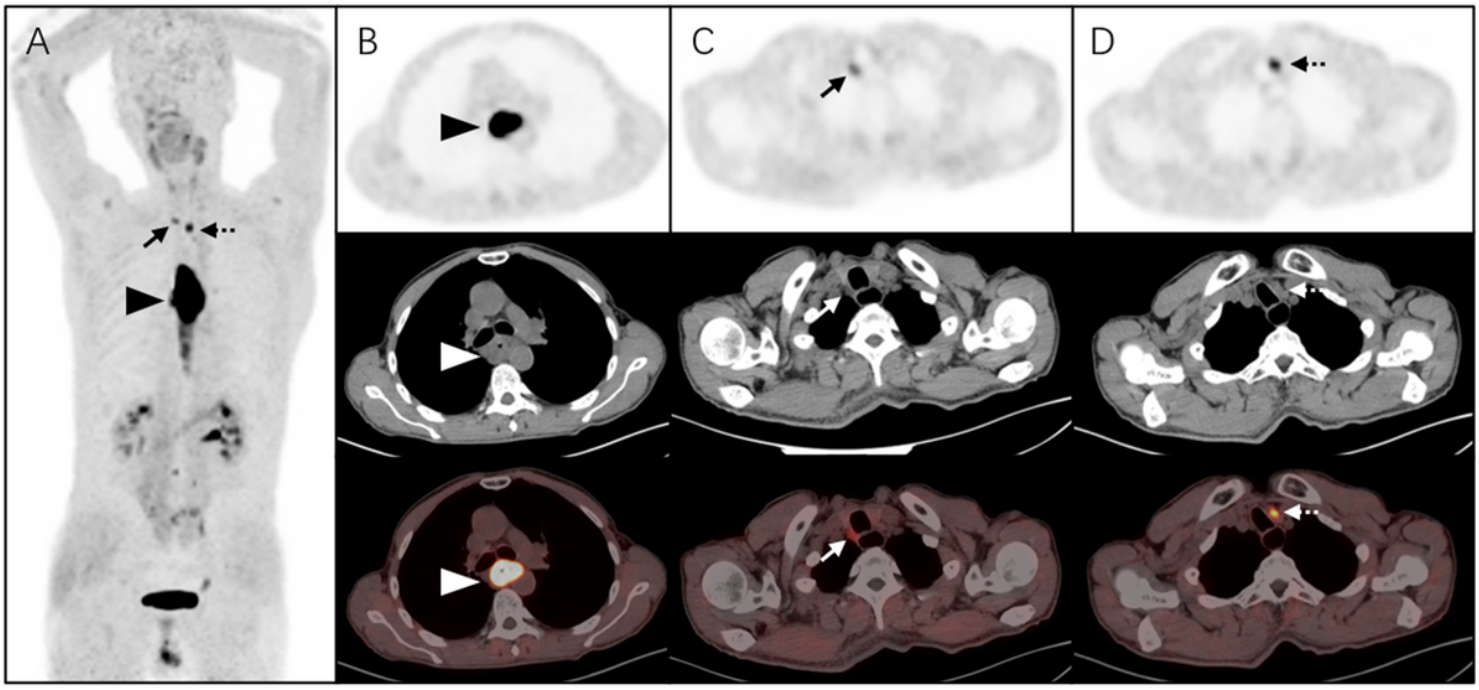

Figure 1

A 63-year-old male with mid-thoracic esophageal cancer. 68Ga-FAPI PET/CT (A, MIP) showed thickening of the middle thoracic tube wall of the esophagus, and esophageal stenosis (B); right upper paratracheal lymph node (C) showed increased FAPI uptake (long diameter 9mm, SUVmax 4.9); The upper left paratracheal lymph node (D) also showed increased FAPI uptake (long diameter 6mm, SUVmax 7.9); mediastinal window of CT scan did not show significant enlargement of mediastinal lymph nodes.

Pathological examination confirmed the middle thoracic esophageal cancer with lymph node metastasis (T4N1M0, G2, III, AJCC, 8th).