Research Square

Preprints are preliminary reports that have not undergone peer review. They should not be considered conclusive, used to inform clinical practice, or referenced by the media as validated information.

Effects of Shumu Decoction on Pathological Changes of Cornea in Patients with Diabetic Dry Eye

hua zhi han
Shaanxi Traditional Chinese Medicine Hospital
Wen-Juan Wei
Shaanxi Tradicine Chinese Medicine Hospital
Sheng-Jun Tuo
Yanan People's Hospital
Wu-Feng Zhang (hanzhihua200@sina.com)
Taizhou Fourth People Hospital

Research

Keywords: Diabetic dry eye, Shumu Decoction, Cornea

Posted Date: September 16th, 2020

DOI: https://doi.org/10.21203/rs.3.rs-72734/v1

License: This work is licensed under a Creative Commons Attribution 4.0 International License.
Read Full License

Abstract

BACKGROUND: To observe the pathological changes of cornea and to clarify the effect Shumu Decoction on the cornea in diabetic dry eye.

METHODS:The study assessed 200 eyes of 100 patients with diabetic dry eye.The treatment group 50 patients(100 eyes) and the control group 50 patients(100 eyes). The control group was treated with sodium hyaluronate eye drops. On the basis of the control group, the treatment group was treated by oral administration of Shumu Decoction.All participants underwent the examination of laser confocal microscope to obtain the image of cornea which were used to evaluate the differences between the two groups before and after treatment.

RESULTS:After treatment,The corneal epithelial cell density in the treatment group was significantly higher than that in the control group($P < 0.05$) .The cell area of the two groups increased compared with that before treatment, but the area in the control group was significantly larger than that in the treatment group ($P<0.05$).The number of Langerhans cells in the control group were significantly higher than that in the treatment group($P<0.05$).The morphology of Langerhans cells was characterized by large area and pseudopodia in the control group.The density, length of central corneal nerve fibers in the two groups were reduced compared to before treatment, but the decrease of nerve fiber in the control group was more obvious than that in the treatment group($P<0.05$), and the morphology of nerve fibers was obvious change in the control group($P<0.05$).At 4 weeks' treatment,the corneal endothelial cells showed morphological abnormality, there was significant difference in the ratio of endothelial cell hexagon between the two groups, and the corneal thickness increased significantly in the control group($P<0.05$).

CONCLUSION:Shumu Decoction can delay the loss of corneal cells and nerve fibers and restore the normal function of cornea.Those changes may alleviate the symptoms of patients with diabetic dry eye

Background

Diabetic dry eye is one of diabetic ocular surface disorders. Epidemiological study has found that about 50% of diabetes concomitant dry eye disease [1]. Various pathological changes of cornea caused by diabetes are the main causes of dry eye disease[2]. Persistent corneal epithelial defects cause many symptoms of dry eye disease, such as dryness, photophobia, foreign body sensation and so on.Decreased corneal sensitivity affect the production of reflexive tears and the stability of tear film.In addition, The amount of tear was significantly reduced in patients with diabetic dry eyes, but the patients had no obvious clinical feature of dry eye disease,which might be related to the changes in corneal structure and function caused by diabetes [3-4], indicating that the corneal abnormality closely associated with occurrence of diabetic dry eye.

Qi deficiency and yin deficiency are the main syndrome grouping of Traditional Chinese Medicine (TCM) of diabetic dry eye. Now treatment is mainly based on the method of nourishing qi and nourishing yin. Although this treatment could improve the clinical symptoms of diabetic dry eye,it was not clear how did

TCM play a role and how did TCM affect cornea.In this paper, the changes of cells and nerve fibers in cornea were observed by laser confocal microscopy and then the effects of Yiqi Yangyin Chinese medicine on the cornea were clarified.

Subjects And Methods

Ethical Approval

The study protocol was approved by the Ethics Committee of Shaanxi traditional Chinese medicine hospital and adhered to the tenets of the Declaration of Helsinki. Before the examination, we have got written informed consents from all subjects.

Subjects

In this study, 200 eyes of 100 patients with diabetic dry eye patients (56 males, 44 females; mean age 51.9 ± 9.5y) were evaluated in Shaanxi traditional Chinese medicine hospital during the period from January 2018 to December 2019. The mean duration of diabetes was 7.7±3.41y (range, 5-20y). The patients were those who meet the diagnostic criteria of type 2 diabetes and dry eye disease,and those who meet the diagnostic criteria of syndrome grouping of TCM of dry eye disease with deficiency of both qi and Yin,and those who have not used local drugs for eyes within one month before entering the group.Exclusion criteria included type 1 diabetes and monocular disease,allergy to research drugs, pregnant or lactating women,ocular and systemic diseases(conjunctivitis,keratitis, iris, lacrimal duct and other local eye diseases,SjÖgren's syndrome and rheumatoid arthritis).

Research methods

All participants were randomly divided into two groups: the treatment group 50 patients(100 eyes) and the control group 50 patients(100 eyes). The control group was treated with sodium hyaluronate eye drops: three times a day, one drop each time, for four weeks as a cycle of treatment. On the basis of the control group, the treatment group was treated by oral administration of Shumu Decoction(Yiqi Yangyin Chinese medicine).The prescription was:(Astragalus membranaceus 15g,Rehmannia glutinosa Libosch 12g,Dendrobium candidum 12g, Polygonatum sibiricum 15g, Paeonia lactiflora Pall 10g, Lycopus lucidus 12g, Astragali Complanati Semen 12g,Cuscuta chinensis Lam 12g, Cyperus rotundus Linn 9g). The raw medicine was provided by Shaanxi traditional Chinese medicine hospital.Taking method:the decoction was processed into a vacuum package by the Chinese pharmacy of the hospital. Each bag was 200ml, one bag a time,twice a day.

Before and 4 weeks after the treatment, the cornea of all participants were examined by laser confocal microscopy.

Laser Confocal Microscope Examination A

ll participants were examined by laser confocal microscope (Heidelberg company, Germany).The eye of participants were topically anesthetized with articaine eye drops (Alcon company, USA) for three times. The operator firstly droped Visdisc eye gel (Bausch & Lomb company, USA) on the surface of laser confocal microscope lens and then covered sterile corneal contact cap on microscope lens. The mandible and forehead of the participants were fixed on the Laser confocal microscope respectively. The participants were asked to look at the fixation lamp, The operator adjusted the position of the objective lens to make the contact cap contact with the central cornea slightly.The operator rotated the focal plane adjusting ring to obtain the image of each layer of cornea, and collected and saved the image. The number of nerve fibers was the total number of nerve fibers in one image. At least three images were analyzed and the average value was taken.

Statistical Analysis

The measurement data was expressed by mean ± standard deviation (), and analyzed by SPSS 22.0 statistical software. Before and after treatment, paired sample t test was used, and two independent samples t test was used. The difference was statistically significant ($P < 0.05$).

Results

1. Corneal epithelial cells and Langerhans cells

The corneal epithelial cell density in both groups decreased after treatment, but the cell density in the treatment group was significantly higher than that in the control group, with a significant difference ($P <0.05$) (Table 1).After treatment, the cell area of the two groups increased compared with that before treatment, but the area in the control group was significantly larger than that in the treatment group, and the difference was statistically significant ($P<0.05$) (Table 1).

Table 1

Comparison of cell density (cells / mm^{-2}) and surface cell area (μm^{-2}) of corneal epithelium in two groups

Group	Time	Superficial cell	Wing cells	Basal cell	Cell area
Control group	Base line	1197±101	4356±231	4532±352	536±88
	4 week	976±92	3756±420	3976±414	662±93
t	—	19.81	15.33	12.53	12.05
P	—	<0.001	<0.001	<0.001	<0.001
Treatment group	Base line	1207±142	4383±382	4507±233	531±84
	4 week	1176±92*	4151±192*	4379±37*	555±91*
t	—	2.16	6.50	3.57	2.37
P	—	0.03	<0.001	<0.001	0.01
*Compared with the control group, P<0.05					

After treatment,the number of Langerhans cells in the treatment group was not significantly increased, while the number of cells was significantly increased in the control group,the difference between the two groups was statistically significant (P<0.05).At the same time,The morphology of Langerhans cells were characterized by large area and pseudopodia (Table 2, Figure 1).

Table 2

Comparison of number of Langerhans cells (cells/mm^{-2}) and morphology of endothelial cells in the two groups

Group	Time	Langerhans	The ratio of hexagonal cell (%)
Control group	Base line	118±37	76.7±3.7
	4 week	152±18	60.9±3.4
t	—	10.12	18.51
P	—	<0.001	<0.001
Treatment group	Base line	116±25	77.1±3.0
	4 week	120±37*	73.7±3.7*
t	—	1.10	8.74
P	—	0.27	<0.001
*Compared with the control group, P<0.05			

2. Nerve fibers

After treatment, the density, length, and branch density of central corneal nerve fibers in the two groups were reduced compared to before treatment, but the density and length of nerve fibers in the treatment group were significantly higher than those in the control group, and the difference between the two groups was statistically significant.(P <0.05).

After treatment, The morphology of nerve fibers was not obvious change in the treatment group, while nerve fiber curvature in the control group increased significantly, and the difference between the two groups was statistically significant (Table 3).

Table 3
Comparison of the number of total nerve fiber and branch nerve fiber, the length of nerve fiber, and nerve curvature between the two groups

Group	Time	Total number（mm^{-2}）	Length（$mm \cdot mm^{-2}$）	Branch number（mm^{-2}）	Curvature
Control group	Base line	24.6±3.1	14.1±3.2	23.7±3.7	2.2±1.1
	4 week	18.1±5.7	9.2±3.6	17.7±3.6	2.8±1.2
t	—	12.27	12.46	14.23	4.51
P	—	<0.001	<0.001	<0.001	<0.001
Treatment group	Base line	25.7±3.7	14.4±2.9	24.3±3.6	2.1±1.0
	4 week	21.7±3.5*	11.1±3.2*	19.7±3.5*	2.4±1.1*
t	—	9.62	9.36	11.22	2.47
P	—	<0.001	<0.001	<0.001	<0.001
*Compared with the control group, P<0.05					

3. Corneal stroma

The corneal stroma is divided into five layers from the back to the front. After treatment, the cell density was(946±21/ $mm^2$and 1074±12 / mm^2 in 0% to 10% depth;849±12 / mm^2 and 939 ± 9 / mm^2 in

11%-33% depth)in two groups and the cell density was decreased significantly in the control group.The difference between the two groups was statistically significant (P <0.05).

There was no significant difference in the cell density of deep cornea between the two groups.

4. Corneal endothelial cells and corneal thickness

After treatment, corneal endothelial cells in the control group showed morphological changes, the cells lost normal regular hexagonal morphology and showed irregular morphology (cell polymorphism) (Table 4) (Figure 1),There was significant difference in the ratio of endothelial cell hexagon between the two groups.In addition, there was no significant change in the density of endothelial cells between the two groups.

After treatment, the corneal thickness increased significantly in the control group(564μm and 520μm,respectively), and the difference was statistically significant (P <0.05).

Discussion

At present, the treatment focused on improving clinical undesirable symptoms of dry eye disease rather than curing.Chinese medicine treatment had obvious advantages in restoring eye surface health, improving eye discomfort, protecting visual function, reducing the recurrence of dry eye disease.In our long-term clinical practice, combined with the clinical characteristics of diabetic dry eye and the experience of dialectical treatment, It was believed that the etiology and pathogenesis of diabetic dry eye, though varied and complicated, were always based on Qi deficiency and yin deficiency, with dry heat as its target.According to this understanding, we proposed the method of benefiting qi and nourishing Yin as the treatment principle for diabetic dry eye, and apply the herbs of nourishing qi and Yin such as Astragalus membranaceus, Rehmannia glutinosa Libosch, Dendrobium candidum,and Polygonatum sibiricum to the treatment of diabetic dry eye. In addition, Zhang analyzed the etiology and pathogenesis of diabetic dry eye, and thought that "deficiency of both Qi and Yin, stagnation of eye and meridians" were the main pathogenesis of diabetic dry eye [5].

In the condition of high blood glucose, the tactile threshold of cornea increased, the shape of nerve fiber became thin and the number of nerve fiber became decreased, the sensitivity of cornea and immune defense of ocular surface were decreased, corneal infection and corneal ulcer appeared, which eventually led to the disorder of ocular surface and induced the morbidity of dry eye disease [6].In addition, the decrease of corneal sensation caused by hyperglycemia reduced tear production. The decrease of corneal innervation was related to the abnormal tear film function and closely related to the severity of dry eye disease[7]. Therefore,cornea was the main tissue invaded by diabetic dry eye, and the clinical symptoms of dry eye disease could be further aggravated after keratopathy, forming a vicious circle between the two.

Diabetes led to a series of pathological changes in corneal epithelial cells,such as the cellular pleomorphism, irregular arrangement and reducing proliferation and decreasing cell density[8]. Our study found that after the treatment the number of epithelial cells mildly decreased compared with the control group, and the thickness of cornea was not obvious increased. These changes indicated that Shumu Decoction could not only improve the effect of hyperglycemia on the morphology and number of corneal epithelial cells, but also enhance the function of corneal epithelial barrier, significantly reduce corneal edema. Previous research found that the use of Yiqi Runmu Chinese medicine could protect cornea and conjunctiva from damage and restore the function of ocular surface barrier in hypertonic saline-induced dry eye mouse models,which was consistent with our findings [9].

In addition, we found that the density of Langerhans cells was significantly increased in the control group. The reason was that the persistent high blood glucose levels made the corneal tissue in the state of hypoxia, causing chronic inflammation of the cornea, and then stimulating the Langerhans cells as antigen presenting cells, and the Langerhans cells had the function of ingesting, processing and presenting antigens, which could cause a variety of inflammatory cells to participate in the ocular surface immune-inflammatory response, resulting in an increase in the density of Langerhans cells [10], while the number of Langerhans cells in the treatment group only slightly increased, indicating that Chinese medicine could improve the symptoms of dry eye increase caused by diabetes by inhibiting the inflammatory response in the cornea,restoring the normal function of cornea.It was found in the rats model of diabetic dry eye that Yiqi Shengjin Chinese medicine (Fuming Tablet) reduce the secretion of IL-6, TNF-a and IL-1β in the tears of rats and the expression of TGF-β1 in the cornea epithelium cell, thereby reducing the level of inflammatory factors on the ocular surface and improving the discomfort symptoms of eye [11].In accordance with our results, it was confirmed that Yiqi Yangyin Chinese medicine can restore the immune barrier of cornea by down-regulating the inflammatory level in cornea so as to achieve the purpose of curing diabetic dry eye.

Recent studies had shown that the density of corneal nerve fiber decreases in people with diabetes and progresses gradually with the duration of diabetes [12]. In this study, we found that in the control group, the number and the length of the nerve fibers were significantly reduced. In addition, the morphology was significantly changed, and the curvature was increased. The number, length and the shape of nerve fibers were significantly improved after oral administration of Shumu Decoction. It was speculated that damage of corneal epithelial cell integrity lead to morphological changes of nerve fibers which eventually lead to the decrease of the number of nerve fibers. After taking Chinese medicine, corneal integrity could be significantly restored, and the nerve fibers could be protected from the effects of hyperglycemia.Studies have confirmed that Yangyinshengjin Chinese medicine (Dendrobium officinale) could inhibit or correct abnormal changes in the activity of polyhydric alcohol dehydrogenase and aldose reductase in cells stimulated by a high glucose[13-14].At present, Dendrobium officinale had been made into eye drops for the treatment of keratoxerosis. The clinical and animal study confirmed that Dendrobium officinale can play a protective role in diabetic keratopathy by inhibiting aldose reductase activity and promoting the expression of laminin[15].This is consistent with our research results, which showed that the treatment of Supplementing Qi and nourishing Yin could obviously protect the corneal nerve fibers from high glucose,

restore corneal sensitivity,blink reflex and ocular surface homeostasis, and reduce the clinical bad symptoms of dry eye decrease.

Normal corneal endothelial cells have a hexagonal structure with almost unchanged cell shape and size.This structure maintains the surface tension and constancy of the cells. Once destroyed, it will affect the cell function. In this study, we found that the morphology of endothelial cells in the treatment group were not obvious change, while in the control group, the cell morphology changed obviously and lost normal hexagon,and the cell stability was destroyed. This change was related to aging, hypoxic injury (diabetes) and stress [16].Goldstein found that the morphology of endothelial cell was significant abnormality in both type 1 and type 2 diabetes, and a more significant deterioration in type 1 diabetes [17]. In this study, the morphology of endothelial cells in the treatment group was only slightly damaged, and the hexagon was well maintained, which indicated that the treatment of Supplementing Qi and nourishing Yin could protect corneal endothelial cells from the double damage of diabetes and dry eye disease, and restore the function of corneal inner barrier. The balance of fluid in corneal stroma is regulated by multiple tight junctions of endothelial cells and the action of Na^+/K^+ ATPase pump. In this study, we found that corneal thickness increase significantly in the control group.Considering that the internal barrier function of the cornea was destroyed to make the fluid in matrix unbalance[18].The function of mitochondria was destroyed, ATP production was decreased in corneal endothelial cells and epithelial cells,the permeability of endothelial cells was increased,these pathological changes destroyed the tight junction and Na^+/K^+ ATPase pump function and aggravated matrix edema[19].And these abnormal changes were related to the age of diabetic patients [20].The corneal thickness was significantly lower in the treatment group,indicating that the function of corneal internal and external barrier was slightly damaged by dry eye disease and hyperglycemia, and the discomfort was further alleviated and visual function were further improved.

Therefore, we concluded that Shumu Decoction(Yiqi Yangyin Chinese medicine) could alleviate the uncomfortable symptoms of patients with diabetic dry eye by delaying the loss of corneal cells and nerve fibers and restoring the normal function of cornea.

Conclusion

Shumu Decoction takes human as a whole, focuses on diabetic keratopathy, clarifies the protective mechanism of cornea, and clarifies the mechanism of Shumu Decoction in treating diabetic dry eye.

List Of Abbreviations

Traditional Chinese Medicine: TCM

Declarations

Ethics approval and consent to participate:

The study protocol was approved by the Ethics Committee of Shaanxi traditional Chinese medicine hospital and adhered to the tenets of the Declaration of Helsinki. Before the examination, we have got written informed consents from all subjects.

Consent to publish:

All authors agree to publish

Availability of data and materials:

All authors wish to share their data

Competing interests:

There is no conflict of interest

Funding:

There is no fund

Authors' Contributions:

Ms. Han is mainly responsible for writing paper, As a co first author, Ms. Wei is responsible for polishing the paper,Mr. Tuo is responsible for data analysis and statistics,Mr. Zhang is responsible for the design and ideas of the paper.

Acknowledgements:

First of all, I would like to give Professor Zhou Jian, my supervisor,who taught me the spirit of persistence and not giving up in my doctorate stage. Without her consistent and illuminating instruction, this paper could not have reached its present form. Secondly, I would like to thank my colleagues who collected clinical cases and pictures in time. I would like to thank director Zhang Wufeng for providing me with the article design and ideas. I would like to thank director Tuo Shengjun for helping me to complete the statistical content of the whole article. Last but not least, I would like to thank my hospital leaders, teachers and staff. Without their help, this paper would be much more difficult.

References

1. Zhang X, Zhao L ,Deng S, Sun X,Wang N.Dry Eye Syndrome in Patients with Diabetes Mellitus: Prevalence, Etiology, and Clinical Characteristics[J].J Ophthalmol,2016, 016:8201053.
2. Wang S,Jia Y,Li T,Wang A,Gao L,Yang C,Zou H.Dry Eye Disease Is More Prevalent in Children with Diabetes than in Those without Diabetes[J].Curr Eye Res,2019,44(12):1299-1305
3. Bikbova G,Oshitari T,Baba T,Yamamoto S.Neuronal Changes in the Diabetic Cornea: Perspectives for Neuroprotection[J]. Biomed Res Int, 2016, 2016:5140823.
4. Petropoulos IN, Ferdousi M, Marshal A,Alam U,Ponirakis G,Azmi S,Fadavi H, Efron N,Tavakoli M,Malik RA.The inferior whorl for detecting diabetic peripheral neuropathy using cornea l confocal microscopy[J].Invest Ophthalmol Vis Sci ,2015,56 (4) :2498–2504.
5. Zhang WQ, Yan J, Li J. Preliminary study on the theory of nourishing qi, nourishing yin and activating blood to treat dry eye of diabetes[J].China Journal of Ophthalmology, 017,27(5): 308-310
6. Pritchard N, Edwards K, Russell AW, Perkins BA,Malik RA,Efron N. Corneal confocal microscopy predicts 4-year incident peripheral neuropathy in type1 diabetes[J]. Diabetes Care,2015,38(4):671-675.
7. Han SB,Yang HK,Hyon,JY.Influence of diabetes mellitus on anterior segment of the eye[J].Clin Inter Aging,2018,14:53-63
8. O'Donnell C, Efron N. Diabetes and contact lens wear[J]. Clin Exp Optom, 2012,95(3):328-337.
9. Zhang Y, Kang ZF, Liu J,Liu YJ. Effect of Yiqi Runmu Decoction on the expression of IL-1β and P-JNK in ocular surface tissue of dry eye mice [J]. China Journal of Traditional Chinese Ophthalmology, 2018,28(1):17-21
10. Liu R, Li B, Sheng MJ. Application of in-vivo confocal microscope in morphological observation of ocular surface of SjÖgren's syndrome [J]. Int J Ophthalmol, 2016,16(12):2213-2216
11. Huang SQ, Liu X, Hu T,Yang SS. Study on the improvement of corneal function and tear inflammation in diabetic dry eye rats by Fuming tablets[J].Evaluation and analysis of drug use in Chinese hospitals, 2019,19(6):666-669
12. Bikbova G,Oshitari T,Baba T,Bikbov M,Yamamoto S.Diabetic corneal neuropathy: clinical perspectives[J]. Clin Ophthalmol, 2018,12:981-987.
13. Li Y, Zhao YP,Chen PY,Jiang SY,Yu WL.The Scavenging Oxygen Free-radical Effects of Water Extract from Five Kinds of Dendrobium candidum[J].Chin Tradit Herb Drugs, 2004,35(11):1240-1242.
14. Li JW, Li CX, Chen GL.Application prospect of Dendrobium polysaccharides in diabetic retinopathy [J].Journal of Liaoning University of Traditional Chinese Medicine, 2015,17(9): 114-116.
15. Liu PA,He Q,Li SX, Xie Y,Chen GY,Cai GX.Study on the preparation process of Dendrobium officinale eye drops [J]. Chinese Medicine Division, 2016,19(1):73-77.
16. Eghrari AO, Riazuddin SA, Gottsch JD. Overview of the Cornea: Structure, Function,and Development[J]. Prog Mol Biol Transl Sci. 2015,134:7-23.

17. Goldstein AS,Janson BJ,Skeie JM,Ling JJ, Greiner MA.The Effects of Diabetes Mellitus on the Corneal Endothelium: A Review[J].Surv Ophthalmol 2020,pii: S0039-6257(20)30005-9.
18. Mahelkova G,Jirsova K,Seidler Stangova P,Palos M, Vesela V, Fales I, Jiraskova N, Dotrelova D.Using corneal confocal microscopy to track changes in the corneal layers of dry eye patients after autologous serum treatment[J].Clin Exp Optom,2017,100(3):243-249.
19. Shih KC, Lam KS, Tong L.A systematic review on the impact of diabetes mellitus on the ocular surface[J]. Nutr Diabetes. 2017,7(3):e251.
20. Fernandes SI,Nagpal S.Corneal thickness and endothelial cell density in children with type 1 diabetes mellitus[J].Oman J Ophthalmol.2019,12(3):186-190

Figures

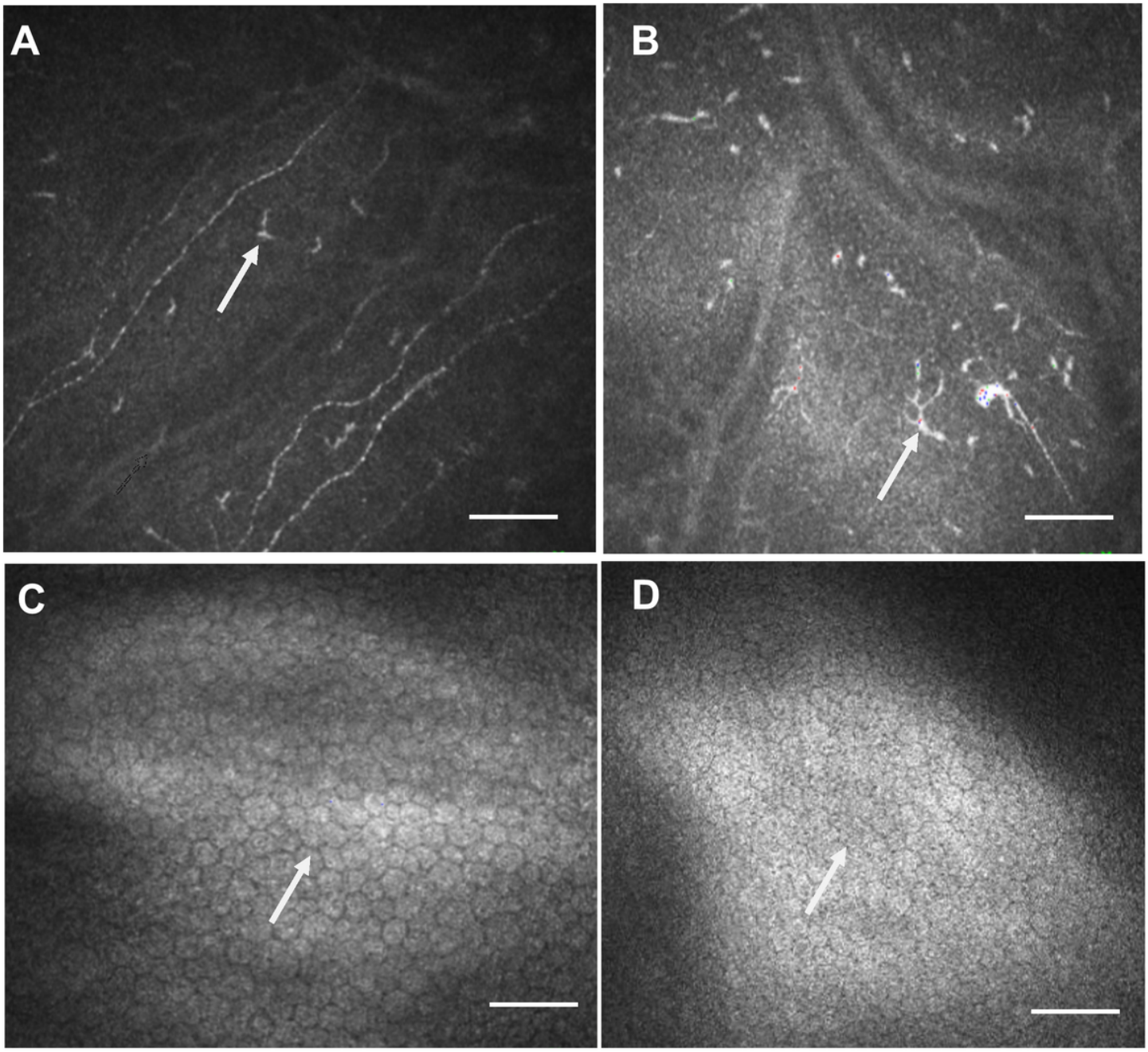

Figure 1

Comparison of morphology of Langerhans cells and endothelial cells between two groups after treatment(×800). A: Langerhans cells were small in size and some of them were dendritic in treatment group. B: Langerhans cells were larger in area,Most of them appeared to be dendritic,and had pseudopods in the control group. C The endothelial cells were regular and the morphology of endothelial cells was hexagonal in treatment group. D The area of endothelial cells was increased, the morphology of endothelial cells lost normal hexagon, and showed pleomorphic changes in the control group.