Clinical Application of a Modified Local Transposition Flap Surgery in Repairing Fingertip Defects

YingKai Zhang (592644257@qq.com)
Shengjing Hospital of China Medical University https://orcid.org/0000-0002-6157-306X

Yao Wang
Jinshan Hospital of Fudan University

Rongbo Wu
Jinshan Hospital of Fudan University

Jiaqi Zhou
Jinshan Hospital of Fudan University

Mingdong Zhao
Jinshan Hospital of Fudan University

Research article

Keywords: Fingertip, Local Flaps, Defect , Coverage

Posted Date: August 9th, 2021

DOI: https://doi.org/10.21203/rs.3.rs-729156/v1

Abstract

Purpose: A modified local transposition flap surgery was performed for fingertip injuries. Given the shape of the flap turnover resembling a parallelogram, we called it a parallelogram flap. This transposition flap surgery allows a more significant transfer distance with good outcomes.

Method: The study collected patients who underwent parallelogram transposition flaps to repair fingertip defects from 2017 to 2020. 32 cases (32 fingers) were included in our study, including 20 males and 12 females, aged 17 to 60 years, with an average age of 36 years. The causes of injury were crush injury in 13 cases, punch injury in 11 cases and sharp cutting injury in 8 cases. There were 6 cases in thumbs, 6 cases in index fingers, 14 cases in middle fingers, 4 cases in ring fingers and 2 cases in little fingers. The area of fingertip defects was 1.2 cm × 2~3 cm × 4 cm, with bone exposure. The interval between the injury and operation was 5.78 h (the mean value was 4.7-8.4 h). All operations were performed by one surgical team, and the average operation time was 31.2 min.Record The length and width of the finger two-point discrimination 2PD Total Active Movement (TAM)and the MHQ (Michigan Hand Questionnaire) of the injured fingers to evaluate the therapeutic effect.

Results: all our parallelogram flaps had survived postoperatively. At last follow-up,There was no difference between the length and width of the reconstructed finger and that of the healthy side P>0.05. The qualification rate of the static 2PD of the flaps were 84.37% .The qualification rate of the TAM of injured figures were 100% . Evaluation of the MHQ subscale performance showed that the score of the overall hand function is 93.71, activities of daily living is 95.22, work performance is 94.23,pain score is 4.34 , aesthetics is 92.15 and satisfaction score is 92.45.All of these were perform well.

Conclusion: This transposition flap surgery allows a more significant transfer distance with good outcomes.

1. Introduction

Finger injury is common in our daily life [1]. However, severe injuries may result in skin and soft tissue defects with the exposure of bone, joint, tendon, blood vessels and nerve, leading to disfigurement and impairment of finger function. Several approaches to repairing injured fingers are being practiced [2]. It is generally believed that amputation with sutured closure of the wound may be the most effective treatment, but patients are usually discontented due to the deficiencies of appearance and function [3]. The application of an abdominal flap allows possible rescue of injured fingers [4, 5]. However, the abdominal flap belongs to the distal flap and has several shortcomings, such as requiring multi-stage surgeries, poor wear resistance, swollen appearance, poor sense of touch, and requiring hand attachment to another part of the body for up to 3 weeks [6, 7]. With the development of flap technology and microsurgery, regional pedicled flap and free flap have become a popular choice in managing injured fingers but again, they are not without drawbacks. While local flaps, such as the V-Y flaps have the advantages of having similar texture and sensation to the defect area, their applicability is limited when

the defect area is large that the wound cannot be covered [8, 9]. In this instance, compared with local flaps, free flaps are superior in facilitating the movement of tissues and restore the aesthetic effect in a single stage [10], but the operation and postoperative care are complex and unfortunately, flap failure is not uncommon. Here, we described a novel transposition flap surgery, which we named the parallelogram transposition flap for fingertip defects and the clinical outcomes were reviewed. With this technique, the length of the fingers was retained while allowing a more significant transfer area than the V-Y flap. Moreover, the aesthetic and function of fingers were preserved. Our study collected 32 cases with fingertip defects repaired by parallelogram transposition flap from 2017 to 2020 that showed sound therapeutic effects.

2. Methodology

2.1 Patients

Patients undergoing parallelogram transposition flaps to repair fingertip defects from 2017 to 2020 were included in our analyses. Patients deemed suitable for this procedure would satisfy the following inclusion criteria: (1) single fingertip injury of one hand; (2) local soft tissue defects and phalangeal bone exposure without skin flap transplantation; (3) the injured finger had not been longer than 10 hours with light contamination of the wound; (4) the patient agreed to participate at the 4-month follow-up.

2.2. Operative method

2.2.1 Wound treatment

All operations were performed by one surgical team. Firstly, the patient was given nerve block anesthesia at the root of the injured finger. A gauze was then placed at the root of the finger and tightened with a rubber band to minimize bleeding. Thorough debridement and hemostasis were performed to the wounded finger. With a partial defect of the phalange, the remnant of the phalange was repaired and the bone structure was polished. The exposed nerve stump was incised with a sharp knife so that the severed end would retract naturally into the normal soft tissue.

2.2.2 Harvesting of skin flap

According to the size of the defect, the flap was designed on the side with more residual skin (Fig. 1). A longitudinal incision was made along the bone surface on both sides of the fingertip and the incised position should not exceed the transverse striation of the distal interphalangeal joint. Then, the skin and subcutaneous tissue were incised along the edge of the skin, and the skin flap was dissected sharply within the subcutaneous fascia, avoiding injury to the proper digital artery and nerve. A transverse incision was made on the side with more remaining skin to provide sufficient angle for flap turnover. Once freed, the designed flap was flipped over. Given its shape resembling a parallelogram, we named the flap a parallelogram flap. The longest hypotenuse c should be longer than the longitudinal length a + the width of defect b (Fig. 2), which was sufficient to cover the defective area. After the flap was flipped over,

a piece of skin graft A was left on the opposite side. The constructed skin graft A could be used to repair the transferred skin defect B.

2.3 Postoperative management

Postoperatively, antibiotics were given intravenously to reduce the risk of infection, in addition to lamp baking heat preservation and other symptomatic treatment. Moreover, patients received regular dressing changes and were advised to bed rest, elevate the affected limb, stop smoking, keep warm, and regularly observe the perfusion of the skin flap.

2.4 Follow-up

2.4.1 In the follow-up, the length of the reconstructed finger and the width of the distal finger were measured. Meanwhile, the length of the healthy side of the finger and the width of the distal finger were measured for comparison.

2.4.2 The Total Active Movement (TAM) of the injured fingers was measured using a standard hand goniometer, which was compared to that on the healthy side finger.The system sums the degrees of active flexion at the interphalangeal joints and metacarpophalangeal joint and subtracts the degrees of the extension deficits (100% for excellent; > 75% for good; > 50% for fair; < 50% for poor)

2.4.3 The sensibility of the palmar part of the flaps was measured using static two-point discrimination (2PD). The modfied American Society for Surgery of the Hand guidelines were used to classify the 2PD (< 6 mm for excellent; 6–10 mm for good; 11– 15 mm for fair; > 15 mm for poor).

2.4.4 The MHQ (Michigan Hand Questionnaire) was used to subjectively evaluate outcomes of the repaired hands. The MHQ includes 6 subscales (overall hand function, activities of daily living, pain, work performance, aesthetics, and satisfaction).

3. Results

A total of 32 patients (32 fingers) undergoing parallelogram flap surgery from 2017 to 2020 and were included in our analyses. Of these, 20 were males and 12 were females, aged 17 to 60 years and with a mean age of 36 years. The nature of the finger injuries included crush injury (n = 13), punch injury (n = 11) and sharp cutting injury (n = 8). Of the finger injuries, 6 were at the thumbs and index fingers respectively, 14 at the middle fingers, 4 at the ring fingers and 2 at the little fingers. The area of fingertip defects measured 1.2 cm × 2 ~ 3 cm × 4 cm, with bone exposure. The interval between the injury occurrence and the operation was 5.78 h (mean = 4.7–8.4 h), while the average time taken for surgery was 31.2 min. All parallelogram flaps had survived postoperatively.The characteristics of the study samples are detailed in Table 1. At last follow-up,There was no difference between the length and width of the reconstructed finger and that of the healthy side($P > 0.05$) the frequency distributions of the static 2PD of the flaps were presented in Fig. 2, and the 2PD of the palmar part of the flaps and the TAM of injured figures are detailed in Table 2. Evaluation of the MHQ subscale performance showed that the overall hand function, activities of daily living, work performance,pain score, aesthetics and satisfaction score perform well.

Table 1
Characteristics of the sample.

Characteristics of the sample.	
Age (year)	40 SD(8.35) range 17–60)
Gender (n)	
Male	20
Female	12
Cause of injury (n)	
Twisting	13
Crushing	11
Cutting	8
Finger type (n)	
Thumb	6
Index fingers	6
Middle fingers	14
Ring fingers	4
Little fingers	2
Interval between injury and operation (h)	5.78h(range 4.7 ~ 8.4 h)
Operation duration (min)	31.2min
Follow-up time (month)	4–6

Table 2
The length and width of the finger

	the reconstructed finger	**the healthy finger**	**Value P**
length	8.369	8.234	0.208
width	1.497	1.434	0.328

Table 3
Clinical examination.

	2PD of the palmar part of the flap	TAM of the injured finger (n)
Excellent	5	27
Good	22	5
Fair	5	0
Poor	0	0

Table 4
Michigan Hand Outcomes Questionnaire (MHQ).

Domain	value
Overall hand function	93.71 (SD 3.51)
Activities of daily living	95.22 (SD 2.23)
Work performance	94.23 (SD 3.21)
Pain	4.34 (SD 4.01)
Aesthetics	92.15 (SD 7.16)
Satisfaction	92.45 (SD 5.61)
Summary scores	94.29 (SD 3.14)

4. Discussion

Fingertip injury represents the most common injury of the hand [11], which is defined as a distal injury of the flexor digital tendon and extensor tendon insertion [12]. In the management of a fingertip injury, although it is essential to maintain the length, preserve the nail and the appearance, the main goal of treatment is to ensure the durability of the fingertip and painless at the skin. Therefore, the treatment must be individualized based on several patient-related factors and unique trauma characteristics [13].

For those injured fingers with bone exposure and local soft tissue defects, stump revision (i.e., phalangeal shortening and direct suture) is the simplest and fastest way to recovery, which can be performed under local anesthesia in the emergency room [2]. However, this operation shortens the phalange and adversely affects the appearance and function of the affected finger. With the advancement of medical technology, stump revision is no longer a common approach to manage tissue defects [3]. Compared with stump revision,, given that our method demonstrated a similar length of operative time and difficulty while retaining the length and function of the affected finger.

At present, the “V-Y” advancement flap [14] is widely performed in the management of fingertip injuries. “V-Y” flap is best used for transverse or anticlinal fingertip amputation and is suitable for injury to any finger. The contraindications of applying this flap include oblique metacarpal fingertip amputation and extensive palmar soft tissue defects. The edge of the wound is at the bottom of a distal triangle of the flap, and the apex of the flap can be extended to the transverse striation of the distal interphalangeal joint. During the operation, the skin and subcutaneous tissues should be incised first, including the fiber septum, and injury to the neurovascular bundle should be avoided. The flap can be advanced 1 cm to the distal end and form a "Y" shape repair. With this method, the maximum advancement distance of the skin flap is limited to 3–4 mm [15] and the skin flap area provided are often inadequate. Moreover, the incision of this operation is made at the finger pulp and the postoperative scar is located at the middle of the finger pulp, which may affect the sensory function. On the other hand, the most widely used transfer flap, the “V-Y” flap is widely used, but its shortcomings still need to be further improved. The parallelogram transfer method allows a longer transfer distance of the transposition flap. In our practice, the residual skin was trimmed and flipped over. The transverse width of the flap was abandoned and the longitudinal length of the flap was obtained. The defects were evenly distributed on each side of the parallelogram to achieve sufficient transfer distance to cover the exposed bone and tissues.

This article provided a detailed description of a modified flap for the surgical management of fingertip defects. The transfer flap was incised closely to the bone surface of the distal phalanx, and the interphalangeal artery was not damaged during stripping [16, 17], which is key to flap survival. Venous outflow is maintained by venules and capillaries in the perivascular adipose tissues through a retrograde fashion [18]. Therefore, if the interphalangeal artery is well protected during the flap design, the flap survival can be assured more confidently, as evidenced in our analyses that all our parallelogram flaps had survived postoperatively.

The reconstructive surgery for fingertip injury aims to obtain stable tissue coverage, achieve acceptable appearance, restore sensitivity, maintain finger length and resume normal physical activity promptly[19]. After a careful preoperative design of the parallelogram flap, postoperative skin flap contracture is less likely to occur, given that the turning over of the flap provides more coverage area than the “V-Y” flap. Furthermore, the incision of the parallelogram flap is distributed at both sides of the fingertip, and therefore the scar is at the sides of the finger. In this way, we abandon the finger’s width and retain the length, successfully achieving the purpose of the operation.

The practice of sensory or non-sensory reconstruction of fingers remains controversial and debatable among hand surgeons. Studies have reported an average of 10 mm in the static two-point discrimination test when a "senseless" reverse digital artery island flap has been performed[20, 21]. Conversely, other studies have demonstrated a normal static two-point discrimination test (1-5mm) following neurovascular island flaps [22, 23]. The findings of these studies indicate a reduced ability of flaps to restore sensation in the absence of nerve connections [24–26]. By performing free flap surgery, the digital nerve can usually be preserved. We demonstrated that our operative method provided a good sensory reconstruction of fingers, leading to satisfactory recovery in the finger movement, strength, etc.

There were limitations to our parallelogram flap. In particular, this flap would not be applicable when there were multiple skin defects at the donor site, or the required transfer distance was more than 6-7mm. In this instance, the skin flap adjacent to the finger or a reverse-flow island flap can be considered. Though the outcomes of our parallelogram flaps appeared encouraging, the results were limited by the absence of comparative analysis with other surgical methods.

In conclusion, for the fingertip injuries requiring less than 7 mm in the transfer distance, the parallelogram flap we have proposed results in favorable outcomes, including a high flap survival rate, acceptable appearance and optimal function of fingers.

Declarations

Acknowledgement

The authors would like to thank Shandong weigao orthopaedic device company for contribution on FEM analysis and the 3D printing technology.

Funding

This study was funded by Jinshan Hospital of Fudan University(No.JYQN-LC-202107)

Author information

Yingkai Zhang and Yao Wang contributed equally to this work.

Affiliations

Department of Orthopaedic Surgery, Jinshan Hospital of Fudan University,

Shanghai City, P.R. China, 201508

Yingkai Zhang, Yao Wang, Mingdong Zhao, Rongbo Wu.

Contributions

Yingkai Zhang and Yao Wang involved in making the conception and design of research and carried out drafing of the article. Mingdong Zhao performed the interpretation of data. Jiaqi Zhou carried out the acquisition of data and made a final approval and guarantor of the manuscript. Rongbo Wu participated

in making the conception and design of the study, carried out the acquisition of data and made a final approval and guarantor of the manuscript. All authors read and approved the final manuscript.

Corresponding author

Correspondence to Rongbo Wu and Jiaqi Zhou.

Ethics declarations

Ethics approval and consent to participate

Retrospective clinical study was approved by Jinshan Hospital of Fudan University's institutional review board (JIEC 2021-S21-01) Registered 03 February 2021,

https://61.49.19.26/research/researchInfo?id=510d3835-5e26-4c5b-966d-84af87eee73b

Consent for publication

Not applicable

Competing interests

The authors declare that they have no competing interests.

References

1. Abbase EA, Tadjalli HE, Shenaq SM. Fingertip and nail bed injuries. Postgrad Med. 1995;98(5):217–36.
2. Tang JB, Elliot D, Adani R, Saint-Cyr M, Stang F. Repair and reconstruction of thumb and fingertip injuries: a global view. Clin Plast Surg. 2014;41(3):325 – 59.
3. Holm A, Zachariae L. Fingertip lesions. An evaluation of conservative treatment versus free skin grafting. Acta Orthop Scand. 1974;45(3):382 – 92.
4. Kleinman WB, Dustman JA. Preservation of function following complete degloving injuries to the hand: use of simultaneous groin flap, random abdominal flap, and partial-thickness skin graft. J Hand Surg Am. 1981;6(1):82 – 9.
5. **BEVIN AG, CHASE RA**. THE MANAGEMENT OF RING AVULSION INJURIES, **AND ASSOCIATED CONDITIONS IN THE HAND**. Plast Reconstr Surg. 1963. 32: 391–400.

6. Giessler GA, Erdmann D, Germann G. **Soft tissue coverage in devastating hand injuries**. **Hand Clin**. 2003. **19** (**1**): **63–71**, **vi**.
7. Buja Z, Arifi H, Hoxha E. Repair of degloving fingers with abdominal tunnelization flap. J Hand Surg Eur Vol. 2013;38(4):439 – 40.
8. Bogov A, Mullin R, Kubitskiy A. The double flap partial reconstruction technique for the avulsion-type finger injuries: a case report. J Hand Surg Eur Vol. 2011;36(5):423-5.
9. Santos T, Oliveira MT, Angelini LC. Retrospective study to evaluate the treatment of digital pulp lesions using a homodigital flap. Rev Bras Ortop. 2018;53(2):200–7.
10. Bashir MM, Sohail M, Shami HB. Traumatic Wounds of the Upper Extremity: Coverage Strategies. Hand Clin. 2018;34(1):61–74.
11. Patel L. **Management of simple nail bed lacerations and subungual hematomas in the emergency department**. **Pediatr Emerg Care**. 2014. **30** (**10**): **742-5**; **quiz 746-8**.
12. Hawken JB, Giladi AM. Primary Management of Nail Bed and Fingertip Injuries in the Emergency Department. Hand Clin. 2021;37(1):1–10.
13. Hao R, Wang B, Wang H, Yang H, Huo Y. Repair of distal thumb degloving injury using combination of reverse dorsoradial flap of the thumb and middle finger proper digital arterial island flap. J Orthop Surg Res. 2020;15(1):417.
14. Atasoy E, Ioakimidis E, Kasdan ML, Kutz JE, Kleinert HE. Reconstruction of the amputated fingertip with a triangular volar flap. A new surgical procedure. J Bone Joint Surg Am. 1970;52(5):921-6.
15. Lee DH, Mignemi ME, Crosby SN. Fingertip injuries: an update on management. J Am Acad Orthop Surg. 2013;21(12):756 – 66.
16. Braga-Silva J, Kuyven CR, Fallopa F, Albertoni W. An anatomical study of the dorsal cutaneous branches of the digital arteries. J Hand Surg Br. 2002;27(6):577-9.
17. Takeishi M, Shinoda A, Sugiyama A, Ui K. Innervated reverse dorsal digital island flap for fingertip reconstruction. J Hand Surg Am. 2006;31(7):1094-9.
18. Lucas GL. The pattern of venous drainage of the digits. J Hand Surg Am. 1984;9(3):448 – 50.
19. Germann G, Rudolf KD, Levin SL, Hrabowski M. Fingertip and Thumb Tip Wounds: Changing Algorithms for Sensation, Aesthetics, and Function. J Hand Surg Am. 2017;42(4):274–84.
20. Yildirim S, Avci G, Akan M, Aköz T. Complications of the reverse homodigital island flap in fingertip reconstruction. Ann Plast Surg. 2002;48(6):586 – 92.
21. Zhang JF, Wang L, Hao RZ, Huo YX, Yang HY, Hu YC. Treatment of fingertip avulsion injuries using two periposition pedicled flaps. J Plast Reconstr Aesthet Surg. 2019;72(4):628–35.
22. Storvik HM. The extended neurovascular island flap in thum reconstruction. Scand J Plast Reconstr Surg. 1973;7(2):147-9.
23. **HUESTON J. THE EXTENDED NEUROVASCULAR ISLAND FLAP**. Br J Plast Surg. 1965;18:304-5.
24. Kleinert HE, McAlister CG, MacDonald CJ, Kutz JE. A critical evaluation of cross finger flaps. J Trauma. 1974;14(9):756 – 63.

25. Johnson RK, Iverson RE. Cross-finger pedicle flaps in the hand. J Bone Joint Surg Am. 1971;53(5):913-9.
26. Hammouda AA, El-Khatib HA, Al-Hetmi T. Extended step-advancement flap for avulsed amputated fingertip–a new technique to preserve finger length: case series. J Hand Surg Am. 2011;36(1):129 –34.

Figures

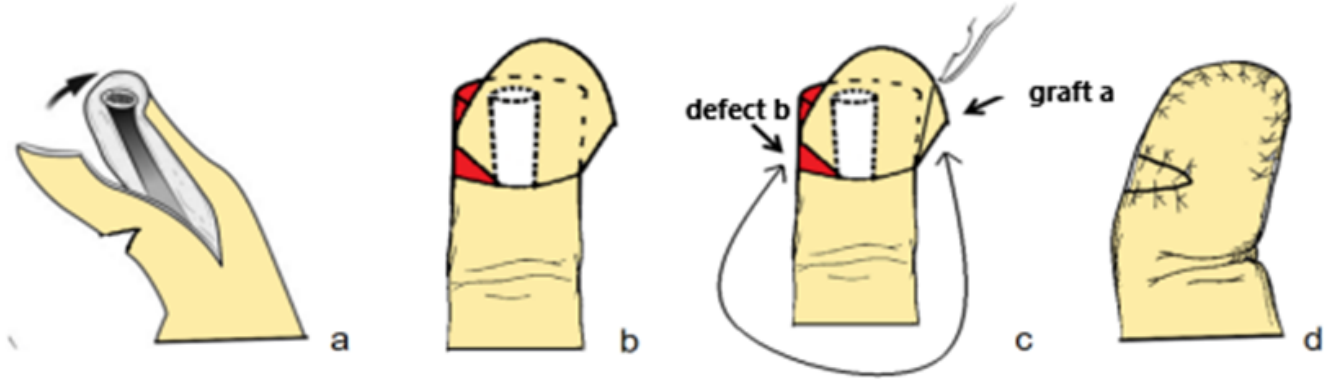

Figure 1

(a-c) Surgical steps of the parallelogram flap (B) The parallelogram flap reconstruction and skin grafts are completed.

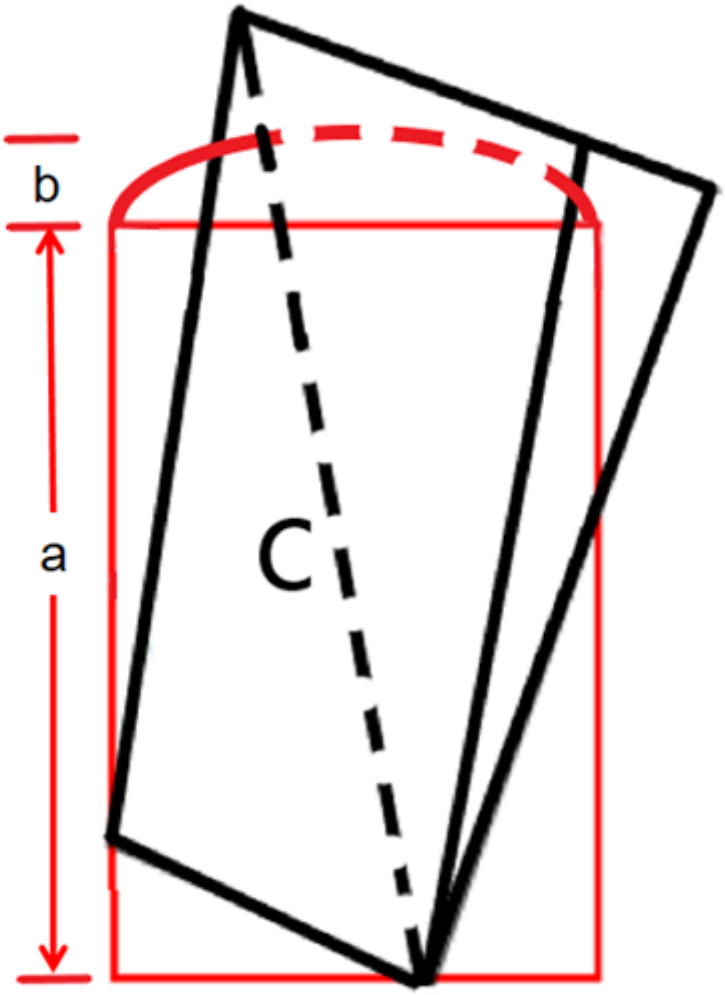

Figure 2

Schematic drawing of the parallelogram flap.

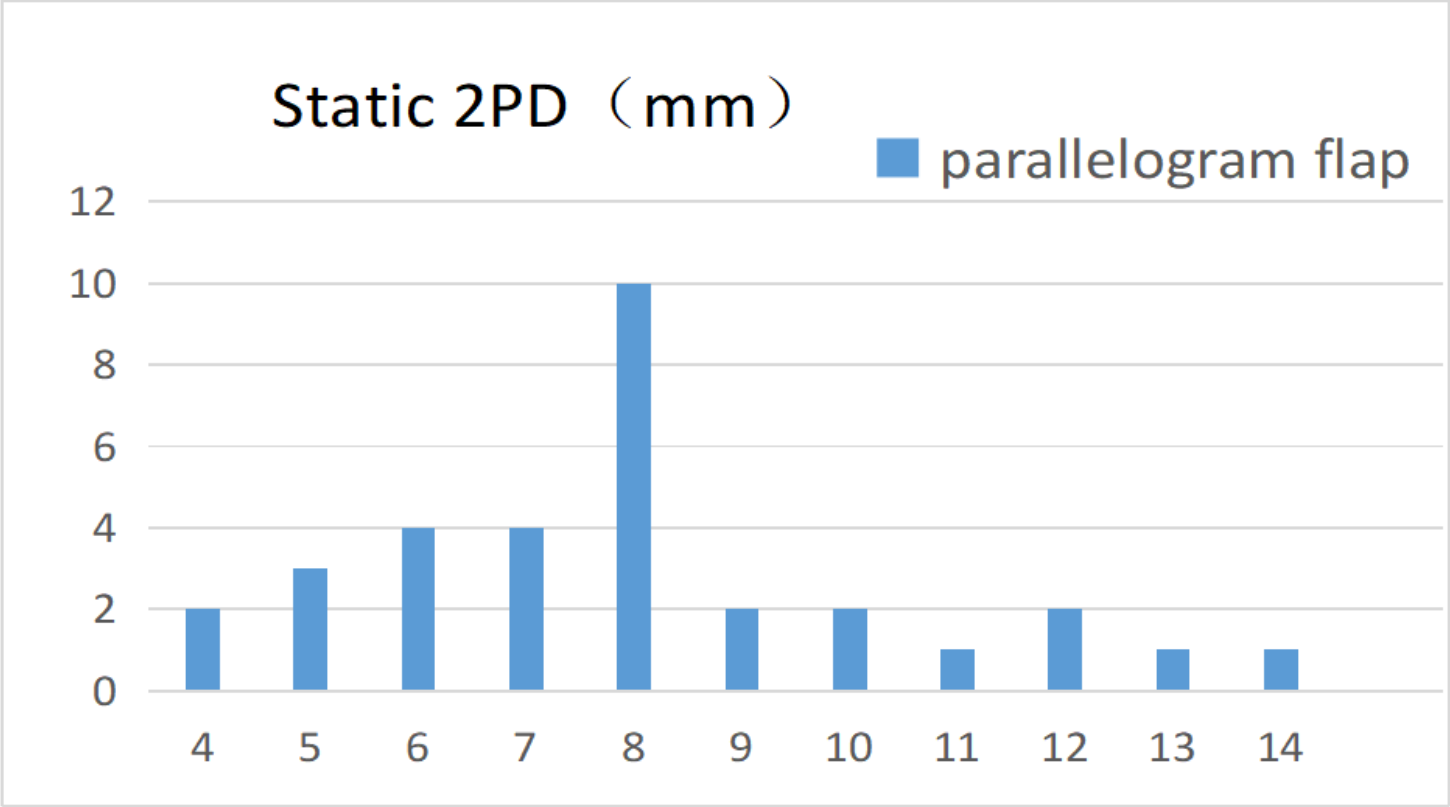

Figure 3

The frequency distribution of the static 2PD values of the flaps in Group parallelogram flap



Figure 4

Case：Patient's intraoperative performance（A,B） Postoperative performance （C,D） One month after surgery（E,F） four month after surgery（G,H）

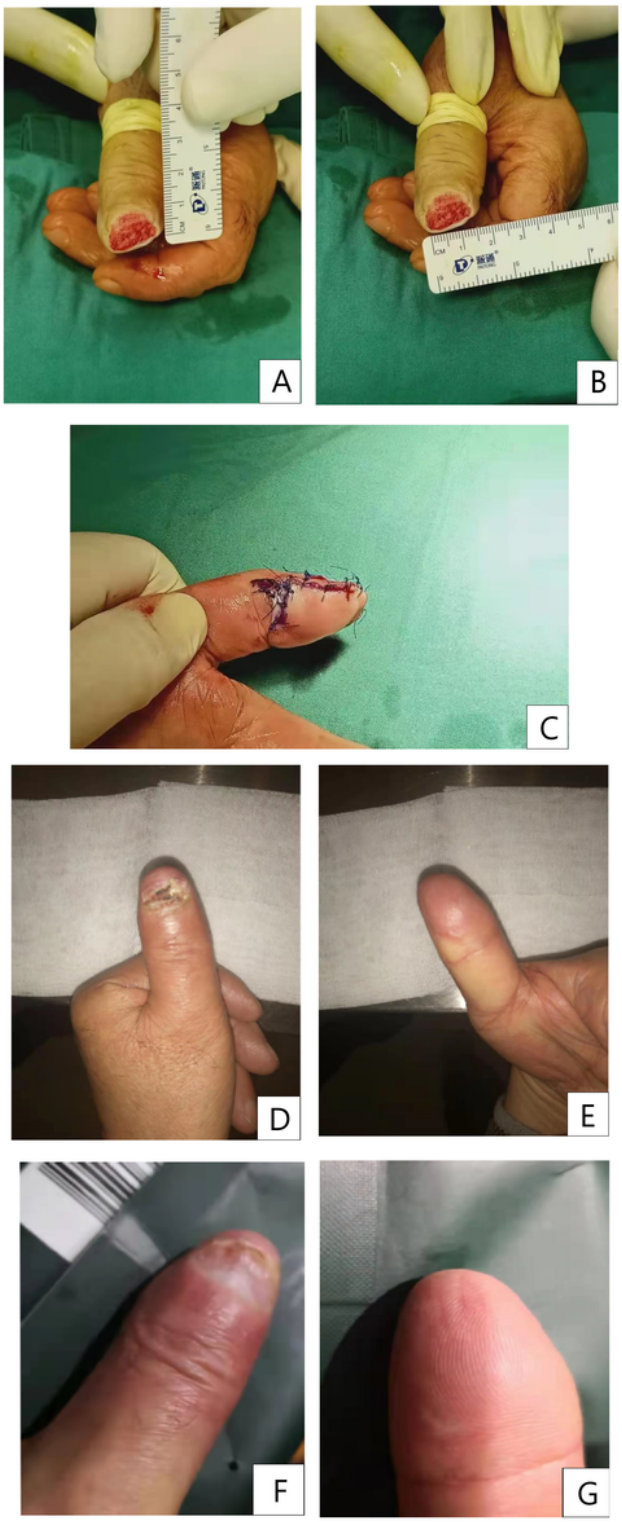

Figure 5

Case（Patient's intraoperative performance（A,B） Postoperative performance （C） One month after surgery （D,E） four month after surgery（F,G）

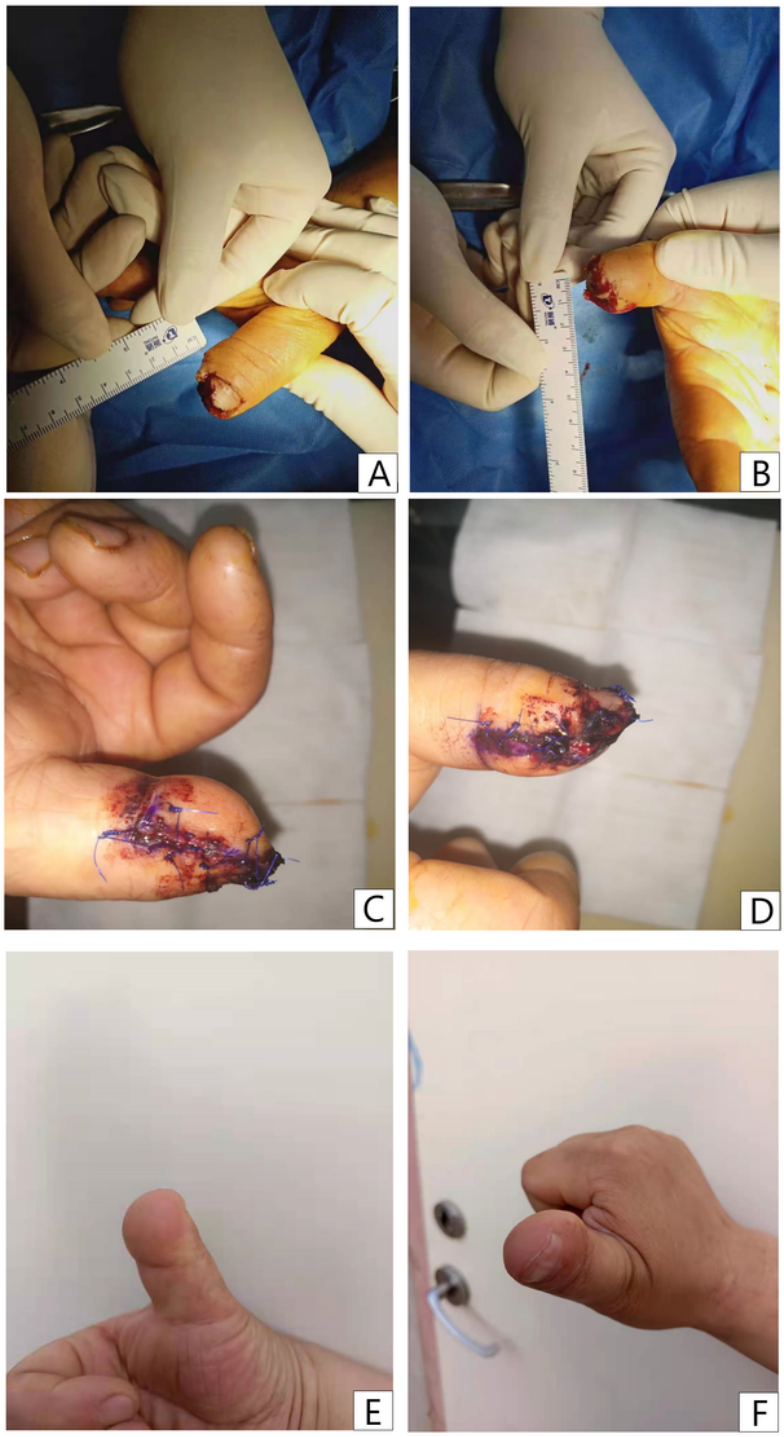

Figure 6

Case Patient's intraoperative performance A,B Postoperative performance C D four month after surgery E,F