Clinical Application of a Modified Local Transposition Flap Surgery in Repairing Fingertip Defects

Yingkai Zhang (592644257@qq.com)
Jinshan Hospital of Fudan University

Yao Wang
Jinshan Hospital of Fudan University

Rongbo Wu
Jinshan Hospital of Fudan University

Jiaqi Zhou
Jinshan Hospital of Fudan University

Research Article

Keywords: Fingertip, Local Flaps, Defect, Coverage, Trauma, Bone exposure.

Posted Date: December 22nd, 2021

DOI: https://doi.org/10.21203/rs.3.rs-729156/v2

Abstract

Background: A modified local transposition flap surgery was performed for fingertip injuries, which allows a more significant transfer distance with good outcomes.

Methods: The study collected patients who underwent parallelogram transposition flaps and V-Y flaps to repair fingertip defects from 2017 to 2020. 122 cases (122 fingers) were included in our study, The interval between the injury and operation was 5.78 h (the mean value was 4.7-8.4 h). All operations were performed by one surgical team, and the average operation time was 31.2 min.Record the operation time two-point discrimination 2PD Total Active Movement (TAM)and the MHQ (Michigan Hand Questionnaire) of the injured fingers to evaluate the therapeutic effect.

Results: All parallelogram Group A and V-Y flaps Group B had survived postoperatively. There was no difference with operative duration and follow-up time in two groups. At last follow-up, there was no difference with the 2PD of the palmar part of the flaps and the TAM of injured figures in Group A and Group B . The MHQ summary scores in Group A were much higher than in Group B . Evaluation of the MHQ subscale performance showed that the overall hand function, activities of daily living, work performance and pain score had no differences, but aesthetics and satisfaction score was higher in Group A .

Conclusions: The reconstruction using parallelogram flaps is a easier and more versatile treatment with better functions, less morbidity and better aesthetics. This method is a better choice for reconstruction of fingertip injury.

1. Introduction

Finger injury is common in our daily life [1]. However, severe injuries may result in skin and soft tissue defects with the exposure of bone, joint, tendon, blood vessels and nerve, leading to disfigurement and impairment of finger function. Several approaches to repairing injured fingers are being practiced [2]. It is generally believed that amputation with sutured closure of the wound may be the most effective treatment, but patients are usually discontented due to the deficiencies of appearance and function [3]. The application of an abdominal flap allows possible rescue of injured fingers [4, 5]. However, the abdominal flap belongs to the distal flap and has several shortcomings, such as requiring multi-stage surgeries, poor wear resistance, swollen appearance, poor sense of touch, and requiring hand attachment to another part of the body for up to 3 weeks [6, 7]. With the development of flap technology and microsurgery, regional pedicled flap and free flap have become a popular choice in managing injured fingers but again, they are not without drawbacks. While local flaps, such as the V-Y flaps have the advantages of having similar texture and sensation to the defect area, their applicability is limited when the defect area is large that the wound cannot be covered [8, 9]. In this instance, compared with local flaps, free flaps are superior in facilitating the movement of tissues and restore the aesthetic effect in a single stage [10], but the operation and postoperative care are complex and unfortunately, flap failure is

not uncommon. Here, we described a novel transposition flap surgery, which we named the parallelogram transposition flap for fingertip defects and the clinical outcomes were reviewed. With this technique, the length of the fingers was retained while allowing a more significant transfer area than the V-Y flap. Moreover, the aesthetic and function of fingers were preserved.

2. Methodology

2.1 Patients

Patients undergoing parallelogram transposition flaps and V-Y flaps to repair fingertip defects from 2017 to 2020 were included in our retrospective analyses. The study was submitted to the Ethics Committee. Patients deemed suitable for this procedure would satisfy the following inclusion criteria: (1) single fingertip injury of one hand; (2) local soft tissue defects and phalangeal bone exposure without skin flap transplantation; (3) the injured finger had not been longer than 10 hours with light contamination of the wound; (4) the patient agreed to participate at the 4-month follow-up. 64 fingers of 64 cases were treated by parallelogram flaps (Group A), and the others (58 fingers of 58 cases) were treated by V-Y flaps (Group B). All operations were performed by two surgical teams which had many years of clinical experience.

2.2. Operative method

2.2.1 Wound treatment

All operations were performed by one surgical team. Firstly, the patient was given nerve block anesthesia at the root of the injured finger. A gauze was then placed at the root of the finger and tightened with a rubber band to minimize bleeding. Thorough debridement and hemostasis were performed to the wounded finger. With a partial defect of the phalange, the remnant of the phalange was repaired and the bone structure was polished. The exposed nerve stump was incised with a sharp knife so that the severed end would retract naturally into the normal soft tissue.

2.2.2 Harvesting of skin flap

Group A

According to the size of the defect, the flap was designed on the side with more residual skin (Fig. 1). A longitudinal incision was made along the bone surface on both sides of the fingertip and the incised position should not exceed the transverse striation of the distal interphalangeal joint. Then, the skin and subcutaneous tissue were incised along the edge of the skin, and the skin flap was dissected sharply within the subcutaneous fascia, avoiding injury to the proper digital artery and nerve. A transverse incision was made on the side with more remaining skin to provide sufficient angle for flap turnover. Once freed, the designed flap was flipped over. Given its shape resembling a parallelogram, we named the flap a parallelogram flap. The longest hypotenuse c should be longer than the longitudinal length a + the width of defect b (Fig. 2), which was sufficient to cover the defective area. After the flap was flipped over,

a piece of skin graft A was left on the opposite side. The constructed skin graft A could be used to repair the transferred skin defect B.(Fig. 6, 7)

Group B

The distal edge of the wound is the base of the flap; the flap's apex should extend to the distal interphalangeal crease (Fig. 3). The skin and subcutaneous tissue are then incised, including the fibrous septa anchoring the pulp tissue to the bone. Damage to the neurovascular bundles should be avoided. The flap can be advanced up to 1 cm over the defect and secured with sutures, creating a Y-shaped repair(Fig. 5).

2.3 Postoperative management

Postoperatively, antibiotics were given intravenously to reduce the risk of infection, in addition to lamp baking heat preservation and other symptomatic treatment. Moreover, patients received regular dressing changes and were advised to bed rest, elevate the affected limb, stop smoking, keep warm, and regularly observe the perfusion of the skin flap.

2.4 Follow-up

2.4.1 The Total Active Movement (TAM) of the injured fingers was measured using a standard hand goniometer. The system sums the degrees of active flexion at the interphalangeal joints and metacarpophalangeal joint and subtracts the degrees of the extension deficits (100% for excellent; > 75% for good; > 50% for fair; < 50% for poor)

2.4.2 The sensibility of the palmar part of the flaps was measured using static two-point discrimination (2PD). The modfied American Society for Surgery of the Hand guidelines were used to classify the 2PD (< 6 mm for excellent; 6–10 mm for good; 11–15 mm for fair; > 15 mm for poor).

2.4.3 The MHQ (Michigan Hand Questionnaire) was used to subjectively evaluate outcomes of the repaired hands. The MHQ includes 6 subscales (overall hand function, activities of daily living, pain, work performance, aesthetics, and satisfaction).

3. Results

The characteristics of the study samples are detailed in Table 1. All the flaps and the skin grafts survived completely in the two groups. Patients in two groups did not differ with respect to age, gender, the cause of injury, the finger type, the interval between injury and surgery and the duration of surgery ($P > 0.05$ for each). There was no difference with operative duration and follow-up time in two groups ($P > 0.05$ for both) (Table 1). Accordingly, the patients' baseline assessment indicated that the two groups were functionally similar, and the selection bias appears to have been limited.

Table 1
Characteristics of the sample.

Characteristics of the sample.	Group A	Group B	P value
Age (year)	40 SD(11)(range17-60)	36 SD(9)(range20-58)	0.258
Gender (n)			0.758
Male	40	36	
Female	24	22	
Cause of injury (n)			0.684
Twisting	26	16	
Crushing	22	18	
Cutting	16	24	
Finger type (n)			
Thumb	12	8	
Index fingers	12	10	
Middle fingers	28	22	
Ring fingers	8	10	
Little fingers	4	8	
Interval between injury and operation (h)	5.78h(range 4.7~8.4 h)	5.12h(range4.6~8.2 h)	0.635
Operation duration (min)	31.2min	35.8min	0.158

At last follow-up, the frequency distributions of the static 2PD of the flaps in the two groups were presented in (Fig. 4), and there was no difference with the 2PD of the palmar part of the flaps (Table 2) and the TAM of injured figures in Group A and Group B (Table 3). The MHQ summary scores in Group A were much higher than in Group B ($P < 0.01$). Evaluation of the MHQ subscale performance showed that the overall hand function, activities of daily living, work performance and pain score had no differences, but aesthetics and satisfaction score was higher in Group A ($P < 0.01$ and $P < 0.05$, respectively) (Table 4).

Table 2
2PD of the palmar part of the flap

value	Group A	Group B
Excellent	10	8
Good	44	38
Fair	10	12
Poor	0	0

Table 3
TAM of the injured finger (n)

value	Group A	Group B
Excellent	54	26
Good	10	12
Fair	0	0
Poor	0	0

Table 4
Michigan Hand Outcomes Questionnaire (MHQ).

Domain	Group A	Group B	P value
Overall hand function	93.71 (SD 3.51)	92.97 (SD 4.73)	P = 0.127
Activities of daily living	95.22 (SD 2.23)	94.38 (SD 3.35)	P=0.09
Work performance	94.23 (SD 3.21)	94.38 (SD 3.65)	P=0.374
Pain	4.34 (SD 4.01)	4.63 (SD 4.71)	P=0.31
Aesthetics	92.15 (SD 7.16)	86.56 (SD 5.60)	P = 0.004
Satisfaction	92.45 (SD 5.61)	86.72 (SD 8.21)	P = 0.017
Summary scores	94.29 (SD 3.14)	91.73 (SD 3.41)	P = 0.005

4. Discussion

Fingertip injury represents the most common injury of the hand [11], which is defined as a distal injury of the flexor digital tendon and extensor tendon insertion [12]. In the management of a fingertip injury, although it is essential to maintain the length, preserve the nail and the appearance, the main goal of treatment is to ensure the durability of the fingertip and painless at the skin. Therefore, the treatment must be individualized based on several patient-related factors and unique trauma characteristics [13].

For those injured fingers with bone exposure and local soft tissue defects, stump revision (i.e., phalangeal shortening and direct suture) is the simplest and fastest way to recovery, which can be performed under local anesthesia in the emergency room [2]. However, this operation shortens the phalange and adversely affects the appearance and function of the affected finger. With the advancement of medical technology, stump revision is no longer a common approach to manage tissue defects [3]. Compared with stump revision,, given that our method demonstrated a similar length of operative time and difficulty while retaining the length and function of the affected finger.

At present, the “V-Y” advancement flap [14] is widely performed in the management of fingertip injuries. “V-Y” flap is best used for transverse or anticlinal fingertip amputation and is suitable for injury to any finger. The contraindications of applying this flap include oblique metacarpal fingertip amputation and extensive palmar soft tissue defects. The edge of the wound is at the bottom of a distal triangle of the flap, and the apex of the flap can be extended to the transverse striation of the distal interphalangeal joint. During the operation, the skin and subcutaneous tissues should be incised first, including the fiber septum, and injury to the neurovascular bundle should be avoided. The flap can be advanced 1 cm to the distal end and form a "Y" shape repair. With this method, the maximum advancement distance of the skin flap is limited to 3-4 mm [15] and the skin flap area provided are often inadequate. Moreover, the incision of this operation is made at the finger pulp and the postoperative scar is located at the middle of the finger pulp, which may affect the sensory function. On the other hand, the most widely used transfer flap, the “V-Y” flap is widely used, but its shortcomings still need to be further improved. The parallelogram transfer method allows a longer transfer distance of the transposition flap. In our practice, the residual skin was trimmed and flipped over. The transverse width of the flap was abandoned and the longitudinal length of the flap was obtained. The defects were evenly distributed on each side of the parallelogram to achieve sufficient transfer distance to cover the exposed bone and tissues.

This article provided a detailed description of a modified flap for the surgical management of fingertip defects. The transfer flap was incised closely to the bone surface of the distal phalanx, and the interphalangeal artery was not damaged during stripping [16, 17], which is key to flap survival. Venous outflow is maintained by venules and capillaries in the perivascular adipose tissues through a retrograde fashion [18]. Therefore, if the interphalangeal artery is well protected during the flap design, the flap survival can be assured more confidently, as evidenced in our analyses that all our parallelogram flaps had survived postoperatively.

The reconstructive surgery for fingertip injury aims to obtain stable tissue coverage, achieve acceptable appearance, restore sensitivity, maintain finger length and resume normal physical activity promptly[19]. After a careful preoperative design of the parallelogram flap, postoperative skin flap contracture is less likely to occur, given that the turning over of the flap provides more coverage area than the “V-Y” flap. Furthermore, the incision of the parallelogram flap is distributed at both sides of the fingertip, and therefore the scar is at the sides of the finger. In this way, we abandon the finger’s width and retain the length, successfully achieving the purpose of the operation.

The practice of sensory or non-sensory reconstruction of fingers remains controversial and debatable among hand surgeons. Studies have reported an average of 10 mm in the static two-point discrimination test when a "senseless" reverse digital artery island flap has been performed[20, 21]. Conversely, other studies have demonstrated a normal static two-point discrimination test (1-5mm) following neurovascular island flaps [22, 23]. The findings of these studies indicate a reduced ability of flaps to restore sensation in the absence of nerve connections [24–26]. By performing free flap surgery, the digital nerve can usually be preserved. We demonstrated that our operative method provided a good sensory reconstruction of fingers, leading to satisfactory recovery in the finger movement, strength, etc.

There were limitations to our parallelogram flap. In particular, this flap would not be applicable when there were multiple skin defects at the donor site, or the required transfer distance was more than 6-7mm. In this instance, the skin flap adjacent to the finger or a reverse-flow island flap can be considered.

Conclusion

The reconstruction using parallelogram flaps is a easier and more versatile treatment with better functions, less morbidity and better aesthetics. This method is a better choice for reconstruction of fingertip injury.

Declarations

Ethics approval and consent to participate

Retrospective clinical study was approved by Jinshan Hospital of Fudan University's institutional review board (JIEC 2021-S21-01). This study was conducted in accordance with the Declaration of Helsinki. All the patients consented to participate in this study, and informed consents were signed by themselves in all instances. In addition, the parents or guardians of the study participants gave written consent for their respective minors to participate in the study.

Consent for publication

Written informed consent was obtained from the patients' guardians for publication of clinical data.

Availability of data and materials

The datasets of the current study are available from the corresponding author upon reasonable request.

Competing interests

The authors declare that they have no competing interests.

Funding

This study was funded by Jinshan Hospital of Fudan University(No.JYQN-LC-202107)

Authors' contributions

ZYK and WY involved in making the conception and design of research and carried out drafing of the article. ZJQ carried out the acquisition of data and made a final approval and guarantor of the manuscript. WRB participated in making the conception and design of the study, carried out the acquisition of data and made a final approval and guarantor of the manuscript. All authors read and approved the final manuscript.

Acknowledgements

The authors would like to thank Hui Liang and Fan Cao for contribution on collecting parents' information.

Footnotes

Publisher's Note

Springer Nature remains neutral with regard to jurisdictional claims in published maps and institutional affiliations.ZYK and WY contributed equally to this work.

References

1. Abbase EA, Tadjalli HE, Shenaq SM. **Fingertip and nail bed injuries**. Postgrad Med. 1995. **98** (**5**): **217-236**.
2. Tang JB, Elliot D, Adani R, Saint-Cyr M, Stang F. **Repair and reconstruction of thumb and fingertip injuries: a global view**. Clin Plast Surg. 2014. **41** (**3**): **325-59**.
3. Holm A, Zachariae L. **Fingertip lesions. An evaluation of conservative treatment versus free skin grafting**. Acta Orthop Scand. 1974. **45** (**3**): **382-92**.
4. Kleinman WB, Dustman JA. **Preservation of function following complete degloving injuries to the hand: use of simultaneous groin flap, random abdominal flap, and partial-thickness skin graft**. J Hand Surg Am. 1981. **6** (**1**): **82-9**.
5. **BEVIN AG, CHASE RA**. THE MANAGEMENT OF RING AVULSION INJURIES **AND ASSOCIATED CONDITIONS IN THE HAND**. Plast Reconstr Surg. 1963. **32**: **391-400**.
6. Giessler GA, Erdmann D, Germann G. **Soft tissue coverage in devastating hand injuries**. **Hand Clin**. 2003. **19** (**1**): **63-71**, **vi**.
7. Buja Z, Arifi H, Hoxha E. **Repair of degloving fingers with abdominal tunnelization flap**. J Hand Surg Eur **Vol**. 2013. **38** (**4**): **439-40**.
8. Bogov A, Mullin R, Kubitskiy A. **The double flap partial reconstruction technique for the avulsion-type finger injuries: a case report**. J Hand Surg Eur Vol. 2011. **36** (**5**): **423-5**.
9. Santos T, Oliveira MT, Angelini LC. **Retrospective study to evaluate the treatment of digital pulp lesions using a homodigital flap**. Rev Bras Ortop. 2018. **53** (**2**): **200-207**.

10. Bashir MM, Sohail M, Shami HB. **Traumatic Wounds of the Upper Extremity: Coverage Strategies**. Hand Clin. 2018. **34** (**1**): **61-74**.
11. Patel L. **Management of simple nail bed lacerations and subungual hematomas in the emergency department**. **Pediatr Emerg Care**. 2014. **30** (**10**): **742-5**; **quiz 746-8**.
12. Hawken JB, Giladi AM. **Primary Management of Nail Bed and Fingertip Injuries in the Emergency Department**. Hand Clin. 2021. **37** (**1**): **1-10**.
13. Hao R, Wang B, Wang H, Yang H, Huo Y. **Repair of distal thumb degloving injury using combination of reverse dorsoradial flap of the thumb and middle finger proper digital arterial island flap**. J Orthop Surg Res. 2020. **15** (**1**): **417**.
14. Atasoy E, Ioakimidis E, Kasdan ML, Kutz JE, Kleinert HE. **Reconstruction of the amputated fingertip with a triangular volar flap. A new surgical procedure**. J Bone Joint Surg Am. 1970. **52** (**5**): **921-6**.
15. Lee DH, Mignemi ME, Crosby SN. **Fingertip injuries: an update on management**. J Am Acad Orthop Surg. 2013. **21** (**12**): **756-66**.
16. Braga-Silva J, Kuyven CR, Fallopa F, Albertoni W. **An anatomical study of the dorsal cutaneous branches of the digital arteries**. J Hand Surg Br. 2002. **27** (**6**): **577-9**.
17. Takeishi M, Shinoda A, Sugiyama A, Ui K. **Innervated reverse dorsal digital island flap for fingertip reconstruction**. J Hand Surg Am. 2006. **31** (**7**): **1094-9**.
18. Lucas GL. **The pattern of venous drainage of the digits**. J Hand Surg Am. 1984. **9** (**3**): **448-50**.
19. Germann G, Rudolf KD, Levin SL, Hrabowski M. **Fingertip and Thumb Tip Wounds: Changing Algorithms for Sensation, Aesthetics, and Function**. J Hand Surg Am. 2017. **42** (**4**): **274-284**.
20. Yildirim S, Avci G, Akan M, Aköz T. **Complications of the reverse homodigital island flap in fingertip reconstruction**. Ann Plast Surg. 2002. **48** (**6**): **586-92**.
21. Zhang JF, Wang L, Hao RZ, Huo YX, Yang HY, Hu YC. **Treatment of fingertip avulsion injuries using two periposition pedicled flaps**. J Plast Reconstr Aesthet Surg. 2019. **72** (**4**): **628-635**.
22. Storvik HM. **The extended neurovascular island flap in thum reconstruction**. Scand J Plast Reconstr Surg. 1973. **7** (**2**): **147-9**.
23. **HUESTON J. THE EXTENDED NEUROVASCULAR ISLAND FLAP**. Br J Plast Surg. 1965. **18**: **304-5**.
24. Kleinert HE, McAlister CG, MacDonald CJ, Kutz JE. **A critical evaluation of cross finger flaps**. J Trauma. 1974. **14** (**9**): **756-63**.
25. Johnson RK, Iverson RE. **Cross-finger pedicle flaps in the hand**. J Bone Joint Surg Am. 1971. **53** (**5**): **913-9**.
26. Hammouda AA, El-Khatib HA, Al-Hetmi T. **Extended step-advancement flap for avulsed amputated fingertip–a new technique to preserve finger length: case series**. J Hand Surg Am. 2011. **36** (**1**): **129-34**.

Figures

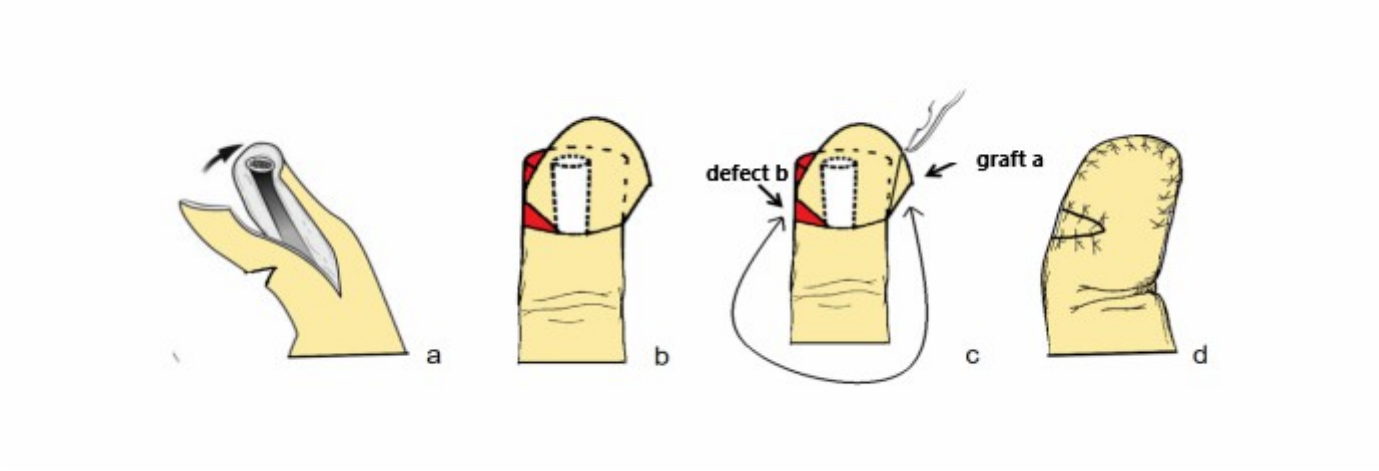

Figure 1

(a-c) Surgical steps of the parallelogram flap (B) The parallelogram flap reconstruction and skin grafts are completed.

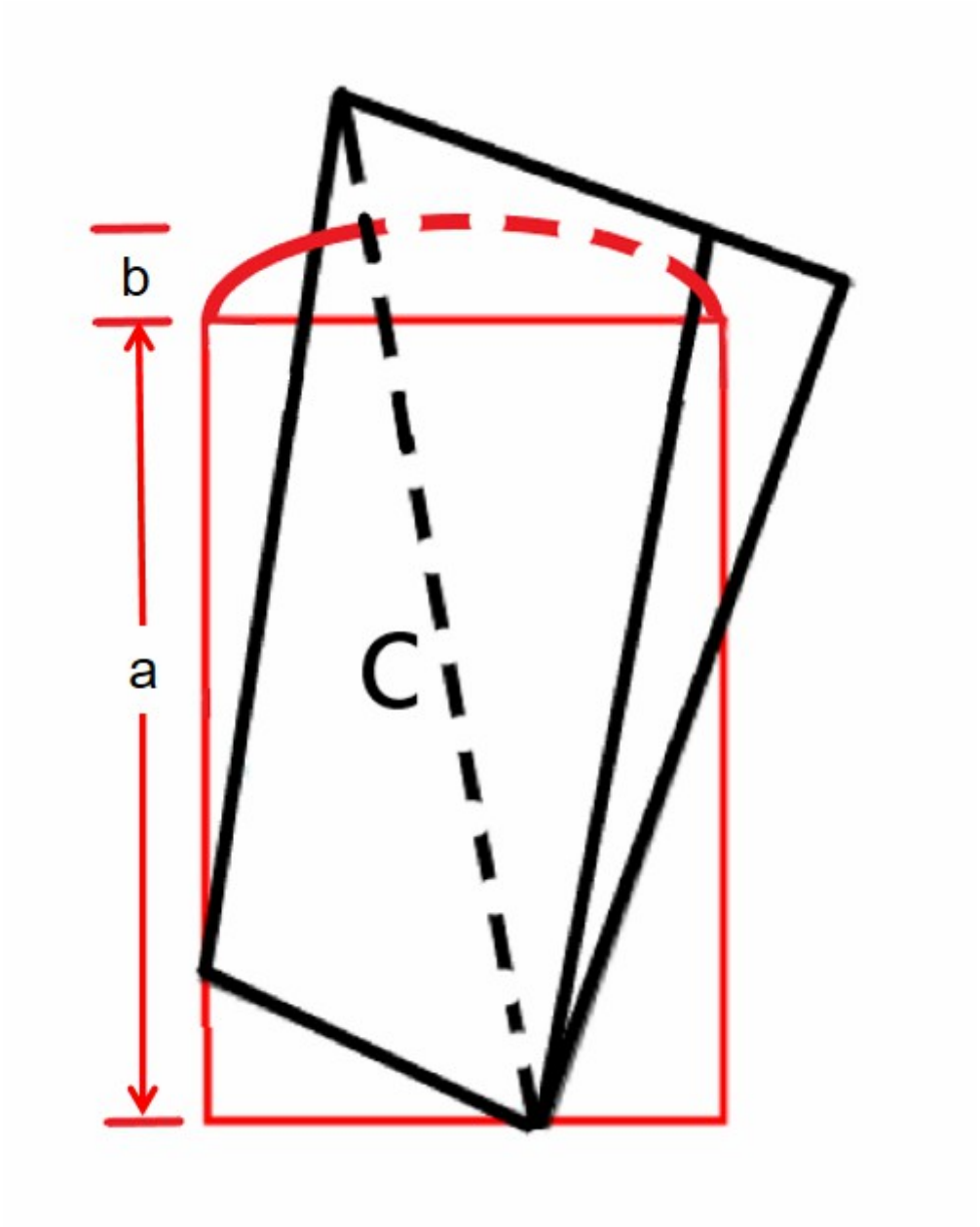

Figure 2

Schematic drawing of the parallelogram flap.

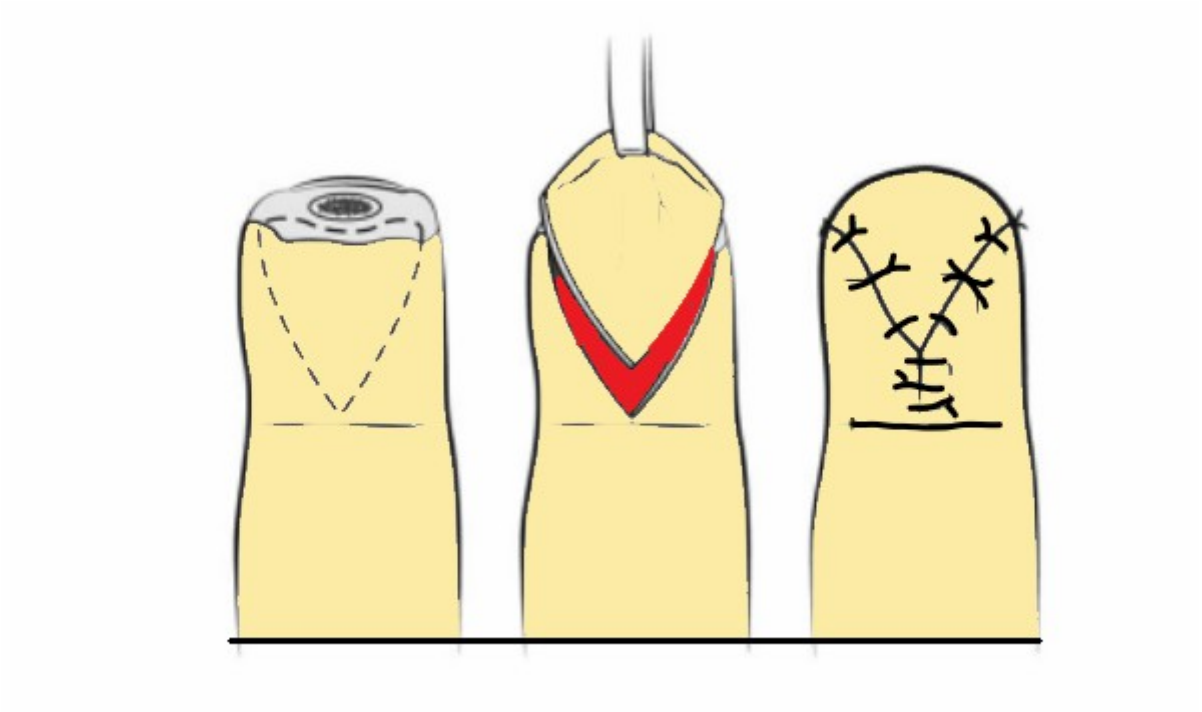

Figure 3

Schematic drawing of the V-Y flap.

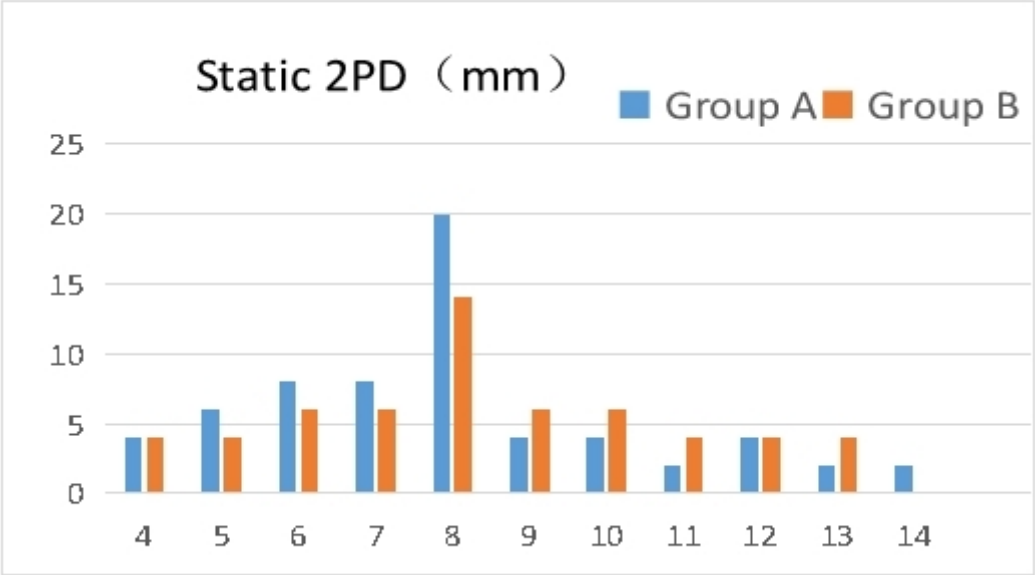

Figure 4

The frequency distribution of the static 2PD values of the flaps in Group parallelogram flap

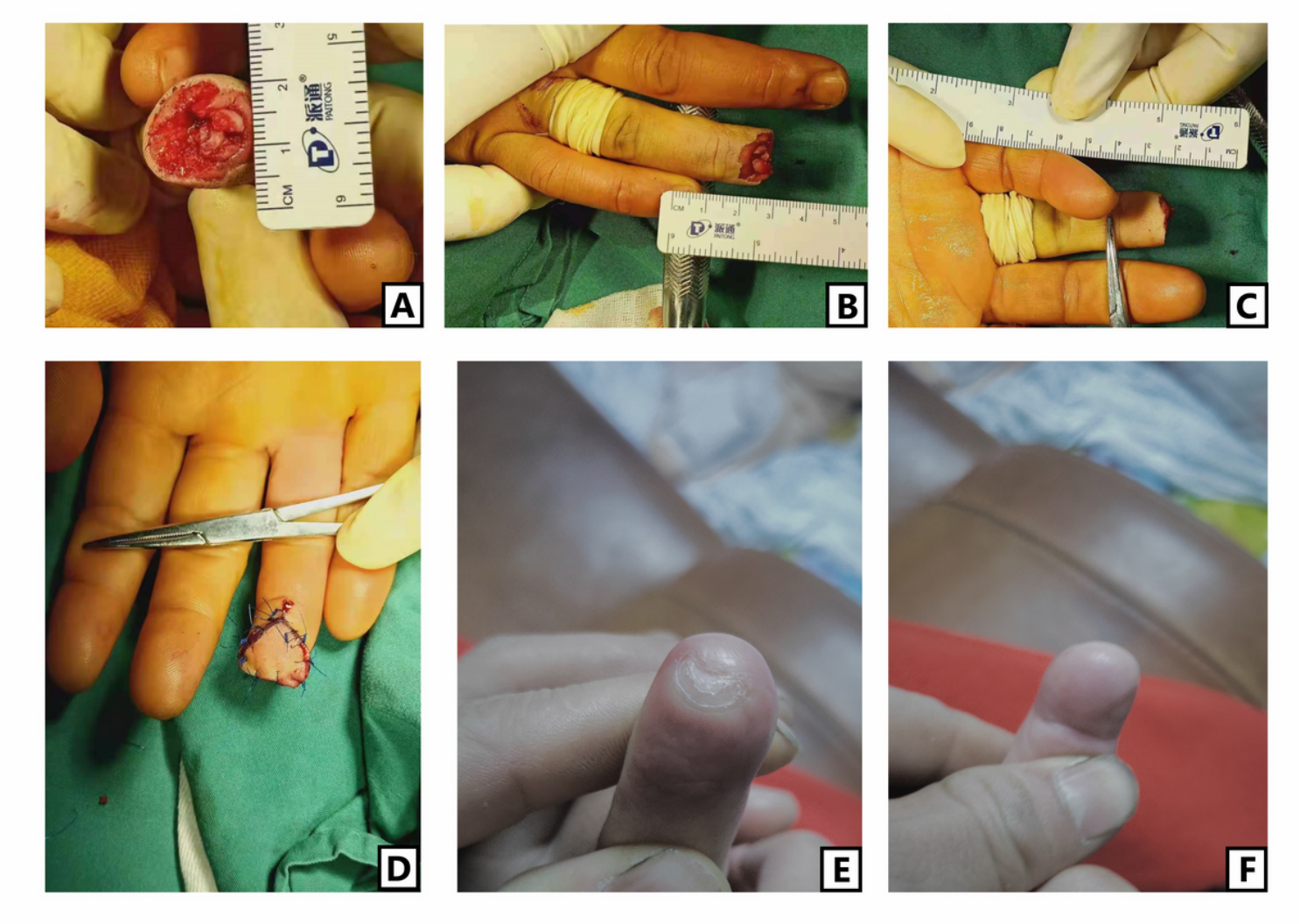

Figure 5

Intraoperative performance: Patients treated by V-Y flaps （A,B） Postoperative performance （D） four month after surgery（E,F）

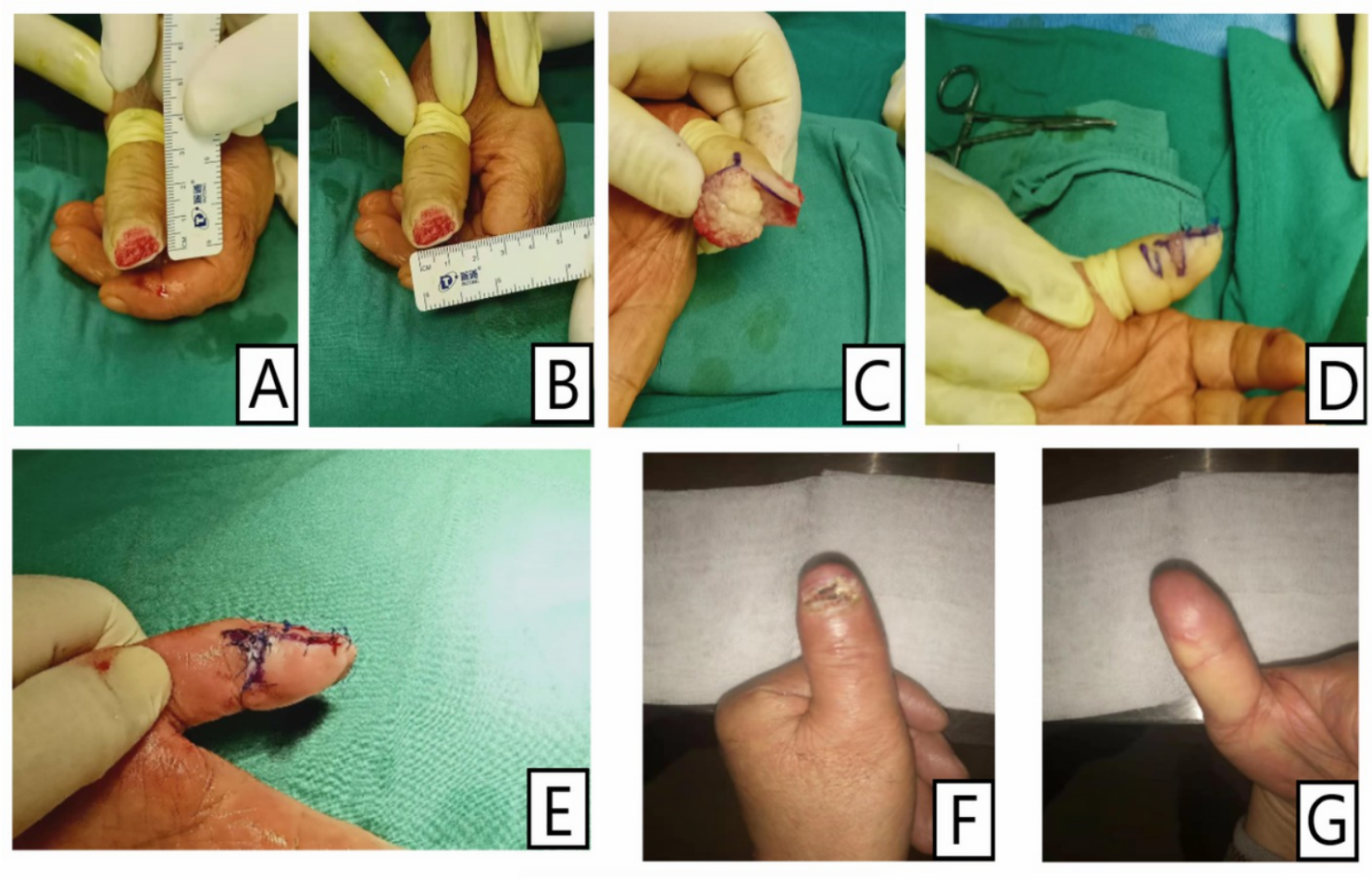

Figure 6

Intraoperative performance: Patients treated by parallelogram transposition flap（A,B,C,D） Postoperative performance （E） four month after surgery（F,G）

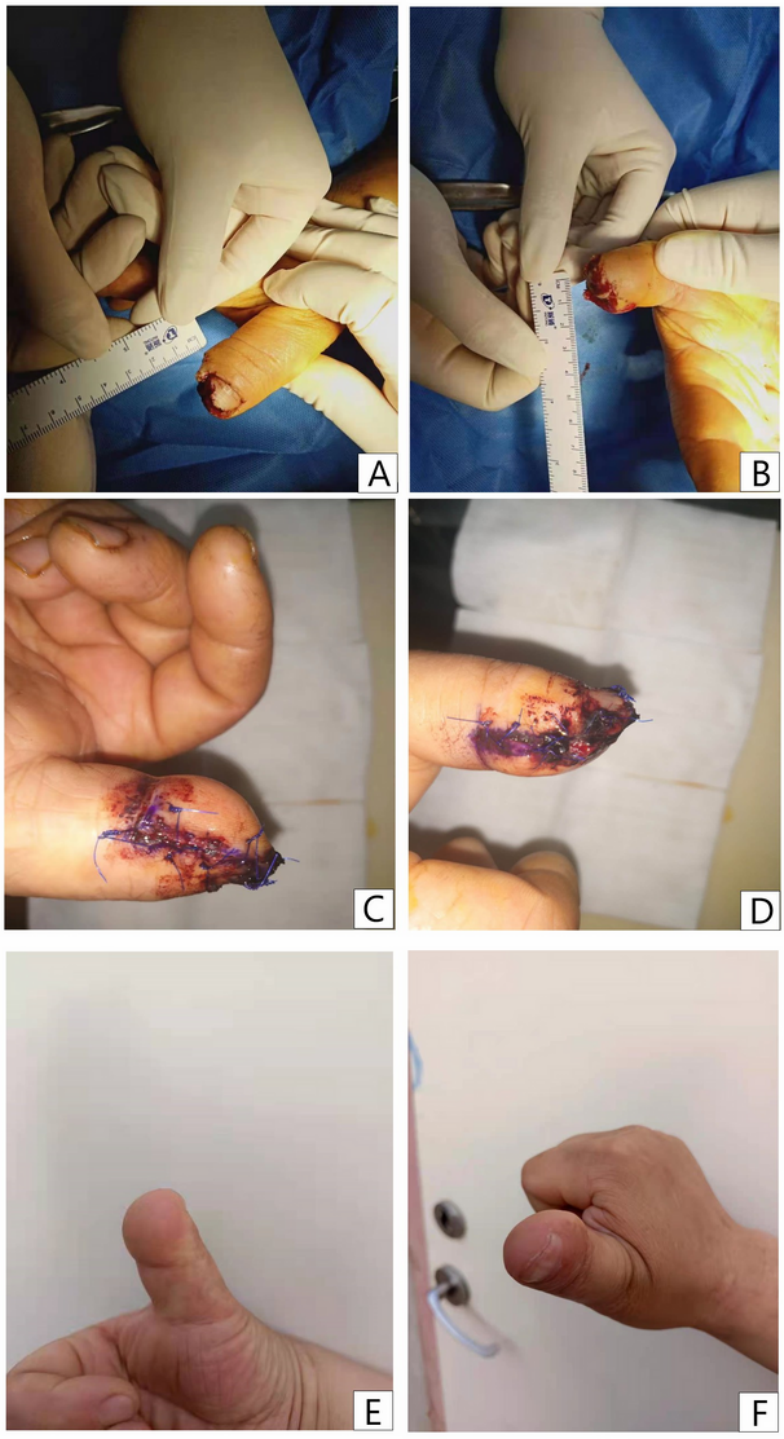

Figure 7

Intraoperative performance: Patients treated by parallelogram transposition flaps （A,B） Postoperative performance （C）（D） four month after surgery（E,F）