Dilatation of the Cystic Duct Confluence in Laparoscopic Common Bile Duct Exploration and stone extraction for Patients with Secondary Choledocholithiasis

Xiao-Bin Yang
the first people's hospital,qujing

An-Shu Xu (315000722@qq.com)
the first people's hospital,qujing https://orcid.org/0000-0002-3080-6430

Jian-Gang Li
the first people's hospital,qujing

Yong-Ping Xu
the first people's hospital,qujing

De-Song Xu
the first people's hospital,qujing

Chao-Chun Fu
the first people's hospital,qujing

Da-Bo Deng
the first people's hospital,qujing

Jie Li
the first people's hospital,qujing

Ma-Zhong Zhang
shanghai children's medical center

Research article

Keywords: Cystic Duct, Common Bile Duct Exploration, Secondary Choledocholithiasis

Posted Date: November 1st, 2019

DOI: https://doi.org/10.21203/rs.2.16697/v1

Version of Record: A version of this preprint was published at BMC Surgery on March 17th, 2020. See the published version at https://doi.org/10.1186/s12893-020-00705-y.

Abstract

The advent of endoscopic and laporoscopic techniques changed surgery in many regards. A number of options exist in the management of cholelithiasis and secondary choledocholithiasis. Among them, laparoscopic common bile duct (CBD) exploration with the choledocotomy followed by laparoscopic cholecystectomy (LC) has gained popularity. However, efforts should be made for minimally invasive or non-invasive to the CBD. For this purpose, we modified the surgical modality by laparoscopic transcystic approach with dilatation of the cystic duct confluence in CBD exploration (LTD-CBDE). The aim of this work was to assess the feasibility, safety and effectivity of LTD-CBDE based on our preliminary experience.

Introduction

The incidence of common bile duct stones (CBDS) reported in the literature in patients with gall bladder stones (GBS) varies between 7% and 20% [1–3]. Shortly after Bobbs performed the first cholecystectomy in 1867, Abbe performed the first common bile duct (CBD) exploration [4]. Subsequently, open cholecystectomy and CBD exploration followed by T-tube drainage gradually became a classic surgical modality for patients with cholelithiasis and secondary choledocholithiasis. With the introduction of endoscopy and laparoscopy into clinic in the 1970s and 1980s, laparoscopic cholecystectomy (LC) has been rapidly accepted as a routine treatment for patients with symptomatic GBS, and has also gradually as the conventional management of common bile duct stone (CBDS) [5]. In China, Yunnan Province is a high-incidence area of GBS and CBDS. A hospital in Qujing city first introduced laparoscopic techniques to China in 1991, and in that year more than 100 cases of LC were performed.

Many different management methods for CBDS have been used in clinical. Thanks to the development of endoscopic and laparoscopic techniques and the evolution of widespread expertise, endoscopic retrograde cholangiopancreatography (ERCP) and stone extraction followed by LC became one of the standard of care for patients with cholelithiasis and secondary choledocholithiasis [5]. The risk for development of pancreatitis related to ERCP technique, varied between 1%~13.5%, is a major concern regarding both pre-, intra- and postoperative extraction of CBDS. Other risks related to ERCP include bleeding, perforation, and those resulting from the disruption of the intact sphincter of Oddi [6–10]. Besides the inherent long-term complication of recurrent primary CBDS formation [11], the long-term sequel of sphincter incision have yet to be elucidated, especially for young patients. It may be due to the above reasons coupled with increasing expertise in laparoscopic procedures, more and more surgeons have started using a single-stage laparoscopic choledochotomy for CBS exploration and stone extraction with choledochoscope followed by LC (LCBDE) to patients. Although the ideal management method is still in dispute, LCBDE (single-stage) and ERCP followed by LC (two-stage) are two commonly used methods for CBD management. The latter is especially suitable for symptomatic CBDS patients, such as acute gallstone pancreatitis, acute cholangitis, *etc.*

Compared with ERCP followed by LC, LCBDE has the advantage of a higher success rate and a shorter duration of hospital stay while reducing the two procedures into a single minimally invasive operation under general anesthesia [5]. The LCBDE modality, avoiding unnecessary ERCP procedures, can be performed by either the transcystic approach or via a choledochotomy for the exploration and removal of CBDS. In most cases, the LCBDE usually has to be performed via a choledochotomy followed by T-tube drainage. However, T-tube placement presents difficulties in post-operative management, decreases quality of life, and extends hospital stays [12]. Recently, Chen *et al.* [13] and Niu *et al.* [14] modified transcystic approach with micro-incision of the cystic duct confluence or CBD in CBD exploration. The incised cystic duct confluence or CBD were closed primarily without a T-tube. Results had achieved good preliminary effects in patients with secondary CBDS. The authors concluded that this technique had many advantages, including avoiding postoperative T-tube drainage, shortening hospital stays, reducing complications, and improving patient's quality of life. Despite this, we think that micro-incision is still a kind of injury to CBD, and in the long run, patients might suffer from CBD stenosis, especially for those patients with CBD stenosis before operation.

Therefore, efforts should be made to minimize the injury to the cystic duct confluence or CBD, preferably without injury. For this purpose, in patients with cholelithiasis and secondary choledocholithiasis who have failed to explore and remove the CBDS by transcystic approach, we modified the surgical modality by replacing choledochotomy or incising confluence with *L*aparoscopic *T*ranscystic *D*ilatation of the cystic duct confluence in *CBD E*xploration (*LTD-CBDE)* intraoperatively. The basic idea of the modified modality is that since secondary CBDS originate from GBS, in some cases, the gallstones will fall through the cystic duct into the CBD, which indicates that if the natural cystic duct and the cystic duct confluence can be safely dilatated, the gallstones will be found and removed through choledochoscope. The improved procedure takes full advantage of the natural tube of the cystic duct and avoids the damage of CBD. At the end of surgery, the stump wall of the cystic duct was used to cover the CBD opening of confluence and primarily closed. In this article, we report our preliminary experience during the last three years, and assess the feasibility, safety and effectivity of LTD-CBDE technique.

Patients And Methods

In the period between December 2015 and April 2018, All patients with cholelithiasis and confirmed secondary choledocholithiasis in our hospital were scheduled for a single-step laparoscopic transcystic duct approach for the exploration and removal of CBDS with choledochoscope followed by LC. Among them, sixty-eight patients who have failed to explore and remove the CBDS by transcystic approach with choledochoscope (LCBDE) were offered our modified LTD-CBDE technique. This study was approved by the Institutional Review Board of The Qujing First People's Hospital(2015–10–15)who waived the need for informed consent for the use of patient data due to the retrospective nature of the study.

All patients underwent routine preoperative examination, including chest X-ray, electrocardiogram, routine blood test, liver and kidney function, and coagulation function. With the preoperative ultrasound (US) and/or magnetic resonance cholangiopancreatography (MRCP) examinations, patients were diagnosed

as cholelithiasis and secondary choledocholithiasis. Meanwhile, the inner diameter of the CBDS, and the location and size of the stones in the CBD were also clearly defined and recorded. The patients presented with acute cholangitis and acute gallbladder pancreatitis are not included in 68 patients. All patients were informed about both the procedure and the technology to be used and provided written informed consent.

Operations were performed by the same surgical team under general anesthesia and endotracheal intubation. During the operation, the patients were placed in a reverse trendelenburg position, tilted to the left. The pneumoperitoneum was established with carbon dioxide at a pressure of 12–15 mmHg and adjusted as needed. Four trocars were used for LC according to the standard technique. The Calot's triangle was dissected, the cystic artery, the cystic duct and CBD were exposed. The cystic artery was clipped and ligated first. Then, the cystic duct was clipped high near the GB, and 3/4 cross section was cut open at a distance of approximately 0.5cm from the CBD. The next steps were performed in the following order: (i) the choledochoscope (4.9 mm, Olympus, Tokyo, Japan) was inserted through the cystic duct and its confluence with CBD for the CBD exploration and stone extraction. If failed, (ii) the ventral side of the cystic duct was longitudinally incised 0.2–0.3cm starting from the cross-sectional incision, and the confluence was dilatated with the separation forceps (figure 1), and then the choledochoscope was inserted again. otherwise (iii) columnar dilatation balloon (M00558410) was used to dilatate the confluence (figure 2) until the choledochoscope was successfully inserted followed by the CBD exploration and stone extraction. The choledochoscope was also turned upward for exploration of the common hepatic duct and intrahepatic ducts, and the distal CBD was explored again after the intrahepatic exploration identified no stones. Intraoperatively, the 68 patients reported herein planned to adopt the surgical methods described in (ii) and (iii) above. As far as our practical experience was concerned, the degree of the cystic duct and/or the confluence dilatation depended on the size of the largest stone individually, which was determined based on preoperative US or MRCP examination. After the stones were removed totally (the CBD was completely clear and no evidence of remnant stones), the cystic duct was cut and LC was performed. The stump wall of the cystic duct was used to covered the entrance of CBD and was primarily closed.The abdominal drainage tube was left at the small omentum hole in all patients.

The patients' demographic data and the following indicators were collected and recorded: operation time in minutes, surgical success rate, open conversion rate, residual stone rate, timing of postoperative return of peristaltic activity and food intake, and the postoperative hospital stay, postoperative bile leakage rate. A follow-up MRCP evaluation was done a year after surgery for 43 patients. Before the patient was discharged from the hospital, the patients were instructed to pay attention to the clinical symptoms, signs, laboratory and imaging findings related to possible biliary disease after surgery. Data are presented with numbers, percentage, arithmetic mean standard deviation (SD).

Results

In the period from December 2015 to April 2018, sixty-eight patients with cholelithiasis and confirmed secondary choledocholithiasis were scheduled to undergo LTD-CBDE. The patient population comprised

19 (27.9%) males and 49 (73.1%) females with mean age 53 12 years (ranged between 18 and 72 years). Among them, 52 patients presented with symptoms and signs of obstructive jaundice, 8 patients had previous abdominal surgery history. The GBS was confirmed by US examinations, and the CBDS was initial diagnosed by US and confirmed by MRCP in all patients. The mean measured inner diameter of CBD was 12.6 1.8 mm (ranged from 9 to 17 mm). The median largest CBDS' diameter was 9 mm (ranged from 0.3 to 1.1 cm). Table 1 shows patients' characteristics, disease-related baseline data and the outcomes of surgical treatments. The mean operation time 106 min (ranged from 90 to 120 min), and the mean postoperative hospital stay was 5.9 days (4–15 days). Patients with ASA III grade will stay in the ICU for 1–4 days and the rest will return to the ward. All patients returned peristaltic activity in the next postoperative day, and intake liquid food on the early morning of the next day.

LC was started in all 68 patients. Of which, 62 cases (91.2%) were performed LC and LTD-CBDE successfully. Among them, columnar dilatation balloon was only needed in 5 patients, and the remainder successfully completed dilation with separation forceps. Stones were removed using a Cook basket (NTSE–045065-UDH). After surgery, the stump wall of the cystic duct was used to cover the entrance of CBD and was primarily closed by the application of laparoscopic interrupted full-thickness suture, as shown in figure 3. Those interested will be able to see the full video of a surgical procedure as shown in supplemented video material. Of the 62 patients who underwent successful surgery with LTD-CBDE, bile leakage was observed in 3 cases (4.4%). The maximum bile drainage volume in these three patients was less than 100 mL/day and the bile leakage stopped within 2 days. The abdominal drains were removed within 24–48 h postoperatively, if no bile leakage was observed. All of the patients were examined with MRCP to confirm that no residual stones and CBD stenosis. 43/68 cases returned to the hospital for MRCP re-examination one year after surgery, and none showed the signs of CBD stenosis or obstruction.

The patients' characteristics, baseline data and outcome table 1

Six patients who failed the LTD-CBDE procedure were not included. ASA: American Society of Anesthesiologists physical status; LC: laparoscopic cholecystectomy; CBD: common bile duct; CBDS: common bile duct stone; MRCP: magnetic resonance cholangiopancreatography.

Of 68 patients included, 6 patients (8.8%) were treated by other surgical methods for various reasons. In 2 cases fibrosis and unclear anatomical structure were present at the Calot's triangle, in 1 case Mirizze syndrome was coexisted, conversion to open cholecystectomy and exploration of the CBD were performed to remove safely the stones with T-tube drainage. In 2 cases with cystic duct atresia and one cases with the low opening position of the confluence respectively, choledochotomy followed by LC and T-tube drainage were performed. Postoperative MRCP revealed patency of the CBD. These six patients had smooth postoperative course.

Discussion

The secondary CBDS may cause many clinical symptoms and signs, including abdominal pain, obstructive jaundice, cholangitis, and biliary pancreatitis, *etc* [2]. just like patients in this article, there were as many as 52 patients diagnosed with obstructive jaundice. The ideal management of secondary CBDS with gallstones remains a matter of debate [5]. Since Endoscopy and laparoscopy were introduced into clinic, the conventional approach to the removal of CBDS is usually by pre-, intra or postoperative ERCP followed by LC [2, 5]. ERCP-related complications such as pancreatitis, bleeding and perforation are the main concerns. In addition, Structure and function of Oddi's sphincter are inevitable, and recurrent retrograde infection of CBD also happen often. Furthermore, ERCP have relatively strict prerequisite for stone removal and a low success rate (about 80%) [11]. For example, the smaller size of the stone, the lower position of the stone closing to the duodenal papilla, etc.

Laparoscopic choledochotomy followed by exploration and stone extraction with choledochoscope has therefore gained popularity for patients with choledocholithiasis and cholelithiasis. In this case, the problems related to T-tube placement, such as patient discomfort, biliary peritonitis, T-tube displacement, etc., have become new problems troubling surgeons [15–16]. In view of this, some surgeons tried to make full use of the natural cystic duct with micro-incision of CBD or confluence so as to facilitate choledochoscope insertion, exploration and removal of CBDS, and micro-incision was closed primarily at the end of operation [13–14]. Inspired by this, we further speculate: could we use the natural orifice comprising of cystic duct and its confluence at the CBD to achieve CBD exploration and stones extraction without incision? Therefore, we designed the current modified methods LD-CBDE, which was laparoscopic transcystic approach for CBD exploration and stones extraction with the dilatation of the confluence. The current design does not require incising the confluence, and primary suture of the mucous and seromuscular layers separately. The dilatation of the confluence not only overcomes the problems that the cystic duct is thin and the spiral valve acts as a barrier in exploration but also dilatates the entrance diameter of the CBD to the inner diameter of largest stone; this makes the insertion of the choledochoscope and stones extraction easier. CBD blood supply is not affected by incision, which can completely avoid postoperative CBD stenosis. The operation was very successful with a success rate of 91.2% (in fact, the success rate can reach 100% in the selective patient) and had a CBDS clearance rate of 100%, and on postoperative follow-up no problems related to a retained stone were encountered.

The reported overall success rates was 88.1% in meta-analysis of eleven randomized trials for LCBDE [5]. It appears that the success rate of 91.2% with present method coincides with those reported in the literature. Using a slightly different surgical approach with a micro-incision at the confluence, Chen et al. and Niu et al reported a success rate of 100% [13–14]. The main reasons for the failure is associated with anatomical problems in our series (6 patients), which suggests the importance of a carefully selected surgical strategy during operation. During the operation, special attention should be paid to the following aspects: Firstly, it is especially important to maintain the cystic duct intact, so as to facilitate the incision, dilatation, insertion of choledochoscope, observation, stones extraction and primary closure. Secondly, it is necessary to correctly identify the confluence and avoid its damage. Finally, limiting factors of success with LTD-CBDE include anatomic features related to the cystic duct and confluence, such as fibrosis and

anatomical abnormality of the Calot's triangle, small size or atresia, tortuous duct, and low level of or posterior insertion of the cystic duct on the CBD, *etc.* The mean operating time 105 min (ranging from 90 to 120 min) in our series was similar to the results reported by Chen *et al.* [13] and Niu *et al.*Using micro-incision of confluence. They reported mean operating times varied between 104 to 150min. The current operating time is relatively short compared to most LCBDE modality (average 119~194min) [2, 17, 18]. However, we don't think it is reasonable to directly compare the operation time, because any new modality is technically difficult with a clear learning curve and requires instruments and instruments, and prolongs the operation time. In the future, with technical improvement and more effective logistic organization, the operation time will be further reduced. We thought that this method appears to be a cost-effective method for treating CBDS, although it requires clinical experience as well as advanced laparoscopic skills.

Patients in our study were discharged after a mean postoperative hospital stay of 5.9 days. The hospital stay was significantly shortened compared with 194 patients adopting CBD mini-incision (mean 8 days) reported by Chen et al, however, similar to the hospital stay time of some LCBDE procedures [5, 17, 18]. No mortality was reported in our series, which is in accordance with the findings of other series with other surgical modality [13–14]. 43 cases were followed up one year after LTD-CBDE operation (25 patients lost to follow up); none of our patients presented with evidence of retained or recurrent CBDS and stenosis of CBD.

Our modified LTD-CBDE is safe and effective for the treatment of secondary choledocholithiasis, but a carefully selected surgical strategy during operation should be especially emphasized as suggested by Gigot *at al* [18]. For patients with anatomical abnormalities, intraperitoneal adhesions in the surgical site just as six patients in our series, the traditional open operation or laparoscopic choledochotomy should be considered as soon as possible in these cases. In addition, despite careful suturing of the confluence with stump wall, there are still 3 cases of postoperative bile leakage. This is not higher than the incidence of LCBDE (5.6% with experienced surgeons vs 17.1% with inexperienced surgeons) reported by liu *et al.* [19]. As analyzed by liu *at al.* [19], it is clear that postoperative bile leakage (and the like) can be reduced with gaining of experience in the technique [20]. Thirdly, in our series, the separation forceps, rather than the balloon, were used in most patients. It is undeniable that the former facilitates a quantitative description of the degree of expansion and resultant better safety. However, Yunnan is a poor province in China, and patients cannot afford the expensive balloon. Therefore, we chose the separation forceps rather than the balloon to dilatate the confluence. This is the biggest shortcoming of the current work, and fortunately, the vast majority of patients who used the separation forceps to dilatate confluence have achieved successfully surgery with LTD-CBDE technique. Finally, although we hypothesized that LTD-CBDE has the potential to reduce postoperative bile duct stricture, this is currently not confirmed and further research is needed. The optimal management of CBDS is dependent on the skills and techniques of the surgical team available at the local hospital. In any case, minimally invasive or non-invasive tissue and/or organ should be the direction of our efforts.

Conclusions

In patients failed to explore and remove the CBDS by transcystic approach, we modified the surgical modality by dilatation of the cystic duct confluence in CBD exploration (LTD-CBDE) and with primary double-layer closure. It is a safe and effective treatment procedure for patients with secondary choledocholithiasis. For suitable patients, the success rate of LD-CBDE is high, without increasing the operation time, incidence of bile leakage rate and postoperative hospital stay. However, the further research is needed to demonstrate whether intact CBD can reduce the incidence of CBD stenosis, especially in patients with preoperative CBD stricture.

Abbreviations

CBD□common bile duct□LC:laparoscopic cholecystectomy;LTD-CBDE:laparoscopic transcystic approach with dilatation of the cystic duct confluence in CBD exploration;CBDS:common bile duct stone;US:ultrasound;GBS:gall bladder stones;ERCP:endoscopic retrograde cholangiopancreatography;MRCP:magnetic resonance cholangiopancreatography.

Declarations

Acknowledgments

Special thanks to Professor MZ for his guidance.

Authors’ contributions

XY, AX, JL, YX, DX,CF,DD,JL,and MZ contributed to the concept and design of the study. XY,AX,YX and CF contributed to clinical information. All authors contributed to the writing of the manuscript.Special thanks to Professor MZ for his guidance.All authors read and approved the final manuscript.

Funding

No funding.

Availability of data and materials

The data that support the findings of this study are available from Department of General Surgery, The First People’s Hospital, Qujing City, Yunnan Province, China, however,restrictions apply to the availability of this data; which was used under license for the current study, therefore are not publicly available. Data are however available from the authors upon reasonable request, with permission from the Department of General Surgery.

Ethics approval and consent to participate

This study was approved by the Institutional Review Board of The Qujing First People's Hospital(2015–10–15)who waived the need for informed consent for the use of patient data due to the retrospective nature of the study.

Consent for publication

Written informed consent for publication was obtained from all participants.

Competing interests

The authors declare that they have no competing interests.

Author details

1Department of General Surgery, The First People's Hospital, Qujing City, Yunnan Province, China 65500.2Department of Anesthesiology, The First People's Hospital, Qujing City, Yunnan Province, China 655000.3Department of Anesthesiology, Shanghai Children's Medical Center, Shanghai Jiaotong University School of Medicine, Shanghai, China 200127.

References

1. Neuhaus H, Feussner H, Ungeheuer A, Hoffmann W, Siewert JR, Classen M. Prospective evaluation of the use of endoscopic retrograde cholangiography prior to laparoscopic cholecystectomy. ***Endoscopy*** 1992; 24(9): 745–749
2. Ghazal AH, Sorour MA, El-Riwini M, El-Bahrawy H. Single-step treatment of gall bladder and bile duct stones: A combined endoscopic–laparoscopic technique. ***Int J Surg*** 2009; 7(4): 338-346
3. Sarli L, Pietra N, Franze A, Colla G, Costi R, Gobbi S, Trivelli M. Routine intravenous cholangiography, selective endoscopic retrograde cholangiography and endoscopic treatment of common bile duct stones before laparoscopic cholecystectomy. ***Gastrointest Endosc*** 1999; 50: 200–208
4. Ellis PH. The story of gallstones and their treatment. J Perioper Pract 2019 (Epub ahead of print)
5. Singh AN, Kilambi R. Single-stage laparoscopic common bile duct exploration and cholecystectomy versus two-stage endoscopic stone extraction followed by laparoscopic cholecystectomy for patients with gallbladder stones with common bile duct stones: systematic review and meta-analysis of randomized trials with trial sequential analysis. ***Surg Endosc*** 2018; 32(9): 3763-3776
6. Sevinc B, Karahanö. The role safety steps in success and complication rate of endoscopic retrograde cholangiopancreatography. ***Surg Aparosc Endosc Percutan Tech*** 2017; 27(4): 233-236
7. Guda NM, Reddy DN, Kumar A. Complications of ERCP. ***Indian J Gastroenterol*** 2014; 33(1): 1-9
8. Andriulli A, Leandro G, Niro G, Mangia A, Festa V, Gambassi G, Villani MR, Facciorusso D, Conoscitore P, Spirito F, De Maio G. Pharmacologic treatment can prevent pancreatic injury after ERCP: a meta-

analysis. ***Gastrointest Endosc*** 2000; 51: 1–7

9. Dickinson RJ, Davies S. Post-ERCP pancreatitis and hyperamylasaemia: the role of operative and patient factors. ***Eur J Gastroenterol Hepatol*** 1998; 10: 423–8
10. Sherman S, Hawes RH, Rathgaber SW, Uzer MF, Smith MT, Khusro QE, Silverman WB, Earle DT, Lehman GA. Post-ERCP pancreatitis: randomized, prospective study comparing a low- and high-osmolality contrast agent. ***Gastrointest Endosc*** 1994; 40: 422–7
11. Nzenza TC, Al-Habbal Y, Guerra GR, Manolas S, McQuillan T. Recurrent common bile duct stones as a late complication of endoscopic sphincterotomy. ***BMC Gastroenteroloy*** 2018; 18: 39
12. Podda M, Polignano FM, Luhmann A, Wilson MS, Kulli C, Tait IS. Systematic review with meta-analysis of studies comparing primary duct closure and T-tube drainage after laparoscopic common bile duct exploration for choledocholithiasis. ***Surg Endosc*** 2016; 30(3): 845-861
13. Chen XM, Zhang Y, Cai HH, Sun DL, Liu SY, Duan YF, Yang C, Jiang Y, Wu HR. Transcystic approach with micro-incision of the cystic duct and its confluence part in laparoscopic common bile duct exploration. ***J Laparoendosc Adv Surg Tech A*** 2013; 23: 977–981
14. Niu X, Song J, He X, Chen J, Xu J, Li Z, Long H, Wei J. Micro-incision of the cystic duct confluence in laparoscopic common bile duct exploration for elderly patients with choledocholithiasis. ***Indian J Surg*** 2018; 80(3): 227-232
15. Decker G, Borie F, Millat B, et al. One hundred laparoscopic choledochotomies with primary closure of the common bile duct. ***Surg Endosc*** 2003; 17: 12–18
16. Hiromi T, Akiko U, Hui C, et al. Laparoscopic management of common bile duct stones: transcystic approach and choledochotomy. ***J Hepatobiliary Pancreat Surg*** 2002; 9: 206–212
17. Darkahi B, Liljeholm H, Sandblom G. Laparoscopic common bile duct exploration: 9 year experience from a single center. ***Front Surg*** 2016; 3: 23
18. Gigot JF. Navez B, Etienne J, Cambier E, Jadoul P, Guiot P, Kestens PJ. A stratified intraoperative surgical strategy is mandatory during laparoscopic common bile duct exploration for common bile duct stones. Lessons and limits from an initial experience of 92 patients. ***Surg Endosc*** 1997; 11(7): 722-728
19. Liu D, Cao F, Liu J, Xu D, Wang Y, Li F. Risk factors for bile leakage after primary closure following laparoscopic common bile duct exploration: a retrospective cohort study. ***BMC Surg*** 2017; 17(1): 1
20. Zhu H, Wu L, Yuan R, Wang Y, Liao W, Lei J, Shao J. Learning curve for performing choledochotomy bile duct exploration with primary closure after laparoscopic cholecystectomy. ***Surg Endosc*** 2018; 32(10): 4263-4270.

Table 1

Table 1 The patients' characteristics, baseline data and outcome

Variable	Value
Gender	
Men	19 (27.9%)
Women	49 (72.1%)
Mean age, year (range)	53±14 (18-72)
Previous abdominal surgery history	8 (11.8%)
ASA I/II/III/IV	42/19/6
Number of CBD	
1	54
2-3	12
>3	2
Median diameter of largest stone, mm (range)	9 (3-11)
Mean operation time, min (range)	106±9 (90-120)*
Success rate	62 (91.2%)
CBDS clearance rate	68 (100%)
Conversion open rate	3 (4.4%)
Conversion Choledochotomy + T-tube	2 (2.9%)
Retained stones with postoperative MRCP	0 (0%)
Complications	
Pancreatitis	0 (0%)
Biliary leakage	3 (4.4%)
Mean postoperative hospital stay, day (range)	5.9±2.4 (4~15)
Number of follow-up one year later	43 (63.2%)

Figures

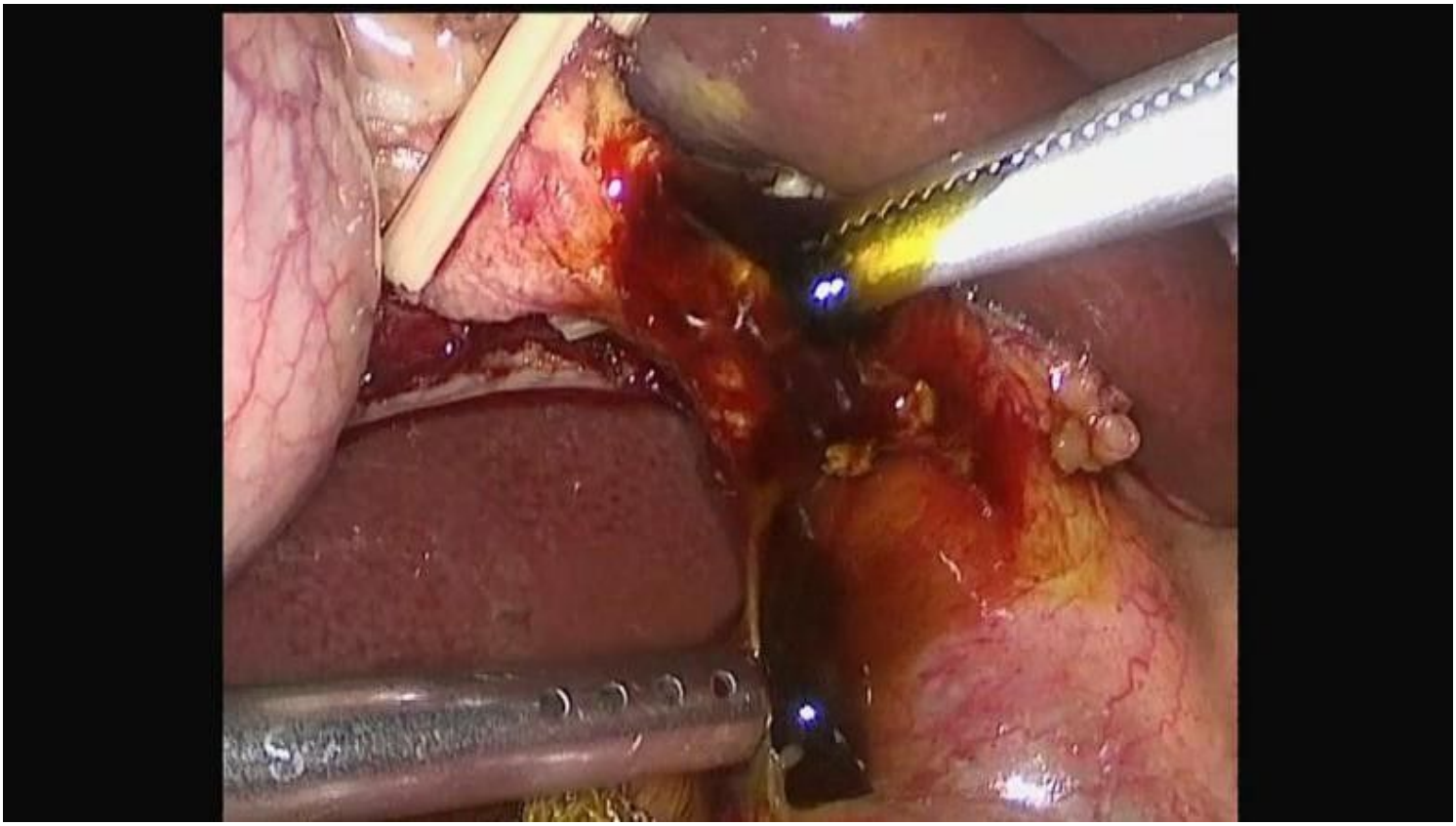

Figure 1

the confluence was dilatated with the separation forceps (arrow)

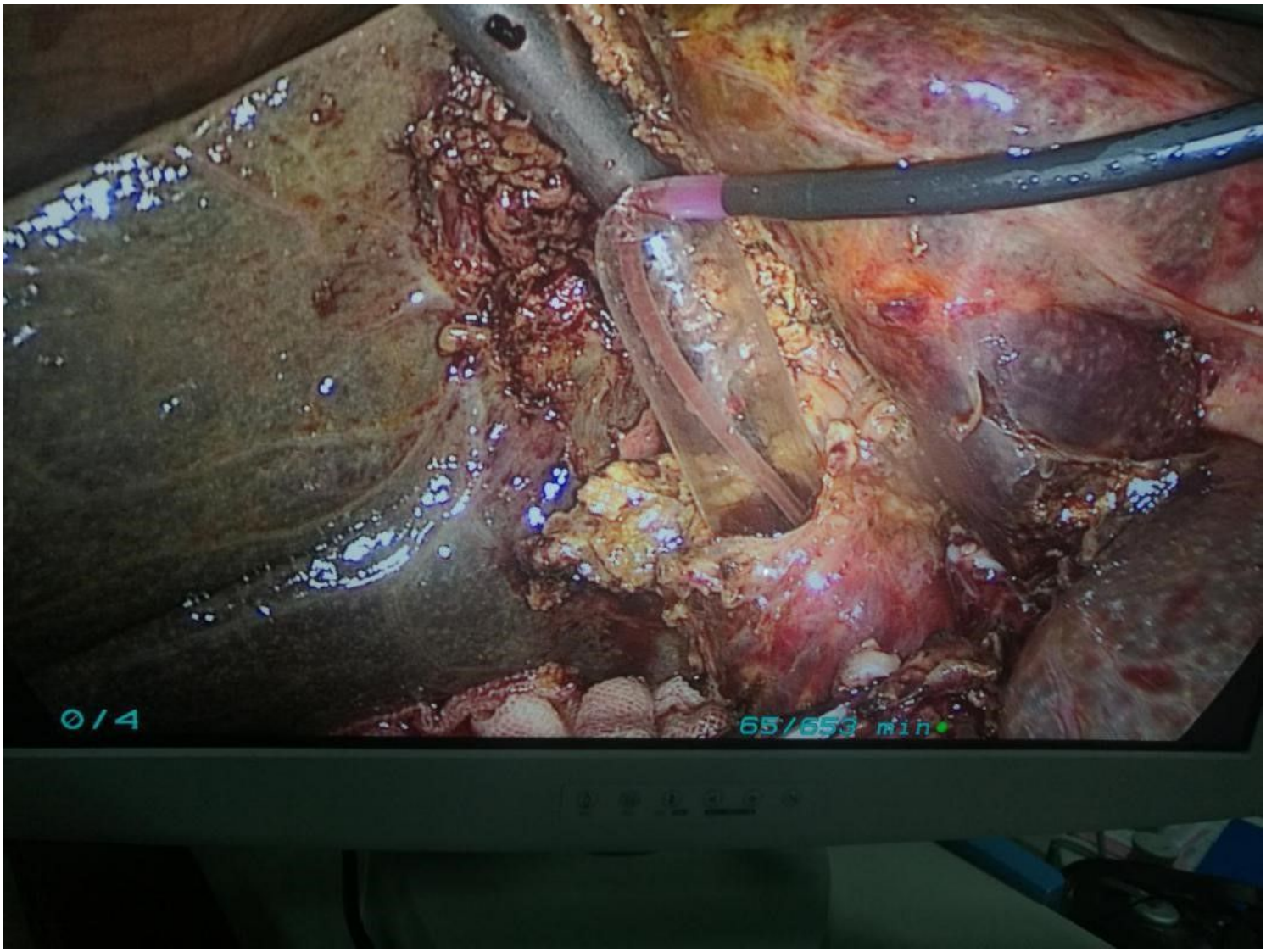

Figure 2

the confluence was dilatated with the columnar dilatation balloon (arrow)

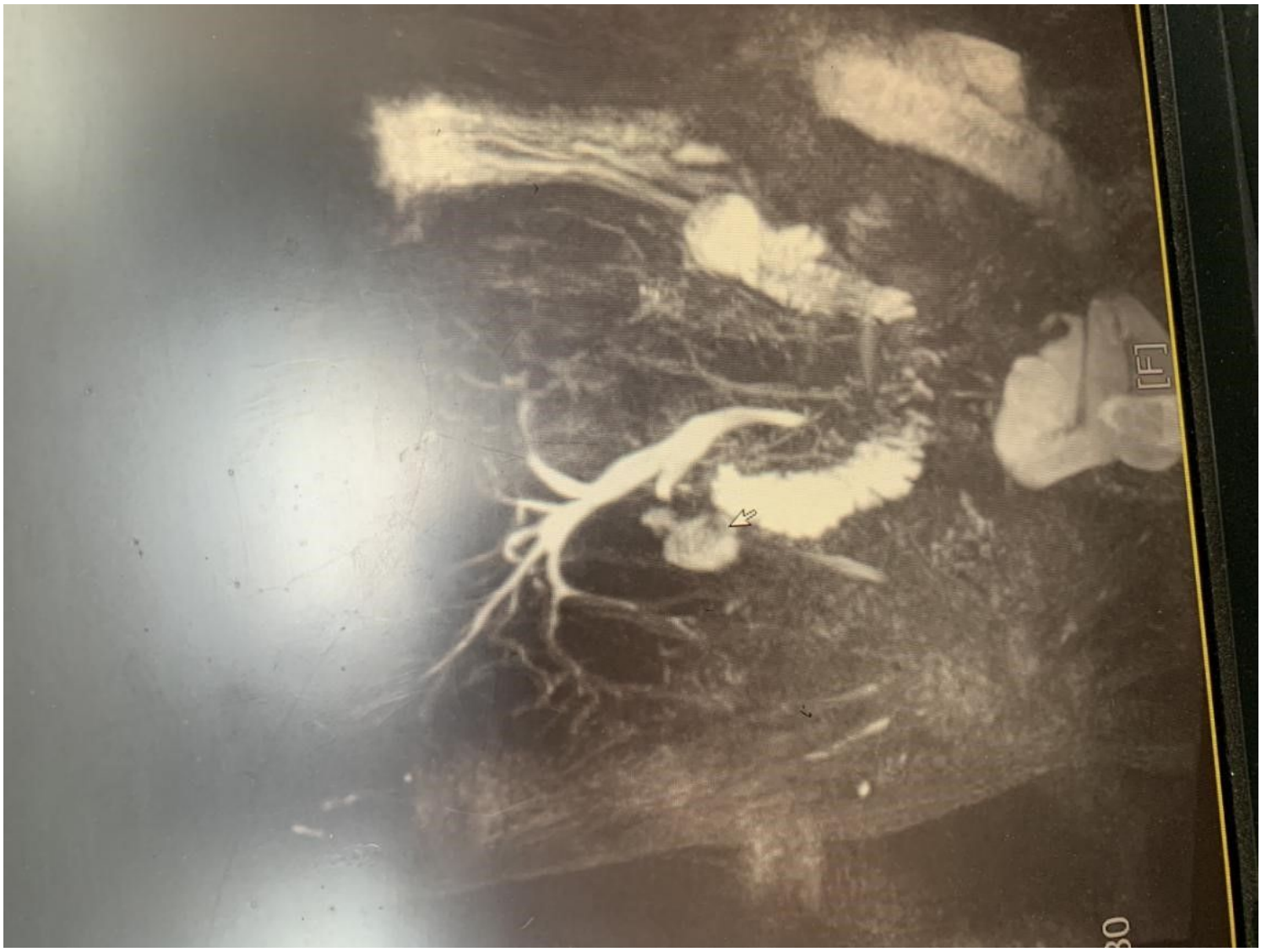

Figure 3

the stump wall of the cystic duct covers the entrance of CBD and close primarily. Postoperative MRCP examination showed good healing (arrow).

Supplementary Files

This is a list of supplementary files associated with this preprint. Click to download.

- video.mp4