

Anterior Spinal Cord Syndrome is a Complication Following Embolisation of Bleeding Intercostal Artery in Penetrating Trauma: A Case Report

Tovi Vo (✉ dr.tovi.vo@gmail.com)

Royal Adelaide Hospital <https://orcid.org/0000-0001-8665-2904>

Daniel Harris

Royal Adelaide Hospital

Ngee Foo

Royal Adelaide Hospital

Daniel Ellis

Royal Adelaide Hospital

Case report

Keywords: Trauma, Haemothorax, Transcatheter arterial embolisation, Intercostal artery, Anterior spinal artery syndrome, Artery of Adamkiewicz, Spinal ischaemia

Posted Date: September 9th, 2020

DOI: <https://doi.org/10.21203/rs.3.rs-73539/v1>

License:   This work is licensed under a Creative Commons Attribution 4.0 International License.

[Read Full License](#)

Abstract

Background:

Transcatheter arterial embolisation of intercostal vessels is a minimally invasive procedure that is increasingly being used in the management of haemothorax in the trauma patient, however significant complications – such as spinal ischaemia can occur. We present a rare case of paralysis in a patient following embolisation of the intercostal arteries due to bleeding from penetrating trauma.

Case presentation:

A 46-year-old male presented to the Emergency department with two stab wounds to the right posterior chest. Computed tomography scan of the chest revealed active contrast extravasation from the right 9th intercostal artery. Selective embolisation of the right 9th intercostal artery using Gelfoam® and coils as well as further embolisation of the 7th, 8th and 10th intercostal arteries was performed. Unfortunately due to ongoing bleeding and hypotension, the patient subsequently required emergency surgery that revealed two penetrating injuries to the right inferior lobe of the lung. After the patient was extubated, he was found to have bilateral motor from the level of L4 and below and sensory deficits from L2 and below. Magnetic resonance imaging of the spine showed spinal cord infarction at the level of T11 and T12 that was thought to be secondary to the embolisation of the intercostal arteries inadvertently affecting the artery of Adamkiewicz.

Conclusions:

Transcatheter arterial embolisation has an established roll in haemostasis of the trauma patient – particularly in intercostal arteries for the management of haemothorax. Although extremely rare, spinal complications from this procedure can be significantly life changing for the patient. The variable anatomy of the artery of Adamkiewicz should be carefully considered on a case-by-base basis in the stable trauma patient and balance of risk versus benefit be determined if the artery is unable to be identified on pre-procedure angiography.

Background:

Transcatheter arterial embolisation (TAE) is a minimally invasive procedure that can be used for haemostasis in bleeding patients (1,2). It is an alternative to surgical management without the associated morbidity and mortality of open surgery and is increasingly being used in the trauma patient (3). Embolisation of intercostal vessels is considered to be a low-risk procedure useful in the treatment of haemothorax and haemoptysis, however significant complications can occur. The great anterior radiculomedullary artery (also known as the artery of Adamkiewicz) is a major artery responsible for the blood supply to the lower spinal cord (4). Due to its high variability in anatomical location and close relation to the intercostal arteries, it can be inadvertently occluded during TAE. We describe a case of paralysis following TAE of a bleeding intercostal artery in penetrating trauma. To date, there have been

three other reported cases of spinal cord ischaemia following intercostal arterial embolisation – and only one case following penetrating trauma (1,5).

Case Presentation:

A 46-year-old previously healthy male presented to the Royal Adelaide Hospital Emergency Department after being stabbed twice with a ten centimetre-long blade. On arrival, heart rate was measured at 135 beats/min with a blood pressure of 116/93mmHg. Respiration rate was 28 breaths/min and oxygen saturation at 94% on 15 litres of oxygen. On examination, there were two small stab wounds to the right posterior chest (one positioned in the mid-posterior trunk and the other more lateral). The initial haemoglobin was 149g/L. Chest X-ray (Figure 1) and focussed assessment with sonography in trauma (FAST) scan confirmed a haemothorax and a 28F intercostal catheter was inserted with initial drainage of 1000mLs of blood. Computed tomography (CT) scan of the chest, abdomen and pelvis showed active contrast extravasation from the right 9th intercostal artery (Figure 2) implying ongoing bleeding.

The patient underwent selective embolisation of the right-sided 9th intercostal artery with a combination of Gelfoam® (Pharmacia & Upjohn Company, Kalamazoo, MI) and metal coils (Figures 3 and 4). Further embolisation of the right 7th, 8th and 10th intercostal arteries was also performed using Gelfoam® alone. Following the procedure, the patient was transferred to the intensive care unit for observation. However, due to ongoing significant haemorrhage (800mls within 25 minutes via chest drain) and progressive hypotension requiring inotropic support, the patient underwent emergency thoracotomy. Intra-operatively, it was discovered that one of the stab wounds had penetrated twice into the inferior lobe of the right lung and was actively bleeding. Haemostasis was achieved using staples and the patient was returned to the ICU following the operation.

Upon extubation on day two, the patient was found to have bilateral motor deficits from level L4 and below and sensory deficits from level L2 and below. Babinski reflex was also not present. Urgent magnetic resonance imaging (MRI) of the spine showed T2 hyper-intensity at level T11 and T12 in keeping with acute infarction of the spinal cord (Figure 5). There was no epidural collection, haematoma or significant spinal canal stenosis. The patient further developed urinary and bowel incontinence which prompted a diagnosis of anterior spinal artery syndrome – likely secondary to the embolisation. The patient was counselled with the diagnosis and prognosis, recovered from the surgery and was transferred to the rehabilitation unit for ongoing treatment. Upon review at six months, the patient was independent with self-catheterisation, bed and wheelchair transfers and receiving ongoing counselling and social supports.

Discussion:

The spinal cord receives blood supply from a single anterior spinal artery and paired posterior spinal arteries. The anterior spinal artery is formed from branches of the vertebral arteries that unite at the level of the foramen magnum (5). As it courses down the anterior median fissure, it is reinforced by several

radicular arteries – the largest being the great anterior radiculomedullary artery. Also known as the artery of Adamkiewicz (AKA), it plays a significant role in the arterial supply of the anterior spinal cord from the level of T8 to the conus medullaris (4). Its origin is highly variable – with the majority (~70%) arising from the T8 to L1 neural foramina from the intercostal or lumbar arteries on the left side (4,5). The AKA makes a characteristic “hairpin” turn as it joins the anterior spinal artery. This morphologic bend enables identification of the artery on radiographic imaging (6).

Occlusion of the AKA typically presents with anterior spinal artery syndrome where there is symmetrical motor dysfunction and spinothalamic sensory deficit below the level of the lesion, as well as autonomic sphincter dysfunction. Identification of the AKA helps reduce the risk of ischaemic spinal complications in vascular and endovascular procedures (4). In a study by Yoshioka et al (6), 30 patients with thoraco-abdominal or descending thoracic aortic aneurysms underwent pre-operative gadolinium-enhanced MR angiography and CT angiography to visualise the AKA. Using the morphologic “hairpin” turn as the diagnostic criteria, the AKA was successfully visualised in 28 of 30 cases with MR angiography and in 25 of 30 cases with CT angiography (6). For our patient, at the time of procedure and on retrospective inspection, the AKA was unable to be identified on CT angiography.

There are several methods of embolisation of vessels. Gelfoam® is a temporary agent derived from purified skin gelatin and is often used in conjunction with permanent agents such as coils (7). The posterior intercostal arteries arise from the thoracic aorta continue to become the spinal branch and then radicular branch which divides into anterior and posterior radicular arteries – both of which join the anterior and posterior spinal arteries respectively (5). Ideally, TAE of intercostal arteries should be performed as distally as possible to reduce the risk of inadvertent embolisation of the spinal branches that lead into the radicular arteries. There have been several reported cases of paralysis following TAE of lumbar and bronchial arteries (8,9) and even less with intercostal arteries (1,5). To our awareness, there has only been one other reported case of paraplegia following embolisation of intercostal arteries in penetrating trauma (5).

In our case, although the AKA was unable to be visualised on CT angiography, the need for urgent embolisation for haemostasis was deemed a necessary lifesaving intervention. Furthermore, the penetrating injury and site of haemorrhage was located near the origin of the posterior intercostal artery and although the AKA is more commonly situated on the left side, TAE of the posterior intercostal arteries likely inadvertently involved the AKA – which for this patient, may have arisen from the right side which is uncommon. This is despite attempts to identify the AKA on pre-embolisation CT angiography. Although it is possible that the cause of the patient’s spinal complication is multifactorial in nature (ie: embolisation of AKA, ongoing hypotension), this case report serves to highlight the importance of understanding the variable anatomy of the AKA. Consideration of haemostasis via endovascular methods or open surgery should continue to be evaluated on a case-by-case basis in the management of intercostal arterial bleeding in the stable trauma patient.

Conclusion:

TAE of intercostal arteries is a minimally invasive procedure with an established role in haemostasis in the bleeding trauma patient. However, spinal complications from this procedure can be life-changing for the patient – both physically and mentally. The variable anatomy of the AKA should be carefully considered in the stable trauma patient and balance of risk versus benefit be determined if the artery is unable to be identified on pre-procedure angiography.

List Of Abbreviations:

AKA – Artery of Adamkiewicz

CT – Computed Tomography

FAST – Focussed Assessment with Sonography in Trauma

MRI – Magnetic Resonance Imaging

TAE – Transcatheter Arterial Embolisation

Declarations:

Ethics approval and consent to participate:

Not applicable.

Consent for publication:

Verbal and written consent has been obtained from the patient for use of images and publication of this case report.

Availability of data and materials:

Not applicable.

Competing interests:

The authors declare that they have no competing interests.

Funding:

No funding was obtained for this case report.

Authors' contributions:

TV (corresponding author) – reviewed the patient case, images and results, performed the literature review and wrote the manuscript

DH – was a major contributor in writing the manuscript

NF – was a major contributor in writing the manuscript

DE – was a major contributor in writing the manuscript

Acknowledgements:

Not applicable

References:

1. Lucocq J, Sinnerton R, Porter DJ. *Intercostal artery embolization in blunt trauma – a case report and review of the literature*. WJPMR 2019;5(11):146-149
2. Chen RB, Hu HJ, Matro E. *Transcatheter arterial embolization for intercostal arterial bleeding in a patient after chest tube insertion*. J Thorac Dis 2015 Jul;7(7):E194-E197
3. Zealley IA, Chakraverty S. *The role of interventional radiology in trauma*. 2010;340:c497.
4. Tattera D, Skinningsrud B, Pekala PA, Hsieh WC, Cirocchi R, Walocha JA, Tubbs RS, Tomaszewski KA, Henry BM. *Artery of Adamkiewicz: a meta-analysis of anatomical characteristics*. 2019; 61(8): 869–880.
5. Ozoilo K, Stein M. *Paraplegia complicating embolization for bleeding intercostal artery in penetrating trauma*. Injury 2013 sept;44(8):70-73
6. Yoshioka K, Niinuma H, Ehara S, Nakajima T, Nakamura M, Kawazoe K. *MR angiography and CT angiography of the Artery of Adamkiewicz: State of the Art*. 2006;26:S63-S73
7. Lopera J. *Embolization in Trauma: Principles and Techniques*. Semin Intervent Radiol. 2010 Mar;27(1):14-28
8. Balasubramanian S, Thind G, Krishnan S. *Anterior spinal cord infarction complicating bronchial artery embolization in a patient with massive haemoptysis*. 2019;156(4):A1925
9. Eltorai IM. *Bronchial artery embolization (BAE) for severe haemoptysis*. Rare Diseases and Syndromes of the Spinal Cord. 2016, pp117-118

Figures

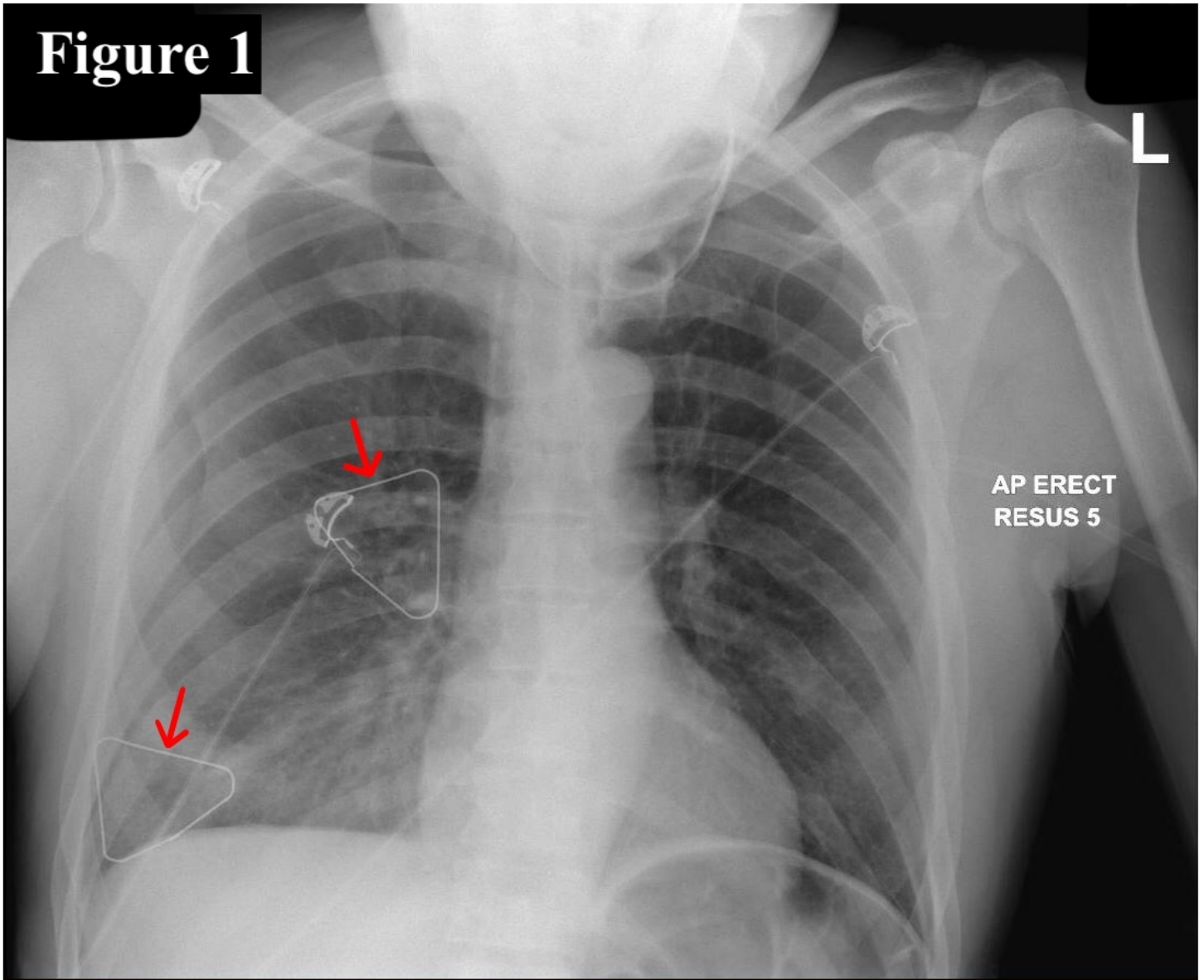


Figure 1

Chest X-ray with radiological markers indicating the two stab wounds on the right posterior chest wall.

Figure 2

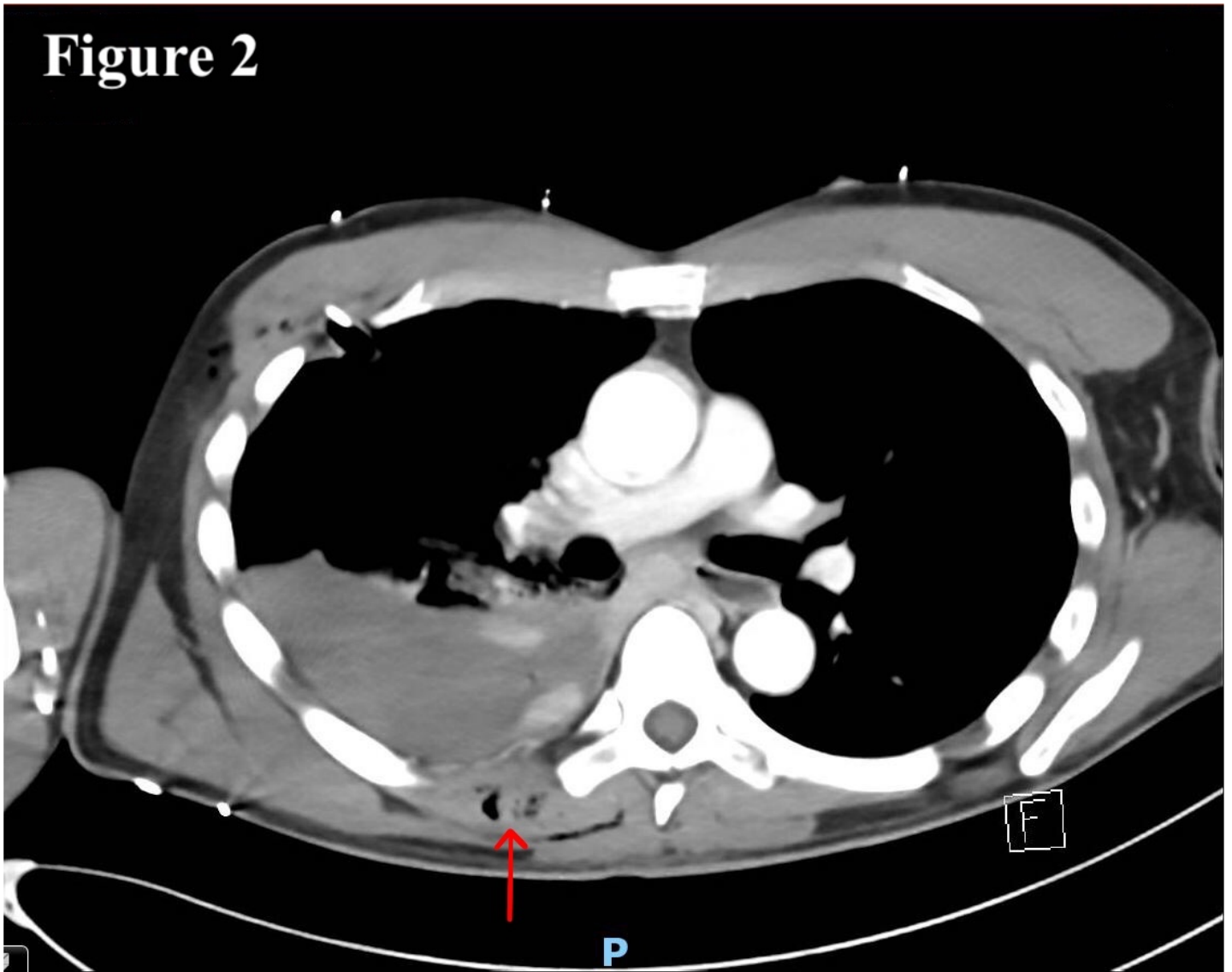


Figure 2

CT scan showing haemothorax and active extravasation of contrast. The arrow indicates the entry point of the more medial penetrating wound near the origin of the posterior intercostal arteries.

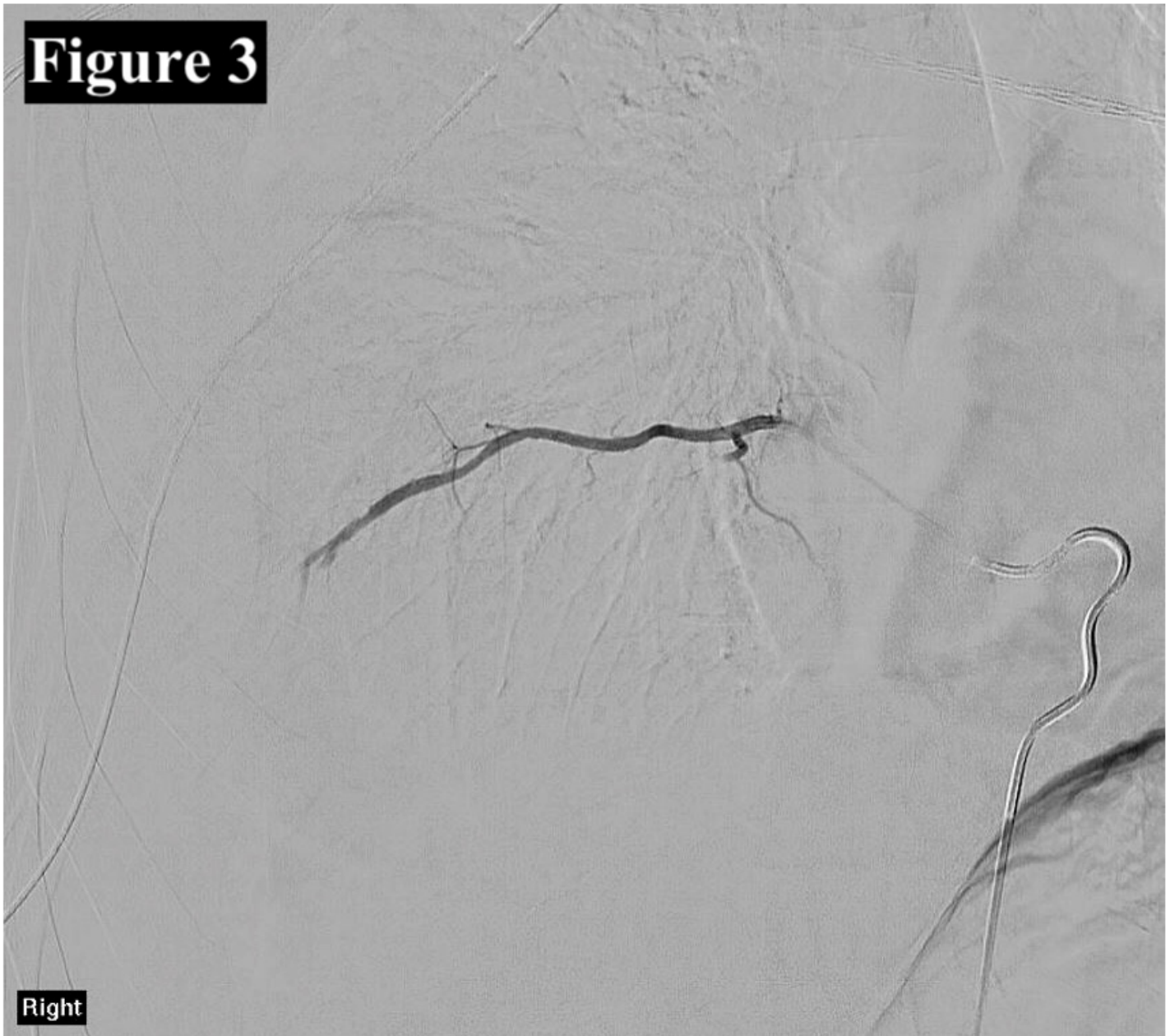

Figure 3

CT angiography of the right 9th intercostal artery prior to embolization.

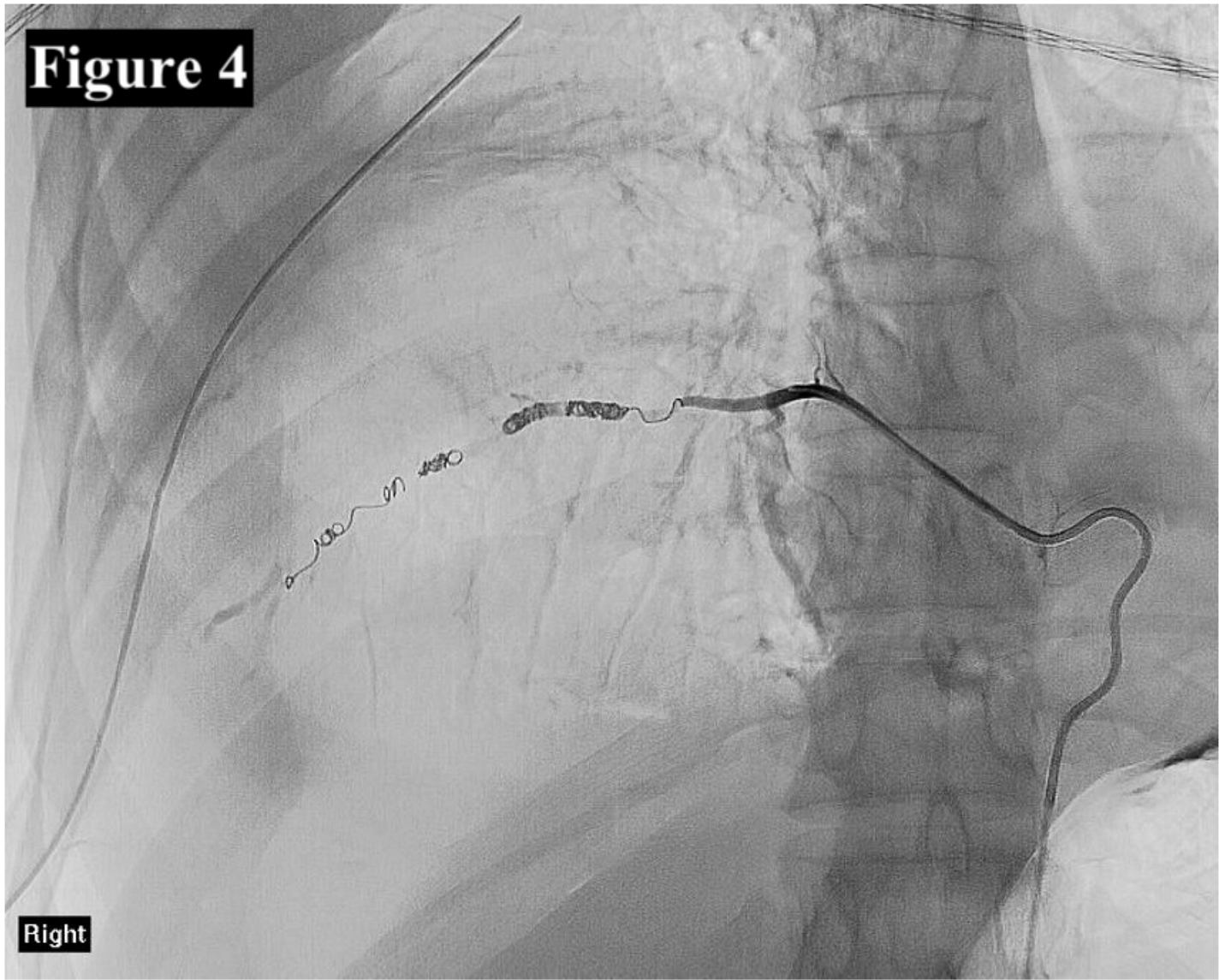


Figure 4

CT angiography of the right 9th intercostal artery after embolization with Gelfoam® and coils.

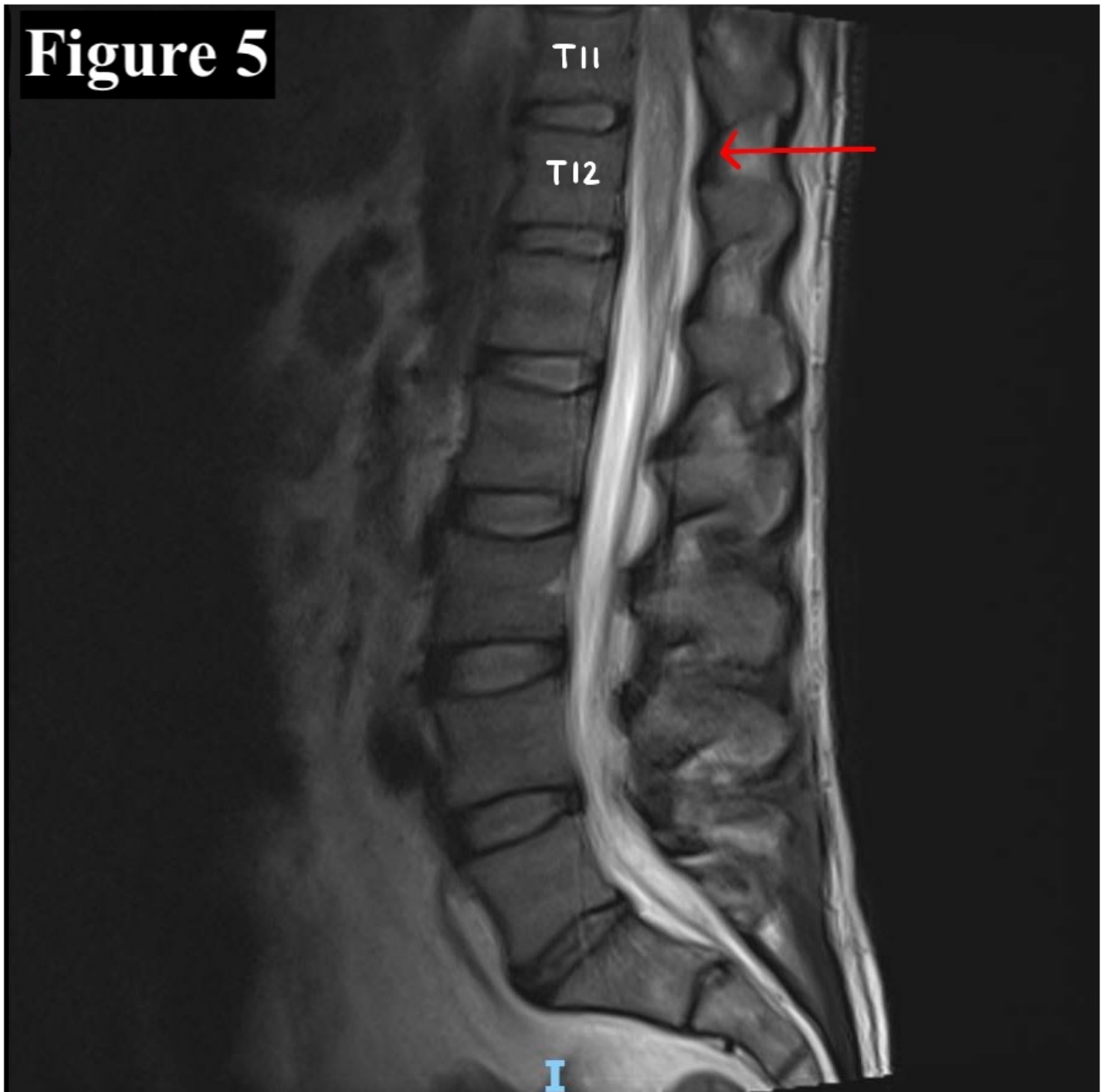


Figure 5

MRI spine showing T2 hyper-intensity at the level of T11 and T12 indicative of spinal infarction.