Retrograde Surgical Cut-down Direct Thrombectomy as a Salvage Procedure for Acute Limb Ischemia With Below the Knee Thrombotic Occlusion: a Case Series

Ying-Sheng Li (fishandchips0612@gmail.com)
Chang Gung Memorial Hospital Linkou Main Branch: Chang Gung Memorial Hospital
https://orcid.org/0000-0002-8329-7465

Ying-Ching Li
Chang Gung Memorial Hospital Linkou Main Branch: Chang Gung Memorial Hospital

---

Case report

Keywords: Acute limb ischemia, retrograde surgical thrombectomy, open thrombectomy

Posted Date: July 28th, 2021

DOI: https://doi.org/10.21203/rs.3.rs-739661/v1

Abstract

Background: Acute limb ischemia is a serious condition even in an era of highly comprehensive medical treatment. Despite the development of conservative and endovascular treatment, complete removal of the thrombus with antegrade thrombectomy via the femoral approach, especially in below-the-knee arteries, is still not possible. In addition, distal embolization of dislodged debris or thrombus during the procedure is another concern as this might cause severe complications, including amputation. Given the above-mentioned issues, retrograde surgical cut-down direct thrombectomy from the dorsalis pedis artery and posterior tibial artery could be an optimal option for complete revascularization in below-the-knee arteries.

Case presentation: We present five cases where the limbs were preserved after retrograde surgical thrombectomy. The standard antegrade thrombectomy procedure with a conventional surgical approach from the common femoral artery was performed. All five patients underwent an intraoperative assessment of indications for dorsalis pedis artery and posterior tibial artery retrograde thrombectomy by the surgical cut-down method. After retrograde thrombectomy, direct evaluation of blood flow was the strongest evidence of revascularization. A retrograde angiogram showed revascularization of below-the-knee arteries. All five patients had successful salvage procedures that prevented major limb amputation.

Conclusion: Retrograde surgical thrombectomy could be a salvage procedure for incomplete antegrade thrombectomy.

Background

Acute limb ischemia (ALI) is a limb-threatening disease that has a poor prognosis if quick and appropriate treatment is not administered [1–3]. Treatment includes conventional surgical thrombectomy, bypass, and endovascular revascularization, or a hybrid procedure [2, 4–6]. However, the amputation rate has remained high at approximately 5 % to 12 % [4, 6]. Aside from delayed diagnosis and treatment, another reason for a poor outcome is the incomplete restoration of perfusion in below-the-knee (BTK) arteries mostly induced by propagation of the thrombi, which are difficult to remove via an antegrade approach from the common femoral artery (CFA) [6–8]. The retrograde approach with surgical cut-down is a novel and effective option for limb salvage. Here, we present five cases of ALI that underwent an emergency operation with incomplete antegrade thrombectomy followed by successful retrograde thrombectomy. All five patients' legs, which could have undergone major amputation, were preserved.

Case Presentation

The characteristics of the five cases are summarized in Table 1.

Table 1: Patient characteristics.

Patient number	Rutherford stage	Age	Possible cause of ALI	Retrograde artery approach	Balloon angioplasty	Fasciotomy	Amputation
1	IIb	64	Af, PAD	DPA/PTA	yes	no	no
2	IIb	62	aorta mural thrombus	DPA/PTA	no	no	minor
3	IIa	94	PAD	DPA	yes	no	no
4	IIa	85	Af	DPA/PTA	no	no	no
5	IIb	41	aorta mural thrombus	DPA/PTA	no	no	no
ALI: Acute limb ischemia; PAD: Peripheral artery disease; PTA: posterior tibial artery; DPA: Dorsalis pedis artery, Af: Atrial fibrillation							

Patient 1

A 62-year-old male patient with nasopharyngeal carcinoma, who was under radiation therapy, was admitted to the emergency room due to sudden onset left whole leg numbness with weakness. The patient was a heavy smoker. The problem was initially considered as a stroke, and treatment was delayed beyond the ideal time. Upon consultation, cyanotic changes were found on the left first and second toes, which progressed to the sole near the ankle. While electrocardiography showed normal sinus rhythm, computed tomography angiography (CTA) revealed a mural thrombus in the distal aorta and an occlusion over the left iliac artery to the proximal superficial femoral artery (SFA) (Fig. 1). There was no flow recanalization on the BTK arteries.

The patient underwent an emergency open thrombectomy. Under general anaesthesia and before we performed a left CFA cutdown, routine bedside sonography showed a thrombus in the distal anterior tibial artery (ATA) and posterior tibial artery (PTA). We first performed a thrombectomy proximal to the aorta with a python over-the-wire embolectomy catheter. Then, we passed the guidewire anterogradely as far as possible to the tibioperoneal (TP) trunk, performed thrombectomy again, and removed as much distal thrombus as we could. However, antegrade angiography revealed a residual thrombus distally and an occlusion over the proximal ATA and distal PTA (Fig. 2). We used the surgical cut-down approach on the dorsalis pedis artery (DPA) and PTA and performed retrograde thrombectomy via a 3F Fogarty catheter under a 0.035 inch guidewire support. After successful revascularization, pulses were detected in both the DPA and PTA. The wound was closed layer by layer after final retrograde angiography showed no specific stenotic lesion that needed to be treated (Fig. 3).

Within the post-operation period, reperfusion injury occurred, which was treated with hydration and acidosis correction. Though fasciotomy is avoided in this hospital, transmetatarsal amputation was performed on the left foot in the outpatient clinic due to the development of dry gangrene. The patient was treated with oral aspirin (100 mg once daily), cilostazol (50 mg twice a day), and rivaroxaban (2.5mg twice daily). Major amputation was prevented, and the patient can now walk by himself.

Patient 2

A 64-year-old male patient presented with right acute chronic leg ischemia during hospitalization for a chronic ulcer deep into the bone. He had multiple comorbidities, including diabetes, hypertension, atrial fibrillation, and peripheral artery disease (PAD). The patient was under treatment with dual antiplatelet drugs and rivaroxaban and had right-sided paraplegia due to a previous stroke and being bedridden for a long time. The patient previously underwent right SFA stent deployment for treatment of PAD. Duplex ultrasonography (DUS) showed occlusion of the popliteal artery without distal flow, with calcification of the vessels, and the patient was immediately treated with catheter-directed thrombolysis but it was unsuccessful. CTA showed the catheter landing over the popliteal artery without distal recanalization. Owing to the failure of the endovascular method, emergency surgery was performed under general anaesthesia. We anterogradely approached the popliteal artery via the CFA cut-down method. Using a python over-the-wire embolectomy catheter, we inserted the 0.035 inch guidewire into the popliteal artery and removed the thrombus, but it failed to pass through the TP trunk. Due to the risk of distal embolism and vessel trauma, we shifted our procedure into a retrograde approach with surgical cut-down to the DPA and distal PTA.

After successfully passing the 0.035 in and 0.018 in guidewires through the popliteal artery proximally, retrograde thrombectomy with a 2F Fogarty catheter was performed followed by balloon angioplasty. A 5-mm balloon (Pacific™ Xtreme) was applied over the popliteal artery and a 3-mm balloon over the ATA and PTA. Final angiography via the DPA retrogradely showed recanalization of the ATA to the TP trunk and PTA. After the surgery, the patient’s right limb was salvaged, and he was treated for the chronic wound. Major amputation was avoided, and the wound healed gradually without progression. The patient was treated with dual-antiplatelet drugs (aspirin 100 mg and clopidogrel 75 mg once daily) and rivaroxaban (2.5mg twice daily) and his PAD was closely monitored at our outpatient clinic.

Patient 3

A 94-year-old male patient complained of a cold and numb right leg for four days. The patient’s medical history showed diabetes and PAD. After admission, DUS showed right TP trunk thrombotic occlusion with monophasic distal flow gain. An emergency operation was performed under intravenous general anaesthesia with local anaesthesia due to the high-risk nature of the surgery. The initial approach was the femoral cut-down method followed by antegrade thrombectomy. After thrombus removal and balloon angioplasty over the TP trunk and ATA orifice, a complete angiogram showed recanalization of the ATA and PTA but with a poor flow rate. Bedside sonography showed no obvious pulsation in the DPA, while there was a pulse in the PTA. We performed retrograde surgical thrombectomy from the DPA. After

arteriotomy, thrombectomy was performed using a 2F Fogarty catheter under the support of a 0.035 inch guidewire passing from the DPA to the distal SFA. Angiography showed successful revascularization, and the wound was closed layer by layer. The symptoms were relieved, and the patient was discharged on postoperative day 12. Aspirin (100 mg once daily) and clopidogrel (75 mg) were prescribed for PAD. We also prescribed rivaroxaban (2.5mg twice daily) to prevent thrombus formation. The patient underwent routine follow-up in our outpatient clinic.

Patient 4

An 85-year-old female patient had colon cancer with carcinomatosis. The medical history showed hypertension, chronic kidney disease, and atrial fibrillation. The patient was also a heavy smoker and had developed severe claudication of the right leg two weeks ago, which progressed to numbness, coldness, and cyanosis. CTA revealed thrombosis occluding the right iliac artery, CFA, SFA, and TP trunk. The orifice of the ATA was occluded, and there was poor recanalization of the distal PTA from the peroneal artery. The patient underwent an emergency operation under general anaesthesia. Our routine procedure was a femoral cut-down method and thrombectomy via python over-the-wire embolectomy catheter. The residual thrombus in ATA and TP was also difficult to remove anterogradely, as evidenced by the intraoperative angiogram showing a static contrast medium in the proximal PTA and slower flow rate in the ATA.

We performed a direct cut-down to approach the DPA and distal PTA followed by retrograde thrombectomy with a 2F Fogarty catheter to regain the flow. Balloon angioplasty was performed for the ATA orifice and proximal PTA due to stenosis. Complete angiography revealed successful revascularization with no residual embolus from the left SFA to the left crural arteries. The patient was discharged on postoperative day 10 after the surgical wound healed. The patient was prescribed oral aspirin (100 mg once daily) and clopidogrel (75 mg once daily) in the first three months and was then shifted to clopidogrel alone. Rivaroxaban (15mg once daily) was given for atrial fibrillation. The patient died a year later due to the progression of her cancer.

Patient 5

The patient was a 41-year-old male with PAD status post right BTK amputation due to ALI two years ago. He was a heavy smoker, and the medical record revealed hypertension and coronary artery disease post coronary artery bypass graft. This time the patient complained of resting pain with cyanotic change over the left leg. Due to the medical history, immediate CTA was performed, which showed left iliac artery occlusion and thrombotic occlusion of the distal SFA. A mural thrombus in the distal aorta, which could be the cause, was detected. The patient underwent an emergency operation with general anaesthesia. Left CFA was approached via the surgical cut-down method. Proximal and distal thrombectomy was performed, followed by an angiography showing recanalization and narrowing of the BTK arteries. Three hours after the operation, there was still no relief from the resting pain and no improvement of cyanosis. Repeat surgery was performed.

Using the same procedure, we removed the proximal and distal thrombus first. This time, bedside sonography was performed to make sure that there was no flow and pulsation in the distal PTA and DPA with vessel collapse. Embolism occlusion in three arteries between the knee and ankle was suspected. Using retrograde surgical thrombectomy, the residual thrombus was removed from the PTA and ATA, and pulsation was regained. Final retrograde angiography showed strong flow and successful revascularization of BTK arteries. The patient was closely monitored for necessary fasciotomy in the intensive care unit. Muscle strength was regained in two days. Tightness and tension improved gradually on postoperative day 5. He was discharged on postoperative day 10 and was treated with oral aspirin (100 mg once daily) and clopidogrel (75 mg once daily). The left leg was salvaged by retrograde thrombectomy and the patient is currently being followed up at the outpatient clinic.

Discussion And Conclusions

ALI is a critical medical condition due to embolic ischemia or thrombotic occlusion [1]. The incidence is approximately 1.5 cases per 10 000 persons per year. Despite prompt surgery and advancements in techniques, there are still poor outcomes. Within 30 days post-operation, 15 % of ALI cases result in amputation. The mortality rate in one year is approximately 20 % [4, 6].

Immediate diagnosis and rapid revascularization are important, but incomplete restoration of perfusion should always be considered, especially in BTK arteries. It is difficult to completely remove the thrombus present within the tibial artery, where the embolectomy catheter or guidewire cannot pass through easily, or there is propagation of the thrombi related to the thrombectomy causing a poor outcome [7–9].

Conventional open thrombectomy or endovascular intervention cannot always completely remove thromboembolism [8]. Up to 30 % of procedures may demonstrate residual thrombus in a large fraction of vessels on an angiogram. The essential step is the advancement and crossing of the guidewire through the lesion. It should be performed carefully without causing an intimal flap. However, procedural failure occurs in up to 20 % of the cases, even when performed by experienced surgeons [9].

Retrograde surgical cut-down direct thrombectomy could be an effective method to deal with this problem, especially when the embolic lesion is found in BTK arteries. The indications for our proposed technique include the following: 1) failure of guidewire passage into BTK arteries, 2) incomplete revascularization with a poor flow rate of ATA and PTA on angiogram, 3) no flow detected by intraoperative bedside sonography after revascularization, and 4) thrombotic occlusion of BTK arteries documented by preoperative sonography. The five patients presented here all had one or more of the indications mentioned above.

Figure 4 shows the procedural details of this approach. First, we used antegrade thrombectomy with a conventional surgical approach from CFA. This is considered the best method for removal of a large thrombus in ALI [6, 7]. After antegrade thrombectomy, all patients received an intraoperative assessment. Retrograde thrombectomy by the surgical cut-down method was indicated if any criteria matched. Then, direct re-anastomosis of CFA was done. Second, one or both DPA and PTA dissection was performed,

followed by arteriotomy. A 2F Fogarty catheter was used for embolectomy with guidewire support. Direct evaluation of the blood flow was the strongest evidence of revascularization. Then, a retrograde angiogram provided us the whole picture of BTK arteries, indicating whether there were residual thrombi or stenotic lesions, which may need balloon angioplasty. After we finished re-anastomosis of the DPA and PTA, complete angiography was performed as a final check.

Although the development of endovascular treatment showed evidence of good outcomes in BTK thrombotic occlusion even with a retrograde method [6, 7, 10, 11], we considered direct surgical thrombectomy for ALI as the better treatment. Aside from the optimal assessment of blood flow, the endovascular approach could not remove the thrombus completely as with open surgery. The residual thrombus might become a distal embolic occlusion, which may increase the risk for amputation or may adhere to the vessel wall after balloon angioplasty, which could be a risk for critical limb-threatening ischemia. There was no better way other than direct removal of the thrombus.

In conclusion, retrograde surgical thrombectomy could be a salvage procedure for incomplete antegrade thrombectomy. In the five cases presented here, the limbs of the patients were successfully salvaged after the combination of antegrade and retrograde thrombectomy.

Abbreviations

ALI: acute limb ischemia; BTK: below-the-knee; CFA: common femoral artery; SFA: superficial femoral artery; PAD: peripheral artery disease; DUS: duplex ultrasonography; CTA: computed tomography angiography; PTA: posterior tibial artery; TP: tibioperoneal; ATA: anterior tibial artery; DPA: dorsalis pedis artery

Declarations

Ethics approval and consent to participate

Our patient’s medical record review was approved by the Institutional Review Board of the Chang Gung Memorial Hospital. Our patients were fully informed about the nature of this report, and Informed Consent forms were signed by our patients.

Consent for publication

Our patients were fully informed about the publication, and Informed Consent forms were signed by our patients.

Availability of data and materials

Data sharing is not applicable to this article as no datasets were generated or analysed during the current study.

Competing interests

The authors declare that they have no competing interests.

Funding

None.

Authors' contributions

YS-Li, the corresponding author and the first author, served as the director of the case report and the writer of the article. YC-Li, the second author, is a resident physician who cared for the patients, provided conceptual guidance, and helped collect references for this article. All authors have read and approved the final manuscript.

Acknowledgements

Not applicable.

References

1. Creager MA, Kaufman JA, Conte MS. Clinical practice. Acute limb ischemia. N Engl J Med. 2012;366:2198-206.
2. Fukuda I, Chiyoya M, Taniguchi S, Fukuda W. Acute limb ischemia: contemporary approach. Gen Thorac Cardiovasc Surg. 2015;63:540-8.
3. Obara H, Matsubara K, Kitagawa Y. Acute Limb Ischemia. Ann Vasc Dis. 2018;11:443-8.
4. Baril DT, Ghosh K, Rosen AB. Trends in the incidence, treatment, and outcomes of acute lower extremity ischemia in the United States Medicare population. J Vasc Surg. 2014;60:669-77.e2.
5. Kempe K, Starr B, Stafford JM, Islam A, Mooney A, Lagergren E, et al. Results of surgical management of acute thromboembolic lower extremity ischemia. J Vasc Surg. 2014;60:702-7.
6. de Donato G, Setacci F, Sirignano P, Galzerano G, Massaroni R, Setacci C. The combination of surgical embolectomy and endovascular techniques may improve outcomes of patients with acute lower limb ischemia. J Vasc Surg. 2014;59:729-36.
7. Cho S, Lee SH, Joh JH. Complete Revascularization of Acute Limb Ischemia With Distal Pedal Access. Vasc Endovascular Surg. 2020;54:69-74.
8. Hill SL, Donato AT. The simple Fogarty embolectomy: an operation of the past. Am Surg. 1994;60:907-11.
9. Adam DJ, Beard JD, Cleveland T, Bell J, Bradbury AW, Forbes JF, et al. Bypass versus angioplasty in severe ischaemia of the leg (BASIL): multicentre, randomised controlled trial. Lancet. 2005;366:1925-34.

10. Davis FM, Albright J, Gallagher KA, Gurm HS, Koenig GC, Schreiber T, et al. Early Outcomes following Endovascular, Open Surgical, and Hybrid Revascularization for Lower Extremity Acute Limb Ischemia. Ann Vasc Surg. 2018;51:106-12.
11. Wang JC, Kim AH, Kashyap VS. Open surgical or endovascular revascularization for acute limb ischemia. J Vasc Surg. 2016;63:270-8.

Figures

Figure 1

Computed tomography angiogram. (A) Occlusion over the left iliac artery and below-the-knee arteries causing acute attack symptoms in Patient 1. (B) In Patient 2, symptoms persisted after catheter-directed thrombolysis was conducted to treat a thrombotic occlusion from the right distal superficial artery to the tibioperoneal trunk.

Figure 2

Intraoperative angiogram. (A) Only the peroneal artery below the knee was patent with occlusion in the orifice of the anterior and posterior tibial arteries before treatment. (B) After antegrade thrombectomy, occlusion was still present in the proximal anterior and distal posterior tibia arteries. This is one of the indications for retrograde surgical cut-down direct thrombectomy.

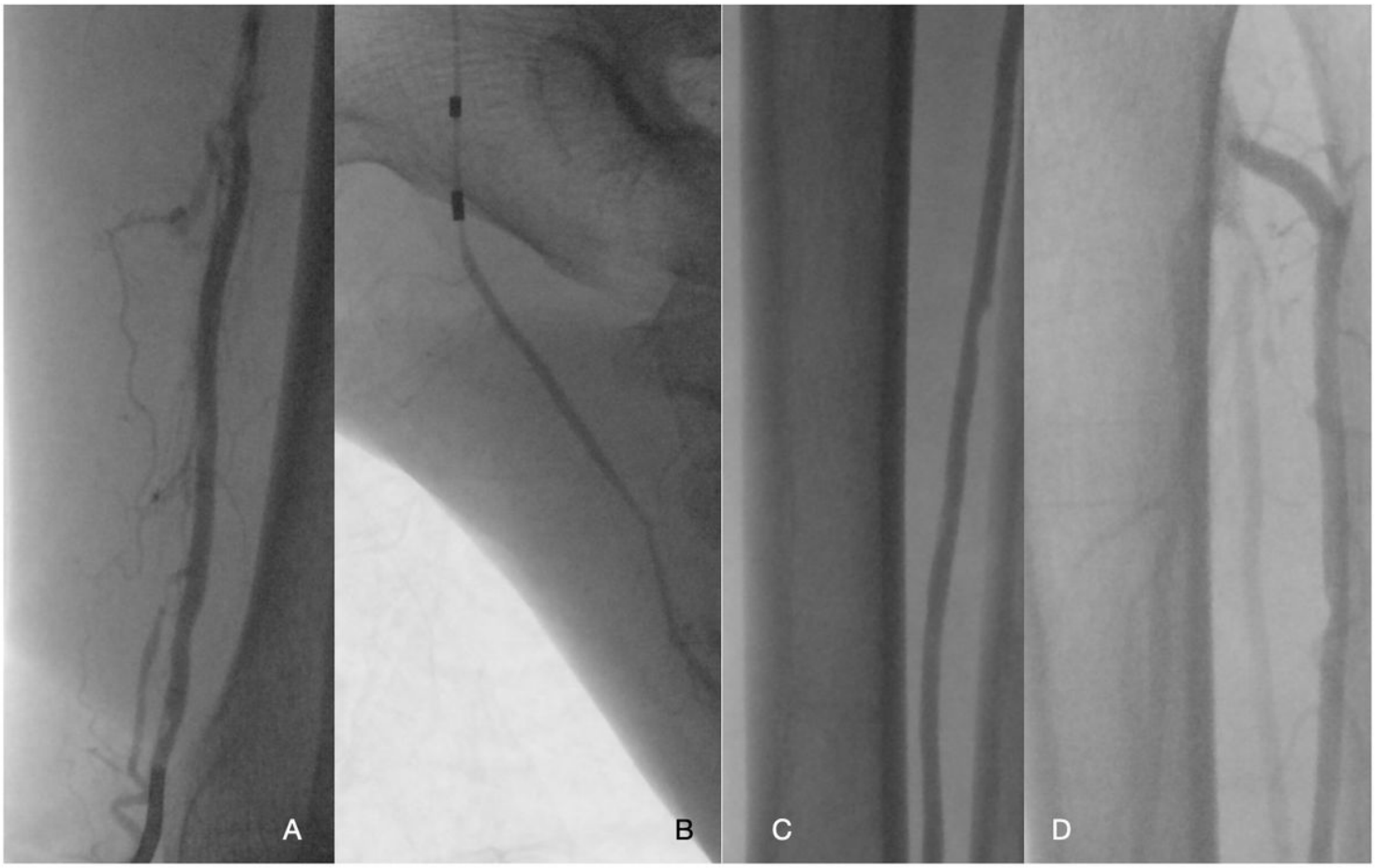

Figure 3

Retrograde angiography performed after retrograde thrombectomy. (A, B) Bi-directional angiograms of the posterior tibia artery and (C, D) the anterior tibial artery were obtained to ensure complete revascularization.

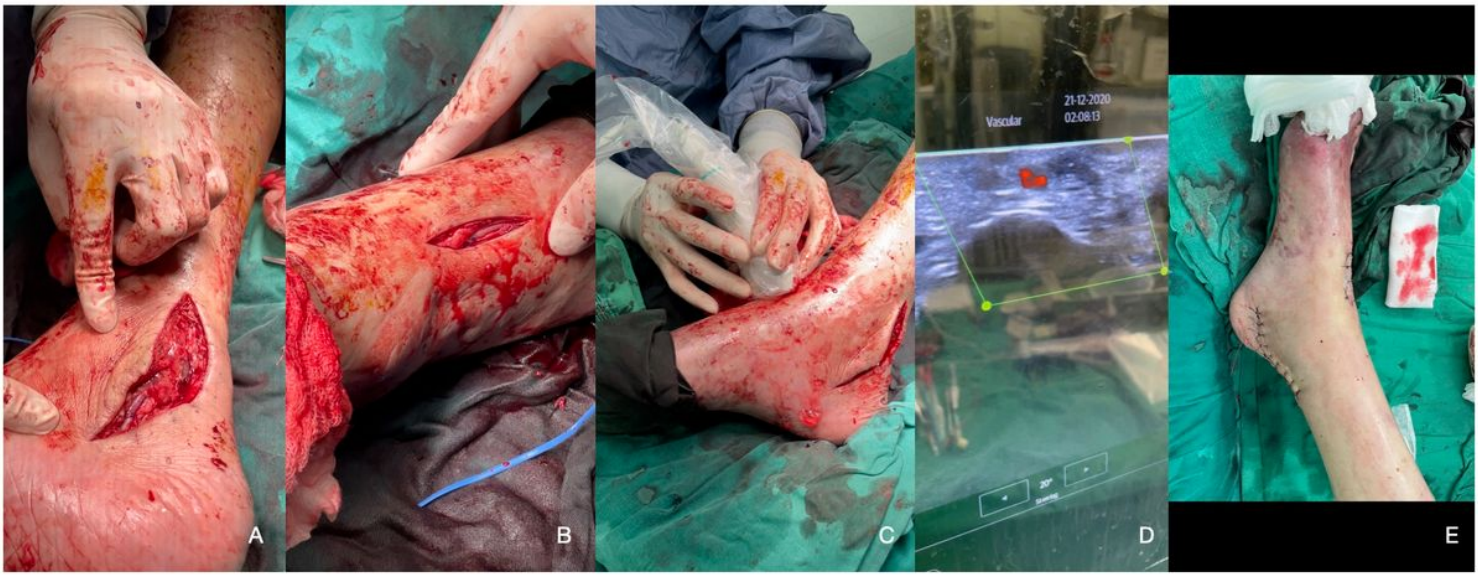

Figure 4

Procedure for retrograde surgical cut-down direct thrombectomy. (A, B) A direct approach is made to the target vessel, such as the dorsalis pedis or posterior tibia artery. (C, D) After open retrograde thrombectomy and re-anastomosis of the vessels, bedside duplex ultrasonography can be used to detect blood flow. (E) Finally, the wound is closed layer by layer.

Supplementary Files

This is a list of supplementary files associated with this preprint. Click to download.

- 221431432nd4.jpg
- 221431432nd5.jpg
- 221431432nd7.jpg
- 221431432nd8.jpg
- CARChecklistEnglish2013.pdf
- IMG0514.mov
- IMG0516.mov
- IMG0517.mov
- renamed281ba.png
- renamedcee62.png