The etiology and prognosis of canalicular laceration repair using canalicular anastomosis combined with bicanalicular stent intubation

Hongwei Wang
Jingjiang people hospital
Xiuhong Qin
Dalian Medical University
Jiali Ji
Shanghai Jiao Tong University
Yang Lu
Shanghai Jiao Tong University
Li Xu
Shanghai Jiao Tong University
Tao Guo
Shanghai Jiao Tong University
Caiwen Xiao
Shanghai Jiao Tong University
Zhenzhen Zhang (zzz1982.happy@163.com)
The Ninth People Hospital, ShangHai Jiao Tong University https://orcid.org/0000-0001-8657-909X

Research article

Keywords: Canalicular lacerations, etiology, prognosis, epiphora

Posted Date: February 24th, 2020

DOI: https://doi.org/10.21203/rs.2.16777/v2

Version of Record: A version of this preprint was published on June 22nd, 2020. See the published version at https://doi.org/10.1186/s12886-020-01506-w.

Abstract

Background: To evaluate the etiology of lacrimal canalicular laceration and explore possible risk factors influencing prognosis.

Methods: A total of 142 patients (142 eyes) with lacrimal canalicular lacerations were reviewed and surgically repaired using canalicular anastomosis combined with bicanalicular stent intubation between March 2017 and March 2018. The analyzed data contained demographic information, the types of trauma, injury locations, associated additional ocular injuries and surgerical outcomes at follow-up. The main outcome measures were anatomic success, functional success, and the complications of surgery.

Results: The mean patient age was 42.07years(ranging from 1-75 years) and 112 (78.87%) were men. Upper and lower canalicular lacerations were found in 14 (9.86%) and 112 patients (78.87%), respectively, and both canalicular lacerations were found in 16 patients (11.27%). Electric bike accidents were the leading cause of injury with 76 patients (53.52%). There were 100 (70.42%) patients who had lid laceration without tarsal plate fracture and 42 (29.58%) patients who had lid laceration with tarsal plate fracture. Anatomic success rate was 98.59%, and functional success rate was 83.8%. Functional reconstruction failure rates were higher in patients with indirect injuries, lid laceration with tarsal plate fracture, and with punctum splitting($P < 0.05$). Surgical Complications were detected in the form of lacrimal punctum ectropion in 3 (2.11%) patients, punctum splitting in 2 (1.41%) patients, stent extrusion and loss in 2 (1.41%) patients.

Conclusions: Electric bike accidents have become the leading cause of injury instead of the motor vehicle accidents because of changes in lifestyle. The indirect injuries, lid laceration with tarsal plate fracture and with punctum splitting, were significantly more likely to lead to a poor prognosis, as comfirmed by the lower functional success rate of surgery.

Background

Canalicular laceration is commonly regarded as ocular emergency, caused by trauma in the eyelids and periorbital areas, frequently involving the lower canaliculus, have been reported in all age groups[1]. They are present in approximately 16% of all eyelid lacerations due to ocular trauma[2]. It has been reported that 72% of lower canaliculus occurs in monocanalicular lacerations and that bicanalicular lacerations occur in 6% to 24% of all canalicular injuries[3]. According to the mechanism of damage, Wulc and Arterberry divided canalicular lacerations into direct trauma like knife and dog bite injuries, and indirect trauma, like blunt trauma, and reported that patients with canalicular lacerations due to indirect or diffuse injuries were more than due to the presence of a penetrating injury[4].

The canaliculus can undergo stenosis, causing lacrimal drainage dysfunction with epiphora if not appropriately managed[5]. The canalicular anastomosis combined with bicanalicular or monocanalicular stent intubation is used for primary canalicular laceration repairs[5]. A variety of materials have been used

to stent the torn canaliculus clinically, such as the medical-grade silicone stent[6,7], such as the Freda silicone tube, the mini-Monoka[8], the Masterka[9]. The mini-Monoka is one of the monocanalicular stents, comprised of a silicon rod with a bulb and collar at the proximal end, which makes it self-retaining[8], Mini-Monoka insertion has its own indications and is suitable for conditions, such as canalicular lacerations, involving the external two-thirds of one canaliculus without damaging the canthal ligament. The silicone intubation was most commonly used in surgery based on its advantage of an inert nature, flexibility, and easy availability[6,7]. Several factors impacting the effectiveness of laceration repair include the extent and location of canalicular laceration, the intubation materials, the duration of intubation, and the surgical technique[10,11,12]. The present study was conducted to review 142 patients with primary canalicular lacerations in the department of Ophthalmology, Shanghai Ninth People's Hospital, China. We described the epidemiology and evaluated the etiology and prognosis of primary canalicular laceration repair using canalicular anastomosis combined with bicanalicular stent intubation.

Methods

Patients

We retrospectively reviewed the medical records of 142 patients (142 eyes) who had primary canalicular lacerations and required surgical repair within 48 hours at the Department of Ophthalmology, Shanghai Ninth People's Hospital, Shanghai JiaoTong University school of Medicine, Shanghai, China, between March 2017 and March 2018. Most of the patients were initially referred to the emergency room, while the others were recruited from clinics. The retrospective study was performed with the approval of the Ethics Committee of Shanghai Ninth People's Hospital, Shanghai JiaoTong University school of Medicine, China. The informed consent and the commitment to follow up were signed by all subjects in our study, including the parents or guardians of the study participants who were minors at the time of study. These patients includes 112 men, 30 women who were 1 to 75 years old (42.07 years on average). Among these 142 patients, 134 received indirect injuries and 8 received direct injuries. Patient demographics, the affected canaliculus, the number of canaliculus injuried, the nature of injury, and associated injuries were obtained through patient records. Exclusion criteria included the lack of adequate follow up(<3months), preinjury epiphora and pyorrhea, additional lacerations involving the lacrimal sac and/or nasolacrimal duct or congential and/or acquired lacrimal stenosis and/or obstruction.

Lacrimal system evaluation

We evaluated the lacrimal system before surgery and estimated whether the lacrimal system was involved when the eyelid laceration was very close to the medial canthus. Further examination of the lacrimal system was done by irrigation of the lacrimal canaliculi with a 2.0mL syringe of 0.9% saline solution under topical anesthesia. If the liquid flowed from the wound, a lacrimal probe was used to confirm the position of the distal lacerated end of the lacrimal canaliculus, and the distance from the lacrimal punctum and then the distal lacerated end was measured.

Surgical procedure

Routine sterilization was provided and infratrochlear and infraorbital nerve block anesthesia were performed with 2 ml 2% lidocaine and 2 ml 0.75% bupivacaine for adults and general anesthesia for pediatric patients. The proximal lacerated ends were found under a surgical microscope (ZEISS, Germany). Then a punctum dilator was used to enlarge the lacrimal punctum and bicanalicular silicone tube intubation was done using a 1.0-mm-diameter silicone tube with a probe at both heads(Shandong Freda Biotechnology Co., Ltd, China) as shown in Figure 1. One head was inserted into the ruptured canaliculus and nasal cavity, while the other end was placed into the upper or lower canaliculus and pulled out from the nasal cavity. The proximal and distal lacerated ends were subsequently anastomosed with 3 pairs of 6–0 absorbable sutures(Johnson Johnson, New Brunswick, NJ) around the silicone tube, and the meticulous re-approximation of the severed canaliculus was performed under an ophthalmic surgical microscope. The two corresponding ends of the silicone tube were tied securely with proper length. If any globe injury occurred, the globe wound repair needed to be performed first before other management. Repairs of additional eyelid injury are conducted at the end of the surgery after the lacrimal intubation. Preoperative and postoperative images of a typical case are provided in Figure 2. All repairs were performed by the same experienced surgeon.

Postoperative management

Antibiotics were simultaneously administrated locally and intravenously to prevent infection. Post-surgery follow-up visits were recorded at 1.0 week and 1.0, 2.0, 3.0, 6.0 months. The silicone tube was shifted and checked monthly and extubation was performed 3 months after surgery followed by lacrimal irrigation. The surgery outcome was defined by lacrimal irrigation and the presence of symptomatic epiphora indoors.

Statistical analysis

Data were presented as mean±SD or *n* patients. The SPSS 22.0 software was used for statistical analysis. The clinical prognosis and surgical effect of canalicular lacerations were compared with Chi Square test. Kaplan-Meier analysis and Cox proportional hazards regression analysis was used to determine risk factors influencing the prognosis of canalicular laceration. All P values were considered statistically significant when the values were < 0.05.

Results

In our study, 112 (78.87%) of the patients were men, and 30 (21.13%) were women. The average age was 42.07 years (ranging from 1-79 years). A total of 88.7% (126) patients had one canaliculus involved. Sixteen patients (11.3%) had 2 canaliculi involved and no patients had 3 or 4 canaliculi involved. The upper and lower canalicular lacerations were found in 14 (9.86%) and 112 patients (78.87%), respectively, and both canalicular lacerations were found in 16 patients (11.27%). The mean time interval between injury and surgery was 14.42±0.36hours (from 3-48hours). The mean time of canalicular stent removal

was 4.5± 0.54months (ranging from 3-6months), and the mean follow-up period was 6.94±0.51months(from 6-9months)(Table 1).

The type of trauma that caused the canalicular lacerations are shown in Table 1. Of all the patients, indirect canalicular injuries were detected in 134 (94.4%) patients, which were remarkably more frequent than direct injuries detected in 8 (5.6%) patients. Electric bike accidents were the leading cause of injury with 76 (53.52%) patients. The other mechanisms of injury were blunt injuries 32 (22.54%) patients, car accidents for 10 (7.04%) patients, fights for 4(2.82%) patients, falls for 12(8.45%) patients, sharp objects for 6(4.22%) patients, and dog bites for 2(1.41%) patients, as shown in Table 1.

Other additional injuries associated with the trauma occurred in all the patients were also represented in Table 1. There were 100 (70.42%) patients who had lid laceration without a tarsal plate fracture and 42 (29.58%) patients with a tarsal plate fracture. Canalicular lacerations combined with globe rupture had occurred in 6 (4.23%) patients of all the additional injuries. Some patients may have experienced 2 or more other additional injuries at the same time, while other injuries associated with the trauma contained 14 (9.86%) extraocular muscle injuries, 10(7.04%) head traumas, 7(4.93%)ptosis, 2(1.41%) optic neuropathies, and 2(1.41%) vitreous and/or retinal detachments(Table 1) .

All the canalicular lacerations were repaired during this study. The mean time of canalicular stent removal was 4.5±0.54months (ranging from 3-6months). During the following-up visits, there was 1 patient with stent extrusion and loss in 1month when he washed face. There was also 1 patient with stent extrusion and loss in 1.5months because of a loose knot and the patient had pulled the suture out. No patients had infections of the lacrimal canaliculi during the visits.

The surgery effects of canalicular lacerations are presented in Table 2. After stent removal, patients were performed irrigation of lacrimal canaliculi, and asked about epiphora during the following-up. All patients 142 patients reflected anatomic success, besides 2 patients with stent extrusion and loss. Among these patients with anatomic success, 119 (83.8%) patients had functional success, claiming no epiphora. As shown in Table 2, among the upper, lower, and both canaliculus laceration repair surgeries, there was no significant difference between the anatomic success rate and functional success rate (P>0.05; P>0.05); the data also showed no siginficant difference in the anatomic success rate between indirect injuries and direct injuries, however, the functional success rate was significantly lower with indirect injuries than with direct injuries(P<0.01); between lacerations with and without tarsal plate fracture, there was no significant difference in anatomic success, whereas the functional success rate was dramatically lower in the latter than the former(P<0.01); and between laceration with and without punctum splitting, no siginficant difference was evident in the anatomic success rate, whereas the functional success rate in the former was significantly lower than the latter (P<0.01). The surgery had a high functional success with fewer complications: we found only 3 (2.11%) patients with lacrimal punctum ectropion, as shown in Figure 3; 2(1.41%) patients with punctum splitting as shown in Figure 4; and no patients had a false path.

The results of the Kaplan-Meier analysis for treatment success are shown in Table 3 and the Cox proportional hazards regression analysis of prognostic factors in canaliculus laceration repair surgery are

also presented. Notably, canalicular laceration with indirect injuries, tarsal plate fracture, and punctum splitting were significantly more likely to have a poor prognosis(P=0.017, 0.036, and 0.045).

Discussion

Canalicular laceration is common in facial trauma and requires early intervention (within 48hours) to restore anatomy and function in the ophthalmology department[4]. Men account for most of the canalicular lacerations or about 78.87% in our study, which was similar to the results of 86% male cases reported by Naik et al[8]. In this study, patients with lower canalicular laceration involvement were the most common (78.87%). Liang et al. reported that 82.9% had lower canalicular lacerations, 11.4% had upper canalicular lacerations, and 5.7% had bicanalicular lacerations in their studies[13]. Lee et al also showed that lower canalicular lacerations occurred in 26 cases (72.1%) and upper canalicular lacerations in 10 (27.8%)[14]. Our data corresponded with the findings of the above studies.

Although the epidemiology of canalicular lacerations had been published in some reports, the types of traumas causing injury were different due to change in lifestyle. In our study, Electric bike accidents became the leading cause of injury, with 76 (53.52%) patients, at least in Shanghai, instead of motor vehicle accidents (35.81%), as in the past[15]. We also found that patients with indirect canalicular injuries were remarkably more prevalent than those with direct injuries, which was similar to the results derived by Wulc and Arterberry[4]. David et al. reported that direct penetrating injuries (54.2%) were more common than avulsive types of injuries due to indirect or diffuse blunt trauma (45.7%) in their study reviewing 236 patients[16]. The reason that the researchers did not receive similar results at this point may be the inequable lifestyles in different countries or cities. For instance, Shanghai is one of the largest cities in China and many people take a long time to work or shop on the road. They need a convenient, cheap, and cost-effective vehicle, so electric bike has replaced motorcycles with the advantages of being inexpensive and providing environmental protection. However, with the increasing number of electric bike, the related rate of accidents is also increasing.

Our studies showed that the rate of patients who had lid lacerations with tarsal plate fracture was 29.58%. As there was no previous data reported on the incidence of tarsal plate fracture during injury, we concluded that lid laceration without tarsal plate fracture was more frequent than that with tarsal plate fracture. In our study, globe rupture occurred in 6 (4.23%) patients. Herzum et al. reported a 20 to 44% incidence rate for globe injury in association with eyelid injuries[2]. These results are quite different from our own. Lee et al. later reported that traumatic hyphema and subconjunctival hemorrhage represent the most frequent associated ocular injuries instead of globe injury[14]. The inconsistency of the results may be due to changes in modes of transportation during the different periods. The maximum speed of Electric bike is not more than 45 kilometers, which is much slower than motorcycles with speed of 90 kilometers, and may cause less serious traffic accidents, reducing the risk of globe injury.

It was believed that the key to a successful surgical repair of canalicular lacerations was to find the proximal lacerated end quickly and precisely[17]. Nevertheless, lacrimal canaliculus anastomosis is no longer a difficult operation with the development of medical practice and the success rate has also increased significantly. Many methods and skills to identify the proximal lacerated end of the canaliculus, such as the pigtail probe[18] ,upper canalicular probing, and injecting a bubble or colored opaque solution, have been shown in previous studies[16,17,19,20]. Silicone intubation[5] was most commonly used in surgery because of its advantage of restoring a normal anatomical pathway to avoid false path. With double-passage canalicular intubation, circular stents using silicone tubes provide good stabilization, and keep the natural location of the medial canthus, maintain the physiological anatomical reposition of the superior and inferior punctum, which prevents the ectropion and laceration of the lower eyelid and inferior punctum, and offer excellent tear drainage[5,6,7]. However, the disadvantages of double-passage canalicular intubation include the irritation symptoms, additional secretion, local bulbar conjunctival infection, which partially resulted from pulling the silicone tube from the nose to the canaliculus[21]. All the canalicular lacerations in our cases were repaired by silicone intubation with successful anastomosis.

Among these patients, 140(98.59%) had anatomic success, while 119 (83.8%) patients had functional success. Kersten and Kulwin described an alternative surgical approach for the repair of canalicular lacerations using silicone tube intubation with a success rate of 96% based on lack of symptomatic epiphora[19]. Liang et al. reported that 91.18% of patients experienced complete success with complete disappearance of epiphora and 8.82% eyes achieved partial success after tube removal[13]. The results of ours were similar to the literatures reported above. Our results showed that the certain factors, namely indirect injuries, lid laceration with tarsal plate fracture, and with lacrimal punctum splitting, lead to the lower functional success rate of surgery, and were the risk factors for canalicular laceration repair surgery; the reason may be the severe scaring surrounding the canaliculus due to the tarsal plate fracture and lacrimal punctum splitting.

Some authors hold that early treatment (9-32hours) is the key to success in canalicular repair[8,22]. Tint et al. showed poor outcome in 6 out of 40 patients with delayed in repair (2-3 days) [22]. Chatterjee et al. reported that 5 patients who even presented between 2 and 4 days since injuries also had a successful outcome after surgery[23]. Our mean time between injury and repair was 14.42$\pm$ 0.36hours (from 3-48hours). The high success rate for canalicular repair may thank to the improvement of surgical technology, medical conditions and the patients themselves for their gradual increasing of medical consciousness.

Conclusions

In conclusions, the reasons for canalicular lacerations have changed because of changes in lifestyle. Electric bike accidents have became the leading cause of injury instead of the motor vehicle accidents, as in the past. Our studies showed that certain factors, namely indirect injuries, lid lacerations with tarsal plate fracture and with punctum splitting, led to the lower functional success rate of surgery, and were the

risk factors for functional reconstruction after canaliculus laceration repair surgery. A key drawback of this study was its retrospective, noncomparative nature; the strengths of the study were the relatively large number of patients participated and the fact that all the surgeries were performed by the same surgeon. However, a larger-scale study of a comparative nature is needed in the future. The results of this study will provide some suggestions for the prognosis of surgerical treatment for canalicular laceration.

Declarations

Acknowledgements

Not applicable.

Abbreviations

The abbreviations are not applicable.

Authors'contributions

Conceived and designed the study: ZZZ, XCW and WHW; Acquisition of data: GT and QXH; Analysis and interpretation of data: JJL; Drafting the manuscript: LY and XL; All authors read and approved the final manscript.

Consent for publication

Written informed consent was obtained from the patients for publication of this article and any accompanying images, written informed consent was also obtained from the patients on the figures to publish their face photos. The parents or guardians of the study participants who were minors at the time of study gave written consent for their personal or clinical details along with any identifying images to be published in this study. A copy of the written consent is available for review by the editor of this journal.

Ethics approval and consent to participate

This study was performed in accordance with the declaration of Helsinki and was approved by the Ethics Committee of the Shanghai Ninth People's Hospital, Shanghai JiaoTong University school of Medicine, Shanghai, China. Written informed consent was obtained from all subjects after the aims and nature of the study were explained to the participants. The parents or guardians of the study participants who were minors at the time of study gave written consent for their particular children to be involved in the study.

Availability of data and materials

The datasets of the current study are available upon request from the co-first author Jiali Ji and the co-correspondence author CaiWen Xiao.

Competing interests

The authors declare no conflict of interest.

Funding

This work was supported by The National Natural Science Foundation of China Grant No.81300779; Zhenzhen Zhang; The Natural Science Foundation of Liaoning Province of China (Grant No.20180550524; Xiuhong Qin); The Foundation of Liaoning Educational Committee (Grant No. LQ2017016; Xiuhong Qin) in collection, analysis, and interpretation of data, and in writing the manuscript.

References

1. Y Bi, G Sui, Q Zhou, et al. Two-step retrograde closed stenting: a novel method for treating canalicular lacerations in Chinese patients. Eye 2013; 27:1275-80.

2. Herzum H, Holle P, Hintschich C. Eyelid injuries: Epidemiological aspects. Ophthalmologe 2001;98:1079-82.

3. Ejstrup R, Wiencke AK, Toft PB. Outcome after repair of concurrent upper and lower canalicular lacerations. Orbit 2014;33:169-72.

4. Wulc AE, Arterberry JF. The pathogenesis of canalicular laceration. Ophthalmology 1991;98:1243-9.

5. Spinelli HM, Shapiro MD, Wei LL, et al. The role of lacrimal intubation in the management of facial trauma and tumor resection. Plast Reconstr Surg 2005;115:1871-6.

6. Walter WL. The use of the pigtail probe for silicone intubation of the injured canaliculus. Ophthalmic Surg 1982;13:488-92.

7. Cho SH, Hyun DW, Kang HJ, et al. A simple new method for identifying the proximal cut end in lower canalicular laceration. Korean J Ophthalmol 2008;22;73-6.

8. Naik MN, Kelapure A, Rath S, Honavar SG. Management of canalicular lacera- tions: epidemiological aspects and experience with mini-Monoka monocanalicular stent. Am J Ophthalmol 2008;145: 375-380.

9. Tavakoli M, Karimi S, Behdad B et al. Traumatic canalicular laceration repair with a new monocanalicular silicone tube. Ophthalmic Plast Reconstr Surg 2017;33:27-30.

10.Chu YC, Wu SY, Tsai YJ, et al. Early versus late canalicular laceration repair outcomes. Am J Ophthalmol 2017;182:155-9.

11.Singh S, Ganguly A, Hardas A, et al. Canalicular laceration: Factors predicting outcome at a tertiary eye care centre. Orbit 2017;

12.Singh M, Gautam N, Ahir N, Kaur M. Is the distance from punctum a factor in the anatomical and functional success of canalicular laceration repairs? Indian J Ophthalmol 2017;36:13-18.

13.Liang X, Lin Y, Wang Z, et al. A modified bicanalicular intubation procedure to repair canalicular lacerations using silicone tubes. Eye (Lond). 2012;26:1542-7.

14.Lee H, Chi M, Park M, Baek S. Effectiveness of canalicular laceration repair using monocanalicular intubation with Monoka tubes. Acta Ophthalmol 2009;87:793-6

15.Bai F, Tao H, Zhang Y, et al. Old canalicular laceration repair: a retrospective study of the curative effects and prognostic factors. Int J Ophthalmol 2017;10: 902-7.

16.Jordan DR, Ziai S, Gilberg SM, Mawn LA. Pathogenesis of canalicular lacerations. Ophthalmic Plast Reconstr Surg 2008;24:394-8.

17.Liu B, Li Y, Long C, et al. Novel air-injection technique to locate the medial cut end of lacerated canaliculus. Br J Ophthalmol 2013; 97:1508-9.

18.Loff HJ, Wobig JL, Dailey RA. The bubble test: an atraumatic method for canalicular laceration repair. Ophthal Plast Reconstr Surg 1996;12:61-4.

19.Wang L, Chen D, Wang Z. New technique for lacrimal system intubation. Am J Ophthalmol 2006; 142:252-8.

20.Kersten RC, Kulwin DR. "One-stitch" canalicular repair. A simplified approach for repair of canalicular laceration. Ophthalmology 1996;103:785-9.

21.Benger RS, Nemet AY. Peripunctal “anchor” suture for securing the silicone bicanalicular stent in the repair of canalicular laceration. Ophthal Plast Reconstr Surg 2008;24:51-3.

22.Tint NL, Alexander P, Cook AE, Leatherbarrow B. Eyelid avulsion repair with bi-canalicular silicone stenting without medial canthal tendon reconstruction. Br J Ophthalmol 2011;95:1389-92.

23.Chatterjee S, Rath S, Roy A, Shrestha E. 20G silicone rod as monocanalicular stent in repair of canalicular lacerations: experience from a tertiary eye care centre. Indian J Ophthalmol 2013;61(10):585-6.

Tables

TABLE 1. Clinical characteristics of patients undergoing Canalicular laceration repair

Variable	Patient numbers	Proportion
Total patients	142	
Mean age	42.07(from1-79 year)	
Males	112	78.87%
Females	30	21.13%
Eye involved	142	
Right	91	64.08%
Left	51	35.92%
Canaliculus involved		
Upper	14	9.86%
Lower	112	78.87%
Both	16	11.27%
Mean time between injury and repair	14.42±0.36(from 3-48hours)	
Mean time of stent removal	4.5±0.54(from 3-6months)	
Mean follow-up period	6.94±0.51(from 6-9months)	
Indirect injuries	134	
Electric bike accidents	76	53.52 %
Blunt injuries	32	22.54 %
Car accidents	10	7.04 %
Falls	12	8.45 %

Fights	4	2.82 %
Direct injuries	8	
Sharp objects	6	4.22%
Dog bites	2	1.41%
Additional injuries		
Lid laceration without tarsal plate fracture	100	70.42%
Lid laceration with tarsal plate fracture	42	29.58%
Lid laceration with lacrimal punctum splitting	6	4.23%
Extraocular muscle injuries	14	9.86%
Head trauma	10	7.04%
Ptosis	7	4.93%
Globe rupture	6	4.23%
Optic neuropathy	2	1.41%
Vitreous and/or retinal detachment	2	1.41%
Surgery complication		
Lacrimal punctum ectropion after surgery	3	2.11 %
Lacrimal punctum splitting after surgery	2	1.41 %
False path	0	0 %
Stent extrusion and loss	2	1.41%

Data presented as mean+SD(range)or *n*(%)

TABLE 2. Outcomes of canaliculus anastomosis and bicanalicular stent intubation.

Parameters	Patients	Anatomic success	Functional success
Canaliculus anastomosis and bicanalicular stent intubation	142	140(98.59%)	119(83.80%)
Upper	13	12(92.31%)	10(83.33(%)
Lower	113	111(98.23%)	96(86.49%)
Upper and lower	16	15(93.75%)	13(86.67%)
P		>0.05	>0.05
Indirect injuries	134	132(98.51%)	101(75.37%)
Direct injuries	8	8(100%)	7(87.5%)
P		>0.05	<0.01
Additional injuries			
Lid laceration without tarsal plate fracture	100	99(99%)	78(78%)
Lid laceration with tarsal plate fracture	42	41(97.62%)	30(71.43%)
P		>0.05	<0.01
Lid laceration without lacrimal punctum splittting	136	134(98.53%)	105(77.21%)
Lid laceration with lacrimal punctum splittting	6	6(100%)	3(50%)
P		>0.05	<0.01

TABLE 3. Cox proportional hazards regression analysia of risk factors for the canalicular lacerations.

Risk factors	Hazard ratio(95% CI)	Statistical signifiance
Canaliculus involved	0.973 (0.901, 1.046)	NS
Indirect injuries	1.062 (1.005, 1.097) 0.641(0.157, 0.965)	P=0.017
Lid laceration with tarsal plate fracture	32.783(1.091, 2475.563)	P=0.036
Lid laceration with lacrimal punctum splitting	1.371(0.255, 6.478)	P=0.045
Globe rupture		NS

Data are based on 142 Chinese patients with lacrimal laceration

CI, confidence interval.

NS, not statistically significant(P≥0.05).

Figures

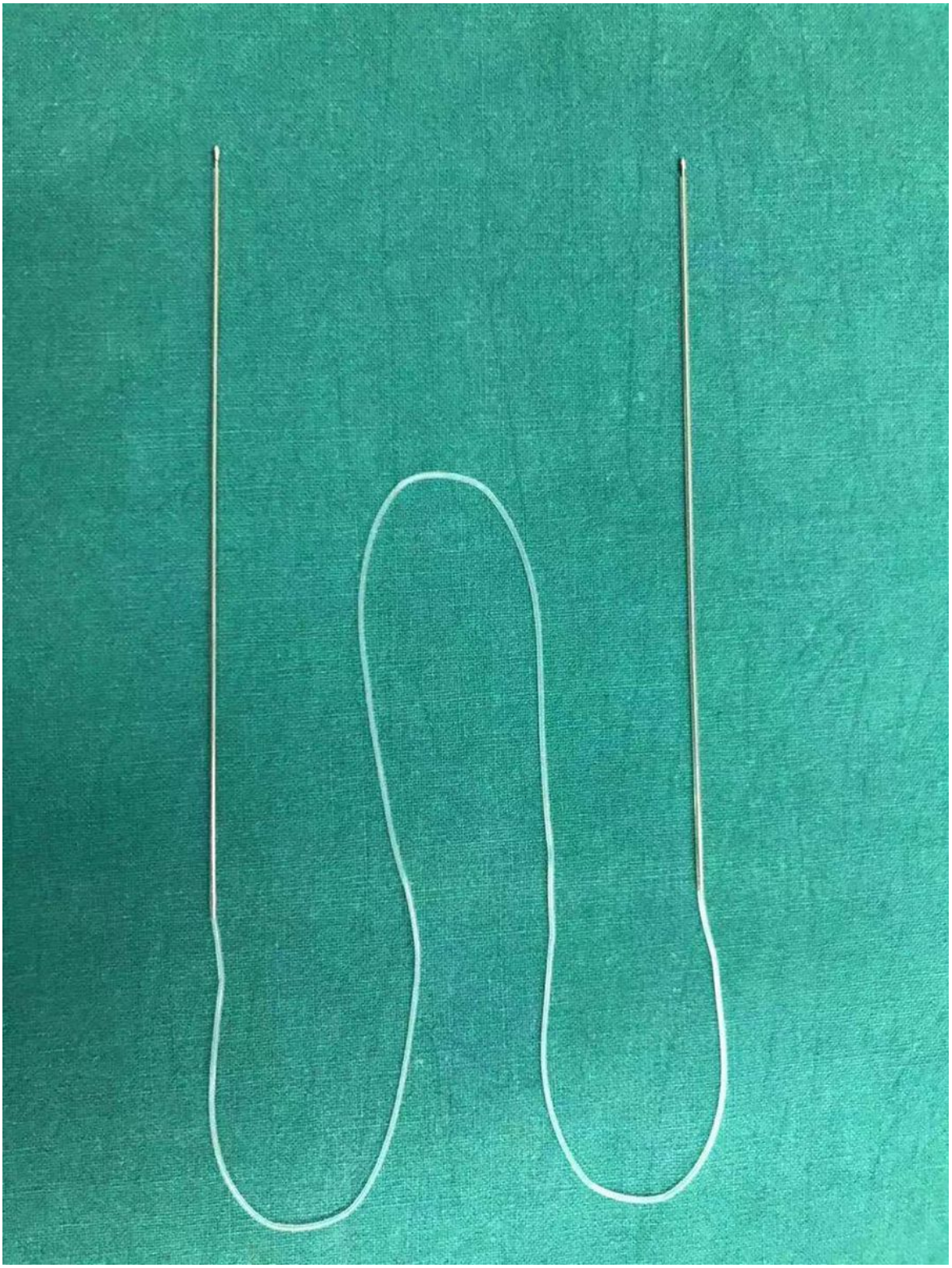

Figure 1

The silicone stent (Shandong Freda Biotechnology Co., Ltd, China)

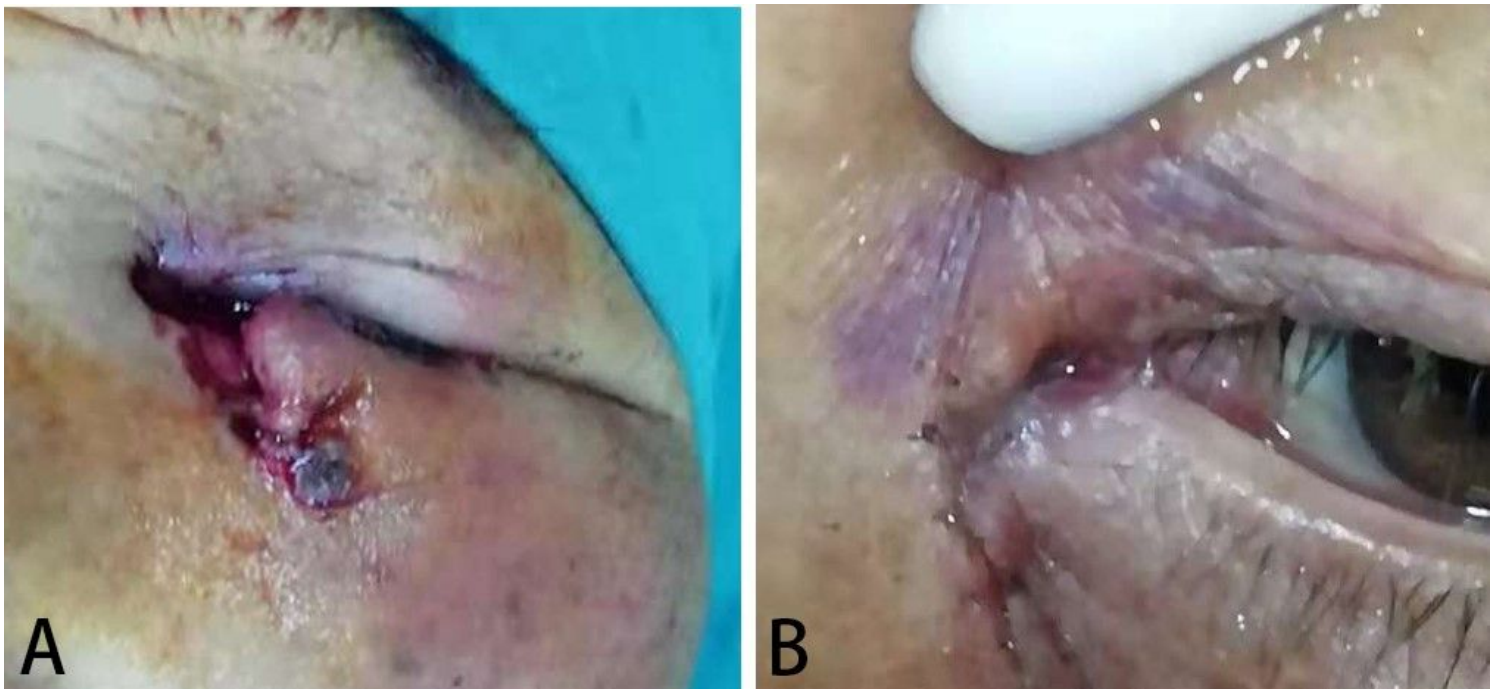

Figure 2

A female patient with lower lacrimal canalicular lacerations and full-thickness eyelid laceration of her left eye. (A)Preoperative view of the patient(B)Postoperative view of the patient by the surgery of silicone intubation. Intubation of a bicanalicular silicone stent was seen after surgery.

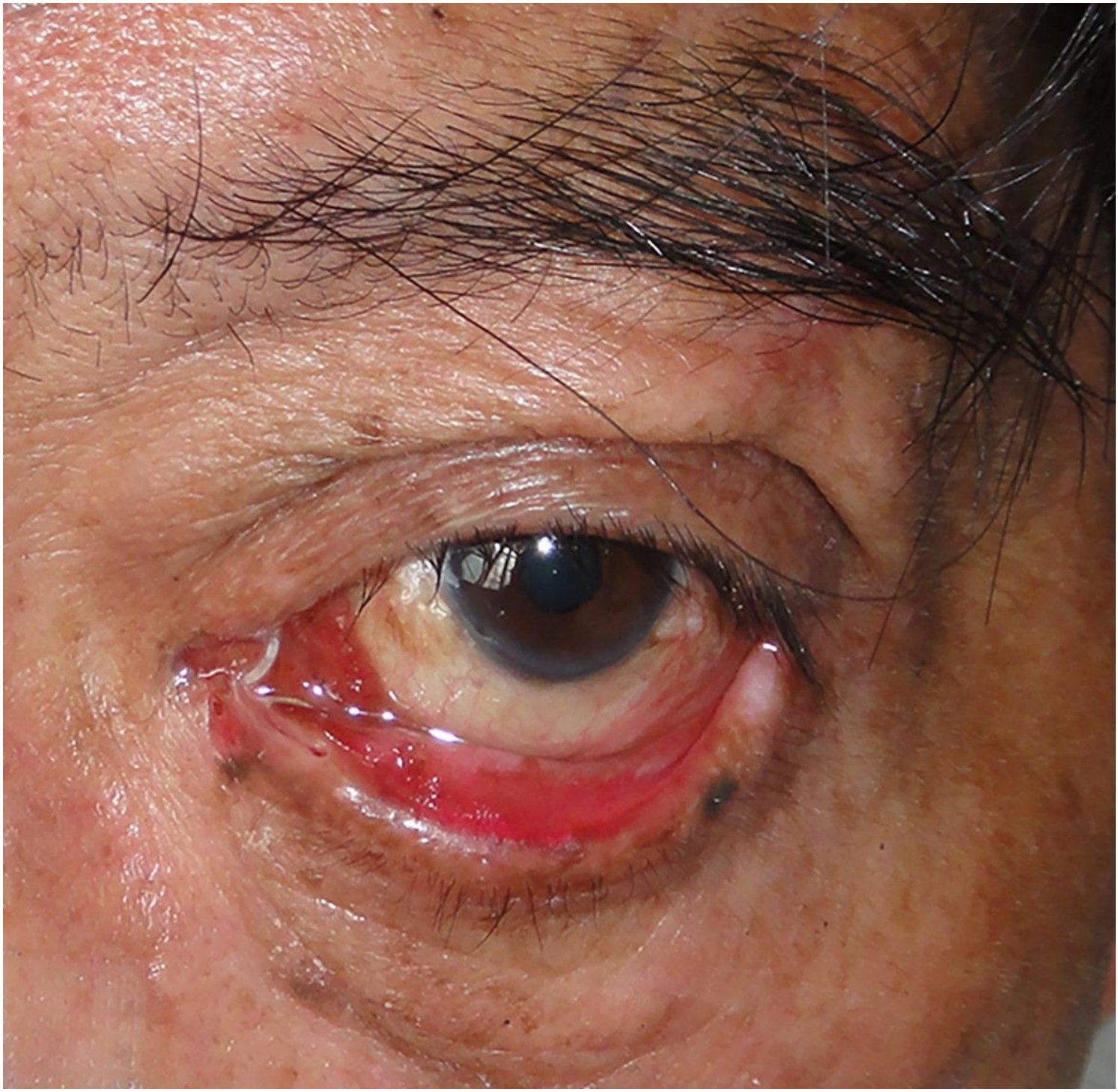

Figure 3

The figure of the complication with lacrimal punctum ectropion and splitting.

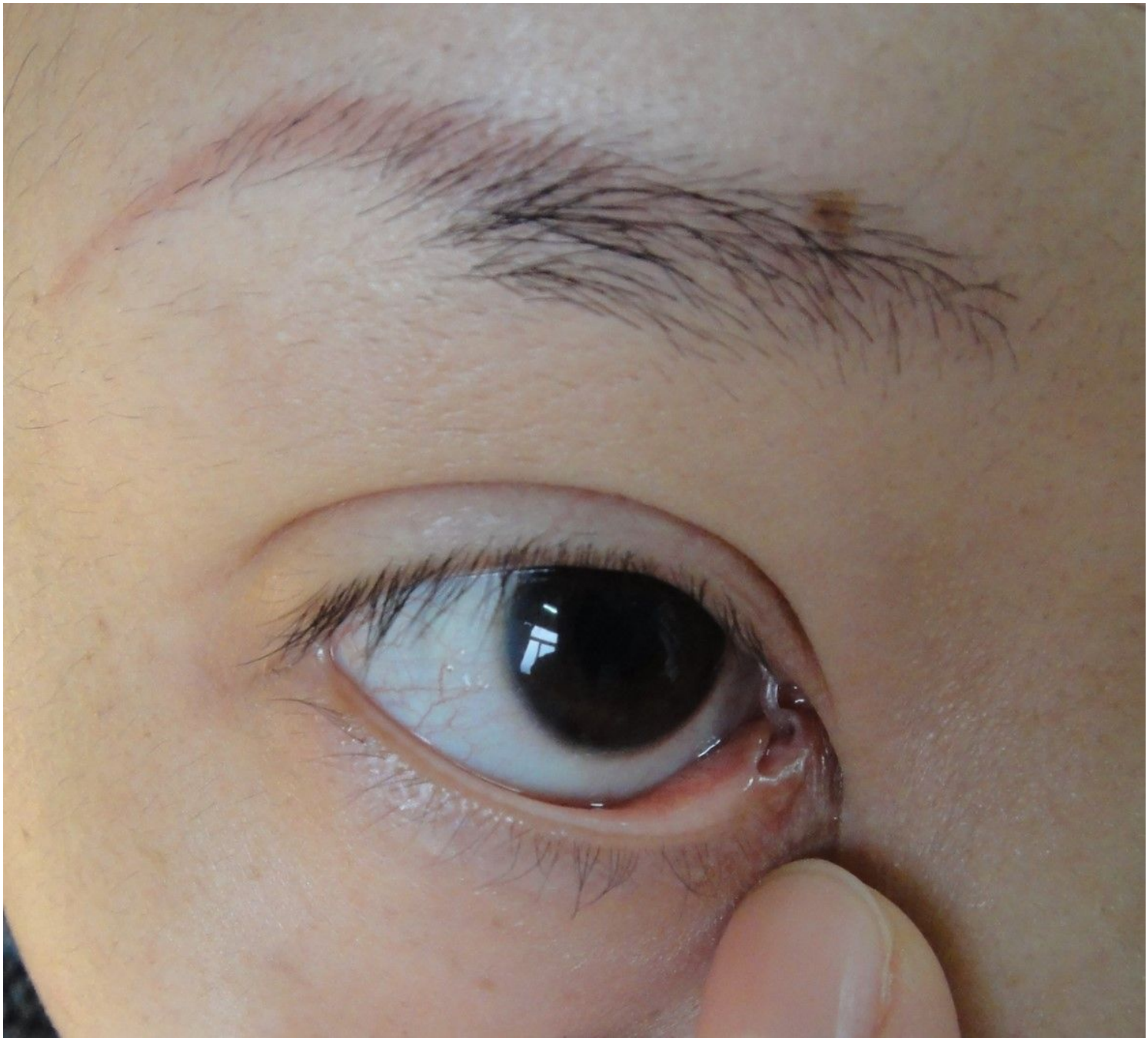

Figure 4

The figure of the complication with lacrimal punctum splitting.