A new classification of femoral shaft fracture combined with femoral artery injury

Yulei Chi
Jining Medical University
Xianmin Bu
Jining No 1 People's Hospital
Xiaoyan Li
Affilited Hospital of Jining Medical University
Rui Zhang
Affiliated Hospital of Jining Medical University
Qinming Zhang
Affiliated Hospital of Jining Medical University
Ronghua Tian
Jining Medical University
Yingjie Xu
Jining Medical University
Fengyu Ma
People's Hospital of Rizhao
Longfei Gao
Affiliated Hospital of Jining Medical University
Chunyang Meng
Affiliated Hospital of Jining Medical University
Haibin Wang
Affiliated Hospital of Jining Medical University
Bin Wu (wb0902@163.com)
Affilited Hospital of Jining Medical University https://orcid.org/0000-0003-3707-0056

Research article

Keywords: femoral shaft fracture, femoral artery injury, classification

Posted Date: September 15th, 2020

DOI: https://doi.org/10.21203/rs.3.rs-76066/v1

Abstract

Background: To explore a new classification of femoral shaft fracture combined with femoral artery injury and to summarize and analyse the characteristics of various types of injury to formulate a correct early diagnosis and treatment strategy.

Methods: The data of 21 patients with femoral shaft fracture combined with femoral vascular injury from December 2009 to March 2019 were analysed retrospectively, including 20 males and 1 female aged (40 ±15.5) years. The causes of injury were traffic injury (n = 16), heavy object injury (n = 3), fall injury (n = 1), crush injury (n = 1), open fracture (n = 12) and closed fracture (n = 9). The patients were classified according to whether the femoral shaft fracture was open, the location of femoral artery injury and whether it was combined with a severe multiple injury. The open femoral shaft fracture with femoral artery injury was type I, in which a similar location of fracture and vascular injury comprised type Ia, while different locations comprised type Ib. The closed femoral shaft fracture with femoral artery injury was type II, in which fracture and vascular injury at same level comprised type IIa and different levels comprised type IIb. Patients with severe multiple injuries had a type III fracture. The location of femoral shaft fracture, femoral artery injury and injury; main signs; diagnosis time; waiting time before operation; operation time; times of operations; hospitalization time; and Enneking lower limb function score were recorded.

Results: According to our classification, there were 7 cases of type Ia, 4 cases of type Ib, 6 cases of type IIa, 3 cases of type IIb and 1 case of type III. The location of femoral fracture (lower segment in 7 cases, middle segment in 9 cases, proximal segment in 5 cases) and feoral artery injury (adductor tendon fissure in 12 cases, superior popliteal fossa in 7 cases, proximal deep femoral artery bifurcation in 2 cases) and the type of femoral artery injury (contusion and embolization in 3 cases, complete rupture in 18 cases) were compared. The diagnosis time for type I patients were 2.0 (1.0, 2.0) h, the preoperative waiting time was 3.5 (3.0, 5.0) h, the first operation time was 405.0 (335.0, 540.0) min, the number of operations was 2.0 (2.0, 4.0) times, the length of hospital stay was 49.0 (21.0, 71.0) days, the fracture healing time was 7.0 (5.0, 9.0) months, and the Enneking lower extremity function score was 20.0 (19.0, 22.0) points. The diagnosis time for type II patients was 7.0 (6.0, 18.5) h, the waiting time before surgery was 9.0 (8.3,20.5) hours, the first operation time was 385.0 (319.5, 490.0) min, the number of operations was 3.0 (2.0, 3.5) times, the length of hospital stay was 57.0 (29.0, 111.5) days, the fracture healing time was 6.00 (5.50, 7.50) months, and the Enneking lower limb function score was 14.0 (13.0, 15.5) points. All patients had signs of obvious weakening or disappearance of dorsal pedis artery pulsation, all type II patients had blue ecchymosis signs at the site of vascular injury, 6 patients had normal muscle strength and sensation of lower limbs, 12 patients had dorsal extension dysfunction, and 1 patient underwent thigh amputation.

Conclusion: The new classification of femoral shaft combined with femoral artery injury is helpful in the diagnosis, treatment and prognosis of the injury. Generally speaking, the diagnosis time of type I injury is faster than that of type II injury, the waiting time before operation is shorter, and the prognosis of lower

limb function is better. Sufficient attention should be paid to the type II injury.Weakening or disappearance of dorsal pedis artery pulsation and blue ecchymosis signs are typical signs .

Background

Femoral shaft combined with femoral artery injury is not uncommon in the clinic, especially open injury[1, 2]. Mostly fresh blood spurted out, and active bleeding continued in the wound, then according to the ischemic symptoms and "5p" signs of the distal limb, the diagnosis is relatively easy. For patients with closed injury, due to the existence of collateral circulation, the symptoms of limb ischemia are not obvious in the early stage, and the diagnosis is relatively difficult[3, 4]. This can lead to delayed diagnosis and treatment, which eventually leads to limb ischemic contracture, muscle necrosis, and even amputation. At present, there has been no clinical study on the classification of femoral shaft combined with femoral artery injury. Twenty-one patients with femoral shaft fracture with femoral artery injury were treated in our hospital from December 2009 to March 2019, as reported as follows.

Patients And Methods

Inclusion and exclusion criteria

Inclusion criteria: (1) fresh femoral shaft fracture with femoral artery injury; (2) no lower limb local infection and severe medical disease; and (3) normal lower limb function before injury.

Exclusion criteria: (1) patients with lower limb arteriosclerosis obliterans; (2) patients with lower limb dysfunction before injury; and (3) lost patients.

Diagnosis

All patients were given detailed physical examination and then ultrasound or CTA examination was performed to confirm the diagnosis.

Surgical Methods

After confirming the diagnosis, all the patients except 1 patient with multiple injuries were treated by emergency operation. There are two kinds of treatment. The first involves debridement, external fixator fixation of the femoral fracture, and repair and reconstruction of the femoral artery injury. This method includes all open fracture cases, and first, contaminated and necrotic tissue was removed, the femoral shaft fracture was reduced, and external fixator fixation was applied. For severe comminuted fracture, the fracture piece was removed and fixed in the shortened position, and the force line was adjusted under fluoroscopy. If the femoral artery injury was within the range of 2 cm, it can be anastomosed directly upstream and downstream. Beyond the 2-cm injuries, the great saphenous vein graft was selected, and the femoral vein injury was repaired at the same time. For long and severe femoral vein injury, direct ligation was employed. At the same time, lateral incision of the leg was performed, and decompressed the Osteofascial compartment. A total of 11 cases in this group were treated with this kind of operation.

The second kind of treatment involves internal fixation of the femoral fracture and repair and reconstruction of the femoral artery injury. In the lateral incision of the fracture of the femur, the broken end of the fracture was exposed, the fracture was reduced, and the plate and screws were used to fix fracture. Then, the site of the “blue ecchymosis sign” was cut and separated layer by layer to find the site of vascular injury[5, 6], and 6 – 0 non-invasive suture was used to repair the femoral artery or great saphenous vein grafting and this operation was used in 10 cases in this group.

Postoperative Treatment And Follow-up

All the patients in this group were sent to the intensive care unit after surgery and were given comprehensive treatment, such as improving circulation, antibacterial treatment, low molecular weight heparin injected subcutaneously every 12 hours to prevent thrombosis.The fascia incision of the leg and the open wound of the thigh were closed by VSD, the peripheral blood circulation was observed, and the liver and kidney function, electrolytes and other systemic conditions were monitored at the same time. Emergency amputation was performed for one patient 48 hours after injury because of limb necrosis. The rest of the patients changed VSD once a week after operation, and it was decided to suture the wound or skin graft according to the condition of the wound two weeks after surgery. The average follow-up was 12 months. The anteroposterior and lateral X-ray films of the femur were examined every one month after surgery. If there was no sign of fracture healing for 6 months, bone grafting was performed, and the time of weight-bearing exercise was determined according to the condition of fracture healing.

Statistical analysis

The IBM SPSS 23.0 statistical software package (SPSS, USA) was used for statistical analysis. The inter-group comparison of counting data is expressed by the Fisher exact probability method, the measurement data is described by medians and quartiles, and the inter-group comparison of measurement data is expressed by the non-parametric test. $P < 0.05$ indicates that the difference is statistically significant.

Results

General information

There were 21 cases, including 20 males and 1 female, with an age of (40 ± 15.5) years. The causes of injury were traffic injury (n = 16), heavy object injury (n = 3), fall injury (n = 1), crush injury (n = 1), open fracture (n = 12) and closed fracture (n = 9).

Table 1
Description of the type I population data

Project		Classification		*P*
		ⅠⅠa[n(%)]	ⅠⅠb[n(%)]	
Sex	Male	7(63.6%)	3(27.3%)	0.364*
	Female	0	1(9.1%)	
Age(years)	≦ 45	2(18.2%)	2(18.2%)	0.7758*
	45⅟60	3(27.3%)	2(18.2%)	
	≧ 60	2(18.2%)	0	
Location of femoral shaft fracture	Upper segment	1(9.1%)	2(18.2%)	0.309*
	Middle segment	2(18.2%)	2(18.2%)	
	Lower segment	4(36.3%)	0	
Vascular injury site	Above the popliteal fossa	3(27.3%)	0	0.625*
	Adductor tendon hiatus	3(27.3%)	3(27.3%)	
	Medial middle part of right thigh	1(9.1%)	0	

* indicates the Fisher exact probability

Table 2
Description of the type ⅠⅠ population data

Project		Classification		*P*
		ⅠⅠa[n(%)]	ⅠⅠb[n(%)]	
Age(years)	≦ 45	4(44.5%)	1(11.1%)	0.206*
	45⅟60	1(11.1%)	3(33.3%)	
Location of femoral shaft fracture	Upper segment	1(11.1%)	2(22.2%)	0.357*
	Middle segment	1(11.1%)	2(22.2%)	
	Lower segment	3(33.4%)	0	
Vascular injury site	Above the popliteal fossa	1 (11.1%)	2 (22.2%)	1.000*
	At the foramen of the adductor tendon	3(33.4%)	2(22.2%)	
	Bifurcation of deep femoral artery	1(11.1%)	0	

* indicates the Fisher exact probability

1. Classification, diagnosis and treatment of femoral shaft fracture combined with femoral artery injury.

In the type case group, we found that the vascular injury sites of 9 male patients were not near the fracture, which greatly increased the difficulty of diagnosis. This situation is particularly prominent in the cases of closed fracture with vascular injury, and through searching literatures, it is found that there is no classification of femoral shaft combined with femoral artery injury at present. Therefore, to facilitate early diagnosis and to guide treatment, the fractures can be divided into three types according to whether the femoral shaft fracture is opening, the location of fracture and femoral artery injury and whether it is combined with severe multiple injuries.

Type I: an open femoral shaft fracture with femoral artery injury (Fig. 1)

Type Ia: the site of the open fracture is near to that of the vascular injury; that is, the site of open femoral shaft fracture is in the upper, middle or lower segment, while the site of vascular injury is near the fracture. The clinical features of this type of injury are obvious, such as open wounds, massive bleeding, and disappearance of dorsalis pedis artery pulsation. These symptoms and signs are relatively easy to diagnose and can be treated surgically in a short time. Most of the treatment methods involve external fixator fixation of femoral fracture, direct anastomosis of arterial injury or vascular transplantation repair, and the clinical recovery is better.

Type Ib: the open fracture site does not correspond to the injury site of the femoral artery, such as the proximal part of the open fracture and the middle or lower segment of the femoral artery. Most examples of this kind of injury have a history of extrusion, and most of the open injuries are degree I and degree II, and the clinical features are not obvious, so it is easy to misdiagnose without careful physical examination. The injury is generally treated with external fixator and vascular repair.

Type II: a closed femoral shaft fracture with femoral artery injury (Fig. 1)

Type IIa: the location of the femoral fracture is near to that of vascular injury, but the clinical feature of this injury is not prominent. In the early stage, due to the existence of collateral circulation, the symptoms of distal ischemia are not obvious, and even weaken arterial pulsation can be felt, which is easy to misdiagnose and delay treatment. A prominent sign is near the vascular injury, which we define as the "blue ecchymosis sign". The treatment of femoral fracture is plate and screws internal fixation and vascular repair.

Type IIb: the femoral fracture does not correspond to the location of the femoral artery injury. This type has the lowest incidence and concealed clinical features and is the most difficult to diagnose, but the "blue ecchymosis sign" still exists. The pulsation of the dorsalis pedis artery also weakens or disappears. CTA can confirm the diagnosis, and the choice of treatment is the same as type IIa.

Type III: open or closed femoral shaft fracture with femoral artery injury and severe multiple injuries (ISS score > 25). This kind of injury is critical and is often combined with haemorrhagic shock and other life-threatening thoracic and abdominal injuries. The diagnosis of femoral fracture is easy, but it is difficult to diagnose whether there is femoral artery injury. Early treatment is to save lives, and there is generally no surgical opportunity for vascular injury repair; thus, amputation is needed to save lives.

According to our classification (Tables 3, 4, 5), there were 7 cases of type Ia, 4 cases of type Ib, 6 cases of type IIa, 3 cases of type IIb, 1 case of type III. The locations of femoral fracture involved the lower segment in 7 cases, the middle segment in 9 cases, and the proximal segment in 5 cases. The femoral artery injury was at the adductor tendon hiatus in 12 cases, above the popliteal fossa in 7 cases, and at the bifurcation of the proximal deep femoral artery in 2 cases. The type of femoral artery injury included contusion and embolism in 3 cases and complete rupture in 18 cases. The diagnosis time for type I patients were 2.00 (1.00, 2.00) h, the preoperative waiting time was 3.50 (3.00, 5.00) h, the first operation time was 405.0 (335.0, 540.0) min, the number of operations was 2.0 (2.0, 4.0) times, the length of hospital stay was 49.0 (21.0, 71.0) days, the fracture healing time was 7.0 (5.0, 9.0) months, and the Enneking lower extremity function score was 20.0 (19.0, 22.0) points. The diagnosis time for type II patients were 7.0 (6.0, 18.5) h, the waiting time before surgery was 9.0 (8.3,20.5) hours, the first operation time was 385.0 (319.5, 490.0) min, and the number of operations were 3.0 (2.0, 3.5) times, the length of hospital stay was 57.0 (29.0, 111.5) days, the fracture healing time was 6.00 (5.50, 7.50) months, and the Enneking lower limb function score was 14.0 (13.0, 15.5) points. All patients had signs of obvious weakening or disappearance of dorsal pedis artery pulsation, and all type II patients had blue ecchymosis signs at the site of vascular injury.

Table 3
Comparison of different diagnostic characteristics of patients with type I and type II injuries (n = 20, M(P25P75))

Project	Classification [$M(P_{25}P_{75})$]		Z	P
	I	II		
Diagnosis time(hours)	2.0(1.0,2.0)	7.0(6.0,18.5)	2.225	0.000
Waiting time before operation(hours)	3.5(3.0,5.0)	9.0(8.3,20.5)	2.225	0.000
Number of operations(times)	2.0(2.0,4.0)	3.0(2.0,3.5)	-0.550	0.582
Soft tissue healing time(days)	35.0(14.0,55.0)	35.0(29.5,58.5)	-0.647	0.517
Enneking lower limb function score	20.0(19.0,22.0)	14.0(13.0,15.5)	1.820	0.003
Fracture healing time(months)	7.0(5.0,9.0)	6.0(5.5,7.5)	-0.652	0.514
The length of the first operation(mins)	405.0(335.0,540.0)	385.0(319.5,490.0)	-0.418	0.676
Hospitalization days(days)	49.0(21.0,71.0)	57.0(29.0,111.5)	-0.798	0.425

Table 4
Comparison of the scores of different diagnostic characteristics of patients with Ia and Ib injuries(n = 11, M(P25P75))

Project	Classification [$M(P_{25}P_{75})$]		Z	P
	Ia	Ib		
Diagnosis time(hours)	1.8(1.3,2.5)	2.00(1.3,2.7)	0.171	1.000
Waiting time before operation(hours)	3.5(3.0,4.5)	4.3(3.1,5.4)	0.570	0.902
Number of operations(times)	2.3(1.4,3.8)	3.0(2.0,4.0)	-0.587	0.557
Soft tissue healing time(days)	35.0(12.5,63.0)	35.0(22.5,55.0)	-0.379	0.705
Enneking lower limb function score	20.0(19.0,25.0)	19.0(16.8,19.8)	0.912	0.377
Fracture healing time(months)	5.7(4.6,7.8)	8.5(7.5,9.5)	-1.812	0.070
Length of the first operation(mins)	405.0(361.3,531.5)	405.0(327.5,598.5)	-0.189	0.850
Hospitalization days(days)	35.0(12.8,65.5)	55.0(39.7,81.7)	-0.947	0.344

Table 5
Comparison of the scores of different diagnostic characteristics of patients with type IIa and type IIb injuries(n = 9, M(P25□P75))

Project	Classification [$M(P_{25}$□$P_{75})$]		Z	P
	IIa	IIb		
Diagnosis time(hours)	13.0(5.8,31.5)	6.7(6.0,15.0)	0.522	0.948
Waiting time before operation(hours)	15.0(7.8,51.0)	9.0(8.6,21.0)	0.522	0.948
Number of operations(times)	2.8(2.1,3.5)	3.0(2.3,5.0)	-0.521	0.602
Soft tissue healing time(days)	42.3(32.5,70.8)	29.5(25.0,45.0)	-1.359	0.174
Enneking lower limb function score	14.0(11.5,15.0)	15.0(14.3,16.5)	1.193	0.116
Fracture healing time(months)	6.0(5.4,7.9)	6.5(5.0,7.5)	-0.128	0.898
Length of the first operation(mins)	375.0(334.8,522.5)	401.0(310.5,443.5)	-0.245	0.806
Hospitalization days(days)	57.0(40.8,94.3)	65.6(29.0,111.5)	0.000	1.000

Discussion

1.Classification of femoral shaft combined with femoral artery injury and its clinical significance.

There are three purposes of fracture and injury classification: rapid diagnosis, guiding treatment, and convenient communication. A good classification should also have the following characteristics. First, the classification is easy to understand and can accurately describe the characteristics or injury mechanism of all kinds of injuries and fractures. Second, the classification should be concise, practical and easy to remember, not too complex, widely accepted by orthopaedic colleagues, and can help to make a correct diagnosis and treatment plan. Femoral shaft fractures are common in the clinic. The literature has cited reports that adult femoral shaft fractures accounted for 2.18% -2.72% of adult general body fractures over the same period and for 17.13% -21.21% of adult femoral fractures[7]. Vascular injuries in the extremities account for 40% -70% of all vascular injuries[8]. If the injury is not detected and treated in time, the disability rate is extremely high, and the amputation rate of blunt injury to the lower limb is 6.5%-20%, while that of acute injury is 0.4%-4% [9]. In this group, 1 patient had amputation; 48 hours after injury, the limb was embolized and necrotic and could not be repaired and reconstructed, and the thigh was amputated directly. For the patients with multiple injuries, there was no opportunity for repair in the first stage, and double thigh amputation was performed in the second stage after the vital signs were stabilized. For injury of the popliteal artery and above the artery, although the incidence is low, the amputation rate is very high[10]. One of the 21 patients in this group had amputation, for an amputation rate of 4.8%. The clinical manifestations of occult vascular injury were delayed and atypical,

which is a difficulty in clinical diagnosis and treatment [11]. Based on the above reasons, combined with what we found in the process of treating this kind of injury, the patients can be divided into roughly three types. Additionally, there are different situations in these kinds of injury, which can be roughly divided into two categories, which are classified as subtypes. Among them, the Ia subtype has outstanding clinical features, easy diagnosis, and can be treated in the early morning. The clinical diagnosis of type Ib is easily missed because the site of open fracture is not in the same place as the vascular injury. Without careful physical examination, the diagnosis rate of primary delay is very high, and the average diagnosis time of patients in this group is significantly longer than that in the IIa group. The second category is closed femoral fracture with femoral vascular injury; this kind of injury accounts for 42.8% of the 21 patients, and the clinical symptoms of this kind of injury are not typical. It has been reported in the literature that 5% – 15% of patients with vascular injury have normal distal arterial pulsation; thus, this kind of diagnosis is the most difficult. In our medical records, we found only one case of normal early arterial pulsation: a 15-year-old patient who was found to have black toes 72 hours later. Colour ultrasound examination found that the femoral blood vessel was ruptured at the fissure of the adductor tendon. There are also two cases of this kind of injury, which we classify into two subtypes, of which the IIa subtype involves fracture and femoral vascular injury at the corresponding site. One of its characteristic manifestations is the "blue ecchymosis sign". We had a total of 5 such patients in this group, all of whom had this typical physical sign. If you examine the body carefully at the early stage, you can achieve an early diagnosis. The other type is the IIb subtype, in which the site of closed fracture and vascular injury are not in corresponding sites. In this group of 4 patients, 3 cases were delayed in diagnosis. For orthopaedic surgeons, the diagnosis of fractures is easier, but vascular problems are often ignored, especially such closed injuries. The third category comprises severe multiple injury patients with femoral shaft fracture with femoral vascular injury; in this category, the patient's ISS score is more than 25 points, most of them have craniocerebral trauma, thoracic and abdominal trauma, haemorrhagic shock and other conditions. The first-stage diagnosis is more difficult, and even if the injury can be diagnosed clearly, there is essentially no time for surgery. Only one patient in this group was treated with pressure bandaging to stop bleeding in the first stage, saving their life actively, with amputation required in the second stage.

2. Strength of the new classification for the diagnosis of femoral shaft fracture combined with femoral vascular injury.

Fracture and severe trauma combined with main vascular injury is common in the clinic and require early diagnosis and treatment [12]. Open fractures with trunk vascular injuries, because of their obvious clinical features, are relatively easy to diagnose. The data showed that the diagnosis time of type I injury was faster than that of type II injury, and the difference in waiting time before operation was statistically significant ($P < 0.05$), which gained time for further treatment. For injuries to main blood vessels, it is generally believed that if the blood vessels are reopened within 6 to 8 hours, the survival rate of the limbs will be high, and the functional recovery of the limbs will be better. However, it is very difficult to do so clinically, especially for patients with closed injury; it is reported in the reference that the diagnosis of

closed trunk vascular injury of the lower extremities is more difficult, and the misdiagnosis rate is as high as 27% [13]. Zhang YZ. put forward the concept of "occult vascular injury" as early as 2011, which is a kind of injury with atypical clinical symptoms that can easily delay diagnosis and miss the best time for treatment[14, 15]. In our classification, there are three types that are more difficult to diagnose, which are considered as "occult vascular injury". The first type is type Ib, which was classified by us. Although this type of fracture is open, the vascular injury is not at the corresponding site of the fracture. For example, open fracture of the middle femur and vascular injury above the popliteal fossa were found in 4 of the 21 patients, and the diagnosis time was significantly later than that of type Ia injuries. The second type is type IIa, that is, closed fracture with vascular injury at the corresponding site. In the early stage of assessing this kind of injury, attention is often paid to the diagnosis of the fracture but ignores the signs of vascular injury, which leads to delayed diagnosis. There were 5 such patients in this group, and the diagnosis time was 13.00 (5.8, 31.5) hours. The third type is type IIb, that is, the femoral fracture and vascular injuries are not at the same level, or there are two vascular injuries. The diagnosis of this kind of injury is particularly difficult, mostly because the patient has severe symptoms of lower limb pain and is diagnosed by doctors. In this group, there was a young male who was admitted to the hospital for 10 hours due to left lower limb dysfunction with severe pain caused by a fall. The results of anterior and lateral radiographs of the left femur after admission showed that the left femoral shaft had a comminuted fracture (Fig. 2.). Before surgery, there was a large "blue ecchymosis sign" in the medial thigh and popliteal fossa of the left leg, and the pulsation of dorsalis pedis artery was weaker than that of the contralateral side (Fig. 2.). At this time, we highly suspected that the patient had femoral shaft fracture with vascular injury; therefore, according to our clinical experience, CTA of the left lower limb was performed before surgery (Fig. 2.). The results showed that the middle and distal segments of the femoral artery had ruptured, and the bifurcation of the popliteal artery was bruised and embolized, which was confirmed during the operation (Fig. 3.). Due to the timely diagnosis and active surgical treatment before surgery, the skin incision healed well 6 months after the operation, X-ray showed that the fracture had healed, and the function of the left lower limb recovered well (Fig. 4.). We found that in the cases of the above three types of injuries, there were the following two characteristics: (1) the pulsation of the dorsalis pedis artery was weaker or disappeared compared with that of the contralateral side; and (2) the skin at the site of the closed vascular injury had blue swelling and bruising, which was defined as "blue ecchymosis sign". The author believes that for patients with femoral shaft fracture, clinicians should attach great importance to the existence of vascular injury, and once the above two signs are found, they should further carry out lower limb arteriovenous colour ultrasound or CTA examination[16, 17], which will be helpful to arrive at a correct diagnosis in the early stage.

Conclusion

In conclusion the diagnosis time of type I injury is faster, the waiting time before surgery is shorter, the postoperative Enneking score of the lower limb function is higher, and the prognosis of lower limb function is better in the later stage. Therefore more attention should be paid to the type II injury.Weakening or disappearance of dorsal pedis artery pulsation and blue ecchymosis signs are two most typical signs. The new classification system for femoral fracture combined with artery injuries will be of great significance for rapid and standardized clinical diagnosis and treatment for this kind of injury in the future.

Declarations

Acknowledgements

Not applicable

Funding

This study was supported by the “Jining Medical University Helin Academician Fund” (grant number JYHL2018FMS13), the “Supporting Fund for Teachers’ Research at Jining Medical University” (grant number JYFC2018FKJ048) and the “Jining Science and Technology Bureau Medical Health Fund” (grant number 2018SMNS002).

Availability of data and materials

Yes, data and meterial were available, not been published, and is not under consideration elsewhere.

Authors’contributions

All authors participated in the design, interpretation of the studies, analysis of the data, and review of the manuscript. CYL, BXM, and LXY carried out the data analysis and drafted the manuscript. WB, MCY and WHB conceived of the study, participated in its design and coordination, and helped to draft the manuscript. ZR, TRH and ZQM participated in the design of the study and performed the statistical analysis. MFY, GLF, and XYJ helped to collect data and performed the statistical analysis. All authors read and approved the final manuscript.

Ethics approval and consent to participate

This retrospective study was approved by the relevant Institutional Review Board at the Affiliated Hospital of Jining Medical University. The reference number is not applicable. Explicit informed consent for this retrospective study was not required.

Consent for publication

Not applicable

ompeting interests

The authors declare that they have no competing interests.

References

1 Isaacson J, Louis DS, Costenbader JM. Arterial injury associated with closed femoral-shaft fracture. Report of five cases. J Bone Joint Surg Am. 1975. 57(8): 1147-50.

2 Owers KL, Blewitt N, Morse MH. Arterial injury complicating femoral shaft fracture: control of primary and secondary profunda femoral bleeding by transcatheter embolisation. Injury 1999; 30:305-8.

3 Rosental JJ, Gaspar MR, Gjerdrum TC, Newman J. Vascular injuries associated with fractures of the femur. Arch Surg 1975;110:494-9.

4 Sharma S, Kothari SS, Rajani M, Venugopal P. Life-threatening arterial haemorrhage: results of treatment by transcatheter embolization using home-made steel coils. Clin Radiol 1994;49:252-5.

5 Papakostidis C, Grotz MR, Papadokostakis G, Dimitriou R, Giannoudis PV. Femoral biologic plate fixation. Clin Orthop Relat Res 2006;450:193-202.

6 Gänsslen A, Gösling T, Hildebrand F, Pape HC, Oestern HJ. Femoral shaft fractures in adults: treatment options and controversies. Acta Chir Orthop Traumatol Cech 2014;81:108-17.

7 Zhang YZ;Clinical epidemiology of orthopedic trauma [M].New York:Thieme.2012:177-92.

8 Feliciano DV, Moore FA, Moore EE, West MA, Mcintyre RC. Evaluation and Management of Peripheral Vascular Injury. Part 1. Western Trauma Association/Critical Decisions in Trauma. Journal of Trauma 2011;70:1551-6.

9 Frykberg ER. Popliteal vascular injuries. Surg Clin North Am 2002;82:67-89.

10 Callcut RA, Acher CW, Hoch J, Tefera G, Turnipseed W, Mell MW. Impact of intraoperative arteriography on limb salvage for traumatic popliteal artery injury. J Trauma 2009;67:252-7; discussion 257-8.

11 Rodriguez-Merchan EC, Moraleda L, Gomez-Cardero P. Injuries associated with femoral shaft fractures with special emphasis on occult injuries. Arch Bone Jt Surg 2013;1:59-63.

12 Lädermann A, Stern R, Bettschart V, Riand N. Delayed posttraumatic pseudoaneurysm of the anterior tibial artery mimicking a malignant tumor. Orthopedics 2008;31:500.

13 Drapanas T, Hewitt RL, Weichert RF 3rd, Smith AD. Civilian vascular injuries: a critical appraisal of three decades of management. Ann Surg 1970;172:351-60.

14 Chen W, Su Y, Zhang Q, Zhang Y, Smith WR, Ma L, et al. A proposed new system of coding and injury classification for arteries in the trunk and extremities. Injury 2012;43:1539-46.

15 Rozycki GS, Tremblay LN, Feliciano DV, McClelland WB. Blunt vascular trauma in the extremity: diagnosis, management, and outcome. J Trauma 2003;55:814-24.

16 Lo SP, Hsieh CC, Yang CY, Lin CJ, Chang CW. Delayed superficial femoral artery pseudoaneurysm following distal femoral shaft fracture: a case report. Kaohsiung J Med Sci 2011;27:242-6.

17 Valli F, Teli MG, Innocenti M, Vercelli R, Prestamburgo D. Profunda femoris artery pseudoaneurysm following revision for femoral shaft fracture nonunion. World J Orthop 2013;4:154-6.

Figures

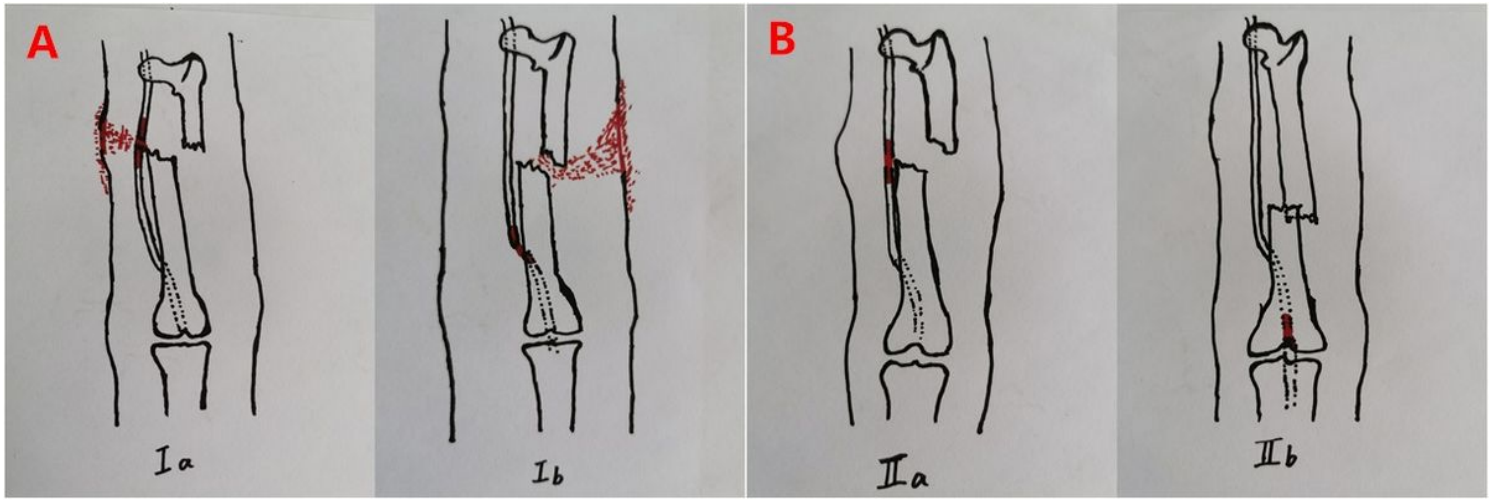

Figure 1

Type Ia: the site of open fracture is similar to that of vascular injury; type IB: there is no correspondence between the site of open fracture and the site of femoral artery injury (A).Type IIa: the location of femoral fracture is similar to that of vascular injury; type IIb: there is no correspondence between femoral fracture and femoral artery injury (B).

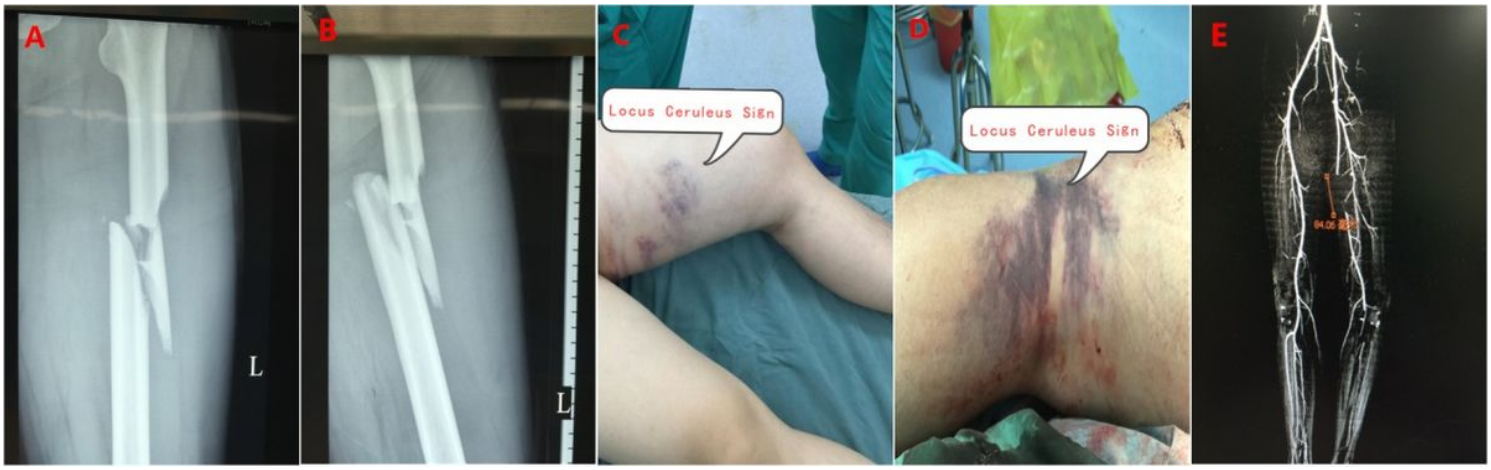

Figure 2

The anterior and lateral films of the femur before surgery showed the comminuted fracture of the left femoral shaft (A, B). Before surgery, there was a flaky "blue ecchymosis sign" in the medial thigh and popliteal fossa (C, D). CTA of the left lower limb before surgery showed rupture of the middle and distal segments of the femoral artery and contusion and embolism at the bifurcation of the popliteal artery (E).

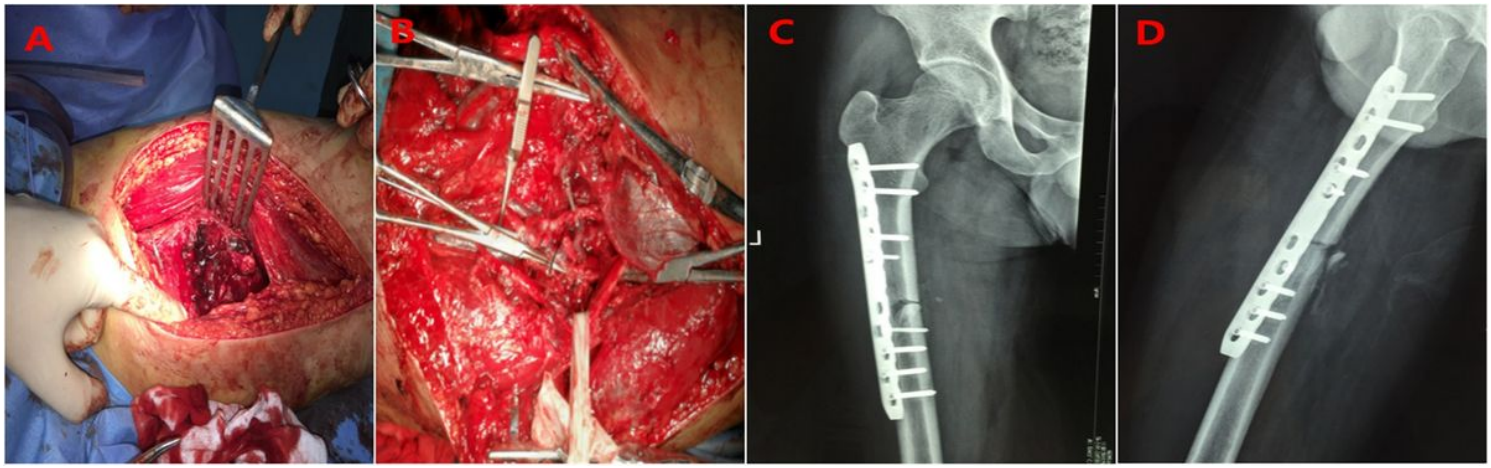

Figure 3

Intraoperative repair of the femoral artery (A, B); positive and lateral X-rays after internal fixation of the femoral fracture (C, D).

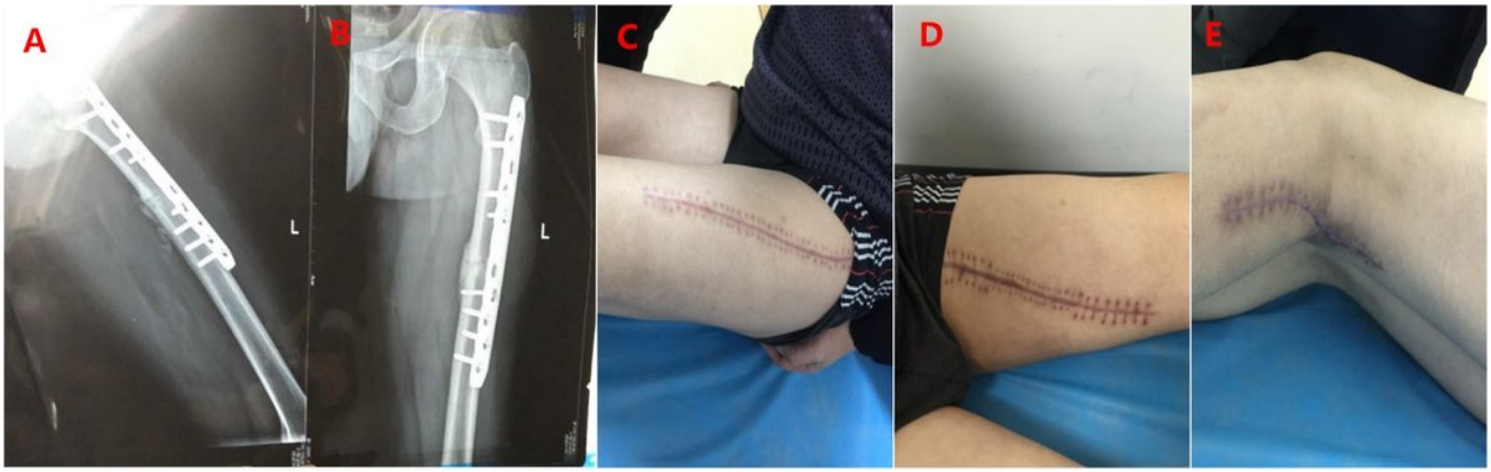

Figure 4

The skin incision healed well 6 months after surgery (A, B). Six months after surgery, X-ray showed that the fracture had healed, and the function of the left lower limb had recovered well (C, D, E).