Sinusitis Independently Predicts the Presence of Headache Following Endoscopic Transsphenoidal Resection for Pituitary Adenomas

Jiayu Gu
Sun Yat-sen University Cancer Center
Xiaoqun Chen
Sun Yat-sen University Cancer Center
Yunzhi Zou
Sun Yat-sen University Cancer Center
Shuo Yang
Sun Yat-sen University Cancer Center
Siyu Chen
Sun Yat-sen University Cancer Center
Depei Li
Sun Yat-sen University Cancer Center
Ke Sai
Sun Yat-sen University Cancer Center
Yonggao Mou
Sun Yat-sen University Cancer Center
Zhihuan Zhou
Sun Yat-sen University Cancer Center
Xiaobing Jiang (jiangxiaob1@sysucc.org.cn)
Sun Yat-sen University Cancer Center https://orcid.org/0000-0001-6566-7269

Research Article

Keywords: Pituitary adenomas, Endoscopic transsphenoidal surgery, Headache, Sinusitis.

Posted Date: August 3rd, 2021

DOI: https://doi.org/10.21203/rs.3.rs-760943/v1

Abstract

Purpose Headache is common among patients with pituitary adenomas undergone endoscopic endonasal surgery (EES), but was seldomly concerned before. The present study aims to investigate the incidence and profile of risk factors of headache after EES.

Methods A meta-analysis was performed to evaluate the occurrence proportions of postoperative headache in patients with pituitary adenomas. Then, a cohort of 101 patients undergone EES were enrolled for analyzing risk factors of headache. The Headache Impact Test (HIT-6) was used to score the headache preoperatively, 1 month and 3 months postoperatively.

Results A total of 18 studies and 4442 participants were included for meta-analysis. The pooled occurrence proportion of postoperative headache was 29% (95% confidential interval: 20-38%). For the 101 patients enrolled in the present study, 26 (25.74%) of them had a HIT-6 scores of > 55 preoperatively, but decreased to 22 (21.78%) at 1 month, and 6 (5.94%) at 3 months, postoperatively. Multivariate analysis showed that pituitary apoplexy (OR=3.591, 95%CI 1.219-10.575, p=0.020) and Hardy's grade C-D (OR=21.06, 95%CI 2.25-197.02, p=0.008) were independently risk factors for preoperative headache. In contrast, postoperative sinusitis (OR=3.88, 95%CI 1.16-13.03, P=0.028) and Hardy's grade C-D (OR=10.53, 95%CI 1.02-109.19, P=0.049) independently predicted the presence of postoperative headache at 1 month. At 3 months postoperatively, the proportion of sinusitis tended to be higher in the headache group than the one in non-headache group (100% vs. 30.0%, p=0.070).

Conclusion Headache is very common following EES for pituitary adenomas. Prophylactic management of postoperative sinusitis may help to alleviate postoperative headache.

Introduction

Pituitary adenomas (PAs) are among the most common benign primary tumors of the central nervous system, accounting for 10% to 15% of all intracranial tumors[1-3]. At present, transsphenoidal surgery is the primary treatment for most of PAs, except prolactinomas[4]. Endoscopic endonasal surgery (EES) has shown advantages in removing pituitary adenomas, and become the mainstream choice for the most of PA patients[5-7]. In the long time, complications with endoscopic transsphenoidal surgery include epistaxis, sinusitis, hyposmia and hypopituitarism[8, 9]. Chronic headache is also very frequent postoperatively, and affects the quality of life of patients, but was seldomly concerned before. The incidence of headaches in patients with pituitary adenomas has been reported to range between 33% and 72%[10-12], and only half of them were relieved postoperatively[13]. The underlining reasons still unclear.

Previous studies tried to investigate the potential risk factors associated with chronic headache post transsphenoidal surgery, and larger tumor volume, cavernous sinus invasion, optic chiasm compression and functioning PAs were shown to be independent risk factors[12, 14]. However, some studies reported the negative results, where cavernous sinus invasion, suprasellar extension, and optic chiasm compression were not associated with the incidence of postoperative headache[15, 16]. Several factors

may account for the inconsistence of previous studies. Firstly, both groups of patients treated by transsphenoidally microsurgical approach and EES were enrolled for analysis, which might partly account for the variation of conclusions from different studies[17, 18]. Secondly, the evaluation scale for headache varied among the studies[12, 15-18]. Last and the most importantly, the evaluation timing was also different among the studies, and few studies have evaluated the headache dynamically.

To address these limitations, a cohort of 101 PAs patients treated only through EES were enrolled to elaborate the risk factors of chronic headache. Moreover, to better characterized the profile of risk factors of headache, we performed a dynamic evaluation of headache at preoperative, 1 month and 3 months postoperative. Interestingly, the pattern of risk factors of pre-and post-operative headache was different. For the first time, PAs of Hardy's grade C-D and postoperative sinusitis were shown to be independently risk factors for the occurrence of headache 1 month postoperatively. Furthermore, by tracking the development of sinusitis and headache in a subgroup of patients with headache, we found that prophylactic care of sinusitis may help to relive the postoperative headache.

Methods

Meta-analysis

Literature was retrieved from PubMed, EMBASE and Cochrane library, and restricted by studies published before April 16, 2021. The search term was "((("Pituitary Neoplasms"[Mesh]) OR (Pituitary cancer or pituitary neoplasm or pituitary tumor or pituitary adenoma or pituitary carcinoma)) AND (pain)) AND (surgery or surgical or surgeries)". Retrieved literature was loaded into Reference management software NoteExpress 3.2.0.7276. The selection criteria were as follows:

The inclusion criteria are as follows：Participants were pituitary adenomas, older than 18, had surgery intervention; Studies with detailed information on the number of headaches after surgery. The exclusion criteria are as follows: Participants were pregnant, had craniectomy. Study selection and data collection process were performed by two researchers separately. We extracted occurrence proportions as outcome indicators and pooled them through R version 4.0.5 (Shake and Throw).

Population for the retrospective study

Our study retrospectively collected clinical data of 101 patients who underwent endoscopic transsphenoidal resection of pituitary adenomas between July 2018 and December 2020. This study was reviewed and approved by the Research Ethics Committee. All the patients have known and agree to be involved in the present study.

Patients underwent pituitary adenoma removal through EES, with pathological confirmation and complete follow-up data, were included. Patients underwent craniotomy resection for pituitary adenomas, or those with incomplete follow-up data were excluded.

EES resection of PAs was performed by an experienced neurosurgeon. In general, posterior nasal septectomy was performed to allow binasal access. The face of the sphenoid and intersphenoidal septations was ground away. The tumor was resected after the dura was incised. Complex intraoperative cerebrospinal fluid leaks were repaired in a layered fashion, which composed of a combination of Gelfoam, fat, facia, bone, and a vascularized naso-septal flap. A catheter balloon was placed in the posterior nostril for reconstruction.

All patients underwent preoperative CT plain scan and contrast-enhanced MRI of the head. Clinical data, including age, gender, pituitary apoplexy, diameter of tumor, clival osseous destruction, sinusitis, extent of tumor resection and postoperative intracranial hemorrhage, were collected. The diagnosis of sinusitis was based on head MRI. The invasiveness of PAs was graded with Knosp's[19] and Hardy's[20] grade system. The Headache Impact Test (HIT-6) was used to evaluate the extent of headache preoperatively, 1 month and 3 months postoperatively[21, 22]. Patients were with a HIT-6 scores of >55 was considered to have headache[23, 24].

Nose care during the follow-up of patients post-EES for PAs.

A follow-up MRI will be performed 1 month, and 3 months postoperatively to assess residual tumor and sinusitis. One month after the operation, all the patients will be suggested to start nose rinsing every day for 2 months. In addition, maxillary natural ostium and sphenoidal sinus will be cleaned endoscopically, 1 month postoperatively.

Statistical analyses

SPSS 20.0 (IBM Corp.) was used for data analysis. The quantitative data were expressed as the mean ± SD. Independent sample *t* test and Pearson chi-square test or Fisher's exact test were used to analyze the statistically significant difference between the two groups. Risk factors of headache were analyzed by univariate and multivariate analysis. A p value less than 0.05 was considered significantly.

Results

Meta-analysis for the occurrence proportion of headache postoperatively.

A total of 619, 735 and 47 studies were retrieved through PubMed, EMBASE and Cochrane library, respectively. As shown in **Fig. 1A**, 18 studies with 4442 participants were finally included in meta-analysis. Information on the number of headaches was shown in **Fig. 1B.** Collectively, the pooled occurrence proportion were 29% (95% confidential interval: 20-38%) **(Fig. 1C)**.

Dynamic analysis for the risk factors of pre-and post-operative headache.

Basic clinical and pathological characteristics of patients.

The baseline clinical characteristics of patients with pituitary adenomas are shown in **Table 1**. A total of 101 patients were enrolled for the present study, with a mean age of 45.71 ± 11.90 years. The mean maximum diameter of the tumor was 28.25 ± 11.04 mm. Thirty-nine patients (38.6%) were with tumor of Knosp's grade 3-4, and 6 patients had those in Hardy's Grade C-D. Gross total resection was achieved in 85 patients (84.2%). Twenty-four cases (23.8%) were functioning pituitary adenomas, and 15 cases of them were growth hormone secreting adenomas. There were 24 samples (23.8%) with positive staining of transcription factor TBX19. The average value of Ki-67 index was 2.56 ± 1.64%. Preoperatively, 32 patients were found to have slight sinusitis, based on head MRI. At the follow-up at 1 and 3-month postoperatively, 54 (53.5%) and 17 (15.9%) were confirmed to have sinusitis.

A total of 26 patients (25.7%) and 22 patients (21.8%) with HIT-6 score > 55 preoperatively and 1 month postoperatively, respectively. Only 6 patients remained with headache 3 months postoperatively. By using c2 test, tumor apoplexy was significantly associated with preoperative headache **(Table 2)**, and Hardy's Grade C-D was significantly associated with both preoperative and 1-month postoperative headache **(Table 1)**. Additionally, postoperative sinusitis and clival osseous destruction were also significantly associated with headache 1month postoperatively **(Fig. 2A)**.

Preoperative headache was significantly relived 3-month after operation.

HIT-6 scores of pre-and post-operations are compared in **Fig. 2B**. On the whole, the HIT-6 scores of 3 months postoperatively was significantly lower than the preoperative one (41.12 ± 0.72 vs. 46.06 ± 1.06, P= 0.0002) and the 1-month postoperative one (41.12 ± 0.72 vs. 46.82 ± 0.90, P< 0.0001). However, there is no statistically significant difference between preoperative HIT-6 scores and the 1-month postoperative one. These data suggested that patients with headache preoperatively could be significantly relived 3-month after operation.

Univariate and multivariate analysis of risk factors associated with headache post EES for PAs.

To compare the pattern of risk factors of pre- and post-operative headache, we first made the analysis on the preoperative HIT-6 scores. Univariate and multivariate analysis showed that both pituitary apoplexy (OR=3.59, 95%CI 1.22-10.58, p=0.020) and Hardy's grade C-D (OR=21.06, 95%CI 2.25-197.02, p=0.008) were independently risk factors (**Table 3**). However, there was no statistically significant difference in gender, presence of sinusitis, clival osseous destruction and Knosp's grade, as well as growth hormone secreting adenomas and TBX19 positive (**Table 3**).

Then, we analyzed the risk factors associated with the headache 1 month postoperatively. Intriguingly, the pattern of risk factors is different from the preoperative one. As displays in **Table 4**, Hardy's grade C-D (OR=10.53, 95%CI 1.02-109.19, P=0.049) remains an independent risk factor of postoperative headache. However, postoperative sinusitis (OR=3.88, 95% CI 1.16-13.03, P=0.028) also independently predicts the presence of postoperative headache at 1 month, which strongly recommends the prevention of sinusitis after EES for PAs.

Correlation analysis of sinusitis and headache in the subgroup of patients with headache.

Considering the clinical significance of the causal correlation between sinusitis and headache, we further analyzed their potential correlation in the subgroup of patients with headache. A total of 35 patients suffered from headache in the current study, including 26 preoperative and 9 postoperative ones. The dynamic change of HIT-6 scores and relevant presence of sinusitis were present in **Fig. 2C-E**.

Then, we further tracked the status of patients 3 months after operation, which are displayed in **Fig. 3**. Among the 26 patients with headache preoperatively, 12 patients relieved and 14 patients remain with headache 1-month postoperatively. The proportion of sinusitis was significantly higher in the headache group than the one in non-headache group (85.7% vs. 41.7%, p=0.038). At 3 months, 10 of the 14 patients relieved and 4 patients remain with headache. The proportion of sinusitis was tended to be higher in the headache group than the one in non-headache group (100% vs. 30.0%, p=0.070).

In the 9 patients who did not have headache preoperatively, 8 patients developed headache 1 month postoperatively, and 6 (85.7%) of them had sinusitis. The patient developed headache at 3 months also was also with sinusitis confirmed by MR. Collectively, these data strongly suggested that postoperative sinusitis partly accounts for the presence and relief of chronic headache following EES for PAs.

Discussion

Chronic headache is a common complication following PAs resection transsphenoidally. However, its incidence and risk factors remain inconsistent. By systematically reviewing previous literature, we declared a pooled occurrence proportion of headache was 29%, following transsphenoidal surgery for PAs. By evaluating the headache at multiple points, we found a different pattern of risk factors of headache between pre- and post-operation, which may help to explain the inconsistent conclusions among previous studies. Furthermore, postoperative sinusitis, but not the preoperative sinusitis, was first shown to be in-dependently risk factors for the occurrence of headache, which strongly suggested that measures are taken to prevent postoperative sinusitis, and thus decrease the occurrence of postoperative headache.

In order to evaluate whether hypothalamus repression will induce headache, patients were divided into Hardy’s grade C-D and Hardy’s grade A, B and E groups. As shown in table 1, the ratio of patients with headache was significantly higher in the Hardy’s grade C-D group (22.7% vs. 1.3%, p=0.002). In multivariate analysis, Hardy’s grade C-D was also independently predicted the presence of headache, in both preoperative and postoperative analysis. Hypothalamic regulation of has been shown to be involved with migraine and cluster headache, and indeed a structure in close proximity to the hypothalamus has been identified to play a crucial role in attack generation[25]. Therefore, for the PAs patients with headache induced by mass effect on hypothalamus, headache could be treated postoperatively. And the function of hypothalamus won’t be recovered until 1-3 months after operation.

Headache associated with pituitary adenomas may be induce through displacement of intracranial pain-sensitive structures located in the blood vessels, cranial nerves and dura mate, inflammation involving pain-sensitive structures or meningeal irritation, or hormonal dysregulation.[12, 15] The cavernous sinus contains pain-producing structures, such as the internal carotid artery and trigeminal nerve and ganglion, invasion of which might be expected to cause pain. Different studies have different opinions on pain caused by cavernous sinus invasion[12, 15, 16]. The evaluation timing for headache, and scale used may partly accounting for the inconsistence. In our study, we evaluate the risk factors at multiple points, including preoperative, 1 month and 3 months postoperatively. Knosp's grade was not shown to be significantly associated with headache at all points. Much more deliberated studies are warranted to declare their correlations.

Postoperative sinusitis is more common due to the opening of the sinuses in the nasal cavity and the need to open the sphenoid sinus for endoscopic resection of pituitary adenomas[26]. Sinusitis can cause headaches[27]. Given that the nasal mucosa is extremely sensitive, the feeling of pain is more obvious after surgery via endoscopic transsphenoidal surgery. In our study, preoperative sinusitis was determined by craniocerebral MRI in 31.7% of patients, and the proportion of postoperative sinusitis increased to 53.5%. The proportion of postoperative sinusitis in headache group was higher than that in non-headache group. Multivariate logistic regression analysis showed that the OR of postoperative headache in patients with postoperative sinusitis was 3.883. When analyzing data of headache and sinusitis, we found that the proportion of sinusitis in patients with postoperative headache at the same period is always higher than that without headache. Patients with postoperative sinusitis are more likely to develop postoperative headaches.

In some studies, patients with functioning pituitary adenomas are more likely to develop postoperative headaches[15], especially nociceptive tumors like growth hormone secreting tumors and prolactinomas. They can potentially demonstrate improvement with endocrinological treatments[28, 29]. In our study, functioning pituitary adenomas and growth hormone adenomas were not associated with postoperative headache in patients with pituitary adenomas. We suspect that some patients with functioning pituitary adenomas have achieved biochemical remission after surgery and their hormone levels have decreased to normal or close to normal and therefore do not present with headache. We need to further verify the relationship between postoperative hormone levels and headache.

Our study also has some limitations. Firstly, the sample size of this study is still insufficient and the follow-up time is limited. it is necessary to further expand the sample size and extend the follow-up time to investigate the risk factors of long-term headache. Secondly, we failed to evaluate the status of pituitary function completely, which is an important issue for the patients' quality of life. Finally, the causation relationship between sinusitis and postoperative headache remains unknown until prospective studies performed.

Conclusion

Headache is a very common complication following EES for pituitary adenomas. Postoperative sinusitis and Hardy's grade are independent risk factors for postoperative headache. Prophylactic treatments may help to prevent postoperative sinusitis, and thus reduce the incidence of headache. Prospective and randomized clinical studies including more patients are suggested to confirm our findings.

Declarations

Funding

This research was supported by the Guangdong Basic and Applied Basic Research Foundation (Grant No. 2020A1515010280). Science and Technology Program of Jiangmen, China (Grant No. 2018630100110019805).

Competing interests

The authors declare that they have no competing interests.

Availability of data and material

The datasets used or analyzed during the current study are available from the corresponding author on reasonable request.

Authors' contributions

JG, XC, SY and SC participated in data collection and follow-up of patients. YZ performed meta-analysis. XJ, DL, KS, and YM performed surgery. JG, XC, ZZ and XJ participated in writing and proofreading the manuscript. ZZ and XJ designed the study, were involved in the whole process and were guarantors of the integrity of the entire study.

Ethics approval

This study was reviewed and approved by the Research Ethics Committee of Sun Yat-sen University Cancer Center.

Consent to participate

All the patients have known and agree to be involved in the present study.

Consent for publication

Written informed consent for publication was obtained from all participants.

Acknowledgments

The authors would like to thank Department of Neurosurgery/Neuro-oncology, Sun Yat-sen University Cancer Center for providing data to this work. This research has been funded by Guangdong Basic and Applied Basic Research Foundation (Grant No. 2020A1515010280) and Science and Technology Program of Jiangmen, China (Grant No. 2018630100110019805).

References

1. Buurman H, Saeger W. Subclinical adenomas in postmortem pituitaries: classification and correlations to clinical data[J]. Eur J Endocrinol, 2006,154(5):753-758.
2. Ezzat S, Asa S L, Couldwell W T, et al. The prevalence of pituitary adenomas: a systematic review[J]. Cancer, 2004,101(3):613-619.
3. Gittleman H, Ostrom Q T, Farah P D, et al. Descriptive epidemiology of pituitary tumors in the United States, 2004-2009[J]. J Neurosurg, 2014,121(3):527-535.
4. Molitch M E. Diagnosis and Treatment of Pituitary Adenomas: A Review[J]. JAMA, 2017,317(5):516-524.
5. Cho D Y, Liau W R. Comparison of endonasal endoscopic surgery and sublabial microsurgery for prolactinomas[J]. Surg Neurol, 2002,58(6):371-375, 375-376.
6. DeKlotz T R, Chia S H, Lu W, et al. Meta-analysis of endoscopic versus sublabial pituitary surgery[J]. Laryngoscope, 2012,122(3):511-518.
7. Goudakos J K, Markou K D, Georgalas C. Endoscopic versus microscopic trans-sphenoidal pituitary surgery: a systematic review and meta-analysis[J]. Clin Otolaryngol, 2011,36(3):212-220.
8. Gondim J A, Almeida J P, Albuquerque L A, et al. Endoscopic endonasal approach for pituitary adenoma: surgical complications in 301 patients[J]. Pituitary, 2011,14(2):174-183.
9. Berker M, Hazer D B, Yucel T, et al. Complications of endoscopic surgery of the pituitary adenomas: analysis of 570 patients and review of the literature[J]. Pituitary, 2012,15(3):288-300.
10. Kreitschmann-Andermahr I, Siegel S, Weber C R, et al. Headache and pituitary disease: a systematic review[J]. Clin Endocrinol (Oxf), 2013,79(6):760-769.
11. Hayashi Y, Kita D, Iwato M, et al. Significant improvement of intractable headache after transsphenoidal surgery in patients with pituitary adenomas; preoperative neuroradiological evaluation and intraoperative intrasellar pressure measurement[J]. Pituitary, 2016,19(2):175-182.
12. Gondim J A, de Almeida J P, de Albuquerque L A, et al. Headache associated with pituitary tumors[J]. J Headache Pain, 2009,10(1):15-20.
13. Shepherd D M, Jahnke H, White W L, et al. Randomized, double-blinded, placebo-controlled trial comparing two multimodal opioid-minimizing pain management regimens following transsphenoidal surgery[J]. J Neurosurg, 2018,128(2):444-451.
14. Suri H, Dougherty C. Clinical Presentation and Management of Headache in Pituitary Tumors[J]. Curr Pain Headache Rep, 2018,22(8):55.

15. Wolf A, Goncalves S, Salehi F, et al. Quantitative evaluation of headache severity before and after endoscopic transsphenoidal surgery for pituitary adenoma[J]. J Neurosurg, 2016,124(6):1627-1633.
16. Levy M J, Jager H R, Powell M, et al. Pituitary volume and headache: size is not everything[J]. Arch Neurol, 2004,61(5):721-725.
17. Rizzoli P, Iuliano S, Weizenbaum E, et al. Headache in Patients With Pituitary Lesions: A Longitudinal Cohort Study[J]. Neurosurgery, 2016,78(3):316-323.
18. Jang M K, Park C G, Jang S, et al. Prevalence and Impact of Postoperative Headaches in Nonfunctioning Pituitary Macroadenoma Patients: A Longitudinal Cohort Study[J]. World Neurosurg, 2020,133:e633-e639.
19. Knosp E, Steiner E, Kitz K, et al. Pituitary adenomas with invasion of the cavernous sinus space: a magnetic resonance imaging classification compared with surgical findings[J]. Neurosurgery, 1993,33(4):610-617, 617-618.
20. Hashimoto N, Handa H, Yamashita J, et al. Long-term follow-up of large or invasive pituitary adenomas[J]. Surg Neurol, 1986,25(1):49-54.
21. Kosinski M, Bayliss M S, Bjorner J B, et al. A six-item short-form survey for measuring headache impact: the HIT-6[J]. Qual Life Res, 2003,12(8):963-974.
22. Nachit-Ouinekh F, Dartigues J F, Henry P, et al. Use of the headache impact test (HIT-6) in general practice: relationship with quality of life and severity[J]. Eur J Neurol, 2005,12(3):189-193.
23. Muller K I, Alstadhaug K B, Bekkelund S I. A randomized trial of telemedicine efficacy and safety for nonacute headaches[J]. Neurology, 2017,89(2):153-162.
24. Cascio R A, Paolucci M, Altavilla R, et al. Daith Piercing in a Case of Chronic Migraine: A Possible Vagal Modulation[J]. Front Neurol, 2017,8:624.
25. May A, Burstein R. Hypothalamic regulation of headache and migraine[J]. Cephalalgia, 2019,39(13):1710-1719.
26. Magro E, Graillon T, Lassave J, et al. Complications Related to the Endoscopic Endonasal Transsphenoidal Approach for Nonfunctioning Pituitary Macroadenomas in 300 Consecutive Patients[J]. World Neurosurg, 2016,89:442-453.
27. Ceriani C E, Silberstein S D. Headache and rhinosinusitis: A review[J]. Cephalalgia, 2021,41(4):453-463.
28. Levy M J, Matharu M S, Goadsby P J. Prolactinomas, dopamine agonists and headache: two case reports[J]. Eur J Neurol, 2003,10(2):169-173.
29. Levy M J, Matharu M S, Meeran K, et al. The clinical characteristics of headache in patients with pituitary tumours[J]. Brain, 2005,128(Pt 8):1921-1930.

Tables

Table 1 The clinicopathological features of patients underwent transsphenoidal endoscopic resection of pituitary adenomas (N=101).

	N (%)	Headache (N=22)	Non-headache (N=79)	*P value*
Gender				0.875
Male	49(48.5%)	11	38	
Female	52(51.5%)	11	41	
Tumor apoplexy				1
Yes	20(19.8%)	4	16	
No	81(80.2%)	18	63	
Preoperative sinusitis				0.988
Yes	32(31.7%)	7	25	
No	69(68.3%)	15	54	
Clival osseous destruction				0.039
Yes	7(6.9%)	4	3	
No	94(93.1%)	18	76	
Extent of tumor resection				0.317
Total resection	85(84.2%)	17	68	
Untotal resection	16(15.8%)	5	11	
Cerebrospinal fluid leaks				0.853
Yes	26(25.7%)	6	20	
No	75(74.3%)	16	59	
Postoperative intracranial infection				1
Yes	3(3.0%)	0	3	
No	98(97.0%)	22	76	
Postoperative intracranial hemorrhage				1
Yes	1(1.0%)	0	1	
No	100(99.0%)	22	78	
Postoperative sinusitis				0.003
Yes	54(53.5%)	18	36	
No	47(46.5%)	4	43	

Knosp's grade				0.806
Grade 0-2	62(61.4%)	14	48	
Grade 3-4	39(38.6%)	8	31	
Hardy's grade				0.002
Grade A,B&E	95(94.1%)	17	78	
Grade C-D	6(5.9%)	5	1	
Functioning pituitary adenoma				0.662
Yes	24(23.8%)	6	18	
No	77(76.2%)	16	61	
GH secreting adenoma				0.735
Yes	15(14.9%)	4	11	
No	86(85.1%)	18	68	
TBX19				0.662
positive	24(23.8%)	6	18	
negative	77(76.2%)	16	61	
Age (years;mean±SD)	45.71±11.90	48.09±8.58	45.05±12.64	0.292
Maximum diameter (mm;mean±SD)	28.25±11.04	30.36±15.20	27.78±9.62	0.457
Ki-67 index (%;mean±SD)	2.56±1.64	2.36±1.29	2.62±1.73	0.519

Table 2 Analysis of related factors of preoperative headache in patients with pituitary adenomas (N=101).

	N (%)	Headache (N=26)	Non-headache (N=75)	*P value*
Gender				0.277
Male	49(48.5%)	15	34	
Female	52(51.5%)	11	41	
Tumor apoplexy				0.028
Yes	20(19.8%)	9	11	
No	81(80.2%)	17	64	
Preoperative sinusitis				0.545
Yes	32(31.7%)	7	25	
No	69(68.3%)	19	50	
Clival osseous destruction				0.07
Yes	7(6.9%)	4	3	
No	94(93.1%)	22	72	
Knosp's grade				0.985
Grade 0-2	62(61.4%)	16	46	
Grade 3-4	39(38.6%)	10	29	
Hardy's grade				0.004
Grade A,B&E	95(94.1%)	21	74	
Grade C-D	6(5.9%)	5	1	
Functioning pituitary adenoma				0.295
Yes	24(23.8%)	4	20	
No	77(76.2%)	22	55	
GH secreting adenoma				0.342
Yes	15(14.9%)	2	13	
No	86(85.1%)	24	62	
TBX19				0.66
positive	24(23.8%)	7	17	
negative	77(76.2%)	19	58	
Age (years;mean±SD)	45.71±11.90	46.62±10.94	45.40±12.28	0.656

Maximum diameter (mm;mean±SD)	28.25±11.04	32.19±13.83	27.01±9.65	0.086
Ki-67 index (%;mean±SD)	2.56±1.64	2.35±1.23	2.64±1.76	0.434

Table 3 Univariate and multivariate logistic regression analysis of related factors of preoperative headache in patients with pituitary adenomas (N=101).

	Univariate logistic regression analysis			Multivariate logistic regression analysis			
	OR	95% CI	*P value*	B value	OR	95% CI	*P value*
Gender	0.608	(0.247, 1.497)	0.279	-	-	-	-
Preoperative sinusitis	0.737	(0.274, 1.984)	0.546	-	-	-	-
Clival osseous destruction	4.364	(0.907, 21.001)	0.066	-	-	-	-
Knosp's grade	0.991	(0.396, 2.479)	0.985	-	-	-	-
Functioning pituitary adenoma	0.500	(0.153, 1.630)	0.250	-	-	-	-
GH secreting adenoma	0.397	(0.083, 1.894)	0.247	-	-	-	-
TBX19	1.257	(0.453, 3.491)	0.661	-	-	-	-
Tumor apoplexy	3.080	(1.099, 8.633)	0.032	1.278	3.591	(1.219, 10.575)	0.020
Hardy's grade	17.619	(1.950, 159.178)	0.011	3.048	21.064	(2.252, 197.023)	0.008

Table 4 Univariate and multivariate logistic regression analysis of the predictive factor for headache after transsphenoidal endoscopic pituitary surgery in patients with pituitary adenomas.

	Univariate logistic regression analysis			Multivariate logistic regression analysis			
	OR	95% CI	*P value*	B value	OR	95% CI	*P value*
Gender	0.927	(0.360, 2.385)	0.875	-	-	-	-
Tumor apoplexy	0.875	(0.260, 2.947)	0.829	-	-	-	-
Preoperative sinusitis	1.008	(0.365, 2.781)	0.988	-	-	-	-
Extent of tumor resection	0.55	(0.168, 1.796)	0.322	-	-	-	-
Cerebrospinal fluid leaks	1.106	(0.381, 3.214)	0.853	-	-	-	-
Postoperative intracranial infection	0	0	0.999	-	-	-	-
Postoperative intracranial hemorrhage	0	0	1	-	-	-	-
Knosp's grade	0.885	(0.332, 2.355)	0.806	-	-	-	-
Functioning pituitary adenoma	0.787	(0.268, 2.307)	0.662	-	-	-	-
GH secreting adenoma	1.374	(0.391, 4.827)	0.62	-	-	-	-
TBX19	1.271	(0.434, 3.725)	0.662	-	-	-	-
Clival osseous destruction	5.63	(1.156, 27.404)	0.032	0.654	1.924	(0.267, 13.847)	0.516
Postoperative sinusitis	5.375	(1.668, 17.325)	0.005	1.357	3.883	(1.157, 13.029)	0.028
Hardy's grade	22.941	(2.516, 209.166)	0.005	2.354	10.53	(1.015, 109.189)	0.049

Figures

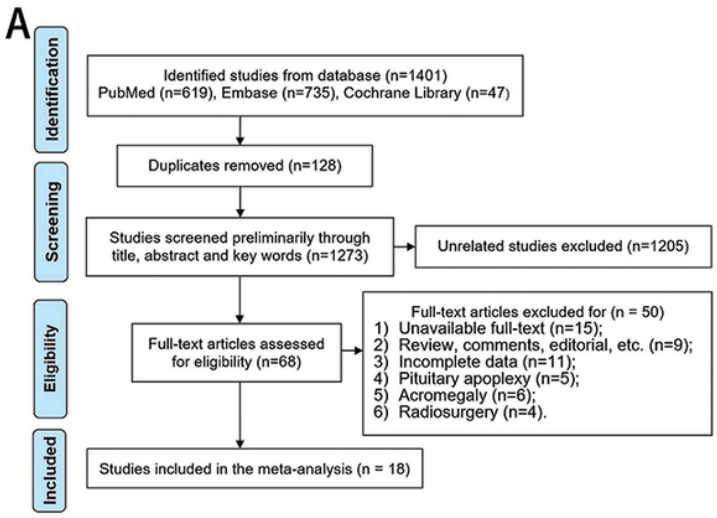

B

Author	Year	Preoperative headache	Postoperative headache	Total
van Lindert	1991		10	53
Abe, T	1998	17	20	49
Zada, G	2003	46	25	100
Dusick, J R	2006		93	259
Clarke, M J	2008		7	21
Fleseriu, M	2009	41	17	41
Dusick, J R	2006	142	98	259
Zhang, X	2007	62	0	65
Mello, P A	2013		61	87
Correia, I A	2014		5	19
Gondim, J A	2015		16	55
Gagliardi, F	2016		4	11
Rizzoli, P	2016	84	51	133
Rutkowski, M J	2018	32	6	32
Agam, M S	2019		323	1153
Li, C	2020	752	752	2032
Jang, M K	2020	15	5	40
Almalki, M H	2020	29	0	33

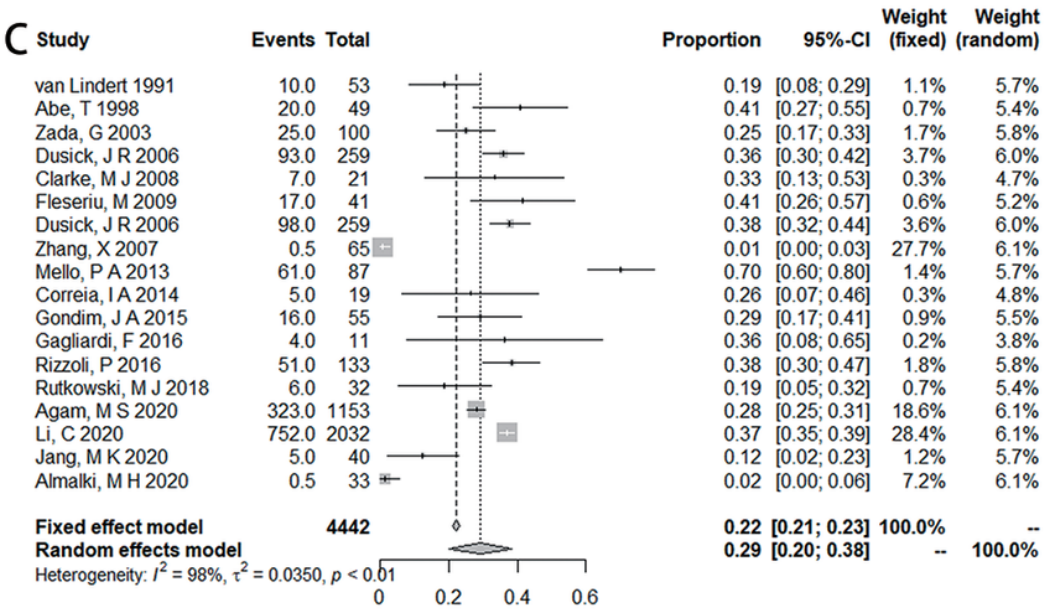

Figure 1

Meta-analysis of postoperative headache in patients with pituitary neoplasms.

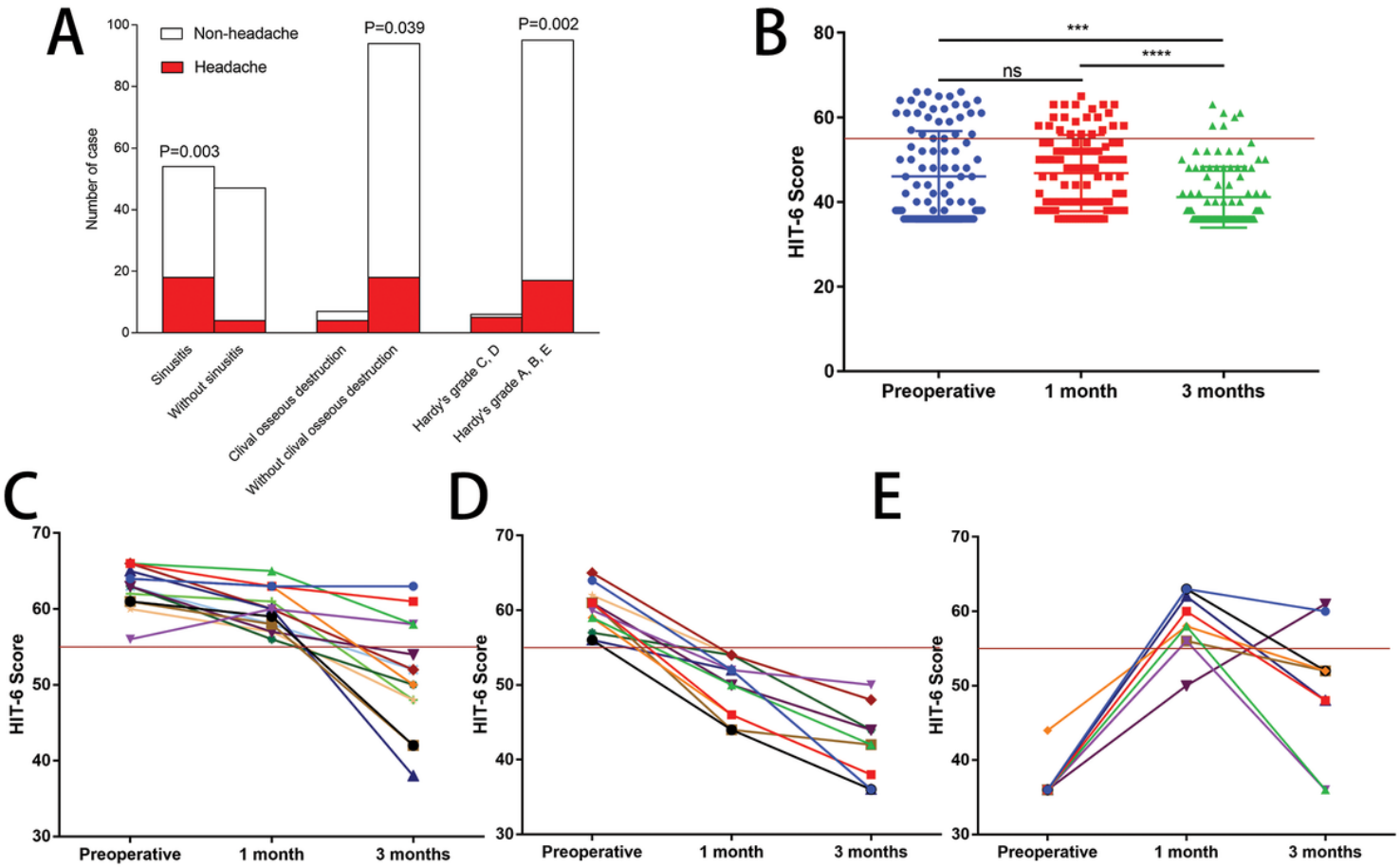

Figure 2

(A) Bar-Stacked segmentation depicting the composition of headaches measured by the HIT-6 questionnaire and p value in Pearson chi-square test in patients with/ without postoperative sinusitis, clival osseous destruction or with different Hardy's grade 1 month postoperatively. (B) Scatter plot of HIT-6 scores preoperatively, 1 or 3 months postoperatively (Horizontal red line represents HIT-6 scores=55, similarly hereinafter in C, D and E). (C) Line chart of HIT-6 scores in 14 patients who had headache 1 month postoperatively. (D) Line chart of HIT-6 scores in 12 patients who did not have headache 1 month postoperatively. (E) Line chart of HIT-6 scores in 9 patients who did not have headache preoperatively.

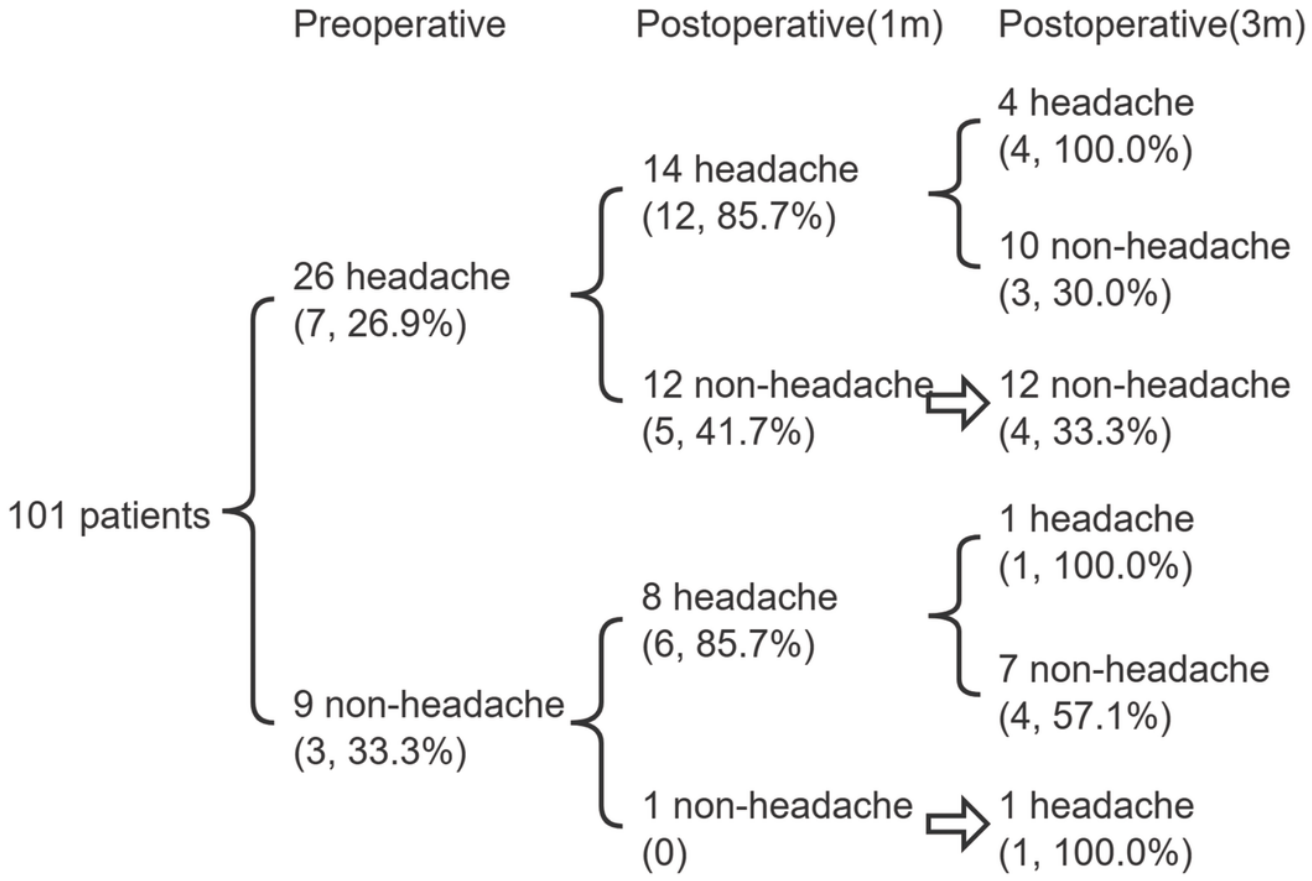

Figure 3

Flow chart of headache and sinusitis preoperatively, 1 or 3 months postoperatively (Numbers in brackets indicate the number and proportion of patients with sinusitis at the same period).