The Effect of Distal Radius Fractures Involving Distal Radioulnar Articular Joint on Forearm Rotation

Lingde Kong
Hebei Medical University Third Affiliated Hospital
Meng Fu
Hebei Medical University Third Affiliated Hospital
Jian Lu
Hebei Medical University Third Affiliated Hospital
Yanqing Zhou
Hebei Medical University Third Affiliated Hospital
Zuzhuo Zhang
Hebei Medical University Third Affiliated Hospital
Bing Zhang (zhangbingdr@126.com)
Hebei Medical University Third Affiliated Hospital

Research article

Keywords: distal radius, distal radioulnar articular, 3D, reconstruction, forearm rotation

Posted Date: September 21st, 2020

DOI: https://doi.org/10.21203/rs.3.rs-76689/v1

Version of Record: A version of this preprint was published on November 19th, 2020. See the published version at https://doi.org/10.1186/s13018-020-02091-w.

Abstract

Background: The objective of this study was to predict the function of forearm rotation on basis of articular surface of sigmoid notch from three-dimensional reconstruction images.

Methods: We retrospectively reviewed patients who underwent volar plate fixation for intra-articular distal radius fractures (DRFs) in our institution between January 2017 and July 2019. The 3D image of sigmoid notch on fractured distal radius was reconstructed and looked up from ulnar view to determine the existence of gaps or steps. Patients with or without gaps/steps on sigmoid notch were included in case group or control group respectively. The patients' basic data and postoperative data were collected and compared.

Results: A total of 81 patients were included. There were 33 patients in case group, and 48 patients in control group. There was no significant difference between the two groups at baseline. Total range of motion (ROM) of rotation in case group and control group were 130.3±6.2 degrees and 145.3±6.7 degrees respectively (P<0.001). Percentage of rotation ROM of contralateral limb in case group and control group were 72.3±3.1% and 80.7±3.6% respectively (P<0.001). VAS during forearm rotation were 2.1±0.7 in case group, which is significantly higher than that in control group (1.5±0.5, P<0.001).

Conclusion: This study proposed a new method to assess the articular surface of sigmoid notch which is based on 3D reconstruction images. With the assistance of this method, we found that gaps or steps on sigmoid notch not only limit forearm pronation rotation and supination rotation, but also cause apparent wrist pain during forearm rotation movement.

Introduction

Distal radius fractures (DRFs) are the most common fractures of the upper extremity [1, 2]. Although favorable clinical outcomes have been reported after surgical treatment, patients with residual deformity frequently complain of wrist pain, reduced grip strength and restricted range of motion (ROM) [3, 4]. Wrist flexion and extension frequently attract people's attention, but restriction of forearm rotation is often disabling because compensation cannot be provided easily via the shoulder. Normal anatomy of the distal radioulnar joint (DRUJ) comprises the distal radius, ulna, and triangular fibrocartilage complex (TFCC), and the sigmoid notch of the distal radius articulates with the convex ulnar head. Any incongruency of the sigmoid notch and the ulnar head may lead to pain or dysfunction of the DRUJ [5, 6].

For common intra-articular DRFs, X-ray is still the preferred test. Though it is easily performed, X-ray test could only recognize apparent intra-articular fractures and tend to miss small step-offs or gaps, because of the blocking of ulna and its single projection angle. Computed tomograph (CT) images could recognize all small fractures, but it had limited capacity to get a full view of the overall fractures.

Three-dimensional images of articular surface can be reconstructed by use of the data transferred from CT. In the 3D reconstruction images, articular surface details such as the fossa, ankle and destruction of

the articular surface were clearly displayed. Compared with traditional CT test, this technique could provide abundant information for surgeons from multiple angles [7, 8].

Though 3D reconstruction technique was frequently used to assist orthopedic surgery, it has never been used to assess the articular surface of sigmoid notch. The objective of this study was to confirm if the 3D reconstruction images could provide additional information for us to predict the function of forearm rotation, especially in patients with intra-articular DRFs.

Materials And Methods

Study design and patient population

We retrospectively reviewed patients who underwent volar plate fixation for intra-articular DRFs in our institution between January 2017 and July 2019. The inclusion criteria were patients over 18 years old with intra-articular DRFs confirmed by X-ray test or CT examination. Patients with open fractures, associated carpal bone fractures, radial head injury, dislocation of distal radioulnar joint, injuries of the TFCC, or history of hand or upper extremity surgery were excluded from this study. Patients with incomplete follow-up data were excluded from this study. This study was approved by the Research and Ethics Committee of the Third Hospital of Hebei Medical University, and all patients gave written informed consent for their information to be stored in the database of this hospital and used for medical research.

Treatment and follow-up

All patients underwent open reduction and volar plate fixation with brachial plexus or general anesthesia. The locking plate is applied through an incision over the volar aspect of the wrist. The details of the surgical approach, the type of plate, and the number and configuration of screws were decided by the surgeon. Some surgeons used a cast/splint after the procedure, but the fixed angle stability provided by the locking plate is generally sufficient to allow early controlled range of movement exercises. The use or otherwise of a cast/splint was also at the discretion of the surgeon. Finger, elbow and shoulder exercises were started at the first day after surgery. After surgery, addition CT examination were performed and analyzed.

Patients were followed up at 4 weeks, 6 weeks and every two weeks until fracture healing. At the 1-year follow-up, additional clinical assessment was performed. ROM of bilateral forearm rotation was measured using a goniometer, and pronation as well as supination motion were measured based on neutral position. Pain in forearm rotation was evaluated by Visual Analogue Scale (VAS), with 0 representing no pain and 10 representing maximum pain.

Data collection and parameter evaluation

The patients' basic data were collected, including age, gender, osteoporosis, dominant extremity fracture, preoperative swelling, AO classification, associated ulnar styloid process fracture and time from injury to operation. Surgical related data were also collected, which included additional Kirschner wire fixation,

post-operative radial inclination, post-operative volar tilt, post-operative ulnar variance, removal of volar plate and assisted cast or splint fixation. Preoperative swelling was assessed on the first day of hospitalization. If the wrist is swelling than the contralateral side but the skin texture can be recognized, the swelling was considered to be slight. If the skin texture cannot be recognized or blisters occurred, the swelling was considered to be severe. Measurements for ulnar inclination, volar angulation, and ulnar variance were performed on the postoperative radiographs according to the previous method [4].

The patients after surgery were required to perform a 1.0 mm CT scan (Aquilion 64; Toshiba, Tokyo, Japan) of the distal radius, and the data were kept in the DICOM format and were 3D reconstructed using Mimics20.0 (Materialise, Belgium). The editing function of software was used to separate the distal radius from the carpal bone and remove the ulnar bone image. The 3D reconstruction image of sigmoid notch on fractured distal radius was looked up from ulnar view to determine the existence of gaps or steps (Fig. 1). Gaps or steps were considered when the distance of fracture borders were more than 1 mm. Patients with gaps or steps on sigmoid notch were included in case group, otherwise, they were included in control group.

Statistical analysis

Data analyses were performed using SPSS version 20 for Windows (SPSS, Inc., Chica go, IL, USA). Data are presented as the number of subjects in each group or mean ± standard deviation (SD). To determine the difference between groups, Fisher exact tests or independent-samples *t* tests were used. Probability value less than 0.05 was considered statistically significant.

Results

A total of 81 patients were included in our study. Among them, 33 patients with unsmooth sigmoid notch were enrolled in case group, and the other 48 patients were enrolled in control group. The age of patients in case group and control group were 50.9 ± 6.1 years and 52.2 ± 5.3 years respectively. Severe preoperative swelling was shown in 14 and 22 patients in case group and control group respectively. The time from injury to operation in the two groups were 3.8 ± 2.1 days and 3.7 ± 2.4 days respectively. Preoperative basic data and postoperative radiographic parameters were listed in Table 1. There was no significant difference between the two groups at baseline.

Table 1
The basic data of patients with intra-articular distal radius fractures.

	Case group	Control group	*P* value
No. of patients	33	48	
Age (years)	50.9 ± 6.1	52.2 ± 5.3	0.311
Gender (male/female)	15/18	20/28	0.821
Osteoporosis (yes/no)	12/21	19/29	0.819
Dominant extremity fracture (yes/no)	17/16	28/20	0.650
Preoperative swelling (slight/severe)	19/14	26/22	0.822
AO classification (type B/type C)	9/24	11/37	0.794
Associated ulnar styloid process fracture (yes/no)	11/22	18/30	0.815
Time from injury to operation (days)	3.8 ± 2.1	3.7 ± 2.4	0.847
Additional Kirschner wire fixation (yes/no)	20/13	24/24	0.373
Post-operative radial inclination (degree)	20.2 ± 3.4	21.1 ± 3.1	0.221
Post-operative volar tilt (degree)	6.5 ± 2.3	7.1 ± 2.7	0.300
Post-operative ulnar variance (mm)	2.3 ± 0.8	2.2 ± 0.5	0.491
Removal of volar plate (yes/no)	13/20	17/31	0.816
Assisted cast or splint fixation (yes/no)	18/15	22/26	0.502

At the final follow-up, ROM of pronation were 68.2 ± 6.4 degrees in case group, which is significantly lower than that in control group (76.1 ± 7.3 degrees, P < 0.001). Similarly, ROM of supination were 62.1 ± 5.8 degrees in case group, which is significantly lower than that in control group (69.2 ± 6.1 degrees, P < 0.001). Total ROM of rotation in case group and control group were 130.3 ± 6.2 degrees and 145.3 ± 6.7 degrees respectively, and the difference showed statistically significant (P < 0.001). Percentage of rotation ROM of contralateral limb in case group and control group were 72.3 ± 3.1% and 80.7 ± 3.6% respectively, and the difference showed statistically significant (P < 0.001). The details were shown in Fig. 2. VAS during forearm rotation were 2.1 ± 0.7 in case group, which is significantly higher than that in control group (1.5 ± 0.5, P < 0.001).

Discussion

The sigmoid notch of the radius is rarely studied because of its hidden position. In the current study, the sigmoid notch was clearly displayed by use of the 3D reconstruction technique with data transferred from

postoperative CT test, and corresponding details help to predict postoperative rotation function and pain score during activity. The results showed that patients with gaps or steps on sigmoid notch not only limit forearm pronation rotation as well as supination rotation, but also cause apparent wrist pain during forearm rotation movement.

Three-dimensional reconstruction technology has been rapidly developed in the medical field, and has become feasible and accessible for wild application in orthopedic surgery[9–11]. It is extremely helpful for preoperative evaluation and planning as well as for intraoperative navigation, but few studies used this technique to predict the outcomes of DRUJ after surgical treatment of DRFs. After the CT images are transformed into 3D images, the occlusion of other bones can be well solved. The ulna and carpal bones are easily removed, and thus surface of sigmoid notch can be clearly displayed, which make following measurement, classification and further analysis become feasible [12].

Free forearm rotation relies on a normal structure of proximal radioulnar joint as well as distal radioulnar joint. DRUJ comprises the distal radius, ulna, and triangular fibrocartilage complex. Malunited DRFs was frequently found to cause forearm rotational restriction, for example, previous studies have revealed that a dorsal angulated deformity of more than 30° causes pronation restriction and a volar angulated deformity of more than 20° causes supination restriction [13, 14]. Radial shortening of 10 mm also causes rotational restriction [15]. However, the association of contact area with forearm rotation is rarely investigated. The sigmoid notch not only serves as an anchor for the TFCC that plays an important role in DRUJ stability, but also provide a smooth articular surface for rotation movement. When the fracture line or displaced fragment of distal radius involving the sigmoid notch, the tension of the TFCC may be changed, which would produce a rotation dysfunction of the forearm [5, 16]. Besides, the gaps or steps could cause articular incongruity of the DRUJ and limited forearm rotation. This could explain our final result that both the pronation and supination rotation was restricted in patients with fractured sigmoid notch in comparison with those without.

Postoperative pain is common in DRFs patients even after surgical treatment[17]. Irregular articular surface has been demonstrated to be the main reason to increase the risk of traumatic osteoarthritis and to cause unsatisfactory function recovery [18–20], and if it is associated with postoperative pain remains unclear. To clarify this confusion, we made a comparison, and the results showed that patients with gaps or steps on sigmoid notch have significant more severe pain during forearm rotation at the one-year follow-up. We supposed that postoperative pain symptoms begin much earlier before osteoarthritis develops. This information allows doctors to have a clearer understanding of the prognosis of fracture, and to better communicate with patients.

This study has several limitations. First of all, this is a retrospective study. The study design and potential for bias are the typical restrictions of our study. Secondly, the exact degree of reduction by surgery which left minimized rotation dysfunction has not been established. Thirdly, limited by the accuracy of CT test, the current technology is unable to differentiate tiny fracture fragments, especially in patients with severely comminuted fractures. Finally, the follow-up time is relatively short, which is only one year. Wrist

degenerative changes or osteoarthritis may occur in long-term follow-up, and should be recorded in further studies.

Conclusions

This study proposed a new method to assess the articular surface of sigmoid notch which is based on three-dimensional reconstruction images. With the assistance of this method, we found that gaps or steps on sigmoid notch not only limit forearm pronation rotation and supination rotation, but also cause apparent wrist pain during forearm rotation movement. This information help doctors to have a better understanding of the prognosis of intra-articular DRFs.

List Of Abbreviations

DRFs, distal radius fractures; ROM, range of motion; DRUJ, distal radioulnar joint; TFCC, triangular fibrocartilage complex; CT, computed tomograph; VAS, visual analogue scale; SD, standard deviation

Declarations

Acknowledgements

The authors would like to thank Bin Wang for his help in collecting data.

Disclosure

The author reports no conflicts of interest in this work.

Authors' contributions

BZ conceptualized and designed the study, drafted the initial manuscript, and reviewed and revised the manuscript. LDK, MF and ZZZ designed the data collection instruments, collected data, carried out the initial analyses, and reviewed and revised the manuscript. JL and YQZ coordinated and supervised data collection, and critically reviewed the manuscript for important intellectual content. All authors approved the final manuscript as submitted and agree to be accountable for all aspects of the work.

Funding

None.

Availability of data and materials

Not applicable.

Ethics approval and consent to participate

This study was approved by the Research and Ethics Committee of the Third Hospital of Hebei Medical University, and all patients gave written informed consent for their information to be stored in the database of this hospital and used for medical research.

Consent for publication

Consent for publication was obtained from every individual whose data are included in this manuscript.

Competing interests

The authors declare that they have no competing interests.

Conflicts of Interest/Disclosures:

The authors declare that they have no financial or other conflicts of interest in relation to this research.

References

1. Kong L, Lu J, Zhou Y*, et al*. Incidence and risk factors for redisplacement after closed reduction and instant rigid cast immobilization for paediatric distal radius fractures: a case control study. J Orthop Surg Res 2020,15:140.
2. O'Neill TW, Cooper C, Finn JD*, et al*. Incidence of distal forearm fracture in British men and women. Osteoporos Int 2001,12:555-8.
3. Kong L, Kou N, Wang Y*, et al*. The Necessity of Restoration of Radiologic Parameters by Closed Reduction in Elderly Patients with Distal Radius Fractures. Med Sci Monit 2019,25:6598-604.
4. Kong L, Zhai Y, Zhang Z*, et al*. Radiocarpal joint stiffness following surgical treatment for distal radius fractures: the incidence and associated factors. J Orthop Surg Res 2020,15:313.
5. Yan B, Chen Y, Yin W. Influence of distal radius fractures involving the intermediate column on forearm rotation. J Orthop Surg Res 2019,14:111.
6. Mok D, Chidambaram R, Nakamura T. Causes of a block to forearm rotation after distal radius fractures. J Wrist Surg 2013,2:180-5.
7. Kong L, Yang G, Yu J*, et al*. Surgical treatment of intra-articular distal radius fractures with the assistance of three-dimensional printing technique. Medicine (Baltimore) 2020,99:e19259.
8. Kim J, Cho J, Lee YH*, et al*. Distal radioulnar joint configurations in three-dimensional computed tomography in patients with idiopathic ulnar impaction syndrome. J Hand Surg Eur Vol 2019,44:488-95.
9. Chen C, Cai L, Zhang C*, et al*. Treatment of Die-Punch Fractures with 3D Printing Technology. J Invest Surg 2018,31:385-92.
10. Shuang F, Hu W, Shao Y*, et al*. Treatment of Intercondylar Humeral Fractures With 3D-Printed Osteosynthesis Plates. Medicine 2016,95:e2461.

11. Baumbach SF, Binder J, Synek A*, et al*. Analysis of the three-dimensional anatomical variance of the distal radius using 3D shape models. Bmc Med Imaging 2017,17:23.
12. Bizzotto N, Tami I, Tami A*, et al*. 3D Printed models of distal radius fractures. Injury 2016,47:976-8.
13. Fraser GS, Ferreira LM, Johnson JA*, et al*. The effect of multiplanar distal radius fractures on forearm rotation: in vitro biomechanical study. J Hand Surg Am 2009,34:838-48.
14. Nishiwaki M, Welsh MF, Gammon B*, et al*. Effect of Volarly Angulated Distal Radius Fractures on Forearm Rotation and Distal Radioulnar Joint Kinematics. J Hand Surg Am 2015,40:2236-42.
15. Bronstein A, Heaton D, Tencer AF*, et al*. Distal radius malunion and forearm rotation: a cadaveric study. J Wrist Surg 2014,3:7-11.
16. Scheer JH, Adolfsson LE. Patterns of triangular fibrocartilage complex (TFCC) injury associated with severely dorsally displaced extra-articular distal radius fractures. Injury 2012,43:926-32.
17. Egund L, Önnby K, Mcguigan F*, et al*. Disability and Pain are the Best Predictors of Sick Leave After a Distal Radius Fracture in Men. J Occup Rehabil 2020.
18. Katayama T, Ono H, Omokawa S. Comparison of Five Years Clinical and Radiological Outcomes between Progressive and Non-Progressive Wrist Osteoarthritis after Volar Locking Plate Fixation of Distal Radius Fractures. J Hand Surg Asian Pac Vol 2019,24:30-5.
19. Forward DP, Davis TR, Sithole JS. Do young patients with malunited fractures of the distal radius inevitably develop symptomatic post-traumatic osteoarthritis? J Bone Joint Surg Br 2008,90:629-37.
20. Wadsten MÅ, Buttazzoni GG, Sjödén GO*, et al*. Influence of Cortical Comminution and Intra-articular Involvement in Distal Radius Fractures on Clinical Outcome: A Prospective Multicenter Study. J Wrist Surg 2017,6:285-93.

Figures

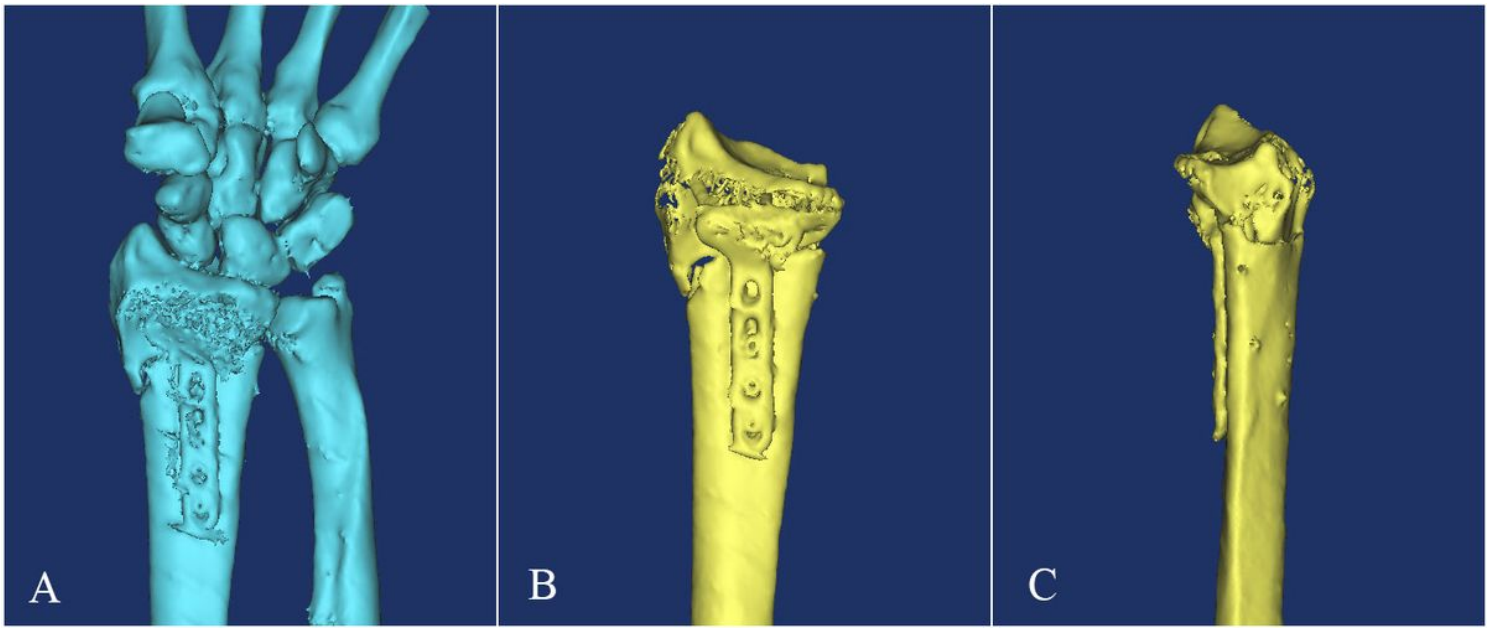

Figure 1

The 3D reconstruction images of distal radius. A. the wrist joint was reconstructed; B. the distal radius was separated from the carpal bone and ulnar bone; C. the 3D reconstruction image of sigmoid notch was shown.

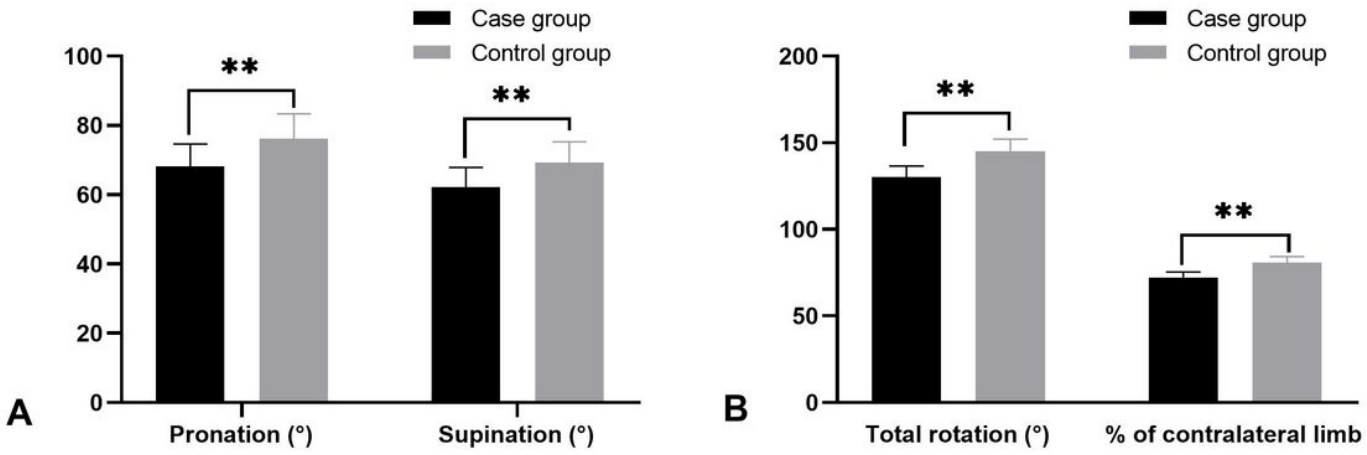

Figure 2

The histogram showing the function results of forearm rotation. A. the results of forearm pronation and supination; B. the results of total rotation and percentage of contralateral limb. **, P<0.001.