Intra-Articular Opening Osteotomy Combined with Lateral Ligament Reconstruction for Varus Ankle Arthritis

Yang Xu
Shanghai Jiao Tong University Medical School Affiliated Ruijin Hospital
Xing-chen Li
Shanghai Jiao Tong University Medical School Affiliated Ruijin Hospital
Chang-jun Guo
Shanghai Jiao Tong University Medical School Affiliated Ruijin Hospital
Xiang-yang Xu (xu664531@hotmail.com)
Shanghai Jiao Tong University Medical School Affiliated Ruijin Hospital

Research article

Keywords: ankle arthritis, osteotomy, lateral ligament reconstruction

Posted Date: September 21st, 2020

DOI: https://doi.org/10.21203/rs.3.rs-77020/v1

Version of Record: A version of this preprint was published on January 6th, 2021. See the published version at https://doi.org/10.1186/s13018-020-02143-1.

Abstract

Background

One type of Takakura 3B ankle arthritis is varus talus with medial disital tibial platform erosion. Among these cases, the tibial anterior surface (TAS) angles are usually normal. The purpose of this study was to evaluate the therapeutic outcomes of intra-articular opening osteotomy combined with lateral ligament reconstruction for Takakura 3B ankle arthritis with medial disital tibial platform erosion.

Methods

From September 2009 to May 2016, 17 patients with Takakura 3B ankle arthritis were reviewed, including 3 male and 14 female patients. All underwent the operation of intra-articular opening osteotomy combined with lateral ligament reconstruction. All patients were available for analysis. The main outcome measurements included TT angle, AOFAS score, VAS score, SF-36 scale and AOS scale.

Results

All patients were followed for a mean follow-up of 87.2 months (range, 49 to 129 months). The VAS scale improved from 5.5 ± 1.6 to 2.3 ± 1.9. The mean AOFAS score improved from 47.7 ± 15.7 to 75.8 ± 12.0. The SF-36 scale improved from 41.6 ± 14.0 to 67.7 ± 14.6. The AOS improved from 60.9 ± 13.9 to 28.2 ± 17.7. The TT angle improved from 14.3 ± 5.0° to 5.3 ± 4.0°.

Conclusion

Intra-articular opening osteotomy combined with lateral ligament reconstruction is an effective method to treat varus ankle arthritis with medial disital tibial platform erosion.

Background

According to Takakura and Tanaka, varus ankle arthritis was classified into four types: Stage1, early sclerosis and formation of osteophytes without changing of ankle joint space; Stage2, narrowing of medial joint space without subchondral bone contact; Stage3, obliteration of ankle space with subchondral bone contact; Stage4, varus ankle joint with complete bone contact. Stage 3 was further classified into stage 3A and 3B. Stage 3B ankle arthritis was defined as obliteration of ankle space extended to the roof of the dome of talus with subchondral bone contact[1, 2].

For young adults and those who do not want to sacrifice the native ankle joint, joint-sparing methods instead of total ankle replacement or ankle arthrodesis are very important. Supramalleolar osteotomy is

an effective joint-sparing surgical treatment for varus type ankle arthritis, especially those with small TAS angles[1–7].

In our practice, we do notice positive outcomes after supramalleolar osteotomy for stage 3B ankle arthritis[8]. However, in some cases, the varus talus repeatedly abrades medial disital tibial platform after long walking. The medial tibial platform is eroded but the general TAS angle is normal. Previous studies reported a new kind of technique known as intra-articular opening medial tibial wedge osteotomy with good results[9, 10]. However, stage 3B ankle was considered not suitable for this osteotomy. In Myerson's study, 4 patients had a type 3B deformity. Two of them underwent ankle arthrodesis and two underwent ankle replacement after the intra-articular opening osteotomy.[9]

The purpose of this study was to evaluate the therapeutic outcomes of intra-articular opening osteotomy combined with lateral ligament reconstruction for Takakura 3B ankle arthritis with medial distal tibial platform erosion.

Materials And Methods

The current study was approved by our institutional review board. From September 2009 to May 2016, 17 patients (17 ankles, 7 left and 10 right) with Takakura 3B ankle arthritis were reviewed, including 3 male and 14 female patients. All underwent the operation of intra-articular opening osteotomy combined with lateral ligament reconstruction. The mean age was 52.35 ± 8.05 years. The inclusion criteria were: (1) Takakura stage 3B ankle arthritis; (2) medial distal tibial platform erosion; (3) normal lateral tibial surface; (4) painful ankle arthritis undergoing at least 1 year’s conservative treatment.

The exclusion criteria were: (1) end stage ankle arthritis; (2) patients with neuropathic arthropathy or rheumatoid arthritis; (3) patients with regional infection around ankle joint or had other ankle surgeries; (4) patients with severe osteoporosis or large bone loss.

Weightbearing X-rays of ankle joint were performed for every patient preoperatively and postoperatively, including anteroposterior ankle views (AP), lateral ankle views. In this study, we recorded tibial articular surface angle (TAS), talar tilt angle (TT) from the AP view, tibial lateral surface angle (TLS) from the lateral view. We routinely reviewed ankle MRI scans for every patient to evaluate the cartilage condition. We used the American Orthopaedic Foot & Ankle Society Ankle-Hindfoot Score (AOFAS-AH), the Visual Analogus Scale (VAS), the Short From-36 scale (SF-36) and the Ankle Osteoarthritis scale (AOS) to determine the functional outcome of patients at the final follow-up. (Fig. 1)

Surgical technique

In this study, all ankle arthritis were varus type. The osteotomy approach was through a medial longitudinal incision. A K-wire was placed as a guide wire of osteotomy. Two or three K-wires were placed parallel to the ankle joint surface portion of the tibial platform within the subchondral bone just under the

articular cartilage at the apex of the plafond angulation. They help prevention of destruction of talus cartilage from the saw blade during the osteotomy. It also acted as a hinge during deformity correction. Then the intra-articular osteotomy was performed. The intraoperation fluoroscopic assessment was performed to evaluate whether the tibial articular surface was normal. If the varus talus could not return to normal, then a release procedure of medial ankle ligament including the superficial and deep deltoid ligament was performed. Debridement of osteophytes was performed if there was impingement around ankle joint such as the anterior distal tibial osteophyte to improve ankle motion through the medial incision and lateral incision. A wedged allograft was shaped and inserted into the osteotomy site and was fixed by a locking plate. The ankle joint was placed into a neutral position and soft tissue including medial ligament was sutured. Lateral ligament reconstruction was performed via a minimally invasive method[11]. 15 patients used allograft, 2 patients autograft. Two guide wires were introduced at the distal end of the fibula, then a tunnel was made. A hole was made at the lateral side of the talar neck. These were all through the lateral incision. A small incision was made at the lateral side of middle portion of the calcaneus and a hole was made. The tendon graft was introduced through the tunnel and the two ends of the tendon were then passed above the bone surface to the holes made at the talar neck and calcaneus fixed by two biodegradable inference screws. The ligament procedures were performed after fixation of osteotomy.(Fig. 2)

A cast was used for 6 weeks. Part weight bearing was allowed 6 weeks postoperatively with the cast. Full weight bearing was allowed two to three months postoperatively. Patients came to hospital two weeks, six weeks, 3 months and 1 year postoperatively.

Statistical methods

All analyses were performed with the SAS software version 8.1 (SAS Institute Inc, Cary, North Carolina). The results were given as means and standard deviation. The paired t test was used for assessing differences between preoperative and postoperative measurements. A p value less than 0.05 was considered to indicate statistical significance.

Results

All patients were followed. Patients were followed for a mean follow-up of 87.2 months (range, 49 to 129 months). There was no loss of follow-up. The VAS scale improved from 5.5 ± 1.6 to 2.3 ± 1.9. The mean AOFAS score improved from 47.7 ± 15.7 to 75.8 ± 12.0. The SF-36 scale improved from 41.6 ± 14.0 to 67.7 ± 14.6. The AOS improved from 60.9 ± 13.9 to 28.2 ± 17.7. The TT angle improved from 14.3 ± 5.0° to 5.3 ± 4.0°. The preoperative TAS and TLS angle were 90.9° and 77.6°, while the postoperative TAS and TLS were 91.3° and 78.1°.

In this study, 2 patients rated their outcomes as “excellent”, 7 patients rated their outcomes as “good”. 4 patients rated their results as “fair”. On the other hand, a “poor” outcome was observed in 4 patients

because of the consistent discomfort. However, none of the patients underwent ankle joint arthroplasty or arthrodesis because of the cost involved or other reasons.

The radiographic parameters including the TAS and TLS angle showed no statistically significant different compared with preoperative condition. 10 patients underwent calcaneal osteotomy.

13 patients recalled an old ankle sprain history. All of them had a long-term ankle sprain history (5–38 years). 1 patient had a lateral malleolar fracture history. 3 patients had no incentive. (Fig. 3, Fig. 4)

Discussion

The causes of varus type ankle arthritis still remain unknown. In other studies, usually, ankle arthritis develops secondary to trauma[4, 7, 12]. However, in this study, more patients recalled an old ankle sprain history. We thought that maybe it was because of the weak lateral ligament resulted in varus type ankle arthritis.

Takakura and Tanaka divided varus ankle arthritis into 4 stages, stage 1, 2, 3 (3A, 3B) and 4[1, 2]. Did stage 3B ankle arthritis develop directly from stage 3A? This is controversial. We do not think all of the stage 3B ankle arthritis were evolved from stage 3A ankle arthritis. When the talus invert in ankle mortise, with long time of walking, the varus talus touch the tibia surface and abrade it gradually. So, maybe the stage 3B ankle arthritis developed directly from stage 2.

One of the causes of varus type ankle arthritis was chronic ankle instability. [13, 14] In this study, all patients underwent lateral ligament reconstruction. Most of the patients in our study recalled repeated ankle sprain histories. The weak lateral ligament resulted in chronically unstable varus ankle. The medially driven talus causes chronic pressure to medial malleolus, which makes medial malleolus no longer vertical. [9] Although some patients in this study had no ankle sprain histories, there were still ankle instabilities after release of ligaments around ankle joint and debridement of osteophytes. When the talus could return to normal during operation, we think lateral ligament reconstruction was very important to keep the talus in this position.

For varus ankle arthritis, especially Takakura stage 3 or 4 ankle arthritis, previous studies has reported good results of ankle arthrodesis or ankle replacement[15–19]. However, ankle arthrodesis is a joint sacrifice method to treat ankle arthritis, which restrict ankle movement. In this study, the mean age of patients was 52.35 ± 8.05 years. The patients are relatively young, so ankle arthroplasty may not be suitable for them. These patients were still very positive and want to keep their native ankle joint. Osteotomy provided the possibility to preserve their native ankle joint.

Previous studies reported that it was contraindication if the varus ankle was rigid and could not be corrected to normal under fluoroscopic examination before the surgery[9, 20]. However, in our study, we concern more about whether the varus ankle could return to normal intraoperatively or not. We performed thorough release of ligaments and capsule around ankle joint if the varus deformity could not be

corrected after osteotomy. After the release and debridement procedure, the ankle joint was flexible and we fixed it into neutral position with 1–2 K-wires, which were removed 3–4 weeks postoperatively. In this position, the medial ligaments were sutured and lateral ligaments were reconstructed. We think that whether the varus ankle could return to normal during operation matters more than preoperative condition. We care more about the joint cartilage than preoperative talar tilt angle.

We think the most important aspect of this kind of procedure is that there is enough residual articular cartilage. Ankle joints with more than 50% residual articular cartilage tends to get better prognosis than those are not. So, we did osteotomy procedure for this kind of ankle arthritis. We do not perform osteotomy surgery for stage IV ankle arthritis. Joint cartilage of stage IV ankle arthritis was always extensively destructed. For this kind of patients, even though realignment of ankle joint may alleviate symptoms, joint damage will progress soon.

Conclusion

For Takakura 3B ankle arthritis with medial distal tibial erosion, intra-articular opening osteotomy combined with lateral ligament reconstruction is an effective method to treat this kind of varus ankle arthritis.

Abbreviations

AOFAS: The American Orthopaedic Foot and Ankle Society Ankle-Hindfoot scores;

SF-36: The Short Form (36) Health Survey

VAS: Visual Analogus Scale,

AOS: Ankle Osteoarthritis scale

TT: Talar tilt angle

TAS: tibial articular surface angle

TLS: tibial lateral surface angle

Declarations

Acknowledgements

The authors gratefully acknowledge all collaborating researchers in collecting information during this study. We would also like to thank the subjects whose participation made this investigation possible.

Funding

This study was funded by National Natural Science Foundation of China grants (No. 81772372).

Availability of data and materials

All data and materials were in full compliance with the journal's policy.

Authors' contributions

YX carried out the literature research, experimental studies, statistical analysis, and manuscript preparation. X-CL,G-CJ participated in the experimental studies and manuscript editing. X-YX made the concepts, study design, and experimental studies. All authors read and approved the final manuscript.

Ethics approval and consent to participate

This study was approved by the ethics committee of Ruijin Hospital, Shanghai Jiaotong University School of Medicine. A written consent to participate was provided by participants included in the study.

Consent for publication

All patients enrolled into the study agree the use of patients' data for research.

Competing interests

The authors declare that they have no competing interests.

Uncategorized References

1. Takakura Y, Tanaka Y, Kumai T, Tamai S: **Low tibial osteotomy for osteoarthritis of the ankle. Results of a new operation in 18 patients**. *J Bone Joint Surg Br* 1995, **77**(1):50-54.
2. Tanaka Y, Takakura Y, Hayashi K, Taniguchi A, Kumai T, Sugimoto K: **Low tibial osteotomy for varus-type osteoarthritis of the ankle**. *J Bone Joint Surg Br* 2006, **88**(7):909-913.
3. Krahenbuhl N, Zwicky L, Bolliger L, Schadelin S, Hintermann B, Knupp M: **Mid- to Long-term Results of Supramalleolar Osteotomy**. *Foot Ankle Int* 2017, **38**(2):124-132.
4. Hintermann B, Knupp M, Barg A: **Supramalleolar Osteotomies for the Treatment of Ankle Arthritis**. *J Am Acad Orthop Surg* 2016, **24**(7):424-432.
5. Ahn TK, Yi Y, Cho JH, Lee WC: **A cohort study of patients undergoing distal tibial osteotomy without fibular osteotomy for medial ankle arthritis with mortise widening**. *J Bone Joint Surg Am* 2015, **97**(5):381-388.
6. Lee WC, Moon JS, Lee K, Byun WJ, Lee SH: **Indications for supramalleolar osteotomy in patients with ankle osteoarthritis and varus deformity**. *J Bone Joint Surg Am* 2011, **93**(13):1243-1248.
7. Takakura Y, Takaoka T, Tanaka Y, Yajima H, Tamai S: **Results of opening-wedge osteotomy for the treatment of a post-traumatic varus deformity of the ankle**. *J Bone Joint Surg Am* 1998, **80**(2):213-

218.

8. Xu Y, Xu XY: **Medial Open-Wedge Supramalleolar Osteotomy for Patients with Takakura 3B Ankle Osteoarthritis: A Mid- to Long-Term Study**. *Biomed Res Int* 2019, **2019**:7630868.
9. Mann HA, Filippi J, Myerson MS: **Intra-articular opening medial tibial wedge osteotomy (plafond-plasty) for the treatment of intra-articular varus ankle arthritis and instability**. *Foot Ankle Int* 2012, **33**(4):255-261.
10. Becker AS, Myerson MS: **The indications and technique of supramalleolar osteotomy**. *Foot Ankle Clin* 2009, **14**(3):549-561.
11. Xu X, Hu M, Liu J, Zhu Y, Wang B: **Minimally invasive reconstruction of the lateral ankle ligaments using semitendinosus autograft or tendon allograft**. *Foot Ankle Int* 2014, **35**(10):1015-1021.
12. Knupp M, Bolliger L, Hintermann B: **Treatment of posttraumatic varus ankle deformity with supramalleolar osteotomy**. *Foot Ankle Clin* 2012, **17**(1):95-102.
13. Harrington KD: **Degenerative arthritis of the ankle secondary to long-standing lateral ligament instability**. *J Bone Joint Surg Am* 1979, **61**(3):354-361.
14. Noguchi K: **Biomechanical analysis for osteoarthritis of the ankle**. *Nihon Seikeigeka Gakkai Zasshi* 1985, **59**(2):215-222.
15. Joo SD, Lee KB: **Comparison of the outcome of total ankle arthroplasty for osteoarthritis with moderate and severe varus malalignment and that with neutral alignment**. *Bone Joint J* 2017, **99-B**(10):1335-1342.
16. Lee GW, Wang SH, Lee KB: **Comparison of Intermediate to Long-Term Outcomes of Total Ankle Arthroplasty in Ankles with Preoperative Varus, Valgus, and Neutral Alignment**. *J Bone Joint Surg Am* 2018, **100**(10):835-842.
17. Trajkovski T, Pinsker E, Cadden A, Daniels T: **Outcomes of ankle arthroplasty with preoperative coronal-plane varus deformity of 10 degrees or greater**. *J Bone Joint Surg Am* 2013, **95**(15):1382-1388.
18. Maenohara Y, Taniguchi A, Tomiwa K, Tsuboyama D, Kurokawa H, Kumai T, Tanaka S, Tanaka Y: **Outcomes of Bilateral vs Unilateral Ankle Arthrodesis**. *Foot Ankle Int* 2018, **39**(5):530-534.
19. Grass R, Rammelt S, Biewener A, Zwipp H: **Arthrodesis of the ankle joint**. *Clin Podiatr Med Surg* 2004, **21**(2):161-178.
20. Hintermann B, Ruiz R, Barg A: **Novel Double Osteotomy Technique of Distal Tibia for Correction of Asymmetric Varus Osteoarthritic Ankle**. *Foot Ankle Int* 2017, **38**(9):970-981.

Tables

Table I:
summarized demographic data

parameter	Data
Number of ankles, n	17
Male:female,n(%)	3:14
Side (left:right),n(%)	7:10
Age at surgery(y)	52.35 ± 8.05
History (%)	
Ankle sprain	13(76.47%)
Ankle fracture	1(5.9%)
None	3(17.65%)

Table II:
Radiographic and functional outcomes

	Preop	postop	p
VAS	5.5 ± 1.6	2.3 ± 1.9	< 0.001
AOFAS	47.7 ± 15.7	75.8 ± 12.0	< 0.001
SF-36	41.6 ± 14.0	67.7 ± 14.6	< 0.001
AOS	60.9 ± 13.9	28.2 ± 17.7	< 0.001
TT (°)	14.3 ± 5.0	5.3 ± 4.0	< 0.001
TAS (°)	90.9 ± 2.9	91.3 ± 3.1	0.55
TLS (°)	77.6 ± 2.1	78.1 ± 2.3	0.71

Figures

Figure 1

Determine the functional outcome of patients at the final follow-up.

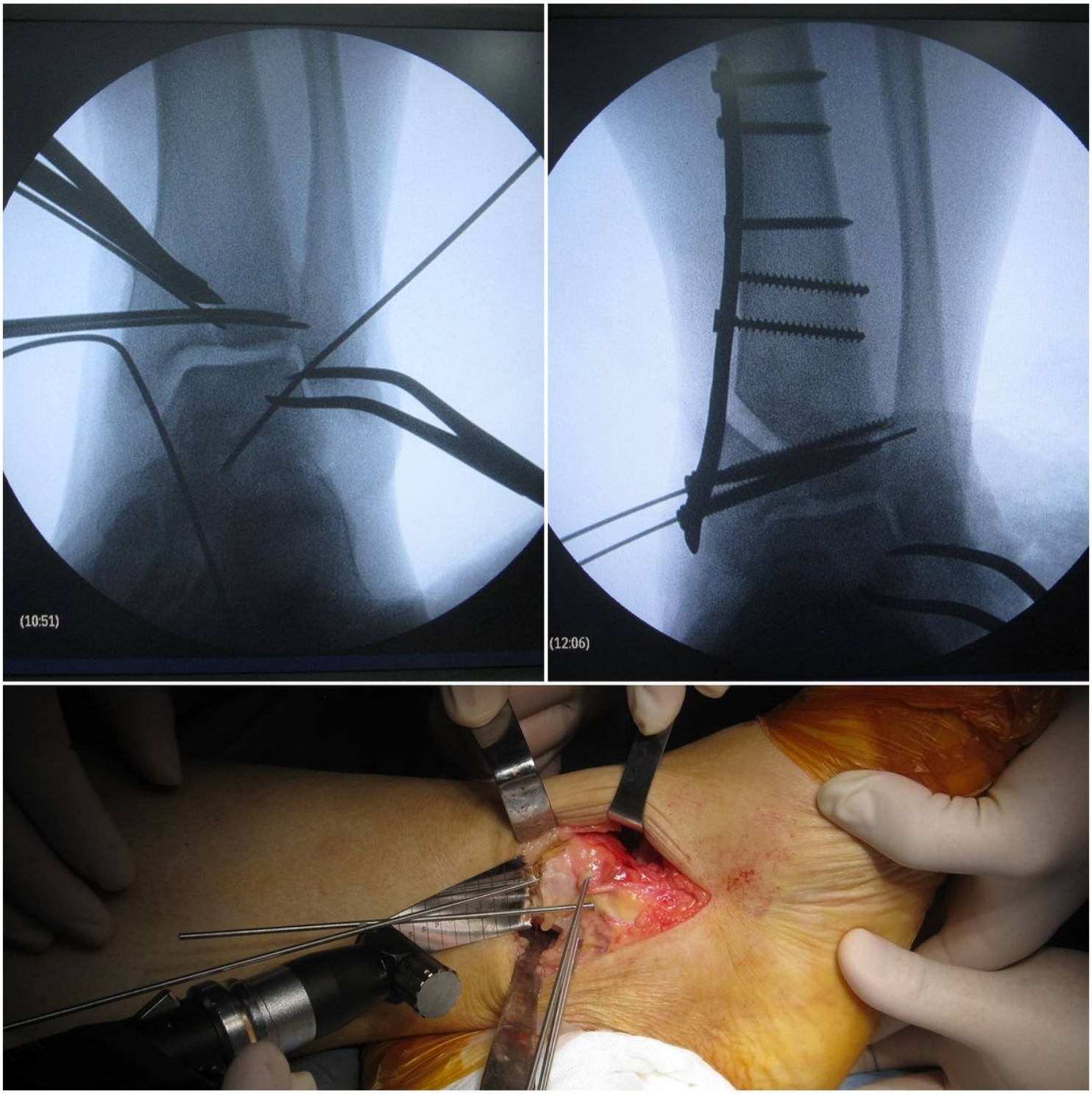

Figure 2

The ligament procedures were performed after fixation of osteotomy.

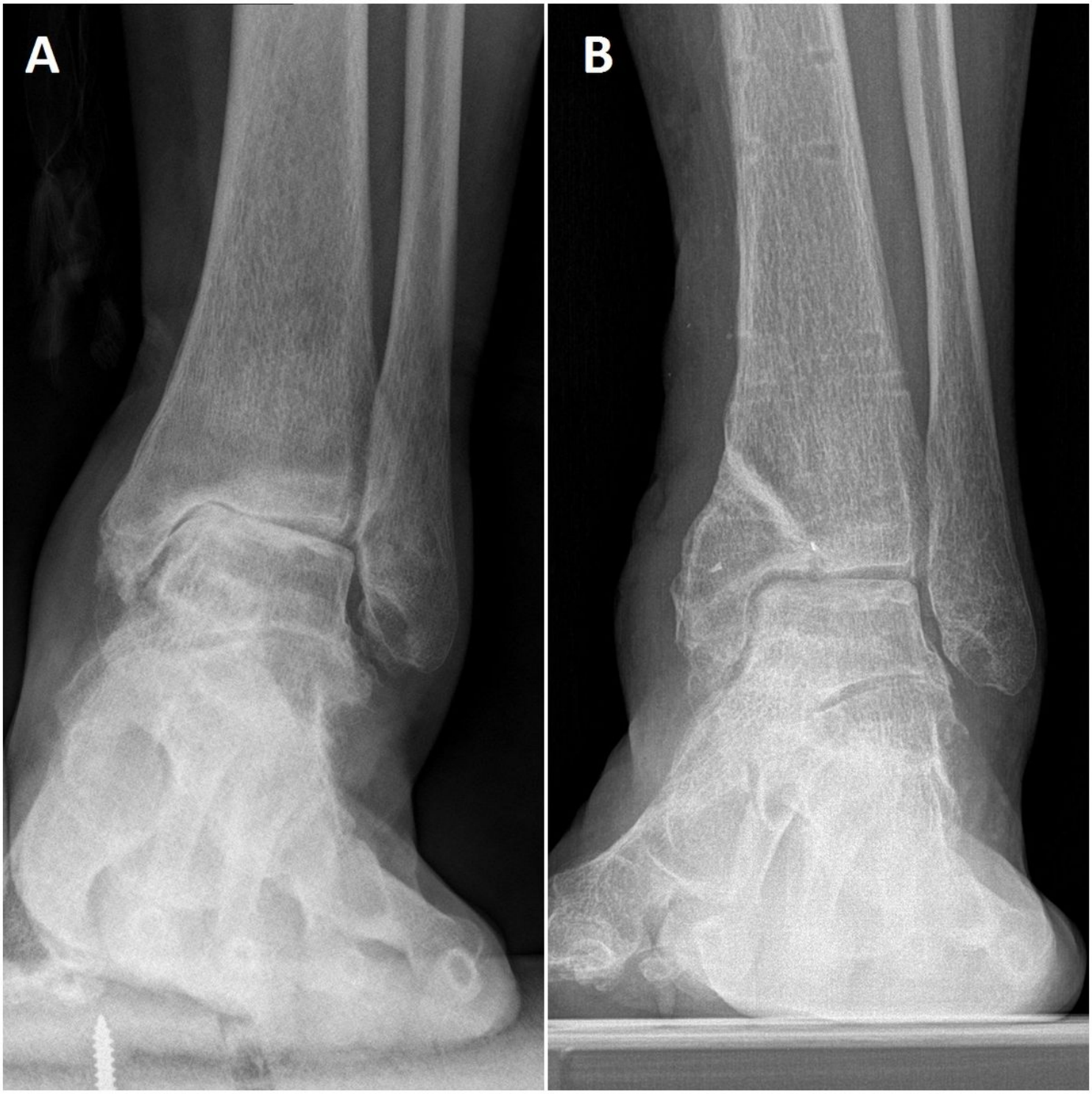

Figure 3

13 patients recalled an old ankle sprain history. All of them had a long-term ankle sprain history (5-38 years). Patient had a lateral malleolar fracture history

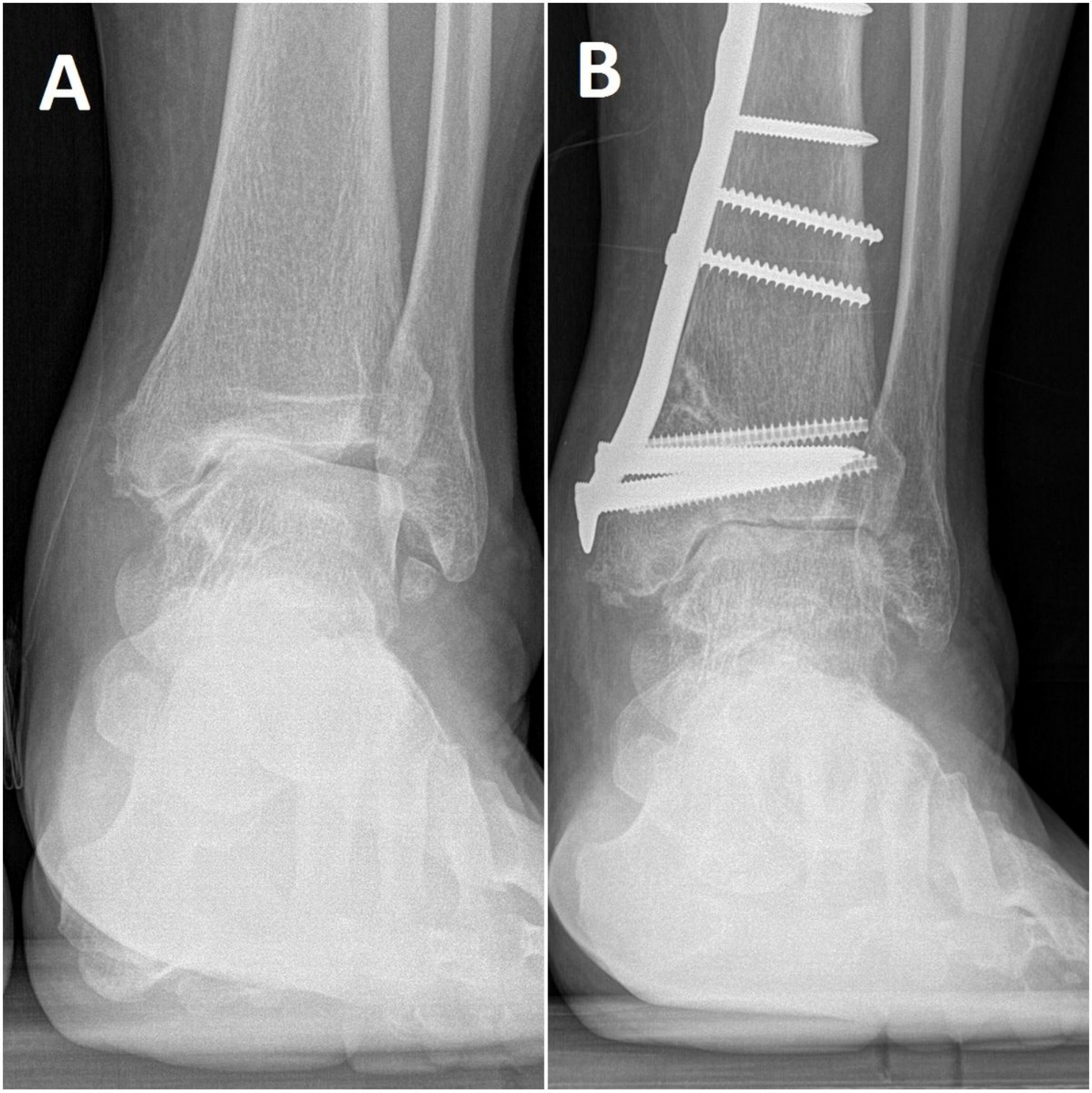

Figure 4

13 patients recalled an old ankle sprain history. All of them had a long-term ankle sprain history (5-38 years). Patients had no incentive.