Observational study for laryngeal mask anesthesia combined with nerve block in internal fixation for rib fractures

Jun Cao (18930173661@189.cn)
Shanghai Sixth People's Hospital https://orcid.org/0000-0002-2645-9245

Junfeng Zhang
Shanghai Sixth Peoples Hospital

Xiaoyun Gao
Shanghai Sixth Peoples Hospital

Xiaoli Zhang
Shanghai Sixth Peoples Hospital

Jing Li
Shanghai Sixth Peoples Hospital

Research article

Keywords: Laryngeal mask anesthesia; Non-tracheal intubation; Thoracic paravertebral block; Erector spinae plane block; Rib fractures

Posted Date: February 10th, 2020

DOI: https://doi.org/10.21203/rs.2.17107/v2

Version of Record: A version of this preprint was published on July 15th, 2020. See the published version at https://doi.org/10.1186/s12871-020-01082-y.

Abstract

Background: General anesthesia with endotracheal intubation always has been considered mandatory for rib fractures surgery. Recently, there has been interestng in nonintubated technique of LMA anesthesia for lung surgery. We developed a protocol with laryngeal mask(LMA) anesthesia combined with nerve block for rib fractures surgery, and performed it in several cases prospectively. Methods: Twenty patients undergoing unilateral rib fractures surgery were enrolled. Thoracic paravertebral block(TPB) and/or erector spinae plane block(ESPB) were carried out before LMA anesthesia. The vital signs(HR, BP, SpO_2) and parameters of breath were gathered during the operation. The arterial blood gas analysis and chest film were performed preoperatively and on the next day after operation. All patients received postoperative continous analgesia pump contained with 500mg of tramadol and 16mg of lornoxicam after the operation, and intravenous 50mg flurbiprofen Bisindie in the ward. Postoperative nausea and vomiting(PONV) within 48 hours after surgery and NRS pain scoreat 6(T1), 12(T2), 24(T3) hours after surgery were assessed as well. We also recorded the incidence of perioperative reflux, aspiration and nerve block complications. Results: Thirteen males and seven females(mean age 54 years) were enrolled in this trial. 6(30%) had a flail chest, 9(45%) had haemothorax, 2(10%) had pulmonary contusion. The vital signs and spontaneous breathing were kept stable. End-tidal carbon dioxide concentrations($EtCO_2$) were in an acceptable range(no more than 63 mmHg in all cases). The mean value of postoperative PaO_2 was increased than that of preoperative PaO_2 (91.2±16.0 vs. 83.7±15.9 mmHg, P=0.004). The mean value of preoperative and postoperative $PaCO_2$ was(42.1±3.7 vs. 43.2±3.7mmHg, P=0.165) respectively. Postoperative NRS at T1, T2, T3 was (3±1, 2±2, 0) respectively. No one suffered from PONV. In addition, perioperative reflux, aspiration and nerve block complications didn't appear in all cases. Conclusions: The technique of laryngeal mask anesthesia combined with nerve block was feasible in the internal fixation for rib fractures.

Background

Rib fractures are one of the most common injuries following blunt trauma, occurring in approximately 10% of all trauma patients. Currently, most scholars believe that surgical stabilization should be considered in the patients with flail chest and multiple, severe displaced fractures.[1] In the past, general anesthesia with endotracheal intubation(ETI) was considered mandatory for ribs surgery. But it may cause ventilator-associated lung injury (VALI),[3] postoperative agitation, cognitive impairment,[4] nausea and vomiting frequently. In addition, the patients may suffer from delayed awakening or even re-intubation due to residual general anesthetics.[11] Recently, Enhanced recovery after surgery(ERAS) protocol is currently well established as the best care. A non-intubation technique such as LMA anesthesia combined with nerve block is a critical part of ERAS, and has been applied on thoracic surgery occasionally,[2] except surgery of rib fractures. Such patients usually suffer dyspnea from the complications like haemothorax, pneumothorax, atelectasis and paradoxical breathing. We observed several cases undergoing the surgery by this anesthesia, to evaluate the feasibility of the anesthesia in the operation of rib fractures.

Methods

Participants

This prospective, observational study was approved by the Ethics Committee of Shanghai Sixth People's Hospital(2019-53) and was registered at www.chictr.org.cn(ChiCTR1900023763). Twenty patients from June to August 2019, scheduled for surgical reduction and fixation of unilateral isolated rib fractures in our hospital, were enrolled in this study. The informed consent was signed by all patients. Inclusion criteria: 1.ASA I and II, 2. aged 18–70 years, 3. BMI<30, 4. Preoperative PaO_2> 60mmHg, 5. Preoperative $PaCO_2$< 50mmHg. Exclusion criteria: 1. Difficult airway, 2. Esophageal reflux, 3. Myasthenia gravis, 4. Abnormal coagulation system, 5. Gastric ulcer or hemorrhage, 6. Allergy to anesthesia-related drugs, 7. Asthma or chronic obstructive emphysema, 8. Pregnant women, 9. The patients presented with major thoracic vascular injuries.

Procedures

All patients fasted for at least 8 h. Noninvasive blood pressure(BP), pulse oximetry(SpO2), and electrocardiography were established when the patients were admitted to the operating room.

The ultrasound-guided TPB was performed with S-Nerve™ Ultrasound System (Fujifilm SonoSite Inc. Bothell, WA, USA). The patient was placed in a lateral decubitus position. Transversal Inferior Articular Process(IAP) approach was applied. A convex array probe (5-2 MHz; C60x; Fujifilm SonoSite Inc. Bothell, WA, USA) was used to visualize the vertebral lamina, internal intercostal membrane and parietal pleura for prescanning(Figure 1). A 22-gauge, 8-cm puncture needle (KDL medical apparatus and instruments Co. Wenzhou, China) was inserted into the thoracic paravertebral space(TPVS) from the lateral side. 20-30ml of ropivacaine 0.375% was injected with no air or blood aspiration.

The injection point of TPVS was selected according to the fracture rib segments requiring surgery (hereinafter referred to "surgical segments"). If the surgical segments were not more than 4 consecutive ribs, 20ml of ropivacaine was injected into the TPVS of the second fractured rib, which was so called single-level block. If the surgical segments were more than 4 consecutive ribs, each 15 ml of ropivacaine was injected into the TPVS of the second and fifth fractured ribs, so called double-level block. We adopt two-person mode in TPBs, one physician operated the ultra-sound probe and needle, the other person performed the injection and aspiration. Before the needle was inserted, Color Doppler ultrasound was used to confirm that there were no vessels on the way to TPVS.

In the case of posterior rib fractures, ESPB was performed to enhance the regional effect of patient’s back. Because it can produce sensory blockade over the posterior as well as anterolateral thorax, and apply more effective analgesia for posterior rib fractures.[19] 20ml of ropivacaine 0.375% was injected between the fifth thoracic vertebral transverse process and erector spinae muscle(ESM) on the injured side, by the transversal in-plane approach under ultrasound-guidance(Figure 1).

The effect of regional block was evaluated in 15 minutes after nerve blockade, the dermatomes of sensory loss were measured by acupuncture and rubbing with alcohol gauze. If patient felt painless while deep breathing and vigorous coughing, and the range of reduction area of cold or pinprick sensation covered the incision. We considered that regional effect was complete, and the patient could be performed with LMA anesthesia. Otherwise, the patient was adopted endotracheal intubation anesthesia directly, and was excluded from the observational objects.

Anesthesia was induced with 0.1ug/kg sufentanil, 3mg/kg propofol and 0.3mg/kg rocuronium successively. We inserted a LMA Supreme^{TM}(Teleflex Medical Co. Westmeath, Ireland) , and make the position was correct. A 14# gastric tube was placed in the esophagus regularly to reduce the gas which might escape into the esophagus during positive pressure ventilation, at the depth of 30cm from the upper incisor. Mechanical ventilation was commenced then: pressure-controlled volumn-guaranteed ventilation(PCV-VG) at 6 ml/kg and respiratory rate(RR) of 12 breaths/min. The inspiratory to expiratory ratio was 1:2.

During the operation, the oxygen concentration was 50%, and the flow rate was 2L/min. Sevoflurane concentration was adjusted in accordance with BP and HR, and the MAC value was adjusted between 0.7 and 1.2. Spontaneous breathing was maintained when it had recovered. A supplementary dose of 0.03 ug/kg sufentanil was allowed if HR was 20% faster than the basic value or RR was more than 20 breaths/min for surgical stimulation. Phenylephrine and atropine would be injected if necessary. At 15 minutes before the end of surgery, sevoflurane inhalation was ceased and 50mg flurbiprofen was infused intravenously. All patients didn’t receive any neuromuscular junction antagonist.

The patient would be converted to ETI anesthesia as follows: 1. surgical field was difficult to be exposed on account of muscular tension, 2. LMA couldn’t be placed in the right position, 3. hemodynamic instability occurred, 4. SpO_2 was less than 90% or concentration of $EtCO_2$ was more than 70mmHg persistently.

Postoperative continous analgesia(infusion rate 2ml/h, total volume 100ml) was conducted routinely. The analgesics contained with 500mg tramadol and 16mg lornoxicam. 50mg flurbiprofen was infused intravenously Bisindie in the ward. If the patient’s NRS was more than 4, 50mg pethidine would be administered intramuscularly as a remedy.

Data Collection

BP, HR, SpO_2 were gathered during the anesthesia, Vt, RR, $EtCO_2$ during spontaneous breathing were recorded. Another investigator recorded the postoperative extubation time and the events of agitation or hoarseness in the PACU. The preoperative and postoperative arterial blood gas analysis and chest film were obtained regularly.

PONV within 48 hours after surgery and NRS pain score at 6(T1), 12(T2), 24(T3) hours after surgery were assessed as well. We also gathered dosages of sufentanil and vasoactive drugs administered, the degree

of surgeon's satisfaction, and the case which would be converted to ETI during the operation.

Statistical Analysis

SPSS 19.0 software was used for statistical analysis. Quantitative variables were expressed as means±SD. Categorical variables were expressed as quantitative value or percentage. The results of arterial blood gas analysis which measured pre/post-operatively were compared using the chi-square test or Fisher's exact test. $P<0.05$ was considered to be statistically significant.

Results

Twenty patients were enrolled in this study, and their characteristics were shown in Table 1. There were 8 cases (40%) received single-level TPB, the rest of 12 cases (60%) received double-level TPB. ESPB was combined in 13 cases (65%). All of the cases had perfect block effect, and received LMA anesthesia.

Patients' MAPs were shown in Figure 2. Among them, 8 patients' (40%) MAPs were less than 60 mmHg and were maintained by phenylephrine. The dosage of phenylephrine was 80-300(200 ± 76) μg. Patients' SpO_2 before anesthesia was 96±3.6%, and remained above 95% (99.1±1.3%) during the operation, except in one patient. His SpO_2 decreased from 100% to 87% transiently, but recovered to 98% within 5 minutes. The duration from LMA inserted to spontaneous breathing recovered was 27.25±19.43 minutes. The ranges of Vt, RR and $EtCO_2$ during spontaneous breathing were shown in Figure 3. One patient's $EtCO_2$ exceeded 60 mmHg, which ranged from 57 to 63 mmHg.

Time of extubation was 1-11(6±3) minutes. None of the patients had agitation or sore throat after anesthesia. Perioperative reflux, aspiration and nerve block complications didn't appear in all cases.

Blood gas analysis were shown in Figure 4. The mean PaO_2 of post-operation was increased than that of pre-operation(91.2±16.0 vs. 83.7±15.9 mmHg, P=0.004). Nevertheless, There was no significant difference between preoperative and postoperative $PaCO_2$(42.1±3.7 vs. 43.2±3.7mmHg, P=0.165).

Postoperative NRS at T1, T2, T3 was 3 ±1, 2 ± 2, 0 respectively(Figure 5). In our study, the highest score was 5 in four cases(20%). Two of them score 5 at 6 hours, and the other two cases at 12 hours after surgery. All four patients received an intramuscular injection of 50 mg pethidine once as rescue, and pain relieved. PONV didn't occur within 48 hours after surgery in all cases.

The dosage of sufentanil was 5-17(9.9±3.3) μg. No one needed atropine. Neither slight muscle twitching caused by high-frequency electrotome, nor thoracic excursion during breathing impeded the surgeon's operation. No one was converted to ETI anesthesia attributed to poor position of LMA or insufficient ventilation. The surgeons were satisfied with the anesthesia in all cases.

TABLE 1. Demographics and clinical characteristics of the patients

Variable	N	Mean	%
Sex (male/female)	13/7		
Age (y)	35-70	54.15±8.67	
BMI (kg/m ^{2})	19.1-29.7	24.29±2.75	
Flail chest	6		30
Haemothorax or/and pneumothorax	10		50
atelectasis	5		25
Pulmonary contusion	2		10
Thoracic drainage placed in surgery	9		45
Duration of surgery (minutes)		70±21	

Discussion

Patients suffering from rib fractures with flail chest and multiple, severe displaced fractures are at risk of respiratory failure. Surgical treatment is thought to be beneficial to early recovery.[1] The anesthesiologists' concerns are not only the patients' oxygenation in the operation, but also the successful extubation after surgery. It seems that LMA anesthesia combined with nerve block is fit for the above-mentioned concerns, because the technique can provide supraglottic airway ventilation and dependable analgesia with less opioids. Our patients were extubated within 1-11(6±3) minutes, which should be attributed to the perfect nerve block effect.

Although, thoracic epidural anesthesia is a golden standard for thoracic analgesia, but it may induce hypotension frequently. It’s also associated with serious complications, such as epidural hematoma and neuropathy.[5] Therefore, a variety of nerve blocks as alternatives to epidural anesthesia, such as serratus anterior plane block(SAPB), intercostal nerve block(INB), ESPB are used for clinic. Nevertheless, there are some limitations to the above-mentioned methods. The local anesthetic of SAPB is distributed along the midaxillary line nearby the surgical incision, may impede the surgeon to transect the muscular layers. INB requires multi-injection, which makes patient more painful and increases the risk of inadvertent intercostal vessels or pleura puncture. ESPB is administered in intermuscular space, the incidence of complete block is only 1/3.[6] TPB has the advantage of reliable effect which even equals to unilateral epidural anesthesia, and can be performed precisely under ultrasound-guidance. Thus we choose TPB as local anesthesia in our study.

The intercostal(IC) approach and the paralaminar(PL) approach are two commonly used in TPB. According to our experience, single-injection of 20ml ropivacaine 0.375% via PL approach could acquire 4-5 dermatomes of sense blockade, which was consistent with Yasuko Take's conclusion.[7] They found the blocked dermatomes of sense loss in group PL were more than in group IC, The average of blocked dermatomes was 3 in group IC and 4 in group PL. Besides, the PL approach was regarded as a better choice to block the dorsal ramus of thoracic nerves.[8] Our approach of TPB is the same as Taketa's PL approach, and is also consistent with the transversal IAP approach described by Krediet, et al.[20] Unlike them, our needle is inserted into the skin obliquely from the lateral of the probe, and advanced into the TPVS beyond the IAP. Based on our pilot experiment, we found that the block area to caudal was more extensive than that to cephalic. That’s the reason we chose the TPVS of the second fractured rib for injection when the surgical segments were not more than 4 consecutive ribs.

Most of the patients with rib fractures suffered from dyspnea. The satisfactory effect of TPB could improve the oxygenation of the patients. Because respiratory amplitude was increased when the patients didn't feel pain.[13] The patients' tidal volume and frequency during spontaneous breathing can meet the needs of intraoperative oxygenation, even in LMA anesthesia with 50% oxygen. Koo CH concluded the oxygen concentration of 50% could decrease the risk of atelectasis which was caused by high oxygen concentration.[14] Our results showed that all patients kept their SpO_2 at 99.1±1.3% during the operation, including 3 patients whose preoperative SpO_2 was lower than 93%. The minimum SpO_2 was 87%, occurred transiently in one case. His preoperative chest CT showed a large amount of pleural effusion, incomplete atelectasis, and consolidation of inferior lobe on the injured thorax. The decline of SpO_2 was attributed to notable decrease of tidal volume caused by sufentanil. But it rose to 98% in a few minutes and kept at 100% till the end of surgery.

Postoperative pulmonary complications(PPCs) always were concerned in thoracic surgery. Recruitment maneuver and airway suction might be beneficial to the patients during ETI anesthesia. The leak pressure of LMA supreme™ was 27.1 ± 5.2 cmH_2O according to Russo's report.[21] Thus LMA supreme™ could settle for recruitment maneuver in the anesthesia. Meanwhile, the early extubation and good analgesia in our study promoted postoperative cough strength and sputum clearance, which also were beneficial to lung recruitment. In particular, the early recovery of spontaneous breath reduced pulmonary problems associated with mechanical ventilation. Because positive pressure ventilation not only changes the pressure gradient of the thoracic cavity and interferes with the distribution of intrapulmonary ventilation, but also leads to the imbalance of V/Q ratio with excessive or inadequate tidal volume. Besides, barotrauma and volume injury caused by mechanical ventilation can also cause VALI. All of the above show that spontaneous breath is beneficial to lung protection. Noda concluded that patients of VATS with spontaneous breath had fewer postoperative respiratory complications, such as pneumonia and ARDS, than those with ETI anesthesia.[22]

In our study, the postoperative PaO_2 was improved compared to the preoperative PaO_2($p=0.004$) in 20 patients. And no pneumonia was found by chest film after surgery. It seemed that the LMA anesthesia wouldn't increase the incidence of PPCs after rib fractures surgery, but it was limited by the small sample size. We will focus on it in our follow-up study.

The patients appeared carbon dioxide retention in different degrees during spontaneous breathing. The $EtCO_2$ of most patients was below 50mmHg at the end of surgery. The highest value of $EtCO_2$ of our research was 63mmHg, happened in a male. His last $EtCO_2$ was 58mmHg when surgery ended. All patients kept fully conscious after extubation. Their $PaCO_2$ values checked on the second day after surgery were all in the normal range. Permissive hypercapnia has been accepted for a long time, O' Toole[15] believed that hypercapnia could produce an anti-inflammatory effect by inhibiting NF-κB. Other scholars thought that hypercapnia had a protective effect on VILI.[16,17] Hypercapnia can also improve pulmonary compliance by a non-surfactants mechanism, and enhance pulmonary vascular resistance by strengthening hypoxic pulmonary vasoconstriction to decrease pulmonary shunt.[18]

The serratus anterior muscle and latissimus dorsi muscle were innervated by the long thoracic nerve and thoracodorsal nerve, respectively. TPB can't paralyze these muscles. We found one ED95 of rocuronium could weaken muscle twitching when the surgeons transected the muscles by high-frequency electrotome. Glenn S Murphy et al.[11] pointed out that the residual effect of muscle relaxants was one of the causes of postoperative respiratory failure, critical respiratory events observed in 18.0% patients undergoing thoracic procedures. Althausen PL. reported the incidence of re-intubation after surgical stabilization of flail chest was 4.55%(1/22).[12] In our study, all 20 patients recovered spontaneous breathing in the operation and maintained a good level of cough strength after extubation, no one needed for re-intubation. This result was attributed to the patients selection and the underpowered trial relatively to the respiratory complications. We expect that LMA anesthesia can show this advantage with further research.

In our study, the patients felt pain obviously at about 6 hours after the operation. This was consistent with the duration of postoperative analgesia of TPB(303.97±76.08 minutes) reported by Das S, et al.[9] Because PCIA and intravenous infusion of flurbiprofen were used after operation, most patients felt pain acceptably, except 4 patients (20%) with an NRS score of 5. It indicated the multi-mode analgesia protocol was effective and necessary for postoperative analgesia. This result also suggests that we may achieve better postoperative analgesia by TPB catheterization in our future work, as reported by Ge Yeying.[10]

Conclusions

In this study, all patients had stable circulation and breath, good oxygenation and acceptable $EtCO_2$. The surgeons were satisfied with the wound exposion. The patients had smooth extubation, high quality of resuscitation, well cough strength and sputum clearance. Neither throat discomfort, nor PONV was observed. No one suffered from reflux, aspiration, atelectasis. Therefore, we demonstrated that LMA anesthesia combined with nerve block anesthesia can be applied in internal fixation for rib fractures feasibly.

Abbreviations

laryngeal mask (airway): LMA

thoracic paravertebral block: TPB

erector spinae plane block: ESPB

heart rate: HR

blood pressure: BP

pulse oxygen saturation: SpO2

postoperative nausea and vomiting: PONV

numerical rating scale: NRS

end-tidal carbon dioxide concentration: EtCO2

partial pressure of artery oxygen: PaO2

partial pressure of artery carbon dioxide: PaCO2

endotracheal intubation: ETI

ventilator-associated lung injury: VALI

body mass index: BMI

Inferior Articular Process: IAP

thoracic paravertebral space: TPVS

pressure controlled ventilation-volume guaranteed: PCV-VG

tidal volume: Vt

respiratory rate: RR

inspiratory/expiratory: I/E

minimum alveolar concentration: MAC

serratus anterior plane block: SAPB

intercostal nerve block: INB

intercostal: IC

paralaminar: PL

95% effective dose: ED95

Postoperative pulmonary complications: PPCs

Declarations

Ethics approval and consent to participate

This prospective, observational study was approved by the Ethics Committee of Shanghai Sixth People's Hospital, No. 2019-53.

Consent for publication

The informed consent was signed by all patients. Meanwhile, consent for publication have been obtained from them.

Availability of data and material

The datasets used and analysed during the current study are available from the corresponding author on reasonable request.

Competing interests

The authors declare that they have no competing interests.

Funding

Not applicable

Authors' contributions

This study was designed by Jun Cao and Junfeng Zhang and was conducted by Jun Cao, Xiaoyun Gao, Xiaoli Zhang. Xiaoyun Gao and Jing Li were responsible for all date collection. Data was analyzed by Jun Cao.

Acknowledgements

Not applicable

References

1. Fredric M. Pieracci, et al. Consensus statement: Surgical stabilization of rib fractures rib fracture colloquium clinical practice guidelines. Injury. 2017 Feb;48(2):307-321.
2. Diego Gonzalez-Rivas, Cesar Bonome, Eva Fieira, et al. Non-intubated Video-Assisted Thoracoscopic Lung Resections: The Future of Thoracic Surgery? Eur J Cardiothorac Surg. 2016; 49 (3), 721-31.
3. C C Dos Santos, A S Slutsky. Invited review: mechanisms of ventilator-induced lung injury: a perspective. J Appl Physiol (1985) 2000;89:1645-55.
4. L Munk , G Andersen, A M Møller,Post-anaesthetic Emergence Delirium in Adults: Incidence, Predictors and Consequences. Acta Anaesthesiol Scand. 2016;60 (8):1059-66.
5. Rosero EB, Joshi GP. Nationwide incidence of serious complications of epidural analgesia in the United States. Acta Anaesthesiol Scand. 2016;60(6):810–820.

6. Ban C.H. Tsui, Ahtziri Fonseca, Farrukh Munshey, et al. The erector spinae plane (ESP) block: A pooled review of 242 cases. Journal of Clinical Anesthesia 53 (2019) 29–34.
7. Yasuko Taketa, Yumi Irisawa, Taro Fujitani. Comparison of analgesic efficacy between two approaches of paravertebral block for thoracotomy: A randomised trial. Acta Anaesthesiol Scand. 2018;62:1274–1279.
8. Thomas Collin, Julie Cox. Innervation of the chest wall. Chapter 53. Gray's Anatomy: The Anatomical Basis of Clinical Practice, 41st edn.In: Jonathan D Spratt, Standring S, eds. Amsterdam, The Netherlands: Elsevier;2015:944-945.
9. Das S, Bhattacharya P, Mandal MC, et al. Multiple-injection thoracic paravertebral block as an alternative to general anaesthesia for elective breast surgeries: A randomised controlled trial. Indian J Anaesth 2012; 56:27–33.
10. Ge Yeying, Yuan Liyong, Chen Yuebo, et al. Thoracic paravertebral block versus intravenous patient-controlled analgesia for pain treatment in patients with multiple rib fractures. Journal of International Medical Research. 2017,Vol.45(6)2085–2091.
11. Glenn S Murphy et al. Residual Neuromuscular Blockade and Critical Respiratory Events in the Postanesthesia Care Unit.Anesth Analg. 2008;107:130 –7.
12. Althausen PL, Shannon S, Watts C, et al. Early surgical stabilization of flail chest with locked plate fixation. J Orthop Trauma. 2011 Nov;25(11):641-7.
13. Bataille B, Nucci B, De Selle J, et al. Paravertebral block restore diaphragmatic motility measured by ultrasonography in patients with multiple rib fractures. J Clin Anesth. 2017 Nov;42:55-56.
14. Koo CH, Park EY, Lee SY, Ryu JH. The Effects of Intraoperative Inspired Oxygen Fraction on Postoperative Pulmonary Parameters in Patients with General Anesthesia: A Systemic Review and Meta-Analysis. J Clin Med. 2019 Apr;28:8(5).
15. O' Toole D, Hassett P, Contreras M, et al. Hypercapnic acidosis attenuates pulmonary epithelial wound repair by an NF- kB dependent mechanism[J]. Thorax, 2009, 64(11):976- 982.
16. Sinclair SE, Kregenow DA, Lamm WJ, et al. Hypercapnic acidosis is protective in an in vivo model of ventilator-induced lung injury[J]. Am J Respir Crit Care Med. 2002;166(3):403-408.
17. Broccard AF, Hotchkiss JR, Vannay C, et al. Protective effects of hypercapnic acidosis on ventilator-induced lung injury. Am J Respir Crit Care Med. 2001;164(5):802- 806.
18. Jonathan M, Eddy F. Carbon Dioxide in the Critically Ill: Too Much or Too Little of a Good Thing? [J].Respir Care. 2014;59(10):1597-1605.
19. Luftig J, Mantuani D, Herring AA, et al. Successful emergency pain control for posterior rib fractures with ultrasound-guided erector spinae plane block. Am J Emerg Med. 2018 Aug;36(8):1391-1396.
20. Krediet AC, Moayeri N, van Geffen GJ, et al. Different Approaches to Ultrasound-guided Thoracic Paravertebral Block: An Illustrated Review. Anesthesiology. 2015 Aug;123(2):459-74.
21. Sebastian G Russo, Stephan Cremer, Tamara Galli, et al. Randomized comparison of the i-gel™, the LMA Supreme™, and the Laryngeal Tube Suction-D using clinical and fibreoptic assessments in

elective patients. BMC Anesthesiol. 2012; 12: 18.

22. Noda M, Okada Y, Maeda S, et al. Is there a benefit of awake thoracoscopic surgery in patients with secondary spontaneous pneumothorax? J Thorac Cardiovasc Surg. 2012;143:613-6.

Figures

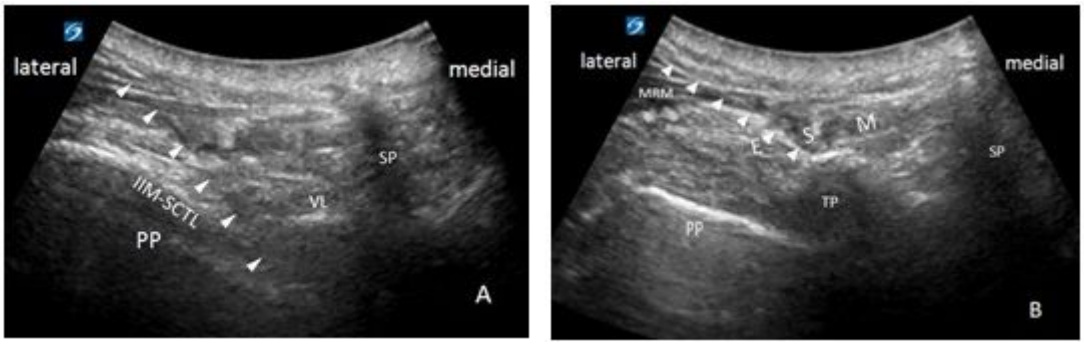

Figure 1

Ultrasound-guided transversal in-plane approach. A, The image of TPB. B, The image of ESPB. Arrowheads indicate the needle. PP, Parietal Pleura; VL, Vertebral Lamina; TP, Transverse Process; SP, Spinae Process; IIM-SCTL, Internal Intercostal Membrane, and Superior Costotransverse Ligament; ESM, Erector Spinae Muscle; MRM, Musculus Rhomboideus Major.

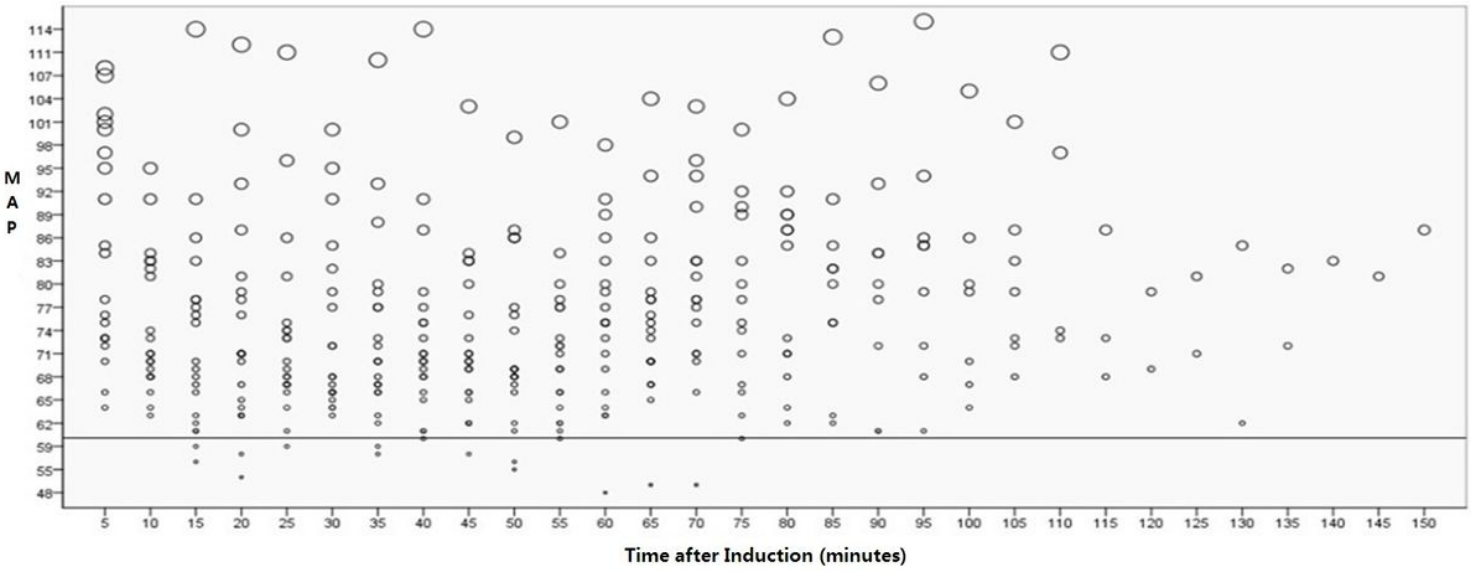

Figure 2

Scatterplot of all patients' MAPs acquired every five minutes during the anesthesia.

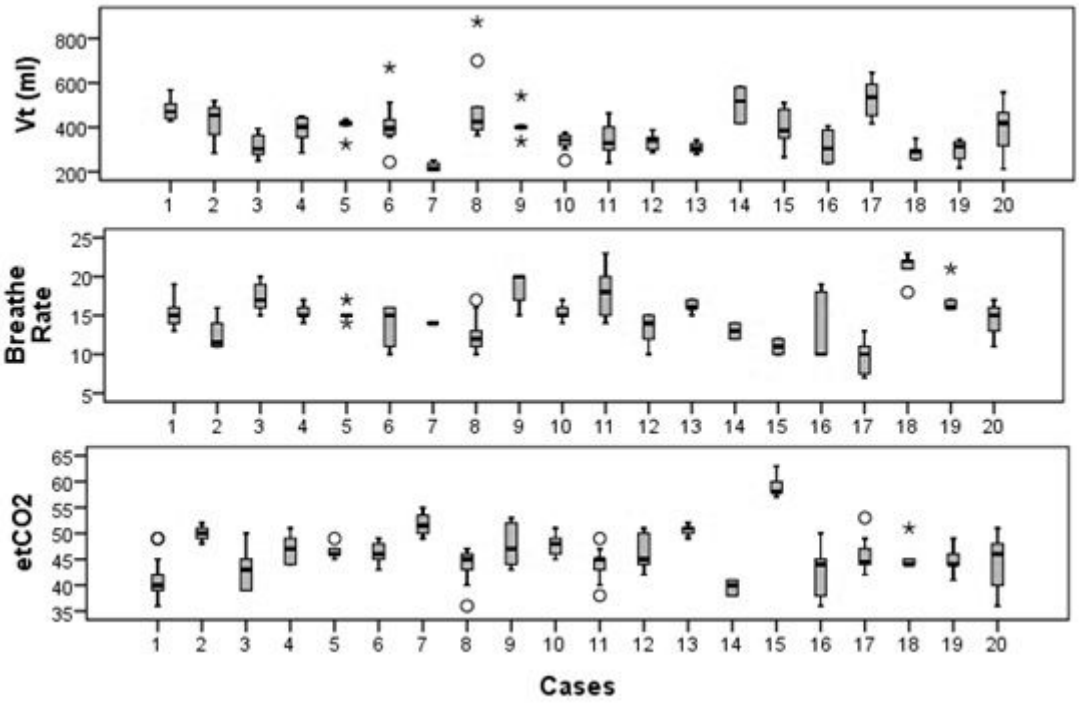

Figure 3

Boxplot of respiratory parameters(Vt, RR, and EtCO2) when patients breathe spontaneously.

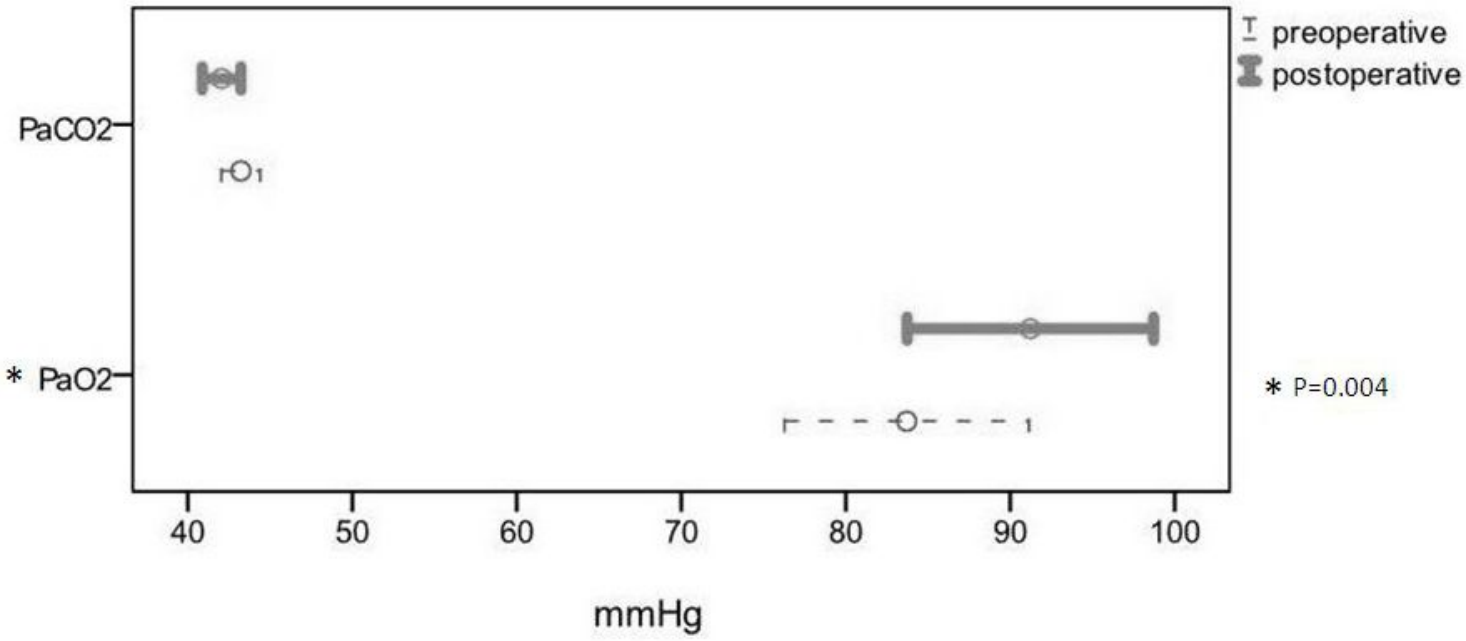

Figure 4

Blood gas analysis(PaO2 and PaCO2) of pre-operation and post-operation.

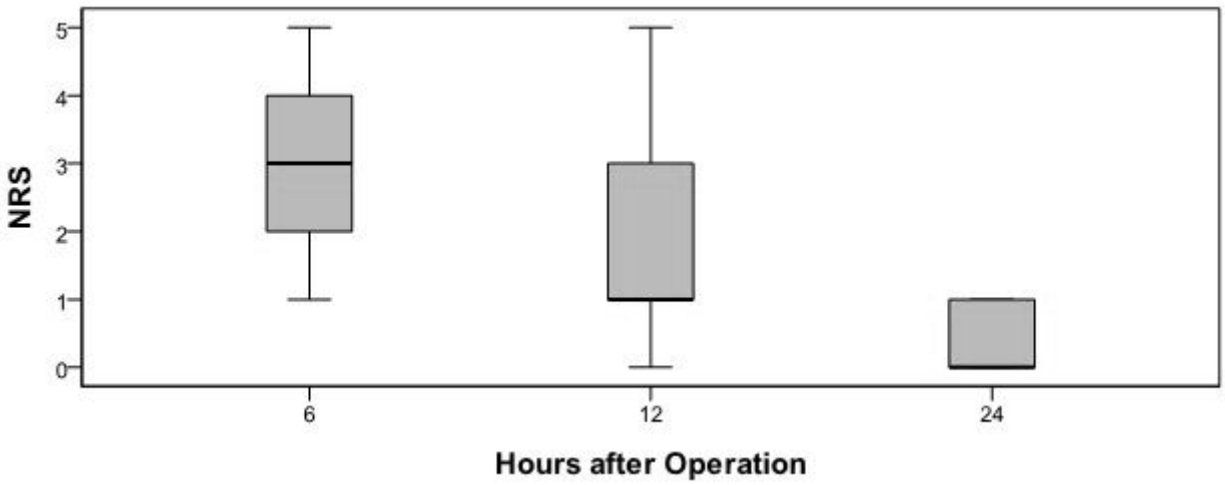

Figure 5

Boxplot of patients' NRS at 6, 12, 24 hours after surgery.