Modified-ramped position: a new position for intubation of obese females: A randomized controlled study.

ahmed hasanin (ahmedmohamedhasanin@gmail.com)
Cairo University https://orcid.org/0000-0001-9947-5863

Hager Tarek
Cairo University

Maha MA Mostafa
Cairo University

Amany Arafa
Cairo University

Ahmed G Safina
Cairo University

Mona H Elsherbiny
Cairo University

Osama Hosny
Cairo University

Ahmed A Gado
Cairo University

Tarek Almenesey
Beni Suef University

Ghada Adel Hamden
Cairo University

Mohamed Mahmoud
Cairo University

Sarah Amin
Cairo University

Research article

Keywords: Obese; laryngoscopy; ramped position; modified-ramped position.

Posted Date: November 14th, 2019

DOI: https://doi.org/10.21203/rs.2.17108/v1

Version of Record: A version of this preprint was published on June 17th, 2020. See the published version at https://doi.org/10.1186/s12871-020-01070-2.

Abstract

Endotracheal intubation requires optimum position of the head and neck. In obese females, the usual ramped position might not provide adequate intubating conditions. We hypothesized that a new position (modified-ramped position) during induction of anesthesia would facilitate endotracheal intubation through bringing the breasts away from the laryngoscope and would also improve the laryngeal visualization Methods Sixty obese females scheduled for general anesthesia were randomly assigned into either ramped or modified-ramped position during induction of anesthesia. In the modified-ramped position (n=30), the patient shoulders were elevated using special pillow, and the head was extended to the most possible range. Our primary outcome was incidence of failure of laryngoscope insertion in the oral cavity due to large breast with the need to repositioning “elevation of the patient’s shoulder during intubation”. Other outcomes included time till vocal cord visualization, time till successful endotracheal intubation, difficulty of mask ventilation, and Cormack-Lehane grade for laryngeal view. Results Fourteen patients (47%) in ramped group required repositioning to facilitate introduction of the laryngoscopy in comparison to one patient (3%) in the modified-ramped position ($p<0.001$). Modified-ramped position showed lower incidence of difficult mask ventilation, shorter time for glottic visualization, and shorter time for endotracheal tube insertion compared to the ramped position. The Cormack-Lehane grade was better in the modified-ramped position. Conclusion Modified-ramped position provided better intubating conditions, improved the laryngeal view, and eliminated the need for repositioning of obese female patients during insertion of the laryngoscope compared to ramped position

Background

Adequate conditions for endotracheal intubation require appropriate positioning of head and neck. The most appropriate position for laryngeal visualization, termed “sniffing position” [1], requires flexion of the neck by 35° (achieved by head elevation), and extension of the head by 15° [2] to have the sternum at the same level of external auditory meatus [3,4]. Sniffing position maintains the alignment of the three axes, namely oral, pharyngeal, and laryngeal axes, to reach the optimal laryngeal visualization [1]. In obese patients, the ramped position was suggested to achieve better intubating conditions [3,5]. However, the data for the optimum position for intubating obese patients is conflicting [3,5,6]. Semler et al pointed out that putting patients in ramped position increased the numbers of intubation trials through wide-ranging of body mass indices. [6] Hence, it had been suggested that more research and modifications are warranted to reach the proper intubating position [7,8].

In addition to difficult laryngeal visualization during intubation of obese females, impedance of laryngoscopy by large breasts could further prolong the intubation process and might lead to serious hypoxia [9]. Most of the positions described in literature were concerned with facilitating laryngeal visualization. No position to the best of our knowledge was applied to aid the introduction of the laryngoscope in the presence of large breasts.

We hypothesized that using a special pillow (Figure 1) to achieve a modified-ramped position, through slight neck extension than that offered in the ramped position, and more head extension, would improve the intubating conditions in obese females. We hypothesized that this slight head, and neck extension at the beginning of the laryngoscopy would bring the breasts away from the laryngoscope and would also improve the laryngeal visualization. The aim of this work is to investigate the feasibility of using the modified-ramped position for intubation of obese females in comparison to the traditional ramped position.

Methods

This randomized controlled study was conducted in Cairo University Hospital after institutional board review approval (N-107-2018) from September 2018 till February 2019. The study was registered before recruitment of the first participant at clinicaltrials.gov registry system on 21 August 2018 (NCT03640442). Written informed consents was obtained from all participants before enrollment. Randomization was achieved using computer-generated sequence. Concealment was achieved using opaque closed envelopes by research assistant who had no further involvement in the study.

The study included: obese female patients (body mass index above 30 kg/m^2) aged above 18 years scheduled for any operation under general anesthesia with endotracheal intubation. Patients with facial or neck scars, edentulous patients, patients with unstable cervical spine, patients with limited neck extension and patients with airway masses were excluded.

On arrival to the operating room, airway assessment for the patients was performed (Mallampati score, thyromental distance, mouth opening, and neck extension). Patients received the routine preoperative medications (metoclopramide 10 mg intravenous and ranitidine 50 mg intravenous). Routine monitors was applied (electrocardiogram, non-invasive blood pressure monitor, and pulse oximetry was applied before induction of anesthesia. End-tidal capnography was applied after endotracheal intubation). Before induction of anesthesia, patients were randomized to be initially settled into either ramped group (n=30) or modified ramped group (n=30).

Details of each position

Ramped position: This position was achieved by elevation of the shoulders and the head elevation till achieving alignment of sternal notch and external auditory meatus (as shown in figure 2).

Modified ramped position: This position was achieved using a special pillow (shown in figure 3). The shoulders were elevated, and the head was extended to the most possible range to bring the breasts away from the laryngoscopy.

Anesthesia was induced using propofol (2 mg/kg), atracurium (0.5 mg/kg), and fentanyl (2 mcg/kg). Ventilation was maintained using face mask for 3-4 minutes, then, the endotracheal tube was inserted using proper sized Macintosh blade. If laryngeal visualization was not sufficient in the modified-ramped

position group, the head was manually elevated to achieve the ramped position. The position of endotracheal tube was confirmed using capnography. The special pillow was removed after confirming successful intubation.

Primary outcome

Incidence of difficult laryngoscopy defined as “failure to insert the laryngoscope in the oral cavity due to large breast with the need to reposition the patient to insert the laryngoscope”. The term “reposition” means: the need to make further elevation of the patient shoulders by the assistant in order to extend the patient neck and to move the breasts away from the handle of the laryngoscope.

Secondary outcomes

Time till complete visualization of the vocal cords: defined as the time from starting to handle the laryngoscope till visualization of the vocal cords.

Time of endotracheal intubation: time from starting to handle the laryngoscope till confirmation of the endotracheal tube position by capnography.

Cormack-Lehane [10] grade of vocal cord view (with and without cricoid pressure).

Incidence of relatively difficult mask ventilation: defined as the need of high force and/or oral airway insertion for maintenance of adequate mask ventilation.

Number of trials for endotracheal tube insertion.

Incidence of hypoxemia (defined as oxygen saturation less than 90%) during the period starting from induction of anesthesia till insertion of the endotracheal tube

Oxygen saturation every 30 seconds starting from induction of anesthesia till confirmation of the position of endotracheal tube

End-tidal CO_2 reading just after insertion of the endotracheal tube.

Incidence of airway trauma (teeth, lips, and tongue trauma)

Statistical analysis

Our primary outcome was the incidence of difficult laryngoscopy. According to a pilot study, we found that the incidence of difficult laryngoscopy in obese females is 80%. We used G power software (3.1.9.2) to calculate a sample size that detects an absolute risk reduction of 40% in the incidence of difficult laryngoscopy. A total number of 54 patients was calculated to have a study power of 80% and alpha error of 0.05. the number was increased to 60 patients to compensate for dropouts.

SPSS 15 package was used for data analysis. Categorical data were analyzed using Chi square test. Continuous data were analyzed using unpaired t test or Mann Whitney-U test as appropriate. Repeated measures were analyzed using analysis of variance (ANOVA) test for repeated measures. P value of 0.05 or lower is statistically significant.

Results

Sixty-five patients were screened for eligibility. Five patients were excluded for not meeting our inclusion criteria, 60 patients were randomized into one of the two groups; all of them completed the intervention and were available for final analysis (Figure 1). Demographic data and baseline characteristics were comparable between both groups (table 1). The modified-ramped group showed lower incidence of difficult mask ventilation, less need for repositioning, shorter time for glottic visualization, and shorter time for endotracheal tube insertion compared to the ramped position (table 2). The Cormack-Lehane grade of laryngeal view was better in the modified-ramped position (table 2); however, with cricoid pressure, most of the patients had adequate laryngeal visualization (Cormack-Lehane grade < III). None of the patients in the modified-ramped position needed head elevation to improve the laryngeal view. None of our patients had significant hypoxemia nor airway trauma (table 2).

Discussion

We reported that our modification of the ramped position improved the intubation conditions of obese females. This is demonstrated by the better laryngeal visualization, the less need of repositioning, and the shorter intubation time in the modified ramped position.

The original ramped position, by elevation of the patient's head whilst keeping the face in horizontal position, had been described for facilitating airway management of obese patients.

In obese patients, increased fat deposition in the chest wall especially in the back increases their antero-posterior chest diameter and consequently, impairs the application of ordinary sniffing position, the recommended position of laryngoscopy in non-obese patients. This high chest/head ratio in obese individuals would result in a lower head position when the patient lies flat; thus, ramped position was proposed to overcome this problem. Collins et al were the first to report that ramped position is superior to sniffing position in morbidly obese patients in terms of laryngeal view; however, they did not report major difference in the difficulty of intubation [5]. Since then, the evidence on comparison of ramped and sniffing positions is relatively conflicting. Ramped position was proved superior to sniffing position in both obese, non-obese populations [11]; and in patients with expected difficult intubation [12]. Semler et al had, surprisingly, reported different results which favored the sniffing position over the ramped position in 260 critically ill patients [6]. Therefore, further research was suggested to reach the proper intubating position [7,8].

In our patients, we introduced a novel modification on the ramped position by the aid of a special pillow. Our modification achieved more neck and head extension than that of the ramped position. This position was hypothesized to 1- Facilitate the insertion of laryngoscope into the oral cavity 2- Improve the mask ventilation. 3- Improve the grade of laryngeal view.

One of the problems in airway management of obese females is the difficulty of insertion of the laryngoscope in the mouth cavity [9]. We reported that patients in modified-ramped position showed easier laryngoscopy and less need for patient reposition. Performing neck extension in the modified-ramped position gave more space for the handle of the laryngoscope away from the sternum and the breast of the patient.

We reported that mask ventilation was easier in the modified-ramped position. We explain this improvement by the more space for movement of the jaw when the neck is in extension; whilst, the accumulated fat in the neck and in the lower face would impair jaw movement when the head is in the horizontal plane in the ordinary ramped position. Moreover, when the physician pulls the patient jaw upwards with head in the tilted position, this moves the jaw in 2 directions (anterior and caudal); this would provide better airway patency than moving the jaw in 1 direction (anterior) only when the head in horizontal in the ramped position.

The impact of patient position on the grade of laryngeal view is a principal factor in assessment of different positions. We had no data about the Cormack-Lehane grade in the modified-ramped position. Therefore, we suggested that manual mobilization of the head would be performed as a rescue maneuver in case of difficult visualization of the glottis; however, we found that, the laryngeal view was better in modified-ramped position. We would clarify that the proper visualization of laryngeal view is based in alignment of oral, pharyngeal, and laryngeal axes which is classically achieved in the sniffing position. The use of ramped position for improving the laryngeal visualization, although widely applied, is still a controversial issue. The proper alignment of 3 airway axes was confirmed in the sniffing position using MRI [4]; however, in the ramped position, the alignment of the 3 axes is only a theoretical assumption [5] without similar MRI confirmation. Semler et al had demonstrated that ramped position might worsen the laryngoscopic view and increase the number of intubation attempts compared to the sniffing position.

Proper head and neck position is an important step for successful laryngoscopy and endotracheal intubation. Airway management in obese patients is relatively challenging due to accumulated fat deposition in the airway that might impair adequate ventilation and visualization of the larynx; furthermore, insertion of the laryngoscope in the oral cavity might also be difficult due to accumulated fat in the anterior chest wall and breasts. Obese patients commonly have restrictive lung disorders which impair their tolerance to any delay in endotracheal intubation [13]. We provided a novel modification for the ramped position which is easily achieved using a simple pillow which provided good space for the handle of the laryngoscope without impairment of the laryngeal visualization. The modified-ramped position would help to avoid the hazards of re-positioning of the patient which is common in obese

females; and would consequently avoid delayed endotracheal intubation especially in this vulnerable population.

Our study had some limitation: 1- It is a single center study. 2- Our methodology did not enable blinding of the physician. 3- We investigated our approach in elective, stable patients. We need to confirm its benefits in emergency endotracheal intubation.

Conclusion

In conclusion, modified-ramped position provided better intubating conditions, improved the laryngeal view, and eliminated the need for repositioning of obese female patients during insertion of the laryngoscope.

List Of Abbreviations

Analysis of variance (ANOVA), Statistical package for social science (SPSS)

Declarations

Ethical approval and consent to participate: ethical approval was obtained from Cairo university hospitals research ethics committee was obtained (N-107-2108) at June 2018**.** Written informed consents were obtained from participants before inclusion.

Consent for publication: not applicable

Availability of data and material:

The datasets used and/or analyzed during the current study are available from the corresponding author on reasonable request.

Competing interests: The authors declare that they have no competing interests

Funding: no funding.

Author contributions:

AH: This author helped in conception of the idea, study design, analysis of the data, and drafting the manuscript.

HT, MMM, AGS, MHE, OH, AG, TA, GAH, MM, SA: These authors helped in acquisition of data, and drafting the manuscript.

All authors approved the manuscript and agreed to be accountable for all aspects of the work.

Acknowledgments

We would like to acknowledge all the residents and assistant lecturers in our department who helped in this work.

References

1. Bannister FB MR. Direct laryngoscopy and tracheal intubation. Lancet. 1944;ii:651–4.
2. IW M. Endotracheal anesthesia. Am J Surg. 1936;34:450–5.
3. Rao SL, Kunselman AR, Schuler HG, DesHarnais S. Laryngoscopy and Tracheal Intubation in the Head-Elevated Position in Obese Patients: A Randomized, Controlled, Equivalence Trial. Anesth Analg. 2008;107:1912–8.
4. Greenland KB, Edwards MJ, Hutton NJ. External auditory meatus-sternal notch relationship in adults in the sniffing position: A magnetic resonance imaging study. Br. J. Anaesth. 2010;104:268–9.
5. Collins JS, Lemmens HJM, Brodsky JB, Brock-Utne JG, Levitan RM. Laryngoscopy and Morbid Obesity: a Comparison of the “Sniff” and “Ramped” Positions. Obes Surg. 2004;14:1171–5.
6. Semler MW, Janz DR, Russell DW, Casey JD, Lentz RJ, Zouk AN, et al. A Multicenter, Randomized Trial of Ramped Position vs Sniffing Position During Endotracheal Intubation of Critically Ill Adults. Chest. 2017;152:712–22.
7. Rahiman SN, Keane M. Ramped Position: What the “Neck”! Chest [Internet]. American College of Chest Physicians; 2018;153:339–48.
8. Vetrugno L, Orso D, Bove T. Ramped position, an uncertain future. Crit Care. 2018;22:6–7.
9. Mushambi MC, Kinsella SM, Popat M, Swales H, Ramaswamy KK, Winton AL, et al. Obstetric Anaesthetists’ Association and Difficult Airway Society guidelines for the management of difficult and failed tracheal intubation in obstetrics. Anaesthesia. 2015;70:1286–306.
10. Koh LKD, Kong CF, Ip-Yam PC. The Modified Cormack-Lehane Score for the Grading of Direct Laryngoscopy: Evaluation in the Asian Population. Anaesth Intensive Care. 2002;30:48–51.
11. Lebowitz PW, Shay H, Straker T, Rubin D, Bodner S. Shoulder and head elevation improves laryngoscopic view for tracheal intubation in nonobese as well as obese individuals. J Clin. Anesth. 2012;24:104–8.
12. Lee J-H, Jung H-C, Shim J-H, Lee C. Comparison of the rate of successful endotracheal intubation between the "sniffing" and "ramped" positions in patients with an expected difficult intubation: a prospective randomized study. Korean J Anesthesiol 2015;68:116.
13. Hasanin A, Taha K, Abdelhamid B, Abougabal A, Elsayad M, Refaie A, et al. Evaluation of the effects of dexmedetomidine infusion on oxygenation and lung mechanics in morbidly obese patients with restrictive lung disease. BMC Anesthesiol. 2018;18:104.

Tables

Table 1: Baseline characteristics. Data are presented as mean (standard deviation), and frequency (%).

	Ramped group (n=30)	Modified ramped group (n=30)	P value
Age (years)	42 (13)	39 (9)	0.26
Body mass index (Kg/m^2)	41(6)	43 (7)	0.4
Diabetes (%)	4(13)	5(17)	1
Hypertension (%)	6(20)	9 (30)	0.55
Snoring (%)	11(37)	9(30)	0.78
Mallampati score (%) Grade I Grade II Grade III Grade IV	 3(10) 15(50) 10(33) 2(7)	 8(27) 10(33) 10(33) 2(7)	0.35

Table 2: Outcomes. Data are presented as mean (standard deviation), median (quartiles), and frequency (%).

	Ramped group (n=30)	Modified ramped group (n=30)	P value
Relatively difficult mask ventilation	25 (83%)*	6 (20%)	<0.001
The need for re-positioning	14 (47%)*	1 (3%)	<0.001
Time till vocal cord visualization (seconds)	17 (2)*	12 (3)	<0.001
Time till endotracheal tube insertion (seconds)	42 (3)*	33 (2)	<0.001
CL view without cricoid pressure	IIb (IIa-IIb) *	IIa (I-IIb)	0.01
CL view with cricoid pressure	I (I-IIa) *	I (I-I)	0.03
CL view without cricoid pressure (%) I II(a) II(b) III	 5 (17) 7 (24) 12 (40) 6 (20)	 14 (47) 8 (27) 5 (17) 3 (10)	0.04
CL view with cricoid pressure (%) I II(a) II(b) III	 16 (53) 11 (37) 3 (10)	 24 (80) 5 (17) 1 (3)	0.09
Number of intubation trials	1(1,1)	1(1,1)	1
First end-tidal CO_2 reading (mmHg)	35.1 (4.4)	34.9 (3.9)	0.88

CL: Cormack-Lehane. *denotes statistical significance (P<0.05).

Figures

Figure 1

The special pillow designed for achieving modified ramped position.

Figure 2

Ramped position.

Figure 3

Modified ramped position.

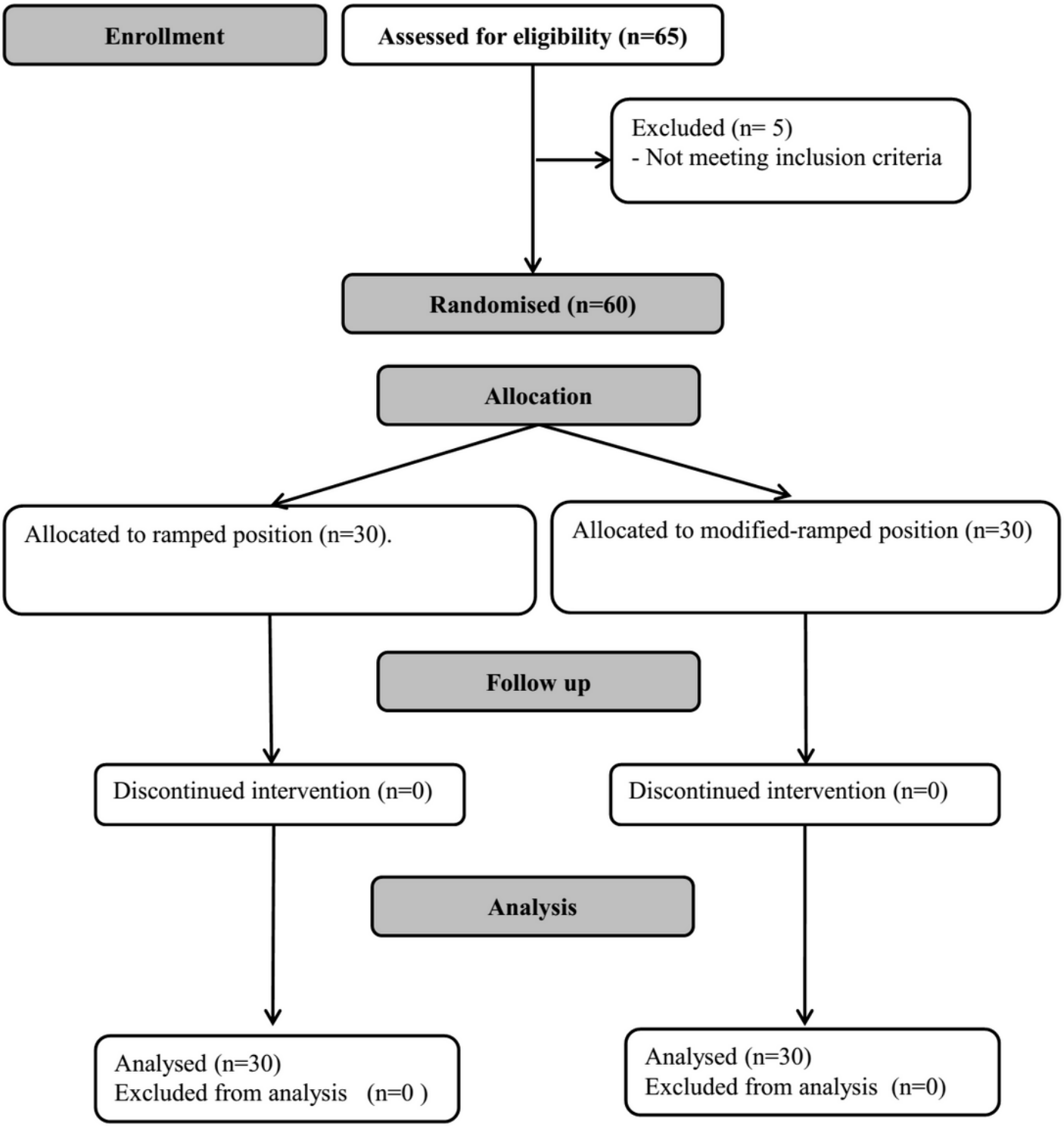

Figure 4

Patient enrollment.

Supplementary Files

This is a list of supplementary files associated with this preprint. Click to download.

- CONSORTChecklist.pdf